

Management of Coronary Sinus Ostial Atresia during a Staged Operation of a Functional Single Ventricle

Seung Ri Kang, M.D.¹, Won Kyoun Park, M.D.¹, Bo Sang Kwon, M.D.¹,
Jae Kon Ko, M.D.², Hyun Woo Goo, M.D.³, Jeong-Jun Park, M.D.⁴

Divisions of ¹Pediatric Cardiac Surgery, ²Pediatric Cardiology, and ³Radiology, Asan Medical Center, University of Ulsan College of Medicine, ⁴Department of Thoracic and Cardiovascular Surgery, Ewha Womans University Mokdong Hospital, Ewha Womans University School of Medicine

Coronary sinus ostial atresia (CSOA) with persistent left superior vena cava (LSVC) in the absence of an unroofed coronary sinus is a benign and rare anomaly that may be taken lightly in most instances. However, if overlooked in patients undergoing univentricular heart repair such as bidirectional Glenn or Fontan-type surgery, fatal surgical outcomes may occur due to coronary venous drainage failure. We report a case of CSOA with a persistent LSVC that was managed through coronary sinus rerouting during a total cavopulmonary connection, and provide a review of the literature regarding this rare anomaly.

Key words: 1. Coronary sinus
2. Fontan procedure
3. Heart bypass, right

Case report

A 3-year-old boy with a previous diagnosis of double outlet right ventricle, double inlet right ventricle, pulmonary stenosis, ventricular septal defect, bilateral superior vena cava, and dextrocardia was admitted. At 4 months of age, he underwent emergent placement of a right modified Blalock-Taussig (RMBT) shunt with a 3.5 mm Gore-Tex stretch vascular pediatric grafts (WL Gore & Associates, Flagstaff, AZ, USA), atrial septectomy, and patent ductus arteriosus ligation due to hypoxia. Then, at 7 months of age, he underwent a non-pulsatile, bidirectional cavopulmonary shunt (BCPS) with division of the azygos vein and main pulmonary artery, take-down of the previously inserted RMBT shunt, as well as implantation of a permanent pacemaker due to Mobitz type II at-

rioventricular block that manifested as severe bradycardia and signs of organ malperfusion. Although we knew that the coronary sinus ostial atresia (CSOA) in this patient was a surgical issue, the boy only weighed 5 kg when undergoing the BCPS procedure, and a computed tomography (CT) scan revealed the left superior vena cava (LSVC) to be very small (about 2 mm). We were concerned that rerouting such a small vessel would possibly result in stricture later, as it is a very low-pressure vessel. Thus, we decided to perform CSOA repair at the time of the Fontan operation. The boy, at the age of 3 years, was admitted for the final stage of his univentricular heart (UVH) repair, the Fontan operation. Preoperative echocardiography showed good BCPS flow with good ventricular function, a large interatrial communication, no significant valve dysfunction, grade 1-2 re-

Received: August 24, 2017, Revised: October 22, 2017, Accepted: October 23, 2017, Published online: April 5, 2018

Corresponding author: Jeong-Jun Park, Department of Thoracic and Cardiovascular Surgery, Ewha Womans University Mokdong Hospital, 1071 Anyangcheon-ro, Yangcheon-gu, Seoul 07985, Korea
(Tel) 82-2-2650-2950 (Fax) 82-2-2650-2085 (E-mail) jjparkmdkr@gmail.com

© The Korean Society for Thoracic and Cardiovascular Surgery. 2018. All right reserved.

© This is an open access article distributed under the terms of the Creative Commons Attribution Non-Commercial License (<http://creativecommons.org/licenses/by-nc/4.0>) which permits unrestricted non-commercial use, distribution, and reproduction in any medium, provided the original work is properly cited.

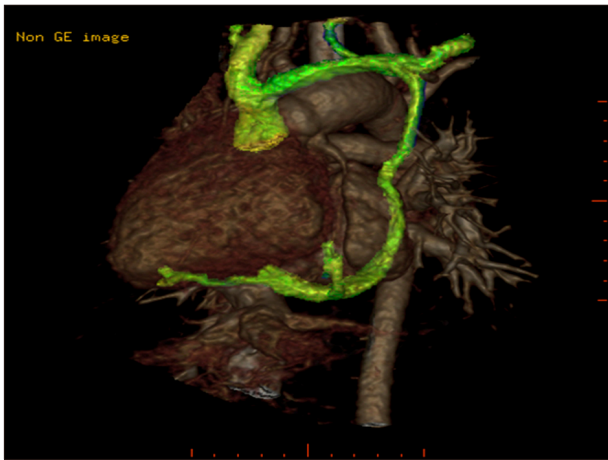


Fig. 1. Computed tomography scan showing a dilated coronary sinus and a left superior vena cava to left innominate vein communication.

gurgitation, and a left vertical vein draining into the left innominate vein, with antegrade and retrograde flow. A CT scan performed prior to the BCPS procedure showed a dilated coronary sinus as well as a LSVC to left innominate vein communication (Fig. 1). As planned, he underwent an extracardiac conduit Fontan operation, as well as coronary sinus rerouting with division of the LSVC. Cannulation was done through the ascending aorta, right superior vena cava (RSVC), and inferior vena cava (IVC). The Fontan circulation was completed by anastomosis of the IVC and pulmonary artery using an 18-mm Gore-Tex Stretch Vascular Graft (WL Gore & Associates). The LSVC was divided, and the mobilized, proximal part of the LSVC was anastomosed and rerouted into the left atrium (LA) to allow unroofed drainage of the coronary venous flow, a method previously described by Oshima et al. [1] in 2004 (Fig. 2). The total aortic cross-clamp time was 30 minutes, the total cardiopulmonary bypass time was 100 minutes, and the operation was uneventful. Postoperative echocardiography showed good Fontan and BCPS flow and the coronary sinus unroofing site was measured at 7.27 mm. The boy was transferred to the general ward on postoperative day 3, and was discharged without any specific complications on postoperative day 20. Thirteen months after the completion of UVH repair, he is receiving outpatient follow-up and doing well. However, a future CT scan and echocardiography is warranted for making exact measurements and for

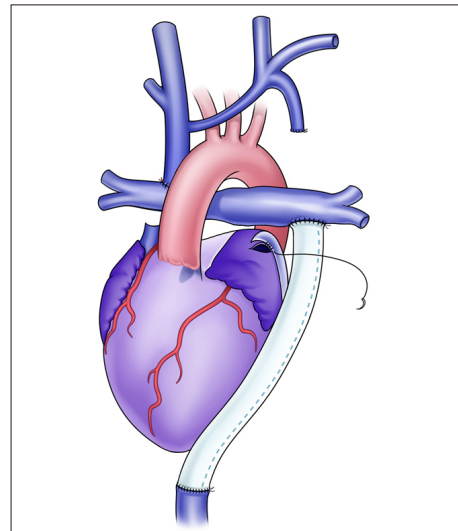


Fig. 2. Postoperative schematic drawing of the described method. The coronary venous flow was rerouted by anastomosis of divided proximal left superior vena cava into the left atrium.

assessing possible signs of stenosis of the unroofed coronary sinus.

Discussion

CSOA was first reported in 1738 [2]. It can be classified into 1 of 2 categories, depending on whether it involves drainage into a persistent LSVC and then into the RSVC through a vertical vein or innominate vein, or drainage directly into a cardiac chamber. In the absence of other cardiac anomalies, the diagnosis of CSOA with persistent LSVC is usually incidental and clinically benign, compatible with the normal drainage of coronary venous flow without physiological consequences.

During cardiac surgery, regardless of whether it is univentricular or biventricular repair, if the LSVC is ligated without providing another source of coronary venous drainage, coronary venous hypertension can deteriorate myocardial perfusion, which can result in a low cardiac output state and mortality [3]. Additionally, direct cannulation of the LSVC can lead to poor cardiac contraction, and stretching and obstruction may occur during median sternotomy [1]. In other words, although CSOA with LSVC is a benign anomaly, protection of the LSVC is crucial even in biventricular repair after recognition of the absence of other routes of coronary venous drainage. In the set-

ting of UVH repair, especially during operations that do not require inspection of the right atrial cavity to confirm CSOA, special considerations must be kept in mind, as incorporating the LSVC into the cavopulmonary circulation must be considered as a possibility for CSOA if there is dilation of the LSVC or the coronary sinus. A bilateral BCPS procedure, which entails ligation of the LSVC and anastomosis of the distal end of the LSVC to the pulmonary artery, can obstruct coronary venous flow. Dual drainage of the coronary sinus without ligation of the LSVC can also block coronary venous flow due to the high pressure of the cavopulmonary circulation [4].

The diagnosis can be rather challenging, as routine preoperative echocardiography may merely hint at this anomaly, and failure to recognize and appropriately handle this condition can result in postoperative mortality. Accordingly, there have been reported cases with fatal results found at autopsies, and CSOA has also been frequently discovered as an incidental intraoperative finding [5]. In our case, echocardiography results revealing retrograde flow of the LSVC into the innominate vein prior to the boy's initial palliative operation led us to suspect CSOA with LSVC, and the final confirmation was made through heart CT, a diagnostic method that has been described in the literature [6]. As the final diagnosis was made using a different method in each case that has been reported, there seems to be no clear guideline. However, retrograde flow of the LSVC or a vertical vein with dilation of the coronary sinus on routine echocardiography should alert surgeons and cardiologists to the possibility of CSOA, and a preoperative CT scan or angiography should confirm the precise anatomy and direction of flow.

As for the surgical technique, several methods have been described in the literature. In 2002, Ohta et al. [7] introduced the use of a probe to guide the open end of the LSVC into the LA after LSVC ligation. Fulton and colleagues described a technique of anastomosis of a connecting vein with the coronary sinus to the LA appendage given the possibility of damaging the atrioventricular node of a diminutive LA [8]. We utilized a simple division and unroofing techni-

que due to its simplicity and the possibility of enabling wide, uninterrupted drainage of the coronary venous flow, as shown in our postoperative studies.

In conclusion, CSOA with LSVC is a rare and physiologically harmless anomaly. However, in the setting of UVH repair, special attention must be paid due to the possible detrimental effects of interrupted coronary venous drainage. We report a case of successful surgical management of this condition, and provide a review of the relevant literature.

Conflict of interest

No potential conflict of interest relevant to this article was reported.

References

1. Oshima Y, Doi Y, Misaki T, Ichida F. *Surgical repair of coronary sinus orifice atresia*. Eur J Cardiothorac Surg 2005;27:351-2.
2. Le Cat CN. *Histoire de l'Academie royale des sciences*. Paris: De L'Imprimerie Royale; 1738.
3. Choi ES, Kim WH, Park SJ, Kwak JG, Seo JW. *Low cardiac output after division of the left superior vena cava during a Norwood operation for hypoplastic left heart syndrome in a patient with coronary sinus orifice atresia: a case report*. Korean J Thorac Cardiovasc Surg 2010;43:161-3.
4. Sim HT, Yu JJ, Goo HW, Yun TJ. *Coronary sinus ostial atresia associated with functionally single ventricle: persistent left superior vena cava should be ligated upon coronary sinus unroofing and bidirectional Glenn shunt*. Pediatr Cardiol 2013;34:1024-6.
5. Santoscoy R, Walters HL 3rd, Ross RD, Lyons JM, Hakimi M. *Coronary sinus ostial atresia with persistent left superior vena cava*. Ann Thorac Surg 1996;61:879-82.
6. Kim C, Goo HW, Yu JJ, Yun TJ. *Coronary sinus ostial atresia with persistent left superior vena cava demonstrated on cardiac CT in an infant with a functional single ventricle*. Pediatr Radiol 2012;42:761-3.
7. Ohta N, Sakamoto K, Kado M, Nishioka M, Yokota M. *Surgical treatment of coronary sinus orifice atresia with hypoplastic left heart syndrome after total cavo-pulmonary connection*. Ann Thorac Surg 2002;73:653-5.
8. Fulton JO, Mas C, Brizard CP, Karl TR. *The surgical importance of coronary sinus orifice atresia*. Ann Thorac Surg 1998;66:2112-4.