




Arab Journal of Urology
(Official Journal of the Arab Association of Urology)

www.sciencedirect.com



ONCOLOGY/RECONSTRUCTION
ORIGINAL ARTICLE

Repair of panurethral stricture: Proximal ventral and distal dorsal onlay technique of buccal mucosal graft urethroplasty



Subbarao Chodiseti, Yogesh Boddepalli *, Malakondareddy Kota

Department of Urology, Andhra Medical College, Andhra Pradesh, India

Received 27 July 2017, Received in revised form 23 October 2017, Accepted 14 November 2017
Available online 26 December 2017

KEYWORDS

Buccal mucosal graft urethroplasty;
Dorsal onlay;
Panurethral stricture;
Stricture urethra;
Ventral onlay

ABBREVIATIONS

BMG, buccal mucosal graft;
DVIU, direct visual internal urethrotomy;
LS, lichen sclerosus;
SPC, suprapubic cystostomy

Abstract Objective: To report the surgical details and results of our technique of buccal mucosal graft (BMG) urethroplasty for panurethral stricture, as many studies have reported repair of panurethral stricture by single-stage BMG urethroplasty by placing buccal mucosa ventrally, dorsally or dorsolaterally.

Patients and methods: This was an observational analysis of 38 patients with panurethral stricture treated by placing two BMGs, one as a ventral onlay in the proximal bulbar urethra and the other as a dorsal onlay in the distal bulbar and penile urethra. Success was defined as asymptomatic state with or without need for a postoperative single intervention such as dilatation or internal urethrotomy.

Results: The 38 patients had a mean age of 44 years, with lichen sclerosus as the predominant cause of stricture. The ultimate success rate was 84.2% at the end of 3 months and 89.5% at the end of 1 year. Recurrent strictures appeared only in the failed cases during the follow-up period of 11 months. None of the patients needed redo urethroplasty during the follow-up period.

Conclusions: A proximal ventral and distal dorsal onlay technique of BMG urethroplasty is an available alternative for repairing panurethral stricture. The technique described is simple and easily reproducible with encouraging results compared to other similar techniques.

© 2017 Production and hosting by Elsevier B.V. on behalf of Arab Association of Urology. This is an open access article under the CC BY-NC-ND license (<http://creativecommons.org/licenses/by-nc-nd/4.0/>).

* Corresponding author.

E-mail address: dryogeshboddepalli@gmail.com (Y. Boddepalli).

Peer review under responsibility of Arab Association of Urology.

Introduction

Buccal mucosal graft (BMG) urethroplasty has recently gained in popularity for urethral reconstruction. In many studies, authors have reported repair of panure-



Production and hosting by Elsevier

<https://doi.org/10.1016/j.aju.2017.11.007>

2090-598X © 2017 Production and hosting by Elsevier B.V. on behalf of Arab Association of Urology.

This is an open access article under the CC BY-NC-ND license (<http://creativecommons.org/licenses/by-nc-nd/4.0/>).

thral stricture by single-stage BMG urethroplasty by placing buccal mucosa ventrally, dorsally or dorsolaterally [1]. In our technique, we place buccal mucosa ventrally in the proximal bulbar urethra and dorsally in the distal bulbar and penile urethra. The present study was conducted with the aim of reporting the surgical details and results of our technique of BMG urethroplasty for panurethral stricture.

Patients and methods

This was an observational analysis of 38 patients with panurethral stricture treated between August 2013 and August 2015. Institutional Ethics Committee approval was obtained before commencing this study. All patients were treated with our technique of BMG urethroplasty during the study period. Other techniques of anterior urethroplasty were not done during this period. All the data were collected according to the following inclusion and exclusion criteria.

Inclusion criteria:

- All patients with panurethral stricture aged 20–65 years.
- Panurethral stricture with history of direct visual internal urethrotomy (DVIU) or dilatation.

Exclusion criteria:

- All cases with history of failed urethroplasty.
- Panurethral strictures with complete or near complete obliteration of the lumen.

Preoperative preparation

Each patient was preoperatively evaluated with a history, clinical examination, urine culture and sensitivity, uroflowmetry, ultrasonography of the abdomen, and a retrograde urethrogram. All patients were treated with appropriate antibiotics based on the urine culture and sensitivity perioperatively.

Our technique of urethroplasty: proximal ventral and distal dorsal onlay BMG urethroplasty

The patient was either nasally or orally intubated and placed in lithotomy. Two teams worked simultaneously with separate sets of instruments to avoid cross contamination, one harvesting oral mucosa and the other preparing the urethra for repair. Oral mucosa was harvested from each cheek as described by Kulkarni et al. [2]. The bulbar urethra was exposed via a midline perineal incision. The penile urethra was exposed via a circumcoronal incision with penile degloving, followed by bringing down the penis to the perineal wound. The lumen of the stricture is usually intubated with either a 6-F feeding tube or with a 0.089 cm (0.035") guidewire,

and the stricture is incised until normal urethra is identified. Ventral urethrotomy was performed over the proximal bulbar urethra below the distal edge of the bulbospongiosum and was extended 5 mm into the normal urethra proximally (Fig. 1). Both distal bulbar and penile urethrae were dissected circumferentially from the cavernosa by the classic Barbagli technique up to its attachment with the glans [3]. Subsequently, the distal bulbar and penile urethrae were incised dorsally through the stricture with the proximal limit corresponding to the visible ventral urethral incision (Fig. 1). We placed one graft over the incised part of the proximal bulbar urethra and fixed it to the edges of urethra with 4-0 polyglactin 910 (Vicryl®; Ethicon Inc., Somerville, NJ, USA) (Fig. 2). The overlying spongiosa was closed over the graft. The second graft was placed on the dorsal aspect of the distal bulbar and penile urethrae. It was fixed to the edges of the incised part of that urethra and tunica albuginea of the corpus cavernosa by applying several 4-0 polyglactin 910 sutures (Fig. 3). Care should be taken to keep the mucosal side of both grafts towards the lumen of the urethra. The proximal end of the dorsally placed BMG overlapped with the distal end of the ventrally placed BMG by about 0.5–1 cm (Fig. 3). In the case of severe meatal stenosis, ventral meatotomy was performed until the upper border of the graft sutured dorsally was visible (Fig. 4). The penis was repositioned in its normal anatomy and a 14-F silicone Foley passed per urethra. In all cases we aimed to achieve a minimum 16-F lumen in every case at the end of surgery. Penile skin was placed back into the circumcisional position and the edges created by the ventral meatotomy were sutured to the skin. The perineal wound was closed in layers after placing a suction drain. The perineal pressure dressing was chan-

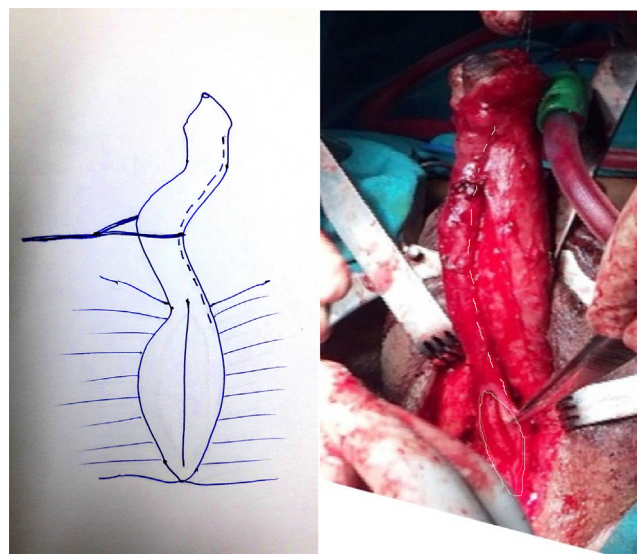


Fig. 1 Proximal ventral urethrotomy and distal dorsal urethrotomy.

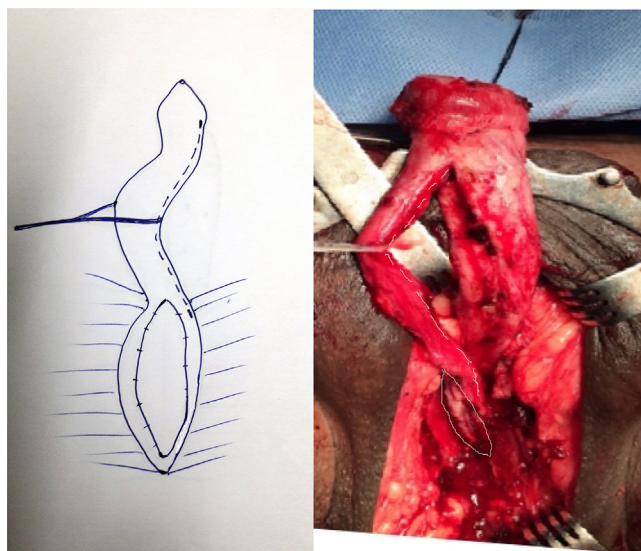


Fig. 2 Proximal ventral onlay.

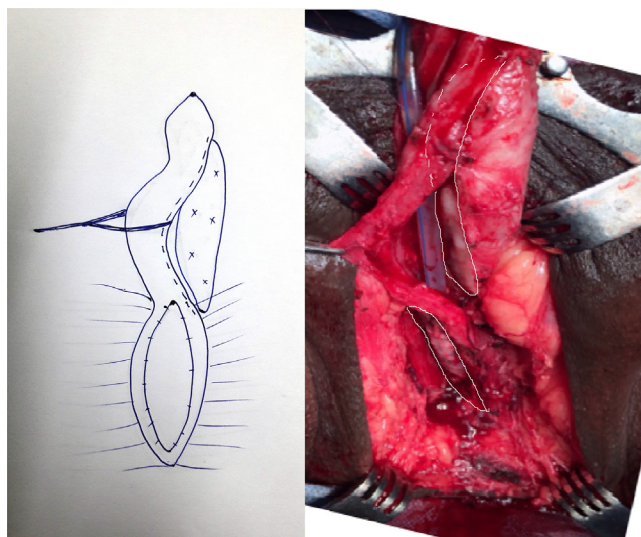


Fig. 3 Proximal ventral onlay and distal dorsal onlay with overlapping.

ged 48 h after surgery and the drain was removed after 2–3 days. The patient was discharged 5–7 days after surgery. The urethral catheter and the suprapubic cystostomy tube were not removed until 20 days after surgery. No per catheter urethrogram was performed.

Cystourethroscopy was done at the end of 3 months and annually thereafter or whenever the patient had symptoms of poor stream. During each follow-up visit, a careful history, examination, urine analysis, post-void residual urine volume estimation by ultrasonography, and cystourethroscopy were performed.

Success was defined as an asymptomatic state with normal cystourethroscopy with or without the need for a postoperative single intervention such as dilatation or internal urethrotomy [4], whilst failure was defined

as symptoms of poor stream requiring more than one intervention such as DVIU, dilatation or redo urethroplasty during follow-up.

Results

The mean (range) age of the patients was 44 (20–65) years. The cause of stricture was lichen sclerosus (LS) in 31 (82%), idiopathic in four (11%), instrumentation in two (5%), and catheter induced in one (2%). In all, 26 of the 38 patients presented with LUTS, eight presented to the emergency department with acute urinary retention and percutaneous suprapubic cystostomy (SPC) was done at that time, and four patients presented with urethrocutaneous fistula, SPC was done in all the four who proceeded with surgery after complete healing of the fistula. Two patients had a history of previous DVIU, three had urethral dilatation, and one had a history of meatotomy (Table 1). In the early postoperative period, three patients had wound infections and one patient had penile skin necrosis. Cystourethroscopy was performed postoperatively in all patients who had LUTS at presentation, and routinely in all patients irrespective of their symptoms at 3 months and 1 year postoperatively. During the first 3 months after surgery, re-stenosis occurred in five patients and meatal stenosis in one. The success rate was 84.2% (32/38) at the 3-month follow-up. The success rate in those aged < 50 and > 50 years was 85% (23/27) and 81% (9/11), respectively; which was not statistically significantly different ($P = 1$). The success rate appeared to be more in non-LS group (100%) and in patients with prior intervention (100%), but this was not statistically significant (Table 2).

Meatal stenosis was treated by ventral lay open of the urethra until healthy buccal mucosa was seen dorsally. Re-stenosis was ring-shaped at the site of the overlapping BMG in two patients, which was treated by DVIU 3 months after the primary reconstructive surgery. One of these patients had re-stenosis again during the follow-up period and currently carries out self-dilatation. In three patients with proximal stricture dilatation was performed, but they all developed recurrent stricture during follow-up. Amongst them, two patients proceeded with perineal urethrostomy in view of advanced age, and in the other patient repeat dilatation was performed to allow him to carry out self-dilatation (Fig. 5 for algorithm). Amongst the six failed cases at 3 months, two were successfully treated, and cystourethroscopy for them at the 1-year follow-up was normal. During the mean follow-up period of 11 months, no patient was lost to follow-up. In the success group at the 1-year follow-up there were no recurrent strictures. The ultimate success rate was 89.5% (34/38) at the end of 1-year after single interventions such as DVIU and ventral lay open.

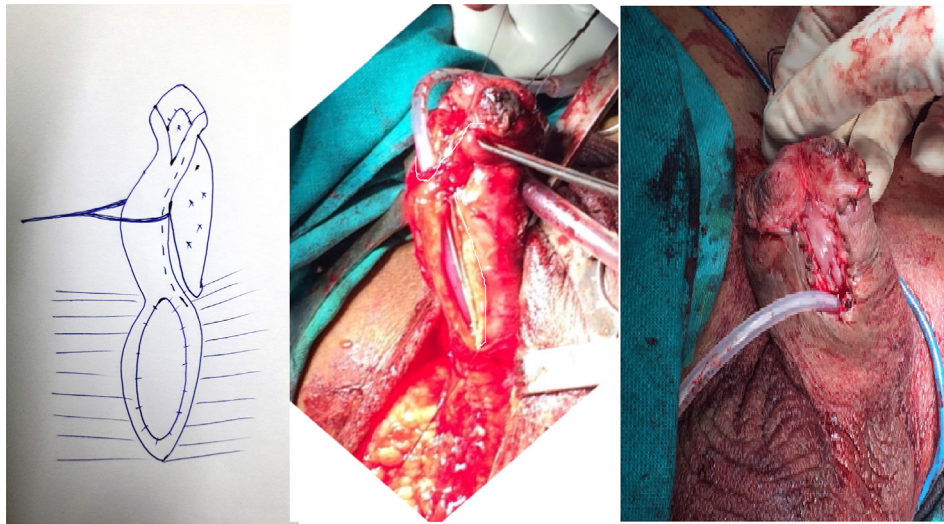


Fig. 4 Distal ventral lay open.

Table 1 Patients' characteristics.

| Characteristic | N (%) |
|---------------------------|----------|
| <i>Age, years</i> | |
| 20–35 | 8(21.1) |
| 36–50 | 19(50) |
| 51–65 | 11(28.9) |
| <i>Cause of stricture</i> | |
| LS | 31(81.6) |
| <i>Instrumentation</i> | |
| Catheter induced | 2(5.3) |
| Idiopathic | 1(2.6) |
| <i>Presentation</i> | |
| LUTS | 4(10.5) |
| Acute urinary retention | 26(68.4) |
| Urethrocutaneous fistula | 8(21.1) |
| <i>Prior intervention</i> | |
| Urethral dilatation | 4(10.5) |
| DVIU | 3(7.9) |
| Ventral meatotomy | 2(5.3) |
| No prior intervention | 1(2.6) |
| | 32(84.2) |

Discussion

Reconstruction of panurethral strictures can be achieved effectively in a single operation using a transperineal approach with a combination of proximal ventral and distal dorsal onlay urethroplasty. In our present technique, degloving the penis and bringing it to the perineum with ventral urethrotomy in the proximal bulbar urethra gives better exposure of the entire stricture and makes the fixation of BMG easy. In this technique, the BMG was placed as a ventral onlay in the proximal bulbar urethra, where the spongiosa is usually adequate. This helps the graft to receive a better blood supply from the spongiosa [5]. On the other hand, in both the distal bulbar and penile urethra, where the

Table 2 Success rate.

| Variable | Success rate, n/N (%) | Failure rate, n/N (%) | P |
|---------------------------|-----------------------|-----------------------|------|
| <i>Age, years</i> | | | |
| < 50 | 23/27 (85.2) | 4/27 (14.8) | 0.79 |
| > 50 | 9/11 (81.8) | 2/11 (18.2) | |
| <i>Cause of stricture</i> | | | |
| LS | 25/31 (80.6) | 6/31 (19.4) | 0.56 |
| Non-LS | 7/7 | 0/7 | |
| <i>Prior intervention</i> | | | |
| Yes | 6/6 | 0/6 | 0.56 |
| No | 26/32 (81.3) | 6/32 (18.8) | |

spongiosa is frequently inadequate, the graft placed as a dorsal onlay receives better mechanical support and blood supply from the cavernosa [6]. In addition, extending the urethral incision 5 mm into the normal urethra and overlapping the proximal and distal ends of the BMG for 0.5–1 cm may decrease the number of recurrences. In our present technique, we perform ventral meatotomy in all cases of meatal stenosis irrespective of the available length of the BMG. Although creating a hypospadiac meatus by doing a ventral meatotomy is troublesome for the patient, it may decrease the meatal-related complications in the long-term. The dorsal access to the proximal bulbar urethra might damage erectile function and the bulbar arteries [1,7]. Therefore, we are limiting this approach only for distal bulbar urethra, whilst for the repair of proximal bulbar stricture the ventral approach is used. The ventral approach in the proximal bulbar urethra provides direct access to the urethral lumen and a clear visualisation of the entire stricture during urethral opening [8]. Therefore, the ventral onlay grafting is more effective in the proximal bulbar urethra, where the spongiosum tissue is thick. A salvageable urethral plate of 3-mm

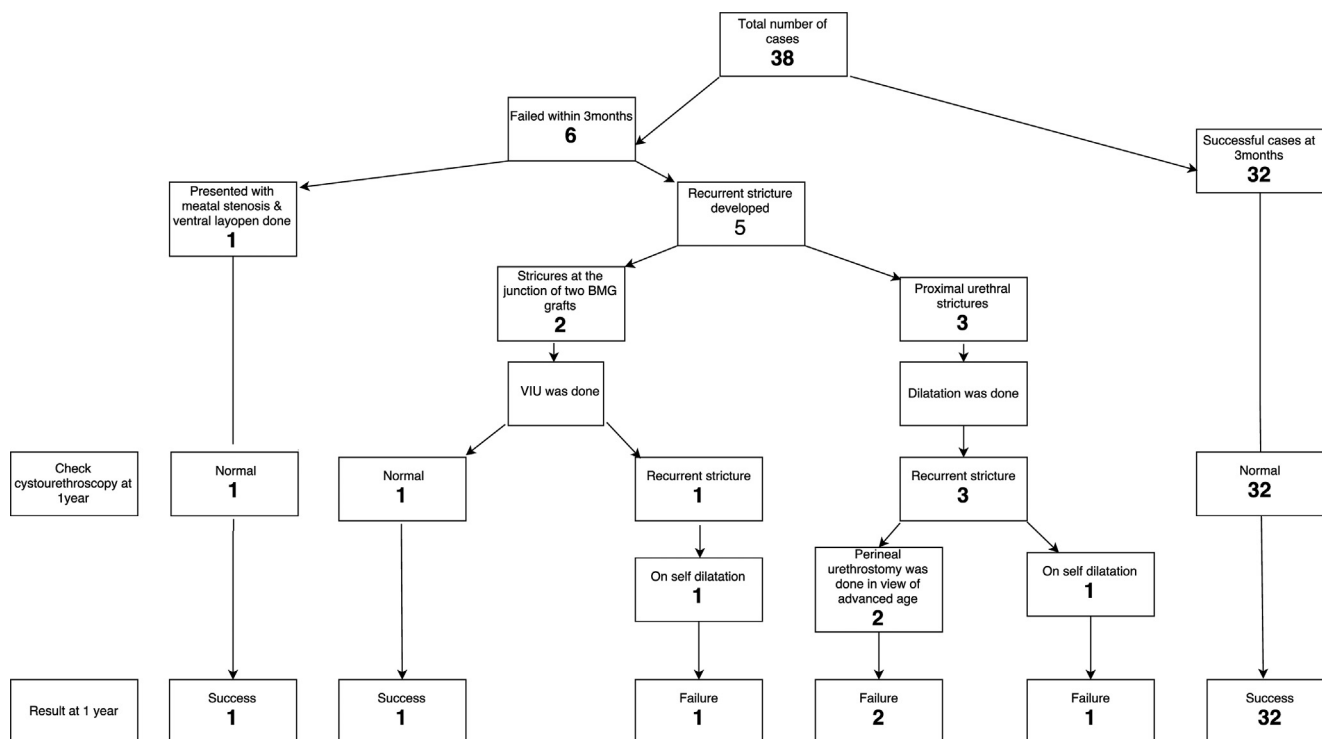


Fig. 5 Algorithm demonstrating outcomes.

width is mandatory to proceed with this technique. Otherwise, all other patients should undergo a two-stage repair or perineal urethrostomy. A >14-F lumen is adequate to void with a normal flow rate [9]. So considering postoperative contraction of the BMG, our goal was to achieve a minimum >16-F lumen in every case at the end of surgery. After urethroplasty recurrent strictures are mainly narrow fibrous rings at the anastomotic sites and usually due to existing pathology of the urethra, local ischaemia or defects in graft uptake [10]. The success rate for single DVIU for these strictures has been reported to be 35% with satisfactory outcomes [11]. Thus, in our present study, postoperative single intervention was considered to treat these ring strictures and was included in the definition of 'success'. The success rate improved to 89.5% (34/38) at the end of 1 year when including a single intervention such as DVIU and ventral lay open. This improvement in success rate can be explained by successful treatment of ring strictures during follow-up. In the present study, all the failures (six of 38) were seen in patients with LS. But based on the statistical analysis age of the patient, cause of stricture, or prior interventions did not predict the success or failure rate of repair ($P > 0.5$). Recurrent strictures were seen only in the initially failed cases but not in the success group. This was probably due to characteristics of the urethral plate and severity of stricture disease encountered intraoperatively. There is always a possibility that failures could appear in the success group with longer follow-up due to the progressive nat-

ure of stricture disease. Kulkarni et al. [12] reported a single-stage dorsal-onlay graft technique with one-sided urethral dissection with a success rate of 86.5% for primary urethroplasty, with most recurrent strictures at the proximal end of the graft. In the Kulkarni et al. [12] technique penile invagination was done and urethroplasty was accomplished without a hypospadiac meatus. In our present technique, penile degloving appears to be unnecessary but it gives additional exposure of urethra and makes the fixation of buccal mucosa easy. In our present technique, we perform two urethrotomies one in the ventrum of proximal bulbar urethra and the other in the dorsum of the distal bulbar and penile urethrae in place of a single dorsal incision of the entire urethra to gain excellent visualisation of entire extent of the stricture including the proximal extent. This allows fixation of the BMG proximally to the normal urethra beyond the stricture to minimise proximal recurrent strictures and overlapping of both the BMGs minimises the likelihood of junctional strictures. Although the immediate outcome of our present technique is favourable there is the possibility of long-term attrition. To establish the favourable outcome of the present technique, these cases require longer follow-up. Comparing these results with other similar studies was difficult, as there were differences in patient demographics, characteristics of the urethral plate, operative technique, follow-up methods, and variation in the definition of success (Table 3).

Table 3 Comparison of outcomes and follow-up of panurethral urethroplasty.

| Reference | Number treated | Follow-up, months | Definition of success | Success rate, % |
|----------------------|----------------|-------------------|--|-----------------|
| Kulkarni et al. [13] | 117 | 59 | If the patient required no further instrumentation, including dilatation or urethrotomy | 86.5 |
| Singh et al. [14] | 8 | 19 | Maximum flow rate of ≥ 15 mL/s, sterile urine, normal urethral imaging (retrograde urethrogram), and/or urethroscopy (with a 19-F sheath) | 88 |
| Our technique | 38 | 11 | Asymptomatic state with normal cystourethroscopy with or without need for postoperative single intervention such as dilatation or DVIU | 89.5 |

Conclusions

A proximal ventral and distal dorsal onlay technique of BMG urethroplasty is an available alternative for repairing panurethral strictures. Failure and disease progression were more common in panurethral strictures with LS. Whilst, we are routinely using this technique to repair all panurethral strictures irrespective of aetiology, the proximal ventral and distal dorsal onlay technique of BMG urethroplasty requires well-conducted multicentre studies with longer follow-up for further acceptance.

Conflict of interest

We have no conflict of interest to declare

References

- [1] Barbagli G, Palminteri E, Guazzoni G, Montorsi F, Turini D, Lazzeri M. Bulbar urethroplasty using buccal mucosa grafts placed on the ventral, dorsal or lateral surface of the urethra: are results affected by the surgical technique? *J Urol* 2005;**174**:955–7.
- [2] Kulkarni SB, Barbagli G, Sansalone S, Joshi PM. Harvesting oral mucosa for one-stage anterior urethroplasty. *Indian J Urol* 2014;**30**:117–21.
- [3] Barbagli G, Morgia G, Lazzeri M. Dorsal onlay skin graft bulbar urethroplasty: Long-term follow-up. *Eur Urol* 2008;**53**:628–33.
- [4] Blaschko SD, McAninch JW, Myers JB, Schlomer BJ, Breyer BN. Repeat urethroplasty after failed urethral reconstruction: outcome analysis of 130 patients. *J Urol* 2012;**188**:2260–4.
- [5] Venkatesan K, Blakely S, Nikolavsky D. Surgical repair of bulbar urethral strictures: advantages of ventral, dorsal, and lateral approaches and when to choose them. *Adv Urol* 2015;**2015**:397936. <https://doi.org/10.1155/2015/397936>.
- [6] Barbagli G, De Stefani S. Reconstruction of the bulbar urethra using dorsal onlay buccal mucosal grafts: New concepts and surgical tricks. *Indian J Urol* 2006;**22**:113–7.
- [7] Barbagli G, Sansalone S, Djinovic R, Romano G, Lazzeri M. Current controversies in reconstructive surgery of the anterior urethra. A clinical overview. *Int Braz J Urol* 2012;**38**:307–16.
- [8] Palminteri E, Berdondini E, Di Piero GB. The advantages of the ventral approach to bulbar urethroplasty. *Arab J Urol* 2013;**11**:350–4.
- [9] Brandes SB. Lichen sclerosus: editorial comment. In: Brandes SB, Morey AF, editors. *Advanced Male Urethral and Genital Reconstructive Surgery*. New Delhi: Springer (India) Private Ltd; 2016. p. 45–7, second ed..
- [10] Barbagli G, Guazzoni G, Palminteri E, Lazzeri M. Anastomotic fibrous ring as cause of stricture recurrence after bulbar onlay graft urethroplasty. *J Urol* 2006;**176**:614–9.
- [11] Brown ET, Mock S, Dmochowski R, Reynolds WS, Milam D, Kaufman MR. Direct visual internal urethrotomy for isolated, post-urethroplasty strictures: a retrospective analysis. *Ther Adv Urol* 2017;**9**:39–44.
- [12] Kulkarni S, Barbagli G, Sansalone S, Lazzeri M. One-sided anterior urethroplasty: A new dorsal onlay graft technique. *BJU Int* 2009;**104**:1150–5.
- [13] Kulkarni SB, Joshi PM, Venkatesan K. Management of panurethral stricture disease in India. *J Urol* 2012;**188**:824–30.
- [14] Singh BP, Pathak HR, Andankar MG. Dorsolateral onlay urethroplasty for anterior urethral strictures by a unilateral urethral mobilization approach. *Indian J Urol* 2009;**25**:211–4.