

Hypomania Induced by Subthalamic Nucleus Stimulation in a Parkinson's Disease Patient: Does It Suggest a Dysfunction of the Limbic Circuit?

Ji Seon Kim^a

Hee Jin Kim^b

Ji-Young Lee^c

Jong Min Kim^d

Ji Young Yun^e

Beom S. Jeon^e

^aDepartment of Neurology,
College of Medicine,
Chungbuk National University,
Chungbuk National University Hospital,
Daejeon, Korea

^bDepartment of Neurology,
College of Medicine,
Konkuk University,
Seoul, Korea

^cDepartment of Neurology,
Seoul National University
Boramae Hospital,
Seoul, Korea

^dDepartment of Neurology,
Seoul National University
Bundang Hospital,
Seongnam, Korea

^eDepartment of Neurology,
Seoul National University Hospital,
Seoul, Korea

Received September 15, 2011

Revised February 19, 2012

Accepted February 19, 2012

Corresponding author

Beom S. Jeon, MD, PhD
Department of Neurology and
Movement Disorder Center,
Seoul National University Hospital,
101 Daehak-ro, Jongno-gu,
Seoul 110-744, Korea
Tel +82-2-2072-2876
Fax +82-2-3672-7553
E-mail brain@snu.ac.kr

· The authors have no financial conflicts of interest.

The aim of this report was to describe a case of hypomania after deep brain stimulation of the subthalamic nucleus (STN DBS) in a Parkinson's disease (PD) patient. 59-year-old man with a 15-year history of PD underwent bilateral implantation of electrodes to the STN. Immediately after surgery, his motor function was markedly improved and his mood was elevated to hypomania. Fusion images of the preoperative MRI and postoperative CT scan showed that the electrodes were located in the medial portion of the STN. In this case, behavioral mood change was related to the deep brain stimulation. Moreover, the anatomical location and the functional alteration of the STN after the DBS surgery might be related to the regulatory system of the associative and limbic cortico-subcortical circuits.

Journal of Movement Disorders 2012;5:14-17

Key Words: Deep brain stimulation, Subthalamic stimulation, Non motor symptom, Hypomania, Mood.

High frequency deep brain stimulation (DBS) of the subthalamic nucleus (STN) is an effective treatment for advanced Parkinson's disease (PD). Since the late 1990s, STN DBS has become a widely performed surgical treatment resulting in improved motor symptoms.^{1,2} Accumulated experiences have suggested that STN DBS plays an important role in motor functions; researchers have also documented its adverse effects on cognition and emotion.²⁻⁶ Particularly for mood, wide spectrum disorders from major depression to mania can occur; in addition, apathy, psychosis, and anxiety have been described after surgery. Postoperative delirium is the most common psychiatric adverse event followed by depression (2-4%) and mania/hypomania (0.9-1.7%).⁴ We now describe a patient who developed hypomania after bilateral STN DBS. This report observed an anatomical relationship between the STN and mood through the computerized tomography-magnetic resonance imaging (CT-MRI) fusion images and by reprogramming of the stimulation contacts.

Case

A 59-year-old man with 15-year history of PD with severe motor fluctuations underwent bilateral implantation of electrodes to the STN region (quadripolar electrodes Medtronic 3389, Medtronic, Minneapolis, MN, USA). Preoperatively, the Hoehn and Yahr stage was 2.5 and the Unified Parkinson Disease Rating Scale (UPDRS) part III motor scores on/off medication were 34/42. The patient took 1500 mg of L-dopa, 1400 mg of entacapone, 150 mg of amantadine, and 5 mg of selegiline daily.

He received a preoperative brain MRI according to the protocol.⁷ The STN was located by a combination of the MRI, microelectrode recording, and stimulation techniques.¹ A brain CT was done immediately after the operation. The preoperative MRI T2-weighted images and the postoperative CT images were fused with the mutual information technique.^{8,9} The 3-dimensional location of the leads and each contact were identified on the fused images; these

were in the ventromedial part of the STN (Figure 1).

Stimulation titration was initiated a day after the leads were implanted. After the testing of each contact, we selected the best one (the right side was contact number 2, and the left was 1), which showed good motor response without any adverse effects. Stimulation parameters were as follows: right DBS setting with an amplitude of 3.0 V, a pulse width of 60 usec, and a frequency rate of 130 Hz and the left side with 2.2 V, 60 usec, and 130 Hz, respectively.

Following implantation of the electrodes, his motor disability improved rapidly and markedly; however, a remarkable mood change took place 2 days after on-stimulator. In parallel with the motor improvement, his mood was also elevated. He became talkative and excessively hopeful. He danced up and down and sang with other patients in the neurosurgical ward. He had increased motor activity and sexual interest and slightly increased irritability. His sleep pattern and quantity were normal and flight of ideas or disruptive-aggressive behavior was absent. The Young Mania Rating Scale (YMRS)

was used to evaluate manic symptoms at baseline and over-time. This scale has 11 items and scored from 0 to 4, the higher the score, the more severe the manic state.¹⁰ He had an YMRS score of 19.

Preoperatively, the patient was a very quiet and taciturn person without any history of psychiatric disorders. In the preoperative neuropsychological test, the score of Mini-Mental State Examination was 23. The Beck Depression Inventory was 23, which represented moderate to severe depression. He noted that he felt sad and had entirely lost his sexual drive. His abrupt emotional change postoperatively was attenuated slowly without any psychiatric medication or changing stimulating parameters.

Two years after surgery, we reprogrammed the stimulator based on the fused images of the MRI and CT. Reprogramming was done in the early morning off-state after 12 hours of overnight withdrawal from anti-parkinsonian medication (5 mg of selegiline and 150 mg of amantadine). We tried to stimulate the contacts; these were located within the STN (1 and

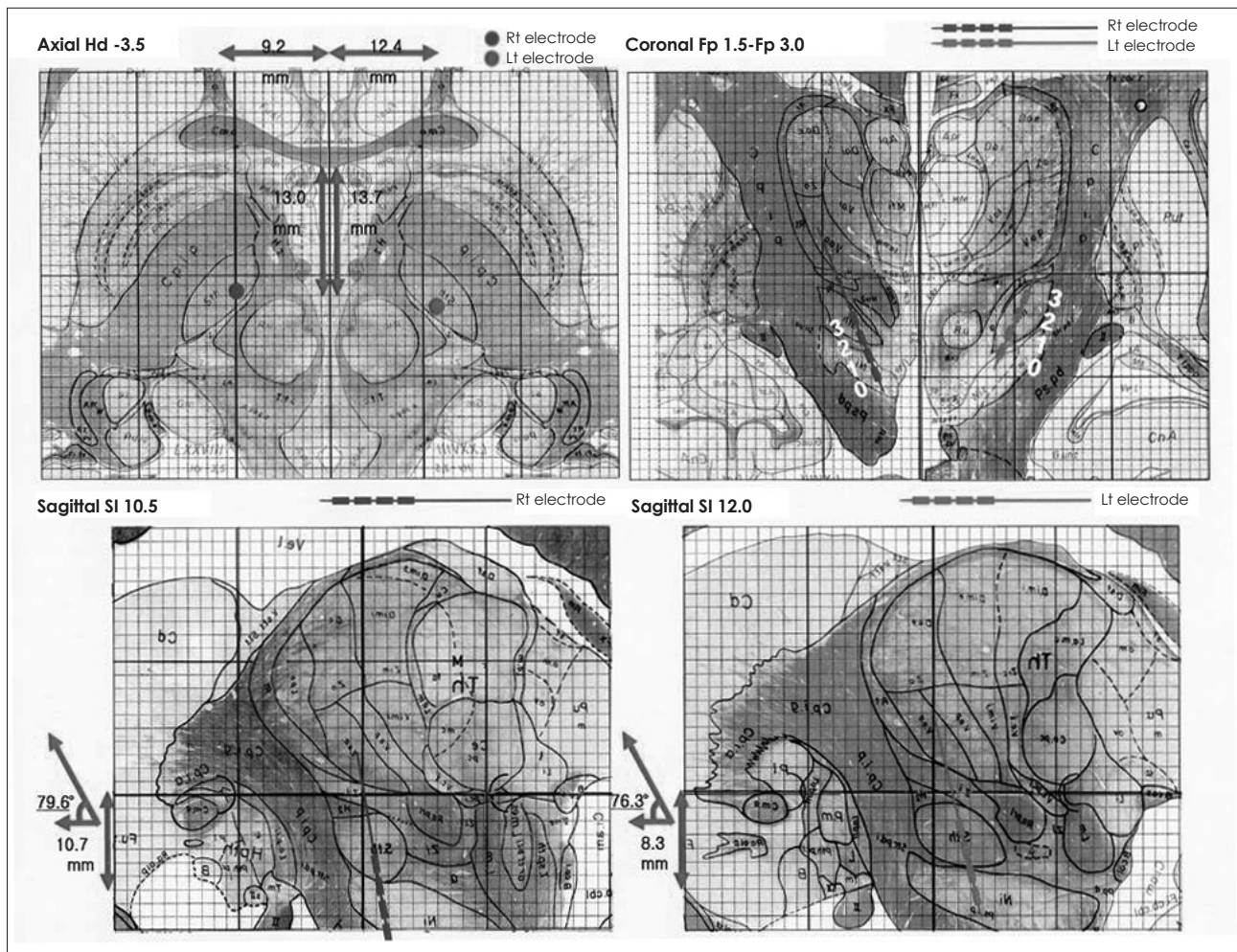


Figure 1. Localization of electrode placement. The 3-dimensional location of the leads and each contact were identified on the fused images. Blue spot represents right side electrode and red spot does left. These were in the ventromedial part of the subthalamic nucleus. The stimulating contact numbers were 2 on the right side and 1 on the left.

2 on the left side and 1, 2, and 3 on the right side). Each stimulation started at 0.5 V and increased by 0.1-0.3 V to a maximal effect level without adverse effects with the pulse width and frequency maintained at 60 us and 130 Hz, respectively. We compared the scores from the UPDRS part III and the mood parameter immediately before and following a formal reprogramming of the stimulation. No mood change occurred when either the devices remained “off” or the contact of the stimulation was switched to the other ones. The patient was optimistic as ever and his wife reported that he was sometimes flirting with her and easily laughing like a boy; however, inappropriate moods or behaviors were not observed. His YMRS score decreased to 4 at last visit.

Discussion

In this case, the acute hypomania was induced by the STN DBS and the electrodes located in the ventromedial part of the STN. With a follow-up period over 24 months, the hypomania state gradually decreased; however, programming and reprogramming of the stimulation parameters did not affect the patient’s emotions 24 months postoperatively.

The STN is generally considered part of the motor system and STN DBS enables many PD patients to experience dramatic improvements in their motor disability. However, mood problems after the STN DBS surgery are an issue of growing concern since it is related to quality of life.

The exact mechanism of action for STN DBS on mood has not been clearly elucidated. Several reasons could be suggested. Most of the patients showed a ‘transient’ mood change that is presumed a psychological reactive process following life-altering surgery. It is also possible that localized edema or a microlesion effect in the STN could contribute to the manic symptoms. The levodopa withdrawal effect is another variable for mood changes. Besides these reasons, it has been suggested that ventral stimulation of the STN generally relates mood changes;⁶ moreover, this supports the theory that the ventromedial part of the STN is linked with limbic information.¹¹

Previous studies suggested that the location of the electrode contacts might be a cause of hypomania or manic complications. Several patients with manic disorders after DBS-STN, in whom the electrodes were probably located in the substantia nigra.^{12,13} This manic state quickly disappeared when using the immediately dorsally located contacts.¹² The hypomanic state was caused only by stimulation through one contact localized in the anteromedial STN.¹⁴ On the basis of experimental studies, the medial part of the STN and the adjacent lateral hypothalamus are intimately connected with the limbic parts of the basal ganglia in a way similar and parallel to the connections of the lateral STN with the motor-related parts of the basal ganglia.^{11,15}

Reversible symptoms were related to anatomical insult; how-

ever, long lasting mood disorder was related to modifications in the subcortical-cortical limbic circuit. In this case, we reprogrammed the stimulator 2 years after DBS surgery. We tried to stimulate different contacts with variable voltages that did not lead to an emotional change. It might support the hypothesis that STN DBS has implications not only structurally but also functionally by alteration of the subcortical-cortical circuit.

In conclusion, the behavioral change in our case was induced by the STN DBS. Postoperative motor and non-motor symptoms represent the functional roles of STN and STN DBS. Further careful evaluation is required to elucidate the anatomical relationship through which the DBS may affect mood and behavior.

REFERENCES

1. Limousin P, Krack P, Pollak P, Benazzouz A, Ardouin C, Hoffmann D, et al. Electrical stimulation of the subthalamic nucleus in advanced Parkinson’s disease. *N Engl J Med* 1998;339:1105-1111.
2. Romito LM, Scerrati M, Contarino MF, Bentivoglio AR, Tonali P, Albanese A. Long-term follow up of subthalamic nucleus stimulation in Parkinson’s disease. *Neurology* 2002;58:1546-1550.
3. Romito LM, Raja M, Daniele A, Contarino MF, Bentivoglio AR, Barbier A, et al. Transient mania with hypersexuality after surgery for high frequency stimulation of the subthalamic nucleus in Parkinson’s disease. *Mov Disord* 2002;17:1371-1374.
4. Appleby BS, Duggan PS, Regenberg A, Rabins PV. Psychiatric and neuropsychiatric adverse events associated with deep brain stimulation: a meta-analysis of ten years’ experience. *Mov Disord* 2007;22:1722-1728.
5. Gervais-Bernard H, Xie-Brustolin J, Mertens P, Polo G, Klinger H, Adamec D, et al. Bilateral subthalamic nucleus stimulation in advanced Parkinson’s disease: five year follow-up. *J Neurol* 2009;256:225-233.
6. Mallet L, Schüpbach M, N’Diaye K, Remy P, Bardinet E, Czernecki V, et al. Stimulation of subterritories of the subthalamic nucleus reveals its role in the integration of the emotional and motor aspects of behavior. *Proc Natl Acad Sci U S A* 2007;104:10661-10666.
7. Lee JY, Jeon BS, Paek SH, Lim YH, Kim MR, Kim C. Reprogramming guided by the fused images of MRI and CT in subthalamic nucleus stimulation in Parkinson disease. *Clin Neurol Neurosurg* 2010;112:47-53.
8. Paek SH, Han JH, Lee JY, Kim C, Jeon BS, Kim DG. Electrode position determined by fused images of preoperative and postoperative magnetic resonance imaging and surgical outcome after subthalamic nucleus deep brain stimulation. *Neurosurgery* 2008;63:925-936; discussion 936-937.
9. Wells WM 3rd, Viola P, Atsumi H, Nakajima S, Kikinis R. Multi-modal volume registration by maximization of mutual information. *Med Image Anal* 1996;1:35-51.
10. Young RC, Biggs JT, Ziegler VE, Meyer DA. A rating scale for mania: reliability, validity and sensitivity. *Br J Psychiatry* 1978;133:429-435.
11. Groenewegen HJ, Berendse HW. Connections of the subthalamic nucleus with ventral striatopallidal parts of the basal ganglia in the rat. *J Comp Neurol* 1990;294:607-622.
12. Ulla M, Thobois S, Lemaire JJ, Schmitt A, Derost P, Broussolle E, et al. Manic behaviour induced by deep-brain stimulation in Parkinson’s disease: evidence of substantia nigra implication? *J Neurol Neurosurg Psychiatry* 2006;77:1363-1366.
13. Kulisevsky J, Berthier ML, Gironell A, Pascual-Sedano B, Molet J,

- Parés P. Mania following deep brain stimulation for Parkinson's disease. *Neurology* 2002;59:1421-1424.
14. Funkiewiez A, Ardouin C, Krack P, Fraix V, Van Blercom N, Xie J, et al. Acute psychotropic effects of bilateral subthalamic nucleus stimulation and levodopa in Parkinson's disease. *Mov Disord* 2003;18:524-530.
15. Tan SK, Temel Y, Blokland A, Steinbusch HW, Visser-Vandewalle V. The subthalamic nucleus: from response selection to execution. *J Chem Neuroanat* 2006;31:155-161.