

# Polyostotic fibrous dysplasia associated with intramuscular myxomas: Mazabraud syndrome

Jose Daniel Samper Wamba, Maria Jose Fernandez Bermudez, Teresa Lorenzo Dominguez, Luis Ramos Pascua<sup>1</sup>

Departments of Radiology, and <sup>1</sup>Orthopaedics and Traumatology, University Hospital of León, León, Spain

**Correspondence:** Dr. José Daniel Samper Wamba, C/Altos de Nava s/n, León - 24071, Spain. E-mail: samper.wamba@gmail.com

## Abstract

The authors report a new case of Mazabraud syndrome in a 69-year-old woman complaining of pain in her right thigh. Plain radiographs demonstrated radiological findings consistent with polyostotic fibrous dysplasia of the right femur and tibia. Magnetic resonance imaging (MRI) study showed soft tissue tumors located in the vastus intermedius muscle with typical signal features of intramuscular myxomas. Biopsy was not performed because of its benign nature. Symptomatic treatment was prescribed and all the lesions remained 1 year after the diagnosis.

**Key words:** Fibrous dysplasia; intramuscular myxomas; Mazabraud syndrome

## Introduction

Mazabraud syndrome was first described by Henschen in 1926, but it was Mazabraud's team in 1967 that established a clear association between fibrous dysplasia and muscular myxomas in the French literature.<sup>[1]</sup> Approximately 80 cases have been described till date,<sup>[2]</sup> but as the condition remains clinically silent, it could be more common than previously thought.<sup>[3]</sup> We present a new case that exemplifies the typical clinical features and radiological findings of this uncommon condition.

## Case Report

A 69-year-old woman presented with history of pain in the anterior aspect of her right thigh since 2 months and no history

of trauma. She gave a history of being diagnosed with a bone disorder when she was young, but did not follow-up for the same. Physical examination revealed a slight convexity of the external and anterior aspect of her thigh with nonspecific complaints during palpation. There were no signs of radicular irritation and joint examination was normal.

Plain radiographs [Figure 1] demonstrated a sclerotic, well-circumscribed, well-marginated lesion with ground-glass matrix, which was involving the neck, inter-trochanteric region, and proximal diaphysis of femur. Extensive similar involvement was seen in rest of the femoral diaphysis which appeared slightly curved on the lateral view. Endosteal thinning with cortical preservation was observed. Other lesions with similar radiological features were seen in the lateral plateau and diaphysis of the right tibia. These findings were consistent with polyostotic fibrous dysplasia. Degenerative changes in the medial tibial plateau were also seen.

Magnetic resonance imaging (Philips Ingenia 1.5 T, Best (Holland) of the right femur [Figure 2] showed imaging findings consistent with fibrous dysplasia which was causing bone expansion and cortical thinning.

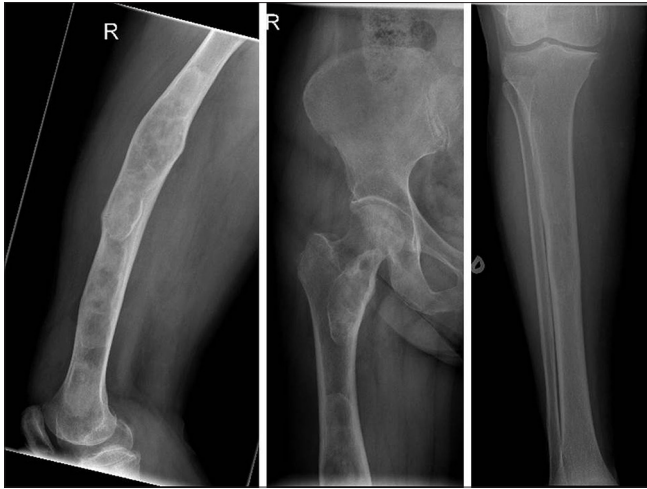### Access this article online

#### Quick Response Code:



**Website:**  
www.ijri.org

**DOI:**  
10.4103/0971-3026.161456



**Figure 1:** Conventional radiographs showed a sclerotic, well-circumscribed, well-marginated lesion, with ground-glass matrix involving the right femur diaphysis, the femur neck and the lateral plateau and diaphysis of the right tibia. Endosteal thinning with no cortical interruption was seen

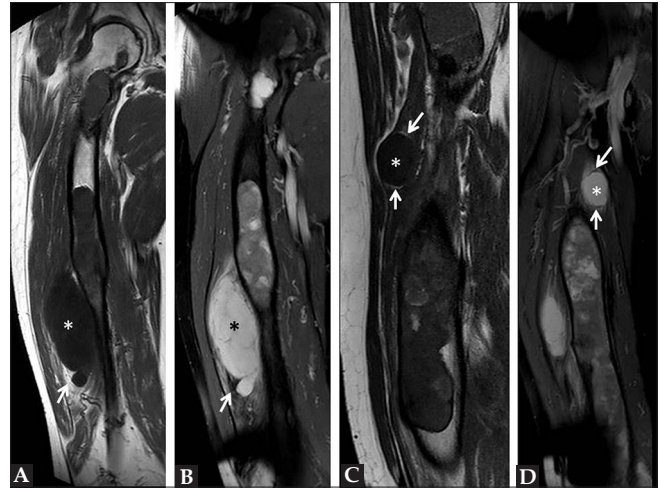
MRI also revealed two soft tissue tumors located in the vastus intermedius muscle. The larger soft tissue mass appeared hyperintense on PD (proton - density) fat-saturated sequences and hypointense on T1W sequences. A soft tissue similar to fat was observed at the inferior pole of the mass, showing high signal intensity on T1W images and a complete suppression on the fat-saturated images. The second smaller soft tissue tumor was located proximally in the medial aspect of the vastus intermedius muscle and showed similar signal intensity features. It was surrounded by a thin rim of tissue similar to fat. An intense but heterogeneous enhancement after gadolinium administration (0,2 ml per kilogram of body weight of Multihance 529 mg/ml. Amsterdam. Holland) was demonstrated in both lesions [Figure 3]. These soft tissue tumors were consistent with intramuscular myxomas.

A whole body bone Tc-99m HMDP scintigraphy [Figure 4] was performed in order to evaluate the extent of the disease. Several foci of hypercaptation along the whole right femur and the proximal half of the tibia were seen. These were particularly intense and confluent in the distal two-thirds of the femur, which produced irregular thickening and deformity and were consistent with fibrous dysplasia of the right femur and tibia.

Hypercaptation in the medial plateau of the right tibia related to osteoarthritis was seen. A subtle focus of osteochondritis in the medial aspect of the left femoral condyle was also seen.

A hypoplastic and ectopic left kidney located in pelvis was described in the patient's medical records, but no contrast uptake was seen in the left kidney.

The patient was treated symptomatically with analgesics and was counseled about the progress and outcome of her



**Figure 2(A-D):** Coronal T1W (A) and PD fat-saturated (B) images of the right femur showed a big soft tissue tumor (stars) with a cap of tissue similar to fat in its inferior pole (arrows). Sagittal T1W reconstruction (C) and coronal PD fat-saturated sequences (D) demonstrated a smaller lesion in the medial aspect of the vastus intermedius muscle (stars) which was surrounded by a thin rim of tissue similar to fat (arrows). Fibrous dysplasia involvement of the right femur was also seen

disease including malignant transformation. The patient was advised yearly follow-up with plain radiographs of the involved bones in conjunction with clinical examination. In case of any interval change in the radiographs, the patient was advised to get an MRI done.

At 1 year follow-up, there was no progression of the clinical or radiological findings.

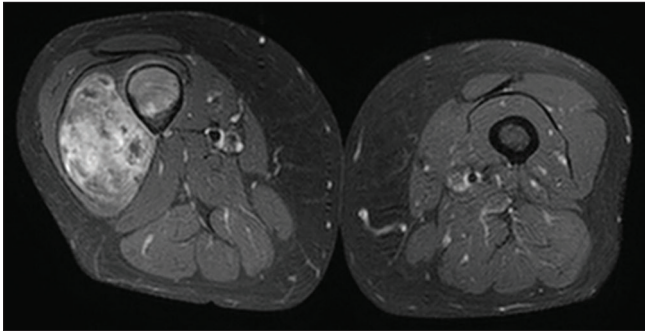
## Discussion

Mazabraud syndrome is the association of fibrous dysplasia (monostotic or polyostotic) with intramuscular myxoma (single or multiple). The etiology of the syndrome remains unknown, although the role of some somatic mutations (*GNAS1*) in its development has been suggested.<sup>[4]</sup>

Our case illustrates the typical features of the syndrome in many aspects. It has been described that Mazabraud syndrome occurs in women in 70% of cases<sup>[5]</sup> and usually the onset of fibrous dysplasia precedes the appearance of myxomas.<sup>[6]</sup> In our case, the patient gave a history of being diagnosed with a bone disorder earlier, which was probably fibrous dysplasia, and was followed by the diagnosis of myxomas at a later date.

Our patient presented with a typical complication of fibrous dysplasia, i.e. bone deformity. Other complications like pain, pathological fractures, and a 1% risk of malignant transformation have also been reported.<sup>[7]</sup>

Polyostotic form has been described at the onset presentation of this syndrome in 81% of cases.<sup>[8]</sup> Myxomas are typically



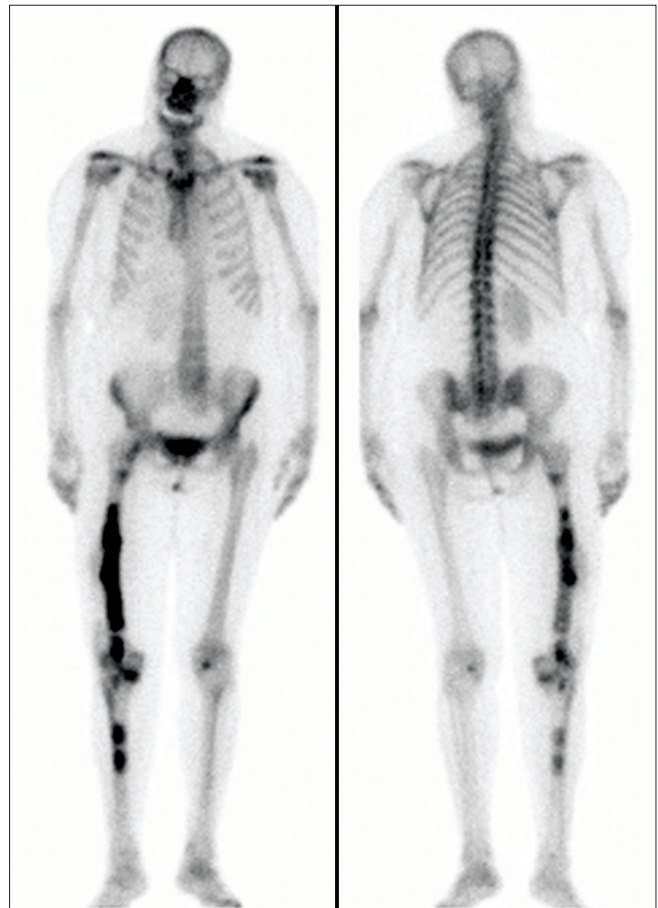
**Figure 3:** Intense but heterogeneous enhancement was demonstrated on T1 fat-saturated sequences after gadolinium administration

seen adjacent to the areas affected by fibrous dysplasia. As in our case, this syndrome appears commonly in the right lower limb,<sup>[6]</sup> but cases with atypical locations such as the ribs<sup>[9]</sup> or the left upper extremity have been reported.<sup>[10]</sup>

Mazabraud syndrome may be associated with endocrine abnormalities (precocious sexual development, hyperparathyroidism) and pigmentation disorders (“café au lait” spots) and would point toward McCune-Albright’s syndrome. In our patient, calcium and parathyroid hormone levels were normal and there was no history of precocious sexual development. No pigmentation disorders were noticed on physical examination. Gene mutations studies were not carried out. About four cases of Mazabraud syndrome associated with gynecological neoplasms have been reported.<sup>[6,11]</sup> Our patient underwent hysterectomy 25 years ago because of a uterine fibroid, indicating some correlation between gynecological neoplasms and Mazabraud syndrome, although more evidence is warranted to derive a causal relationship. Our patient also had hypoplastic and ectopic left kidney.

Both fibrous dysplasia and myxomas presented with typical findings on imaging studies. Bone involvement by fibrous dysplasia on conventional radiographs consists of ground-glass appearance of the bone and widening of the affected bones causing endosteal thinning with cortical preservation.<sup>[7]</sup> On MRI, intramuscular myxomas are seen as hypointense lesions on T1W sequences and hyperintense lesions on T2W sequences with marked enhancement after gadolinium administration. A thin rim and a cap of tissue similar to fat were demonstrated in our patient, which is an important feature that is not frequently described in the literature.<sup>[5]</sup>

We did not consider performing biopsy because the typical imaging appearance of intramuscular myxomas on MRI studies associated with polyostotic fibrous dysplasia was interpreted as diagnostic of Mazabraud syndrome. In our opinion, the diagnosis of both intramuscular myxomas and fibrous dysplasia is straightforward when typical features are present. Only clinical and radiological surveillance is suggested in the follow-up of asymptomatic patients.



**Figure 4:** Whole body bone scintigraphy demonstrated several foci of hypercaptation which were consistent with fibrous dysplasia of the right femur and tibia

In case of symptomatic lesions or suspicion of malignant transformation, surgical resection should be considered. Histological confirmation would be necessary when there is suspicion of malignant transformation. Most common malignant transformation of fibrous dysplasia is to osteosarcoma (70%), fibrosarcoma and chondrosarcoma.<sup>[12]</sup>

## Conclusion

In conclusion, the present case exemplifies the typical imaging features of Mazabraud syndrome. Although Mazabraud syndrome is an uncommon entity, it is imperative that general radiologists know its imaging characteristics in order to make an accurate diagnosis.

## References

1. Mazabraud A, Semat P, Roze R. Apropos of the association of fibromyxomas of the soft tissues with fibrous dysplasia of the bones. *Presse Med* 1967;75:2223-8.
2. Gaumétou E, Tomeno B, Anract P. Mazabraud’s syndrome. A case with multiple myxomas. *Orthop Traumatol Surg Res* 2012;98:455-60.
3. Iwasko N, Steinbach LS, Disler D, Pathria M, Hottya GA, Kattapuram S, *et al.* Imaging findings in Mazabraud’s syndrome: Seven new cases. *Skeletal Radiol* 2002;31:81-7.

4. Okamoto S, Hisaoka M, Ushijima M, Nakahara S, Toyoshima S, Hashimoto H. Activating Gs (alpha) mutation in intramuscular myxomas with and without fibrous dysplasia of bone. *Virchows Arch* 2000;437:133-7.
5. Murphey MD, McRae GA, Fanburg-Smith JC, Temple HT, Levine AM, Aboulaia AJ. Imaging of soft-tissue myxoma with emphasis on CT and MR and comparison of radiologic and pathologic findings. *Radiology* 2002;225:215-24.
6. Munksgaard PS, Salkus G, Iyer VV, Fisker RV. Mazabraud's syndrome: Case report and literature review. *Acta Radiol Short Rep* 2013;2:8.
7. Kransdorf MJ, Moser RP Jr, Gilkey FW. Fibrous dysplasia. *Radiographics* 1990;10:519-37.
8. Fujii K, Inoue M, Araki Y, Ishida O. Multiple intramuscular myxomas associated with polyostotic fibrous dysplasia. *Eur J Radiol* 1996;22:152-4.
9. Case DB, Chapman CN Jr, Freeman JK, Polga JP. Best cases from the AFIP: Atypical presentation of polyostotic fibrous dysplasia with myxoma (Mazabraud syndrome). *Radiographics* 2010;30:827-32.
10. McLaughlin A, Stalley P, Magee M, Soper J, Van der Wall H. Correlative imaging in an atypical case of Mazabraud syndrome. *AJR Am J Roentgenol* 2007;189:W353-6.
11. Faivre L, Nivelon-Chevallier A, Kottler ML, Robinet C, Khau Van Kien P, Lorcerie B, *et al.* Mazabraud syndrome in two patients: Clinical overlap with McCune-Albright syndrome. *Am J Med Genet* 2001;99:132-6.
12. Ruggieri P, Sim FH, Bond JR, Unni KK. Malignancies in fibrous dysplasia. *Cancer* 1994;73:1411-24.

**Cite this article as:** Samper Wamba JD, Fernandez Bermudez MJ, Dominguez TL, Pascua LR. Polyostotic fibrous dysplasia associated with intramuscular myxomas: Mazabraud syndrome. *Indian J Radiol Imaging* 2015;25:280-3.

**Source of Support:** Nil, **Conflict of Interest:** None declared.