

# Effects of Combined Therapy with Ezetimibe Plus Simvastatin After Drug-Eluting Stent Implantation in a Porcine Coronary Restenosis Model

The aim of this study was to examine the anti-proliferative and anti-inflammatory effects of ezetimibe/simvastatin (E/S) after drug-eluting stent (DES) implantation in a porcine coronary restenosis model. Pigs were randomized into two groups in which the coronary arteries (23 pigs) had DES. Stents were deployed with oversizing (stent/artery ratio 1.3:1) in porcine coronary arteries. Fifteen pigs were taken 10/20 mg of E/S and eight pigs were not taken E/S. Histopathologic analysis was assessed at 28 days after stenting. In neointima, most inflammatory cells were lymphohistiocytes. Lymphohistiocyte count was not different between two groups ( $337 \pm 227$  vs.  $443 \pm 366$  cells,  $P=0.292$ ), but neointima area was significantly smaller ( $1.00 \pm 0.49$  mm<sup>2</sup> vs.  $1.69 \pm 0.98$  mm<sup>2</sup>,  $P=0.021$ ) and percent area stenosis was significantly lower ( $23.3 \pm 10\%$  vs.  $39 \pm 19\%$ ,  $P=0.007$ ) in E/S group compared with control group. There were no significant differences in fibrin score ( $1.99 \pm 0.79$  vs.  $1.81 \pm 0.88$ ,  $P=0.49$ ), endothelial score ( $1.75 \pm 0.66$  vs.  $1.80 \pm 0.59$ ,  $P=0.79$ ), and the percent of endothelium covered lumen ( $43 \pm 21\%$  vs.  $45 \pm 21\%$ ,  $P=0.84$ ) between E/S group and control group. Combined therapy with ezetimibe and simvastatin inhibits neointimal hyperplasia, but does not inhibit inflammatory infiltration and arterial healing after DES implantation in a porcine coronary restenosis model.

**Key Words :** Stents; Restenosis; Inflammation; Endothelization

© 2010 The Korean Academy of Medical Sciences.

This is an Open Access article distributed under the terms of the Creative Commons Attribution Non-Commercial License (<http://creativecommons.org/licenses/by-nc/3.0>) which permits unrestricted non-commercial use, distribution, and reproduction in any medium, provided the original work is properly cited.

Jung Sun Cho<sup>1</sup>, Myung Ho Jeong<sup>2</sup>,  
Doo Sun Sim<sup>2</sup>, Young Joon Hong<sup>2</sup>,  
Kyung Seob Lim<sup>2</sup>, Jung Ha Kim<sup>2</sup>,  
Hyoung Doo Kim<sup>1</sup>, Ju Yeal Baek<sup>1</sup>,  
Hee Jeoung Yoon<sup>1</sup>, Sung-Ho Her<sup>1</sup>,  
Seung Won Jin<sup>1</sup>, Ju Han Kim<sup>2</sup>,  
Youngkeun Ahn<sup>2</sup>, Jeong Gwan Cho<sup>2</sup>,  
Jong Chun Park<sup>2</sup>, and Jung Chae Kang<sup>2</sup>

Department of Internal Medicine<sup>1</sup>, The Catholic University of Korea College of Medicine, Seoul; The Heart Center of Chonnam National University Hospital<sup>2</sup>, Chonnam National University Research Institute of Medical Sciences, Gwangju, Korea

Received : 1 July 2009  
Accepted : 21 October 2009

## Address for Correspondence

Myung Ho Jeong, M.D.  
Director of The Heart Research Center of Chonnam National University Hospital Designated by Korea Ministry of Health, Welfare and Family Affairs, 671 Jaebong-ro, Dong-gu, Gwangju 501-757, Korea  
Tel : +82.62-220-6243, Fax : +82.62-228-7174  
E-mail : myungho@chollian.net

This study was supported by a grant of the Korea Healthcare Technology R&D project (A084869), Ministry for Health, Welfare & Family Affairs, Republic of Korea.

## INTRODUCTION

Drug-eluting stents (DES) were developed in an effort to further reduce the rate of restenosis. Anti-restenotic drug (e.g. sirolimus or paclitaxel) is released over a period as short as days to as long as one year after implantation to reduce the local proliferative healing response. Animal autopsy studies suggested that DES affected re-endothelization, leading to late thrombosis (1-4).

Delayed healing is associated with local and long-term endothelial dysfunction and inflammation (5-8). Statins have been shown to have pleiotropic effects apart from serum lipid-lowering effect in human especially the effects in the vascular endothelium have been highlighted as the therapeutic potential of statins (9). Furthermore, recent clinical data also supported the early initiation of statin therapy in patients with acute coronary syndromes (10-12). Previous studies have

shown that combined therapy with ezetimibe plus simvastatin produced favorable effects on lipid levels and significant reductions in C-reactive protein relative to statin monotherapy (13, 14). We examined the neointima hyperplasia, endothelization and arterial healing of ezetimibe/simvastatin after DES implantation in a porcine coronary restenosis model.

## MATERIALS AND METHODS

### Animal study protocol

From January 2007 to March 2008, 23 female swines weighing 22-35 kg were studied in Animal Catherterization laboratory of Chonnam National University Hospital in Gwangju, Korea. The animal study was approved by the Institutional Animal Care and Use Committee of the Chonnam National

University Hospital (CNU IACUC-H-2008-3).

To decrease acute thrombosis after stenting, premedication with aspirin 100 mg and clopidogrel 75 mg per day was given for 5 days before procedure. Statin group also was given ezetimibe/simvastatin 10/20 mg before procedure and it was maintained to 28 days after stenting, but control group was not.

On the day of the stent implantation, pigs were anesthetized with ketamine (20 mg/kg intramuscularly) and xylazine (2 mg/kg intramuscularly). They received 3 liters/min of supplemental oxygen continuously through oxygen mask. After subcutaneous lidocaine 2% at the cut-down site was administered, left carotid artery was surgically exposed, and a 7-8F sheath was inserted. Continuous hemodynamic and electrocardiographic monitoring was maintained throughout the procedure. After 10,000 units of heparin was administered intravenously as a bolus prior to the procedure, the target coronary artery was engaged using standard 7-8F guiding catheters and control angiograms of the left coronary artery was performed using nonionic contrast agent in two orthogonal views.

#### Stent-induced coronary artery stenosis in porcine model

Pigs were randomized into two groups in which the coronary arteries (23 pigs, 28 coronaries in ezetimibe/simvastatin group, 15 coronaries in no ezetimibe/simvastatin group) had either a sirolimus-eluting stent (SES) or paclitaxel-eluting stent (PES) that was selected by random number generator. Stents were deployed with oversizing (stent/artery ratio 1.3:1) in porcine coronary arteries that was not different between two groups. Fifteen pigs were taken 10/20 mg of ezetimibe/simvastatin and 8 pigs were not taken ezetimibe/simvastatin. The stent was deployed by inflating the balloon to nominal pressure at injury site and the resulting stent to artery ratio was 1.3:1. Coronary angiograms were obtained immediately after stent implantation. Equipment was removed and the carotid artery was ligated. All animals received 100 mg of aspirin and 75 mg of clopidogrel orally daily until sacrifice. At 28 days after stenting, animals underwent coronary angiography in the same orthogonal views before sacrifice and 20 mL of potassium chloride intracoronary injection was done. The hearts were removed, and the coronary arteries were pressure-perfusion fixed at 70 mmHg in 10% neutral buffered formalin overnight. Arteries were step-sectioned, processed routinely for light microscopy, and stained with hematoxylin-eosin stain for histological analysis.

#### Histopathological analysis

Histopathologic evaluation of each artery was blindly performed by an experienced cardiovascular pathologist. The specimens were embedded in methylmethacrylate and sections were cut with the low speed diamond wafer mounted to the Buehler Isomet saw (Buehler Ltd., IL, USA), leaving

the stent wires intact in the cross sections to minimize potential artifacts from removal of stent wires. Fifty to 100  $\mu$ m sections were obtained at about 1 mm apart and stained with hematoxylin-eosin for histological analysis with grinding method. Also, the specimens were stained with Carstairs's fibrin stain for determining delayed arterial healing according to discriminate fibrin score. The quantitative analysis included the cross-sectional areas of the external elastic lamina (EEL), internal elastic lamina (IEL), and lumen of each stented section, and the lumen area of each non-stented sections, measured with a calibrated microscope, digital video imaging system, and microcomputer program (Visus 2000 Visual Image Analysis System). Neointimal thickness was measured as the distance from the inner surface of each stent strut to the luminal border. From the measured data, the following parameters were calculated: percentage area stenosis (%AS) [(neointimal area/IEL area)  $\times$  1,000] (15-19). Selected case were stained by CD31 immunohistochemistry stain for confirming evaluation of endothelialization.

#### Evaluation of arterial injury, fibrin scores, endothelialization scores, inflammatory cells

Arterial injury at each strut site was determined by the anatomic structures penetrated by each strut. A numeric value was assigned, as previously described by Schwartz et al.: 0=IEL intact; 1=IEL lacerated; 2=IEL and media lacerated, EEL not lacerated; 3=EEL lacerated, stent strut may extend into the adventitia. The injury score for the vessel section is calculated as dividing the sum of injury scores by the total number of struts (18, 19). Total cells and inflammatory cells which were mostly lymphohistiocytes otherwise eosinophils, giant cells were counted. The histomorphometric parameters measured on 5 or 6 sections per vessel were averaged and expressed as mean value  $\pm$  standard error. Ordinal data for fibrin were collected on each stent section using a scale of 0 to 3 as pre-

**Table 1.** Coronary artery morphometric measurements in stented vessels according to medication of ezetimibe plus simvastatin

Variables	Ezetimibe plus simvastatin (n=28)	Control (n=15)	P value
Types of DES			
Sirolimus-eluting stent	14	8	NS
Paclitaxel-eluting stent	14	7	NS
IEL area (mm <sup>2</sup> )	4.42 $\pm$ 0.8	4.30 $\pm$ 1.0	NS
Lumen area (mm <sup>2</sup> )	3.42 $\pm$ 0.9	2.61 $\pm$ 1.0	0.013
Neointima area (mm <sup>2</sup> )	1.00 $\pm$ 0.4	1.69 $\pm$ 0.9	0.021
Area stenosis (%)	23.5 $\pm$ 10.3	39.4 $\pm$ 19.1	0.007
Inflammatory cell (%)	5.20 $\pm$ 2.7	5.57 $\pm$ 4.0	NS
Injury score	1.40 $\pm$ 0.2	1.38 $\pm$ 0.2	NS
Endothelial score	1.75 $\pm$ 0.6	1.80 $\pm$ 0.59	NS
Endothelialized lumen (%)	43.70 $\pm$ 21.1	45.06 $\pm$ 21.9	NS

IEL, internal elastic lamina; NS, not significant; DES, drug eluting stent.

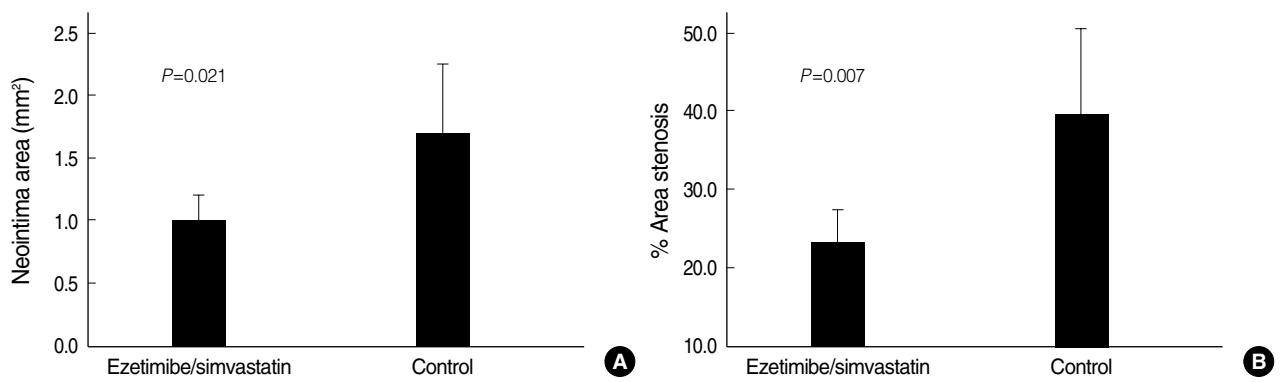


Fig. 1. Neointima area was significantly smaller (A) and percent area stenosis was significantly lower (B) in ezetimibe/simvastatin group compared with control group.

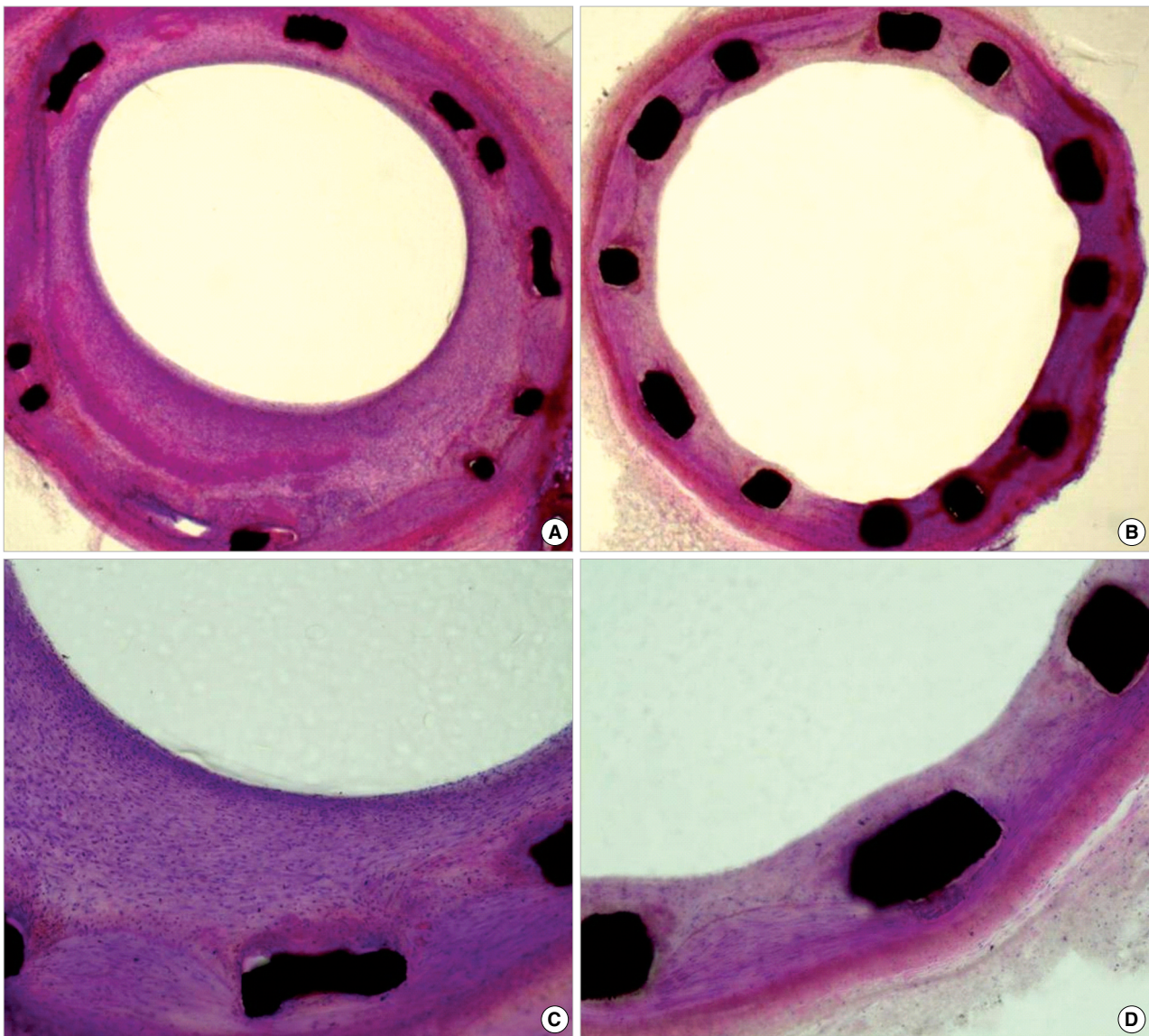


Fig. 2. Drug-eluting stented porcine coronary arteries (Methyl methacrylate staining:  $\times 25$ , A, B and  $\times 100$ , C, D). Neointima area was larger and percent area stenosis was higher in control group compared with ezetimibe/simvastatin group.

viously reported (17). The endothelialization score was defined as the extent of the circumference of the arterial lumen covered by endothelium and was scored from 1 to 3: 1 <25%; 2 25-75%; 3 >75% (19).

### Statistical analysis

Statistical analysis was performed using the commercially available software (SPSS Version 15, Chicago, IL, USA). The data are presented as mean value  $\pm$  SD. Unpaired Student's *t* test was used for the comparison of inflammatory cell counts normalized to injury score of the two stent groups. To examine the correlations between the measured histologic variables, regression analysis was applied for each set of measured variables. A value of  $P < 0.05$  was considered statistically significant.

## RESULTS

One pig of ezetimibe/simvastatin group died before 28 days, one coronary artery of one pig of no ezetimibe/simvastatin group could not be engaged guiding catheter. Therefore, 28 coronaries in ezetimibe/simvastatin group and 15 coronaries in no ezetimibe/simvastatin group was analyzed. The types of DES were not different between two groups (Table 1).

In neointima, most inflammatory cells were lymphohistiocytes. Lymphohistiocyte count was not different between two groups ( $337 \pm 227$  cells vs.  $443 \pm 366$  cells,  $P = 0.292$ ). Furthermore, the percent of inflammatory cell among the total cell in neointima was not different between two groups

( $5.2 \pm 2.77\%$  vs.  $5.57 \pm 4.0\%$ ,  $P = 0.73$ ). Neointima area was significantly smaller ( $1.00 \pm 0.49$  mm<sup>2</sup> vs.  $1.69 \pm 0.98$  mm<sup>2</sup>,  $P = 0.021$ ) and percent area stenosis was significantly lower ( $23.3 \pm 10\%$  vs.  $39 \pm 19\%$ ,  $P = 0.007$ ) in ezetimibe/simvastatin group compared with control group (Figs. 1, 2).

There was no significant differences in fibrin score ( $1.99 \pm 0.79$  vs.  $1.81 \pm 0.88$ ,  $P = 0.49$ ), endothelial score ( $1.75 \pm 0.66$  vs.  $1.80 \pm 0.59$ ,  $P = 0.79$ ), and the percent of endothelium covered lumen ( $43 \pm 21\%$  vs.  $45 \pm 21\%$ ,  $P = 0.84$ ) between ezetimibe/simvastatin group and control group (Table 1, Figs. 3, 4).

## DISCUSSION

In our study, combined therapy with ezetimibe and simvastatin may inhibit neointimal hyperplasia, and that result may be related with effects of ezetimibe in animal study (26). Furthermore, we evaluated for inflammatory reaction, reendothelialization, and arterial healing, but there are no significant differences between two groups. These results suggested ezetimibe and simvastatin prevent the neointima hyperplasia, but does not promote arterial healing for preventing late stent thrombosis.

In DES period, main concern about the DES was divided to ISR by intimal hyperplasia and late stent thrombosis by delayed arterial healing (21-23). In this aspect, statin could be expected to have therapeutic potential in the both aspects. Endothelium is a single layer of endothelial cells lining the vascular wall and plays an integral part in maintaining vascular homeostasis. However, stenting causes significant injury to the vascular wall and endothelium resulting in inflamma-

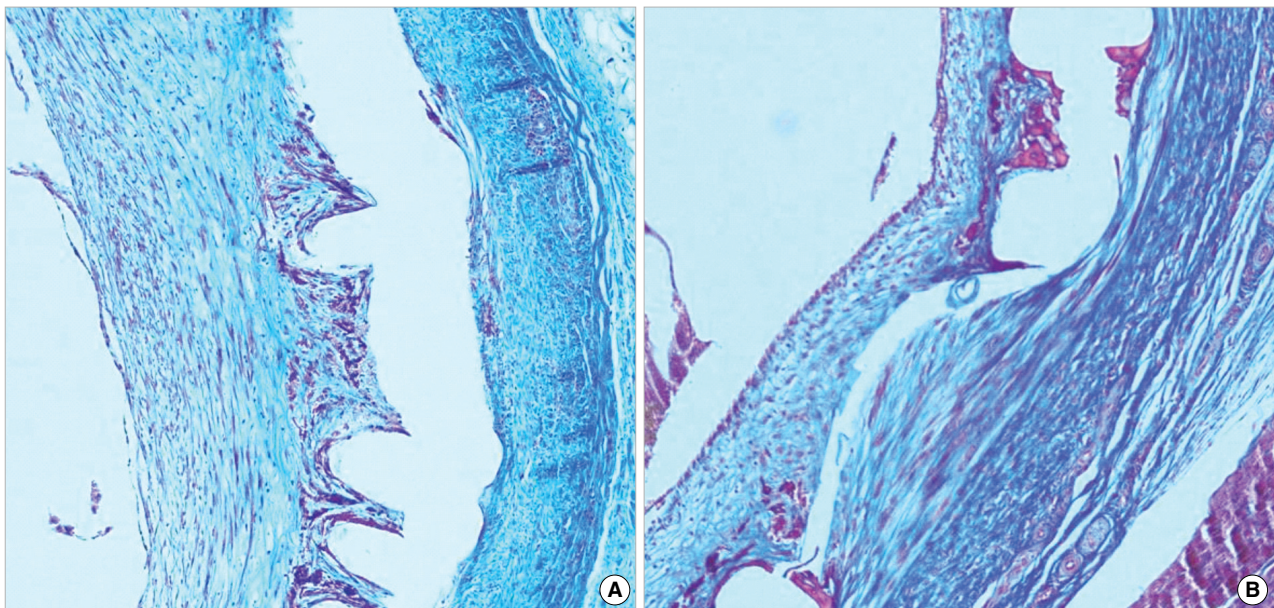


Fig. 3. Carstairs' fibrin stain ( $\times 200$ ) for determining delayed arterial healing according to discriminate fibrin score that is not different between ezetimibe/simvastatin (A) and (B) control groups.

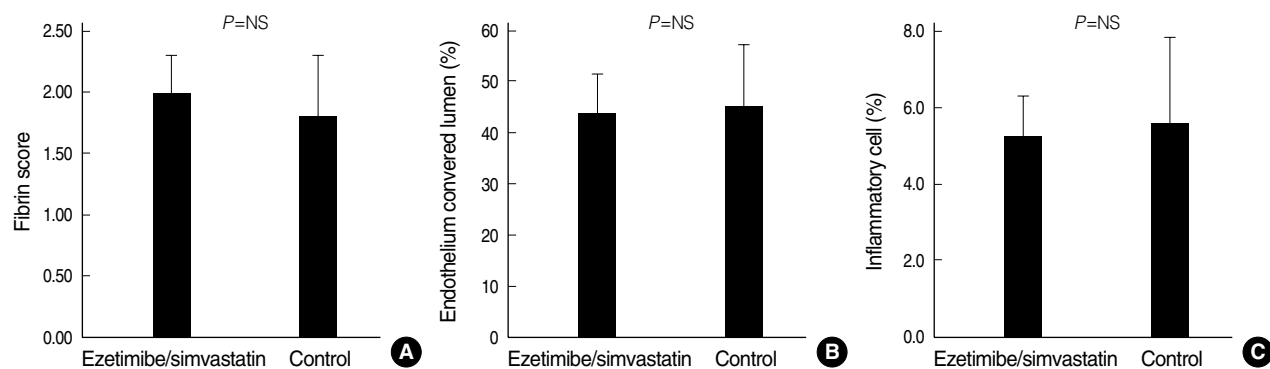


Fig. 4. There was no significant differences in fibrin score (A), endothelial score (B), and the percent of enthelium covered lumen (C) between ezetimibe/simvastatin group and control group.

tion, repair and the development of neointimal hyperplasia. Hastening the natural process of repair has potentially benefit of reducing the amount of neointimal hyperplasia and stent thrombosis.

The cholesterol-independent pleiotropic effect of statin has been proved, especially the effects in the vascular endothelium have been highlighted as the therapeutic potential of statins. The mechanisms of pleiotropic effects in the vascular endothelium of statin without changes in serum cholesterol levels was not proved clearly. However, inhibition of Rho and Rho kinase activity and stimulation the PI3 kinase/Akt pathway may lead to increased in endothelial nitric oxide synthase (eNOS) expression and activation was considered one of the mechanisms (28-30). Statin is identified as agents that augment the mobilization and recruitment of endothelial progenitor cell (EPC) to the injured area (24). EPC mobilization from bone marrow by statins may contribute to reendothelization or angiogenesis. eNOS, vascular endothelial growth factor (VEGF), and adhesion molecules mediate statin-induced EPC recruitment and activation in deendothelized vascular wall. Also, other mechanisms of pleiotropic effects in the vascular smooth muscle cell of statin were suggested; statin modulates phenotypic changes of vascular smooth muscle cell (VSMC) and subsequently their proliferation and migration.

Statins also have been shown to reduce the number of inflammatory cells in atherosclerotic lesions. Recent reports have shown the inhibitory effects of statins on adhesion molecules such as intercellular adhesion molecule-1 (ICAM-1), vascular cell adhesion molecule (VCAM-1) and E-selectin, which are involved in the adhesion, rolling, extravasation of inflammatory cells. However, the effect of statins on vascular inflammation mediated by adhesion molecules is still controversial (9). In our study, numbers of migrated inflammatory cells in neointima were not different between two groups.

Several animal studies indicated that neointimal hyperplasia and inflammation in stented vessels can be reduced by statin both in hypercholesterolemic animals and in animals with normal lipid levels (20, 28-30). However, in nor-

mcholesterolemic patients undergoing coronary stenting, simvastatin does not prevent intimal hyperplasia or in-stent restenosis, but it promotes atherosclerotic regression both at stented and at non-stented sites. The above result was not based on histopathologic analysis but intravascular ultrasound analysis that can cause different result from animal studies (23).

Ezetimibe is a novel agent that potentially inhibits the intestinal absorption of cholesterol by blocking the Niemann-Pick C1-like 1 protein for cholesterol transport across the intestinal wall (14, 25-27). Combined therapy with ezetimibe plus simvastatin produced favorable effects on blood lipid levels and significant reductions in C-reactive protein compared with statin monotherapy (13, 14).

In our porcine model, combined therapy with ezetimibe plus simvastatin inhibits neointimal hyperplasia, but does not inhibit inflammatory infiltration and arterial healing after DES implantation in a porcine coronary restenosis model.

## REFERENCES

1. Bavry AA, Kumbhani DJ, Helton TJ, Borek PP, Mood GR, Bhatt DL. *Late thrombosis of drug-eluting stent: A meta-analysis of randomized clinical trials.* *Am J Med* 2006; 119: 1056-61.
2. Farb A, Sangiorgi G, Carter AJ, Walley VM, Edwards WD, Schwartz RS, Virmani R. *Pathology of acute and chronic coronary stenting in humans.* *Circulation* 1999; 99: 44-52.
3. Finn AV, Kolodgie FD, Hamek J, Guerrero LJ, Acampado E, Tefera K, Skorija K, Weber DK, Gold HK, Virmani R. *Differential response of delayed healing and persistent inflammation at sites of overlapping sirolimus- or paclitaxel-eluting stents.* *Circulation* 2005; 112: 270-8.
4. Lim SY, Jeong MH, Hong SJ, Lim DS, Moon JY, Hong YJ, Kim JH, Ahn Y, Kang JC. *Inflammation and delayed endothelization with overlapping drug-eluting stents in a porcine model of in-stent restenosis.* *Circ J* 2008; 72: 463-8.
5. Hong YJ, Jeong MH, Lim SY, Lee SR, Kim KH, Sohn IS, Park HW, Kim JH, Kim W, Ahn Y, Cho JG, Park JC, Kang JC. *Elevated pre-*

- procedural high-sensitivity C-reactive protein levels are associated with neointimal hyperplasia and restenosis development after successful coronary artery stenting. *Circ J* 2005; 69: 1477-83.
6. Suzuki T, Kopia G, Hayashi S, Bailey LR, Llanos G, Wilensky R, Klugherz BD, Papandreou G, Narayan P, Leon MB, Yeung AC, Tio F, Tsao PS, Falotico R, Carter AJ. *Stent-based delivery of sirolimus reduces neointimal formation in a porcine coronary model. Circulation* 2001; 104: 1188-93.
  7. Heldman AW, Cheng L, Jenkins GM, Heller PF, Kim DW, Ware M Jr, Nater C, Hruban RH, Rezaei B, Abella BS, Bunge KE, Kinsella JL, Sollott SJ, Lakatta EG, Brinker JA, Hunter WL, Froehlich JP. *Paclitaxel stent coating inhibits neointimal hyperplasia at 4 weeks in a porcine model of coronary restenosis. Circulation* 2001; 103: 2289-95.
  8. Farb A, Heller PF, Shroff S, Cheng L, Kolodgie FD, Carter AJ, Scott DS, Froehlich J, Virmani R. *Pathological analysis of local delivery of paclitaxel via a polymer-coated stent. Circulation* 2001; 104: 473-9.
  9. Ii M, Losordo DW. *Statins and the endothelium. Vascul Pharmacol* 2007; 46: 1-9.
  10. Miyauchi K, Kasai T, Yokoyama T, Aihara K, Kurata T, Kajimoto K, Okazaki S, Ishiyama H, Daida H. *Effectiveness of statin-eluting stent on early inflammatory response and neointimal thickness in a porcine coronary model. Circ J* 2008; 72: 832-8.
  11. Aronow HD, Topol EJ, Roe MT, Houghtaling PL, Wolski KE, Lincoff AM, Harrington RA, Califf RM, Ohman EM, Kleiman NS, Keltai M, Wilcox RG, Vahanian A, Armstrong PW, Lauer MS. *Effect of lipid-lowering therapy on early mortality after acute coronary syndromes: an observational study. Lancet* 2001; 357: 1063-8.
  12. Cannon CP, Braunwald E, McCabe CH, Rader DJ, Rouleau JL, Belder R, Joyal SV, Hill KA, Pfeffer MA, Skene AM; Pravastatin or Atorvastatin Evaluation and Infection Therapy-Thrombolysis in Myocardial Infarction 22 Investigators. *Intensive versus moderate lipid lowering with statins after acute coronary syndromes. N Engl J Med* 2004; 350: 1495-504.
  13. Cannon CP, Giugliano RP, Blazing MA, Harrington RA, Peterson JL, Sisk CM, Strony J, Musliner TA, McCabe CH, Veltri E, Braunwald E, Califf RM; IMPROVE-IT Investigators. *Rationale and design of IMPROVE-IT (IMProved Reduction of Outcomes: Vytorin Efficacy International Trial): comparison of ezetimibe/simvastatin versus simvastatin monotherapy on cardiovascular outcomes in patients with acute coronary syndromes. Am Heart J* 2008; 156: 826-32.
  14. Pearson T, Ballantyne C, Sisk C, Shah A, Veltri E, Maccubbin D. *Comparison of effects of ezetimibe/simvastatin versus simvastatin versus atorvastatin in reducing C-reactive protein and low-density lipoprotein cholesterol levels. Am J Cardiol* 2007; 15: 1706-13.
  15. Farhan S, Hemetsberger R, Matiassek J, Strehblow C, Pavo N, Khorasand A, Petneházy O, Petrás Z, Kaider A, Glogar D, Huber K, Gyöngyösi M. *Implantation of paclitaxel-eluting stent impairs the vascular compliance of arteries in porcine coronary stenting model. Atherosclerosis* 2009; 202: 144-51.
  16. Schwartz RS, Edelman ER, Carter A, Chronos N, Rogers C, Robinson KA, Waksman R, Weinberger J, Wilensky RL, Jensen DN, Zuckerman BD, Virmani R; Consensus Committee. *Drug-eluting stents in preclinical studies: recommended evaluation from a consensus group. Circulation* 2002; 106: 1867-73.
  17. Kolodgie FD, John M, Khurana C, Farb A, Wilson PS, Acampado E, Desai N, Soon-Shiong P, Virmani R. *Sustained reduction of in-stent neointimal growth with the use of a novel systemic nanoparticle paclitaxel. Circulation* 2002; 106: 1195-8.
  18. Hong YJ, Jeong MH, Kim W, Lim SY, Lee SH, Hong SN, Lee SH, Kim KH, Yun KH, Kang DG, Lee YS, Park HW, Kim JH, Ahn Y, Cho JG, Park JT, Park CS, Park JC, Kang JC. *The effects of abciximab (ReoPro®)-coated stents on extracellular matrix synthesis and apoptosis. Korean Circ J* 2005; 35: 290-301.
  19. Schwartz RS, Huber KC, Murphy JG, Edwards WD, Camrud AR, Vlietstra RE, Holmes DR. *Restenosis and the proportional neointimal response to coronary artery injury: results in a porcine model. J Am Coll Cardiol* 1992; 19: 267-74.
  20. Indolfi C, Cioppa A, Stabile E, Di Lorenzo E, Esposito G, Pisani A, Leccia A, Cavuto L, Stingone AM, Chieffo A, Capozzolo C, Chiariello M. *Effects of hydroxymethylglutaryl coenzyme A reductase inhibitor simvastatin on smooth muscle cell proliferation in vitro and neointimal formation in vivo after vascular injury. J Am Coll Cardiol* 2000; 35: 214-21.
  21. Hong YJ, Jeong MH, Kim W, Lim SY, Lee SH, Hong SN, Kim JH, Ahn YK, Cho JG, Park JC, Cho DL, Kim H, Kang JC. *Effect of abciximab-coated stent on in-stent intimal hyperplasia in human coronary arteries. Am J Cardiol* 2004; 94: 1050-4.
  22. Kim W, Jeong MH, Kim KH, Sohn IS, Hong YJ, Park HW, Kim JH, Ahn YK, Cho JG, Park JC, Cho DL, Kang JC. *The clinical results of a platelet glycoprotein IIb/IIIa receptor blocker (abciximab: ReoPro)-coated stent in acute myocardial infarction. J Am Coll Cardiol* 2006; 47: 933-8.
  23. Petronio AS, Amoroso G, Limbruno U, Papini B, De Carlo M, Micheli A, Ciabatti N, Mariani M. *Simvastatin does not inhibit intimal hyperplasia and restenosis but promotes plaque regression in normocholesterolemic patients undergoing coronary stenting: a randomized study with intravascular ultrasound. Am Heart J* 2005; 149: 520-6.
  24. Ong AT, Aoki J, Kutryk MJ, Serruys PW. *How to accelerate the endothelialization of stents. Arch Mal Coeur Vaiss* 2005; 98: 123-6.
  25. van Heek M, Farley C, Compton DS, Hoos LM, Smith-Torhan A, Davis HR. *Ezetimibe potently inhibits cholesterol absorption but does not affect acute hepatic or intestinal cholesterol synthesis in rats. Br J Pharmacol* 2003; 138: 1459-64.
  26. Altmann SW, Davis HR Jr, Zhu LJ, Yao X, Hoos LM, Tetzloff G, Iyer SP, Maguire M, Golovko A, Zeng M, Wang L, Murgolo N, Graziano MP. *Niemann-Pick C1 Like 1 protein is critical for intestinal cholesterol absorption. Science* 2004; 303: 1201-4.
  27. Garcia-Calvo M, Lisnock J, Bull HG, Hawes BE, Burnett DA, Braun MP, Crona JH, Davis HR Jr, Dean DC, Detmers PA, Graziano MP, Hughes M, Macintyre DE, Ogawa A, O'Neill KA, Iyer SP, Shevell DE, Smith MM, Tang YS, Makarewicz AM, Ujjainwalla F, Altmann SW, Chapman KT, Thornberry NA. *The target of ezetimibe is Niemann-Pick C1-Like 1 (NPC1L1). Proc Natl Acad Sci USA* 2005; 102: 8132-7.
  28. Fujita H, Banno H, Yamanouchi D, Kobayashi M, Yamamoto K, Komori K. *Pitavastatin inhibits intimal hyperplasia in rabbit vein graft. J Surg Res* 2008; 148: 238-43.

29. van der Harst P, Groenewegen HC, Roks AJ, Buikema H, Zijlstra F, van Gilst WH, de Smet BJ. *Rosuvastatin attenuates angiotensin II-induced neointimal formation after stent implantation in the rat. Coron Artery Dis* 2008; 19: 47-53.
30. Kiyon J, Kusch A, Tkachuk S, Krämer J, Haller H, Dietz R, Smith G, Dumler I. *Rosuvastatin regulates vascular smooth muscle cell phenotypic modulation in vascular remodeling: role for the urokinase receptor. Atherosclerosis* 2007; 195: 254-61.