



OPEN ACCESS

'Vanishing' fragmented potential at the epicardium in a patient with Brugada syndrome

Tatsuya Hayashi,¹ Yukio Sekiguchi,² Shingo Yamamoto,¹ Hideo Fujita¹

► Additional supplemental material is published online only. To view, please visit the journal online (<http://dx.doi.org/10.1136/bcr-2022-249054>).

¹Division of Cardiovascular Medicine, Saitama Medical Center, Jichi Medical University, Saitama, Japan

²Department of Cardiology, Kasumigaura Medical Center, Tsuchiura, Japan

Correspondence to

Dr Tatsuya Hayashi;
tatsuya.hayashi@jichi.ac.jp

Accepted 12 July 2022

SUMMARY

A man in his 40s with Brugada syndrome underwent catheter ablation for ventricular fibrillation. When we performed epicardial mapping again to check for residual ablation sites after ablation, a remarkable reproducible fragmented potential was observed at the anterior aspect of the right ventricle using an Advisor HD Grid (Abbott), which had not been detected during the initial mapping before ablation, and which was invisible to the ablation catheter. Fluoroscopic imaging demonstrated a shiny area anterior to the heart, suggesting trapped air, presumed to have arisen when the sheath was inserted into the pericardial space. The air trapped between the heart and pericardium prevented the HD grid from contacting the epicardium, resulting in the recording of a fragmented potential. The trapped air was removed manually via the sheath, and the potential vanished. When fragmented potentials are observed at the anterior right ventricle (RV) in the epicardium, air trapping should be ruled out by fluoroscopy.

BACKGROUND

Effective ablation for Brugada syndrome requires ablation of all fragmented potentials,¹ and because the arrhythmogenic substrate of Brugada syndrome is on the epicardial side, this means ablation is largely delivered via an epicardial approach. Epicardial ablation can result in recording artefacts different from those encountered during endocardial ablation.

CASE PRESENTATION

A man in his 40s with Brugada syndrome and an implantable cardiac defibrillator underwent catheter ablation for frequent ventricular fibrillation episodes (online supplemental figure 1). Under

general anaesthesia, we punctured the pericardium below the xiphoid and inserted a sheath into the pericardial space (Agilis NxT Steerable Introducer, Abbott, USA). Epicardial mapping using the Advisor HD Grid Mapping Catheter (Abbott, USA) revealed fragmented potentials mainly on the anterior aspect of the right ventricle, which we proceeded to ablate. After the initial round of ablation, we performed epicardial mapping a second time to check for residual ablation sites, and discovered a remarkable reproducible fragmented potential at the anterior aspect of the right ventricle (figure 1A), which had not been detected in the initial mapping. To ablate this potential, we exchanged the HD grid catheter with an ablation catheter but were surprised when we could not detect this abnormal potential with the ablation catheter (figure 1B).

Fluoroscopic imaging in the anterior-posterior projection showed no significant changes from an earlier image taken during the procedure. However, a lateral projection image taken next demonstrated a shiny area in front of the heart, suggesting trapped air (figure 2A) that likely arose from the gap created by the Agilis sheath. The trapped air was removed manually using the same sheath (figure 2B). After removal, the potential 'vanished' and was no longer observable using HD grid entire area around this location (figure 3). Online supplemental figure 2 shows the precise position of the HD grid and ablation catheter before and after air removal on 3D mapping as well as their local EGMs.

OUTCOME AND FOLLOW-UP

We did not perform any further ablation, and the patient has been free of ventricular fibrillation in a year of follow-up.

DISCUSSION

This case report demonstrates a 'vanishing' epicardial fragmented potential which was caused by trapped air in the epicardium.

Artefact with HD grid

HD grid is a high-density electrode mapping catheter that ends in a square wafer of 4×4 electrodes of 1 mm length distributed every 3 mm square. Since the wafer is about 1 mm thick, it can map even in narrow spaces, including epicardial spaces. However, due to its slenderness, the contact between the catheter and heart can be weaker in larger epicardial spaces, resulting in insufficient cardiac potential recording and artefacts. We described a case in which artifactual potentials were recorded that were likely caused by air trapped in

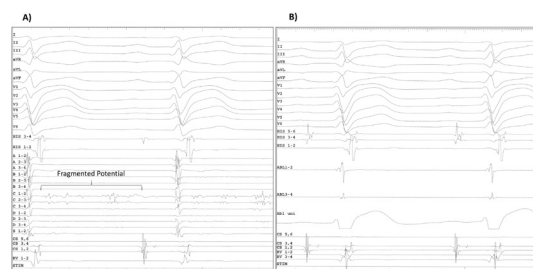
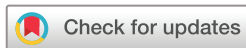

Figure 1 (A) Fragmented potentials were recorded in the HD grid electrodes at the anterior aspect of the right ventricle in the pericardium. (B) An ablation catheter was inserted into the epicardial space to ablate the fragmented potentials observed by the HD grid mapping catheter. However, those potentials could not be seen.



© BMJ Publishing Group Limited 2022. Re-use permitted under CC BY-NC. No commercial re-use. See rights and permissions. Published by BMJ.

To cite: Hayashi T, Sekiguchi Y, Yamamoto S, et al. *BMJ Case Rep* 2022;**15**:e249054. doi:10.1136/bcr-2022-249054

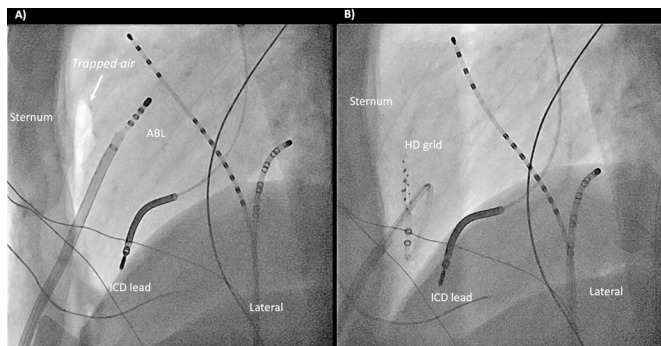


Figure 2 (A) Trapped air (shiny area at the anterior aspect of the right ventricle) was observed by fluoroscopy in a lateral projection (the ablation catheter was placed in the lateral site at this time). (B) The HD grid catheter was reinserted at the anterior surface of the right ventricle after removal of the trapped air.

the epicardial space. The artefacts appeared reproducibly in every heartbeat and were difficult to distinguish from actual local fragmented potentials.

In our case, the fragmented potentials picked up by HD grid were not recorded by the ablation catheter, so this led us to consider the possibility of artefact. Fluoroscopy demonstrated trapped air in the pericardium. We believe the trapped air between the heart and pericardium prevented the HD grid from contacting the epicardium, resulting in the appearance of a fragmented potential. The high-resolution of the HD grid electrodes likely contributed to their sensitivity to noise. The ablation catheter, in contrast, likely did not display artefact because it is thicker (about 2.7 mm) and fit the space more snugly, and lower resolution. We experienced this rare phenomenon due to a ‘perfect’ amount of air that was just right for the HD grid to pick up artefacts and for the ablation catheter not to pick up artefacts. We did not deliver RF application at this location based on the belief that it was an artefact, and indeed, this patient has not had recurrence of ventricular fibrillation more than a year of follow-up in the absence of antiarrhythmic drugs.

To the best of our knowledge, this is the first report to describe trapped air in the pericardial space leading to

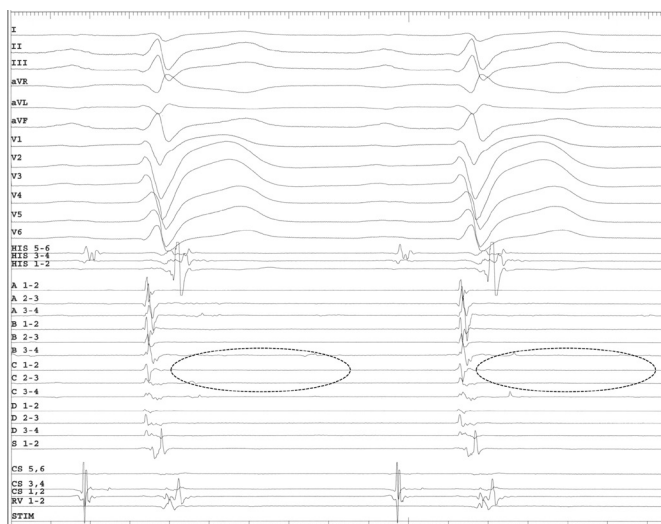


Figure 3 The HD grid electrodes show the fragmented potentials had vanished after trapped air removal.

Learning points

- ▶ During epicardial ablation, air can become trapped in the pericardial cavity. Air in the anterior aspect of the right ventricle can result in artefact that is indistinguishable from fragmented potentials.
- ▶ The trapped air cannot be identified by 3D mapping, so it needs to be confirmed by fluoroscopy, for which we recommend a lateral projection.
- ▶ Trapped air may cause complications and is best checked for and removed at the end of epicardial procedures.

Patient's perspective

I was very worried about the frequent shocks caused by ICD due to ventricular fibrillation of Brugada syndrome.

I am now free from shocks without anti-arrhythmic drugs and am doing very well.

appearance of a fragmented local potential. Artefacts can be caused by mechanical bumps, and in the epicardial space, they are likely to occur when space is created between the catheter and myocardium.² When using HD grid for epicardial mapping, one should be aware of artefacts caused by such trapped air, especially when a local fragmented potential is observed at the anterior RV epicardium.

Air trapping in the pericardium

Epicardial puncture is an essential ablation technique when targeting arrhythmogenic substrates on the epicardial side. Epicardial puncture is known to cause major complications in about 5% of cases³ and can also cause atypical complications involving thoracic structures.⁴ However, there are few reports of complications related to trapped air. Trapped air during or after catheter ablation in the pericardial space sometimes increases the defibrillation threshold⁵ or can cause pneumopericardium leading to drop in blood pressure.⁶ Trapped air should be checked for during or at the end of ablation procedures involving the pericardial space and removed if present.

Trapped air is hard to recognise by 3D mapping. Once trapped air is suspected, it should be ruled out by fluoroscopy, for which we recommend a lateral projection. Fluoroscopy can also be used to confirm successful removal of the air. In our case, we removed the trapped air with the sheath which had been used to insert the HD grid, but if air removal proves difficult with the instruments at hand, we recommend use of a pigtail catheter because it can reach every corner of the pericardial space.

Contributors TH: planning, conduct, reporting; YS: interpretation; SY: acquisition of data; HF: final approval.

Funding The authors have not declared a specific grant for this research from any funding agency in the public, commercial or not-for-profit sectors.

Competing interests None declared.

Patient consent for publication Consent obtained directly from patient(s).

Provenance and peer review Not commissioned; externally peer reviewed.

Open access This is an open access article distributed in accordance with the Creative Commons Attribution Non Commercial (CC BY-NC 4.0) license, which permits others to distribute, remix, adapt, build upon this work non-commercially, and license their derivative works on different terms, provided the original work

is properly cited and the use is non-commercial. See: <http://creativecommons.org/licenses/by-nc/4.0/>.

Case reports provide a valuable learning resource for the scientific community and can indicate areas of interest for future research. They should not be used in isolation to guide treatment choices or public health policy.

REFERENCES

- 1 Nademanee K, Veerakul G, Chandanamattha P, *et al*. Prevention of ventricular fibrillation episodes in Brugada syndrome by catheter ablation over the anterior right ventricular outflow tract epicardium. *Circulation* 2011;123:1270–9.
- 2 Romero J, Ajjola O, Shivkumar K, *et al*. Characterization of aortic valve closure artifact during outflow tract mapping: correlation with hemodynamics and mechanical valves. *Circ Arrhythm Electrophysiol* 2017;10:e004845.
- 3 Sacher F, Roberts-Thomson K, Maury P, *et al*. Epicardial ventricular tachycardia ablation. *J Am Coll Cardiol* 2010;55:2366–72.
- 4 Killu AM, Friedman PA, Mulpuru SK, *et al*. Atypical complications encountered with epicardial electrophysiological procedures. *Heart Rhythm* 2013;10:1613–21.
- 5 Yamada T, McElderry HT, Platonov M, *et al*. Aspirated air in the pericardial space during epicardial catheterization may elevate the defibrillation threshold. *Int J Cardiol* 2009;135:e34–5.
- 6 Wakabayashi Y, Hayashi T, Mitsuhashi T, *et al*. Tension pneumopericardium after pericardiocentesis: useful echocardiographic obscured heart sign and effective postural change during air aspiration. *Heart Rhythm* 2018;15:1116.

Copyright 2022 BMJ Publishing Group. All rights reserved. For permission to reuse any of this content visit <https://www.bmj.com/company/products-services/rights-and-licensing/permissions/>
BMJ Case Report Fellows may re-use this article for personal use and teaching without any further permission.

Become a Fellow of BMJ Case Reports today and you can:

- ▶ Submit as many cases as you like
- ▶ Enjoy fast sympathetic peer review and rapid publication of accepted articles
- ▶ Access all the published articles
- ▶ Re-use any of the published material for personal use and teaching without further permission

Customer Service

If you have any further queries about your subscription, please contact our customer services team on +44 (0) 207111 1105 or via email at support@bmj.com.

Visit casereports.bmj.com for more articles like this and to become a Fellow