

Received: 2010.11.05
Accepted: 2011.01.27
Published: 2011.05.01

Candidemia in children after complex congenital heart defects surgery treated with caspofungin – our own experience and a review of literature

Authors' Contribution:

- A** Study Design
- B** Data Collection
- C** Statistical Analysis
- D** Data Interpretation
- E** Manuscript Preparation
- F** Literature Search
- G** Funds Collection

Radoslaw Jaworski^{1ADEF}, Ninela Irga^{2ADE}, Ireneusz Haponiuk^{1BCD},
Maciej Chojnicki^{1BCD}, Elzbieta Arlukowicz^{3CDF}, Mariusz Steffek^{1AEF},
Mariusz Sroka^{1CD}, Katarzyna Gierat-Haponiuk^{4EF}, Jacek Juscinski^{1EF},
Lucyna Palkowska^{1BDE}, Aneta Sendrowska^{1BE}, Wojciech Kosiak^{2BCD}

¹ Department of Pediatric Cardiac Surgery, Mikołaj Kopernik Pomeranian Centre of Traumatology, Gdansk, Poland

² Department of Pediatrics, Hematology, Oncology and Endocrinology, Medical University of Gdansk, Gdansk, Poland

³ BRUSS Laboratories, ALAB group, Medical Microbiological Laboratory, Gdynia, Poland

⁴ Department of Rehabilitation, Medical University of Gdansk, Gdansk, Poland

Source of support: Self financing

Summary

Background:

Invasive fungal infections due to *Candida* species constitute an increasing clinical problem. There are no guidelines for the management of candidemia in children undergoing surgical procedures for congenital heart defects (CHD). The aim of the study was to draw attention to the problem of candidemia in children who are operated on due to congenital heart defects.

Material/Methods:

We retrospectively analyzed medical documentation of 307 children with congenital heart defects treated in 1 clinical centre in Poland, from whom we selected those diagnosed with candidemia during the postoperative period. Next, we analyzed in detail the clinical course of invasive candidiasis in each individual and we performed an analysis of risk factors that lead to candidemia.

Results:

In the analyzed period, among 307 children who underwent surgical procedures, we observed 2 cases of candidemia (0.65%) which were effectively cured with caspofungin. No adverse effects were observed after treatment with the drug.

Conclusions:

Candidemia in children who undergo surgical treatment of congenital heart defects is an important factor that can influence final clinical results. Caspofungin may be an effective therapeutic option when treating candidemia in children after extensive cardiosurgical procedures.

key words:

candidemia • caspofungin • congenital heart defects • pediatric cardiac surgery • postoperative treatment

Full-text PDF:

<http://www.medscimonit.com/fulltxt.php?ICID=881751>

Word count:

2961

Tables:

–

Figures:

2

References:

17

Author's address:

Radoslaw Jaworski, Department of Pediatric Cardiac Surgery, Mikołaj Kopernik Pomeranian Centre of Traumatology, 1-6 Nowe Ogrody Str., 80-803 Gdańsk, Poland, e-mail: radicis@go2.pl

BACKGROUND

Invasive fungal infections due to *Candida* species constitute an increasing clinical problem. In recent years, those fungal species have become the fourth most common etiological cause of systemic infections in children. Data from the literature suggest that surgical procedures may constitute a significant risk factor, making the spread of infection easier [1]. Due to diagnostic problems and often extremely rapid clinical course, many invasive fungal infections due to *Candida* species are diagnosed during *post-mortem* examinations. Unfortunately, there are no clear guidelines for therapeutic management of candidemia in children operated on for congenital heart defects (CHD). Only single case reports on the problem are available, and to the best of our knowledge, until now only 1 case of effective caspofungin therapy in this group of patients has been reported [2]. The majority of papers on this topic have described use of echinocandins in children with proliferative diseases of the hematopoietic system. Clinical practice guidelines for the management of candidiasis in cardiac surgery updated in 2009 concern only adult patients [3].

The aim of the study was to draw attention to the problem of candidemia in children who are operated on for congenital heart defects. Additionally, we have analyzed all the available literature on the management of candidemia in children undergoing cardiosurgical procedures.

MATERIAL AND METHODS

We retrospectively analyzed medical documentation of 307 children with congenital heart defects treated in the period between January 2008 and July 2010 in the Department of Pediatric Cardiac Surgery, Pomeranian Centre of Traumatology in Gdańsk (Poland). We included in our analysis both the children who were operated on with extracorporeal circulation (ECC), and those operated on without extracorporeal circulation (non-ECC). From all 307 cases, we selected children who had candidemia due to *Candida* species diagnosed on the basis of positive blood cultures during the postoperative period.

Blood samples were collected onto PediBact multiplication medium. Incubation was carried out in the BacT/ALERT 3D system (bioMerieux SA, EU). Reaching sufficient growth, the material was cultured on various solid media, including chromogenic medium for culturing *Candida* ID2 (bioMerieux SA, EU). Identification was carried out with 2 methods: with use of API ID 32C test (ATB Expression, bioMerieux SA, EU) in case of species other than *C. albicans*, and with use of the YST test card (Vitek 2, bioMerieux SA, EU) to confirm identification of *C. albicans* [4–6]. Drug sensitivity was determined with 2 methods: for species other than *C. albicans* it was done with ATB Fungus 3 test (ATB Expression, bioMerieux SA, EU), and for *C. albicans* it was done with the AST-YS01 test (Vitek 2, bioMerieux SA, EU). Sensitivity to caspofungin was determined with the E-test on RPMI medium (Biomed, EU). The results of the procedures were interpreted according to the established guidelines for clinical microbiology. Reference species were used to control biochemical tests and drug sensitivity determination.

Next, we analyzed in detail the clinical course of invasive fungal infection in each individual with candidemia. We

performed an analysis of risk factors for the studied children in respect to risk factors of candidemia described in the literature, which include neutropenia, receipt of immunosuppressive agents, diabetes mellitus, prematurity and/or secondary immune deficiencies, presence of congenital heart defects, prolonged antibiotic therapy (over 5 days), previous *Candida* species colonization, receipt of total parenteral nutrition, extracorporeal circulation, presence of intravascular thrombus or implantable prosthetic devices, and receipt of renal replacement therapy [1,3,7–10]. Next, we analyzed the course of treatment of candidemia in the selected children and long-term results of the therapy. Adverse effects of the applied antifungal management were also assessed.

RESULTS

During the analyzed period, 307 children with CHD were operated on in our Department, including 119 with ECC and 188 with non-ECC. Two of them (0.65%) had candidemia diagnosed during the postoperative period and the infection was successfully treated with caspofungin.

The first patient was a 20-month-old girl (AW) with the diagnosis of a complex congenital heart defect in the form of coarctation of the aorta (CoA) and double-outlet right ventricle (DORV). In the neonatal period the patient underwent a successful surgical procedure of aortic arch repair using the extended end-to-end method, patent ductus arteriosus (PDA) ligation and pulmonary artery banding (PA banding). At the age of 20 months (body weight 9 kg), the performed diagnostic tests confirmed the correct repair of aortic coarctation (with no gradient in the area of previous stenosis) and DORV with non-restrictive non-committed VSD (DORV-nc-VSD) of about 15 mm in diameter. The child was referred for a surgical correction of the defect. Microbiological examinations performed before the surgical procedure confirmed colonization with *C. albicans* in the nasal cavity. The surgical procedure included DORV correction with Kawashima intraventricular tunnelization with Dacron Savage patch with ECC. After removal of the banding, the pulmonary artery trunk was widened with an autologous pericardial patch. The early postoperative period was complicated with heart failure, therefore support with high doses of catecholamines and delayed sternum closure was necessary. Additionally, the child needed peritoneal dialysis due to acute renal failure (10 days) and total parenteral nutrition (TPN) (16 days). On the eleventh day after the surgery, despite compensation of the cardiovascular system sternum closure, use of antibiotic agents (tazobactam + cefoperazone, vancomycin) and antifungal prophylaxis (fluconazole), the general condition of the girl deteriorated and fever >38.5 degrees Celsius was noted. We observed significantly increased leucocytosis with a left shift (47.3 G/L) and a slight increase of acute-phase reactants (CRP 24 mg/L, normal range <5 mg/L). Blood samples from the central venous catheter were cultured. Two days later, *Candida albicans* isolates were identified in the blood (minimal inhibitory concentration (MIC) for caspofungin 0.023 mg/L; for fluconazole ≤ 1 mg/L; for amphotericin B ≤ 0.25 mg/L). The antifungal management was altered and caspofungin was initiated (loading dose of 70 mg/m², 50 mg/m² daily thereafter). Clearance of *Candida* from the blood was documented and we observed a gradual decrease

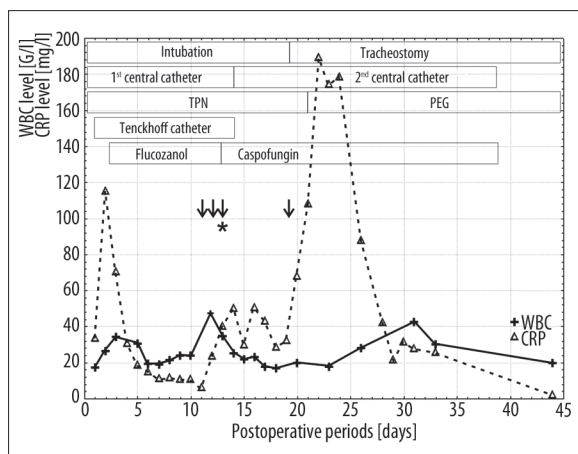


Figure 1. Graph illustrating WBC and CRP levels on consecutive postoperative days for the girl with DORV, together with the main risk factors and antifungal therapies. Arrows signify positive *Candida albicans* isolates from the bloodstream; asterisk – telephone information on positive *Candida* isolates from the bloodstream.

of leucocytosis. Antifungal therapy was continued for the next 20 days. Over this period, we noted an increase of CRP and leucocytosis. In our opinion, the incident was related to surgical procedures: tracheostomy and percutaneous endoscopic gastrostomy (PEG). After the removal of tracheostomy and PEG (48 days after the surgery) and implementation of intensive rehabilitation, we observed final recovery of the child (Figure 1).

The other patient was an 8-month-old boy (LD) (body weight 6 kg) who was qualified for a corrective surgery of tetralogy of Fallot (ToF) with a critical narrowing of the outflow tract from the right ventricle (RV), with an anomalous course of coronary vessels, hypoplasia of the PA trunk and malalignment ventricular septum defect (VSD) of 15 mm in diameter. Microbiological examinations performed before the surgical procedure excluded *Candida* colonization. During the surgical correction of the defect with ECC with use of a xenograft (Contegra, USA), we found the thymus to be small and restricted to a single lobe. The early postoperative period was complicated with heart failure and acute renal failure, requiring peritoneal dialysis (3 days). We observed an outflow of dialysis fluid from the pleura despite no iatrogenic communication between the peritoneum and the pleura. On the tenth day after the surgery, despite the use of broad-spectrum antibiotic agents (meropenem, vancomycin) and antifungal prophylaxis (fluconazole), we observed high fever (38.3 degrees Celsius) and deterioration of the general condition of the child. Blood samples from the central venous catheter were cultured; candidemia with *Candida parapsilosis* isolates was diagnosed (MIC for caspofungin =0.75 mg/L; for fluconazole <1.0 mg/L; for amphotericin B <0.5 mg/L). Fluconazole administration was discontinued and caspofungin was initiated (loading dose of 70 mg/m², 50 mg/m² daily thereafter). Positive *C. parapsilosis* isolates from the pleural drainage were also documented. Blood cultures became negative 20 days after the first positive *C. parapsilosis* isolates, despite replacement of the central venous catheter. Cultures from the drainage became negative on the fifth day of the antifungal therapy. The

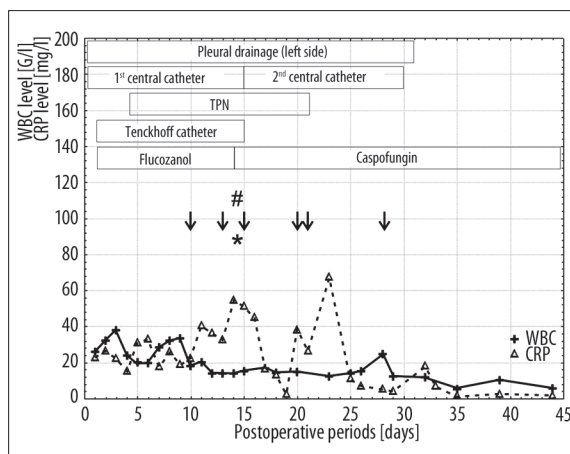


Figure 2. Graph illustrating WBC and CRP levels on consecutive postoperative days for the boy with ToF, together with the main risk factors and antifungal therapies. Arrows signify positive *Candida parapsilosis* isolates from the bloodstream; hash – positive *Candida parapsilosis* isolate from the pleural drainage; asterisk – telephone information on positive *Candida* isolates from the bloodstream.

total time of caspofungin management reached 34 days (Figure 2). The child was discharged home with no symptoms of heart failure or infection after rehabilitation in our pediatric hospital.

In the both presented cases, systemic infection was suggested on the basis of clinical symptoms (high fever, deterioration of general condition) and prior the results of laboratory tests (increased leucocytosis and CRP), and the final diagnosis of fungemia was based on microbiological examinations. The risk factors present in both patients were: congenital heart defects, use of extracorporeal circulation (ECC), central venous catheters, previous treatment with broad-spectrum antibiotic agents, receipt of parenteral nutrition (TPN), renal replacement therapy, and use of implantable prosthetic devices. The applied antifungal therapy with caspofungin enabled complete eradication of the infection. No adverse effects were observed after treatment with the drug.

The follow-up for these patients is currently 13 and 9 months after the surgical procedures. During this period, we observed no recurrent fungal infections, long-term consequences or symptoms that might be related to the past infection or the applied antifungal treatment.

DISCUSSION

Invasive fungal infections due to *Candida* species constitute the fourth most common etiological cause of systemic infections in the USA [9,10]. They are a significant therapeutic problem, since it has been estimated that the attributable mortality of *Candida* infections in children is 10–15% [11]. It is also reported that in the subgroup of children with CHD after cardiac surgery, the attributable mortality reaches 39%, and in infants below 6 months of age it may be as high as 83% [1,7]. Non-albicans species tend to be more common world-wide in comparison to *Candida albicans*, which most probably results from frequent administration of azole

antifungals and from a concomitant increase of resistance to administered drugs [10]. In the case of candidemia in children with CHD after cardiac surgeries, the most common etiologic factor is *C. parapsilosis* (54%), followed by *C. albicans* (42%), and other species are detected significantly less frequently (4%) [1]. In our pediatric patients with CHD after cardiac procedures, candidemia was detected only in 2 patients, however it must be emphasized that our study was carried out in a relatively limited population. Risk factors which lead to candidemia include: neutropenia, receipt of immunosuppressive agents, diabetes mellitus, prematurity, primary and/or secondary immune deficiencies (including AIDS), CHD, prolonged antibiotic therapy (over 5 days), previous *Candida* species colonization, TPN, ECC by-pass time, presence of intravascular thrombus, presence of central venous catheter, receipt of renal replacement therapy and implantable prosthetic devices [3,7,12].

Both patients showed an acute postoperative course which resulted from extended corrective procedures of complex heart defects (DORV-nc-VSD, complex form of ToF). Prolonged catecholamine support with subcompensation periods of the cardiovascular system, extended antibiotic therapy, increased period of central cannulation, parenteral nutrition and peritoneal dialysis applied in those patients are all common elements of intensive postoperative care that increase the risk for development of invasive fungal infections. The correction of complex heart defects in the described patients required the use of implantable prosthetic devices, including a xenograft, which significantly increases the risk of infections, including fungal infections. Due to acute renal failure related to circulatory failure, peritoneal dialyses were necessary in both patients.

Primary immune deficiencies (PID) are a well-known risk factor that leads to invasive fungal infections. In pediatric cardiac surgery it is extremely important to realize that some complex heart defects are accompanied by primary immune deficiencies. DiGeorge syndrome (CATCH 22) is the most common PID with a co-existing CHD, and is characterized by phenotypical thymic aplasia or hypoplasia related to cellular immune deficiencies [13]. Therefore, we suggest that when qualifying the child for a cardiosurgical procedure, special attention should be paid to the presence or absence of the thymus gland during preoperative diagnosis and during the operation. Patients who have microscopical thymic aplasia or hypoplasia are at higher risk for invasive fungal infections. A cardiac surgeon or cardiologist who detects thymic aplasia is obliged to refer the child to a specialist immunological centre in order to perform diagnostic tests for DiGeorge syndrome [14]. The described patient with ToF who had thymic hypoplasia detected intraoperatively, currently undergoes a genetic process of diagnosis for CATCH 22 syndrome. In the discussed group of children with diagnosed or suspected PID, introduction of antifungal prophylaxis or pre-emptive therapy in the early postoperative period might be of great importance.

Unfortunately, there are no guidelines for diagnostic and therapeutic management of candidemia in children undergoing cardiosurgical procedures. Therefore, for the described children we decided to apply guidelines for non-neutropenic patients, as well as guidelines for oncohematological children [3]. The only available guidelines

in cardiac surgery involve adult patients, mainly in the following cases: native valve endocarditis, valve replacement candidemia, prosthetic valve endocarditis, pericarditis, myocarditis, suppurative thrombophlebitis, pacemaker and implantable cardiac defibrillator wire infections or ventricular assist devices infection [3].

According to the available literature, the median time from the surgical procedure to the first symptoms of candidemia after admitting the child to an ICU is 19–24 days [1,7]. In the described patients, this time was 10 and 11 days. The main symptoms that may suggest candidemia include high body temperature over 38 degrees Celsius (in 73% of patients), increased WBC and a moderate increase of CRP, as well as deterioration of the general condition of the child – both of the described children demonstrated these symptoms [1]. For the children presented in this paper, the time between initiation of treatment and the first negative blood cultures was 9 days in the first case, and 20 days in the other. The total therapy time was 29 days for eradication of *C. albicans* and 34 days for eradication of *C. parapsilosis*. Chakradabi described a group of 6 infants operated on for CHD, for whom the median time of infection after introducing antifungal treatment was 17 days (range 12–32) [7].

When candidemia is diagnosed, it is recommended to remove central catheters and other artificial elements such as drains, probes or catheters, even if the condition of the child remains severe [1]. We suggest, however, that risk-benefit ratio should always be considered. The removal of the central venous catheter seems to be safe only when another central catheter is placed, especially when the condition of the patient remains unstable and the patient requires administration of catecholamines and/or parenteral nutrition. Central venous catheters were removed and replaced in both the described patients. We decided to leave the drainage in the left pleural cavity of the patient with ToF, despite positive *C. parapsilosis* isolates, because of the severe condition of this child. It was unconditionally necessary to maintain the pleural drainage due to lymphorrhea and the risk related to another introduction of the drainage was assessed as too high.

It is especially important to administer the correct antifungal agent when managing candidemia, mainly in the case of previous exposure to azoles. The 2009 guidelines for empirical treatment and treatment of confirmed candidemia in adult non-neutropenic patients recommend administration of fluconazole for stable patients and echinocandins for patients in moderately severe to critically condition, or for patients have had recent azole exposure [7]. Transition from an echinocandin to fluconazole is recommended for clinically stable patients after confirming susceptibility of the isolate to azoles. The recommended duration of therapy is for 2 weeks after documented clearance of *Candida* from the bloodstream. Amphotericin B is the treatment of choice in neonates.

Caspofungin is an echinocandin, a class of antifungal agents which were not yet described in the guidelines in 2000 [15]. Guidelines for clinical management with use of this drug were included in the study by Pappas et al. in 2004 [16]. The drug has a unique mechanism of action on the cell wall and therefore is active against all *Candida* species, even

though *C. parapsilosis* demonstrates less *in vitro* susceptibility to the drug. However, in clinical studies it has not been proved [17]. Another advantage of caspofungin is that it does not require dosage adjustments for renal insufficiency or dialysis [3]. It is important for children who undergo cardiosurgical procedures with ECC, since the procedures are frequently complicated with renal insufficiency. Both of the studied children had acute renal failure which required receipt of renal replacement therapy. Caspofungin is well tolerated by patients – there are hardly any interactions with other drugs. Similarly to reported patients with neoplasms, the children treated by our team did not show any adverse reactions related to administration of the drug.

Echinocandins are not the drug of first choice for positive *Candida parapsilosis* isolates. We decided to introduce caspofungin in our both patients because of the previous fluconazole exposure, which is in concordance with the guidelines [3]. Concomitant renal insufficiency which required receipt of renal replacement therapy was another reason for our choice of treatment. The determination of drug sensitivity on the second day after initiating caspofungin in the patient with *Candida parapsilosis* infection confirmed that the selected therapeutic option was rational.

When suspecting candidiasis of the CNS, treatment with echinocandins is not recommended. Our patients did not show any symptoms that might have suggested a neuroinfection. Candidal endophthalmitis was excluded on the basis of a dilated retinal examination.

For the presented cases, we are convinced that clinical alertness and fast mycological identification led to diagnosis of the disease, introduction of targeted antifungal treatment and the final positive therapeutic outcome, as it is commonly considered that early initiation of effective antifungal therapy is crucial [3]. We believe, as do other authors, that pre-emptive therapy should be considered for patients with CHD and additional risk factors for infection when no microbiological confirmation is available [12].

CONCLUSIONS

Initiation of caspofungin in the management of candidemia in both the described patients after complex cardiac procedures, despite the lack of precise guidelines for the use and

effectiveness of the drug in the case of infections of this type in pediatric cardiac surgery, proved to be a successful method which safely led to fungal infection control and protected the patients against full-symptom sepsis.

REFERENCES:

1. San Miguel LG, Cobo J, Otheo E et al: Candidemia in pediatric patients with congenital heart disease. *Diagn Microbiol Infect Dis*, 2006; 55: 203–7
2. Mrowczynski W, Wojtalik M: Caspofungin for *Candida endocarditis*. *Pediatr Infect Dis J*, 2004; 23: 376
3. Pappas PG, Kauffman CA, Andes D et al: Clinical practice guidelines for the management of candidiasis: 2009 update by the Infectious Diseases Society of America. *Clin Infect Dis*, 2009; 48: 503–35
4. Cardenas-Perera CD, Torres-Lana A, Alonso-Vargas R et al: Evaluation of API ID 32C and VITEK-2 to identify *Candida dubliniensis*. *Diagn Microbiol Infect Dis*, 2004; 50: 219–21
5. Cejudo MA, Gallego AG, Lacasa EC et al: Evaluation of the VITEK 2 system to test the susceptibility of *Candida* spp., *Trichosporon asahii* and *Cryptococcus neoformans* to amphotericin B, flucytosine, fluconazole and voriconazole: a comparison with the M27-A3 reference method. *Med Mycol*, 2010; 48: 710–19
6. Torres-Rodriguez JM, Alvarado-Ramirez E: *In vitro* susceptibilities to yeasts using the ATB FUNGUS 2 method, compared with Sensititre Yeast One and standard CLSI (NCCLS) M27-A2 methods. *J Antimicrob Chemother*, 2007; 60: 658–61
7. Chakrabarti C, Sood SK, Parnell V, Rubin LG: Prolonged candidemia in infants following surgery for congenital heart disease. *Infect Control Hosp Epidemiol*, 2003; 24: 753–57
8. Garcia-San ML, Cobo J, Martos I et al: Risk factors for candidemia in pediatric patients with congenital heart disease. *Infect Control Hosp Epidemiol*, 2006; 27: 576–80
9. Sims CR, Ostrosky-Zeichner L, Rex JH: Invasive candidiasis in immunocompromised hospitalized patients. *Arch Med Res*, 2005; 36: 660–71
10. Singhi S, Deep A: Invasive candidiasis in pediatric intensive care units. *Indian J Pediatr*, 2009; 76: 1033–44
11. Zaoutis TE, Argon J, Chu J et al: The epidemiology and attributable outcomes of candidemia in adults and children hospitalized in the United States: a propensity analysis. *Clin Infect Dis*, 2005; 41: 1232–39
12. Garcia-San ML, Cobo J, Martos I et al: Risk factors for candidemia in pediatric patients with congenital heart disease. *Infect Control Hosp Epidemiol*, 2006; 27: 576–80
13. Sedivá A, Bartůnková J, Zachová R et al: Early development of immunity in diGeorge syndrome. *Med Sci Monit*, 2005; 11(4): CR182–87
14. Sane SY: Di-George's syndrome with multiple infections (an autopsy report). *J Postgrad Med*, 1989; 35: 114–15
15. Rex JH, Walsh TJ, Sobel JD et al: Practice guidelines for the treatment of candidiasis. *Infectious Diseases Society of America. Clin Infect Dis*, 2000; 30: 662–78
16. Pappas PG, Rex JH, Sobel JD et al: Guidelines for treatment of candidiasis. *Clin Infect Dis*, 2004; 38: 161–89
17. Bennett JE: Echinocandins for candidemia in adults without neutropenia. *N Engl J Med*, 2006; 355: 1154–59