

Access this article online

Quick Response Code:



Website:

www.ajts.org

DOI:

10.4103/ajts.ajts_30_21

Patient blood management in a neurosurgical patient with anti-e antibody

Sreethu Chand, Anila Mani, R. Amita, Debasish Gupta

Abstract:

The successful application of patient blood management approach in a 48-year-old neurosurgery patient planned for meningioma excision and requiring transfusion is described. The patient had multiple past immunizing events and developed antibody against a high-frequency antigen “e” of the Rh blood group system. With the joint effort from transfusion medicine specialist, anesthesiologist, and surgeon, the patient was successfully managed using the preoperative autologous blood donation program.

Keywords:

Alloimmunization, anti-e, autologous blood donation, patient blood management

Introduction

Patient blood management (PBM) is an evidence-based multidisciplinary approach to optimize the care of patients who need blood transfusion.^[1] Preoperative autologous blood donation (PAD) where the patient donates his/her blood few weeks before the surgery has been a primary modality of therapy to reduce the use of Allogeneic blood. PAD program is an option for patients with rare blood types, patients alloimmunized to multiple red cell antigens, and for those having an antibody against a high-frequency red cell antigen.^[2]

Case Report

A 48-year-old female with recurrent atypical meningioma was admitted to a tertiary care hospital and was planned elective craniotomy and decompression surgery. Her blood group was typed as O Rh D positive. As per our maximum surgical blood order schedule, three units of packed

red blood cell concentrates were put for cross-matching. All three units were found to be incompatible.

Advanced immunohematology workup was done as detailed in Table 1. Antibody screening (3-cell panel, Reacell I II II from Tulip Diagnostics lot no. 722001) and identification (11-cell panel, Reacell panel from Tulip Diagnostics lot no. 741919) using commercial cell panel was suggestive of the presence of anti-e antibody of IgG type [Figure 1]. Extended Rh antigen phenotype of the patient was D+C-c+E+e- with a probable genotype of R2R2.

A detailed medical history of the patient was sought. She had significant past immunizing events, in the form of three pregnancies, past history of surgery for meningioma requiring transfusion of packed red cells 5 years back, and transfusion of packed red cells for anemia following menorrhagia 1 year back. A further 16 O Rh D-positive and 3 O Rh D-negative units available in inventory were also found incompatible on cross-matching. The treating anesthesia and

This is an open access journal, and articles are distributed under the terms of the Creative Commons Attribution-NonCommercial-ShareAlike 4.0 License, which allows others to remix, tweak, and build upon the work non-commercially, as long as appropriate credit is given and the new creations are licensed under the identical terms.

For reprints contact: WKHLRPMedknow_reprints@wolterskluwer.com

How to cite this article: Chand S, Mani A, Amita R, Gupta D. Patient blood management in a neurosurgical patient with anti-e antibody. Asian J Transfus Sci 2021;15:226-8.

Department of Transfusion
Medicine, Sree Chitra
Tirunal Institute for Medical
Sciences and Technology,
Thiruvananthapuram,
Kerala, India

Address for correspondence:

Dr. Debasish Gupta,
Department of Transfusion
Medicine, Sree Chitra
Tirunal Institute for Medical
Sciences and Technology,
Thiruvananthapuram -
695 011, Kerala, India.
E-mail: debasishgupta@
gmail.com

Submitted: 10-03-2021

Revised: 03-04-2021

Accepted: 11-04-2021

Published: 01-11-2021

Table 1: Results of immunohematology workup performed

Test	Result	Remarks
ABO and Rh grouping	O Rh D positive	No grouping discrepancy
Direct antiglobulin test	Negative	CTT
Indirect antiglobulin test	Positive	CTT and CAT
Autocontrol	Negative at 4°C, RT, and 37°C	CTT
Three-cell panel	Positive	CTT and CAT
Eleven-cell panel	Positive	CTT and CAT correspond to anti-e

CTT=Conventional tube technique, CAT=Column agglutination technique, RT=Room temperature

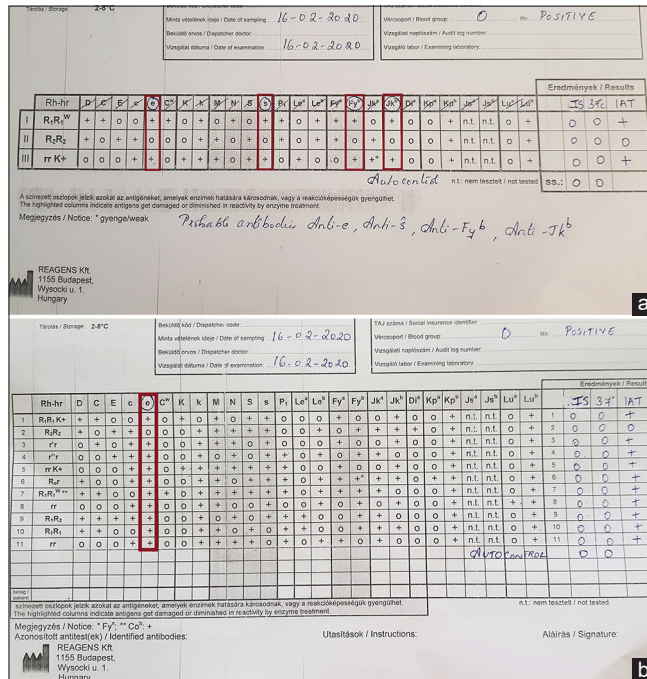


Figure 1: (a) Antibody screening using 3-cell panel and (b) identification using 11-cell panel

neurosurgery team was informed of the presence of antibody against high-prevalence “e” antigen of the Rh blood group system and the practical difficulty to obtain an antigen-negative compatible unit. Directed donation was not possible as she had no siblings and her both daughters were A Rh D positive.

Surgery was postponed with a plan to collect predeposit autologous blood units. Her initial hemoglobin was 13.2 g/dl, and two autologous whole blood (350 ml) units were collected at an interval of 1 week. Both blood units were separated into packed red cells and fresh frozen plasma and stored as autologous units. She was started on iron and folic acid supplementation, however, erythropoietin was not considered due to its stimulatory effect on tumor angiogenesis.

While in hospital, she developed impaired sensorium, seizures, and bladder incontinence due to the pressure effect of meningioma, with imminent transtentorial herniation. She developed high-grade fever with blood and urine culture exhibiting growth of Gram-negative

bacterial colonies of *Escherichia coli*. She was started on antibiotics and anti-edema medications, with continued iron and folic acid supplementation. Her blood cultures were sterile in 2 weeks, and surgery was scheduled immediately in view of her deteriorating neurological status. Surgeon and anesthesiologist on team were informed about the availability of only two autologous red cell units and fresh frozen plasma. The availability of group-compatible fresh frozen plasma, cryoprecipitate, and platelets was ensured. Surgery was done on day 21 calculated from the date of the first autologous blood unit collection. Intraoperative bleeding was estimated at a volume <1000 ml, and her arterial blood gas analysis showed hemoglobin of 11.4 g/dl toward the end of surgery. She was transfused with two units of autologous red cells and fresh frozen plasma. No allogeneic transfusion was required. Her postoperative period was uneventful and was discharged on day 7. Histopathology report was suggestive of atypical meningioma Grade 2. As the tumor could not be excised completely, there is a risk of recurrence. She is on regular follow-up for 4 months and is better symptomatically.

Discussion

Alloimmunization is a known adverse effect of blood transfusion. A literature review done by Al-Riyami and Daar on alloimmunization in transfusion-dependent thalassemia patients, found the estimated prevalence between 2.87% and 30%.^[3] The prevalence of alloantibodies in the general patient population was found to be 1.4% in a study from India.^[4] This variability in the prevalence of alloimmunization is due to the polymorphism of immunogenic blood group antigens, phenotypic differences among blood donors and recipients in different populations, and number of transfusions.^[5]

The detection of clinically significant alloantibody in a preoperative patient may delay the surgical procedure, particularly if the antibody is against a high-prevalence antigen as in our case or when there is presence of multiple red cell antibodies. Proper identification of antigen-negative units is of paramount importance, as otherwise hemolytic transfusion reaction can occur. In addition, delay in surgeries can have a deleterious effect on the health condition of the patient. Possible strategies

available in managing patients alloimmunized with high-frequency antigen include obtaining blood units either by directed donation or from a rare blood donor registry. Both of these were unsuccessful in our case, hence optimizing and conserving the patient's own blood using PBM strategies with a team-based approach was adopted for a successful clinical outcome.^[6]

In this case, we detected a clinically significant alloantibody against the high-frequency e antigen of Rh blood group system.^[7] The prevalence of "e" antigen in the Indian population is estimated at 98%–100%; hence, searching for an antigen-negative unit would have delayed the surgery further.^[8,9] Information regarding the difficulty in finding an antigen-negative unit was promptly conveyed to the treating team, and focus was given on the PBM strategies.^[10,11] Iron-folic acid supplementation, preoperative autologous blood collection as well as application of surgical techniques such as the use of tranexamic acid to minimize blood loss and fibrin glue as hemostatic agents, helped in successfully managing the patient.

Coordinated efforts from transfusion medicine specialist, anesthesiologist, and neurosurgeon helped in limiting the transfusion requirements of the patient to autologous blood units alone, thereby improving the patient outcome. The presence of a national database for rare donors can help the blood transfusion services (BTS) in managing patients with rare blood phenotypes, patients alloimmunized to multiple red cell antigens, or those having an antibody against a high-frequency red cell antigen as in our case.^[12] Establishing a rare donor registry in India can address these special needs and strengthen the BTS within the country.

Declaration of patient consent

The authors certify that they have obtained all appropriate patient consent forms. In the form the patient(s) has/have given his/her/their consent for his/her/their images and other clinical information to be reported in the journal. The patients understand that their names and initials will not be published and due efforts will be made to conceal their identity, but anonymity cannot be guaranteed.

Financial support and sponsorship

Nil.

Conflicts of interest

There are no conflicts of interest.

References

1. Frietsch T, Shander A, Faraoni D, Hardy JF. Patient blood management is not about blood transfusion: It is about patients' outcomes. *Blood Transfus* 2019;17:331-3.
2. Stehling L. Predeposit autologous blood donation. *Acta Anaesthesiol Scand Suppl* 1988;89:58-62.
3. Al-Riyami AZ, Daar S. Red cell alloimmunization in transfusion-dependent and transfusion-independent beta thalassemia: A review from the Eastern Mediterranean Region (EMRO). *Transfus Apher Sci* 2019;58:102678.
4. Zaman S, Chaurasia R, Chatterjee K, Thapliyal RM. Prevalence and Specificity of RBC Alloantibodies in Indian Patients Attending a Tertiary Care Hospital. *Adv Hematol* 2014;2014:749218.
5. Allali S, Peyrard T, Amiranoff D, Cohen JF, Chalumeau M, Brousse V, *et al.* Prevalence and risk factors for red blood cell alloimmunization in 175 children with sickle cell disease in a French university hospital reference centre. *Br J Haematol* 2017;177:641-7.
6. Sachan D, Tiwari AK, Dara R, Jothimani D, Kaliamoorthy I, Reddy SM, *et al.* Patient blood management in a patient with multiple red cell antibodies (anti-C, anti-e, and anti-K) undergoing liver transplant in South India: A team approach. *Asian J Transfus Sci* 2020;14:74-8.
7. Avent ND, Reid ME. The Rh blood group system: A review. *Blood* 2000;95:375-87.
8. Pachaury DR, ARYA DR, Mahawar NL, Bharti A, Das PK. Frequency of Rh Phenotypes in Voluntary Blood Donors. *JMSCR*. 2017 Jul 18. Available from: <http://jmscr.igmpublication.org/v5-i7/129%20jmscr.pdf>. [Last accessed on 2021 Mar 06].
9. Kahar MA, Patel RD. Phenotype frequencies of blood group systems (Rh, Kell, Kidd, Duffy, MNS, P, Lewis, and Lutheran) in blood donors of south Gujarat, India. *Asian J Transfus Sci* 2014;8:51-5.
10. Franchini M, Marano G, Veropalumbo E, Masiello F, Pati I, Candura F, *et al.* Patient blood management: A revolutionary approach to transfusion medicine. *Blood Transfus* 2019;17:191-5.
11. Gooptu S, Ali I, Bawa AS, Singh G, Kumar A, Kumar H. Predeposit autologous blood transfusion: Do we require to promote it? *Med J DY Patil Univ* 2015;8:474.
12. Kaur R, Jain A. Rare blood donor program in the country: Right time to start. *Asian J Transfus Sci* 2012;6:1-2.