

Long-term hormonal therapy resulting in breast cancer in female-to-male transsexual

Case report

Inka Treskova, MD, PhD^{a,*}, Ondrej Hes, MD, PhD^b, Vlastimil Bursa, MD^a

Abstract

Rationale: Testosterone is important for the development of secondary sexual characteristics in female-to-male transsexuals. On the contrary, it can increase the risk of breast cancer.

Patient concerns: We present a rare case of breast cancer in female-to-male transsexual patient after long-term hormonal therapy.

Diagnosis: Breast cancer in female-to-male transsexual patient.

Interventions: The patient underwent mastectomy and chemotherapy.

Outcomes: The patient had local recurrence of the disease and he underwent re-excision, radiotherapy and the tamoxifen treatment. After this treatment, the patient is in the remission from the disease.

Lessons: Breast cancer in transsexuals appears to be rare. However, there is a potential risk that testosterone exposure can increase the risk of developing breast cancer by the stimulation of breast tissue. There is limited published literature on the risk of breast cancer in transsexual patients.

Abbreviation: FTM = female-to-male.

Keywords: breast, breast cancer, hormonal therapy, surgery, transsexuals

1. Introduction

Testosterone is the crucial hormone in female-to-male (FTM) transsexuals for the development of secondary sexual characteristics.^[1] Transsexual people receive cross-sex hormones as part of their treatment, the studies are limited which means the risk of breast cancer development is unclear; some studies suggest that high levels of circulating androgens increase the risk of developing breast cancer, whereas others do not.^[2,3] We present a rare case of breast cancer in FTM transsexual patient after long-term hormonal therapy.

2. Case report

A 58-year-old FTM transsexual began the treatment with testosterone 25 years ago. He did not undergo bilateral mastectomy because of very small breasts. He only underwent

hysterectomy in the past. In 2013, he finally decided to undergo mastectomy and came to our department. He had mammography preoperative that showed mammary gland involution with the residuum in the upper outer quadrants and microcalcification 23 × 6 mm in the left breast as well as some kind of formation in the left upper outer quadrant 6 mm in diameter. The correlation with ultrasonography was recommended. The ultrasonography revealed also the residuum of breast gland bilateral. In the left breast, there was described an irregular structure and few fibroadenomas with maximal diameter 7 mm.

Biopsy was considered but because the patient decided to undergo bilateral mastectomy (exactly the subcutaneous mastectomy), this approach was chosen. He underwent bilateral subcutaneous mastectomy and the histopathologic examination of the specimen revealed invasive ductal carcinoma, estrogen receptors 100% positive, progesterone receptors negative, proliferative activity 30%, HER2/neu negative (Fig. 1). The tumor was classified as pT1b. According to oncologist, the total mastectomy was then performed in the left side with axillary lymph node dissection. The patient received chemotherapy (cyclophosphamid, doxorubicin), and radiotherapy was not indicated. In the follow-up in the beginning of 2015, he had local recurrence of the disease and he underwent re-excision, radiotherapy, and the tamoxifen treatment. Since that time, the patient is in the remission from the disease.

The ethical approval is not necessary because we present no study. The informed consent of the patient is not given because there is no study involved and the patient cannot be recognized.

3. Discussion

Transsexual people receive cross-sex hormones as part of their treatment, the studies are limited which means the risk of breast

Editor: N/A.

The authors have no funding and conflicts of interest to disclose.

^a Department of Plastic Surgery, ^b Department of Pathology, University Hospital in Plzen, Charles University in Prague, Alej Svobody, Plzen, Czech Republic.

* Correspondence: Inka Treskova, Department of Plastic Surgery, University Hospital in Plzen, Charles University in Prague, Alej Svobody 80, 323 00 Plzen, Czech Republic (e-mail: treskova@fnplzen.cz).

Copyright © 2018 the Author(s). Published by Wolters Kluwer Health, Inc. This is an open access article distributed under the terms of the Creative Commons Attribution-Non Commercial License 4.0 (CCBY-NC), where it is permissible to download, share, remix, transform, and buildup the work provided it is properly cited. The work cannot be used commercially without permission from the journal.

Medicine (2018) 97:52(e13653)

Received: 9 May 2018 / Accepted: 14 November 2018

<http://dx.doi.org/10.1097/MD.0000000000013653>

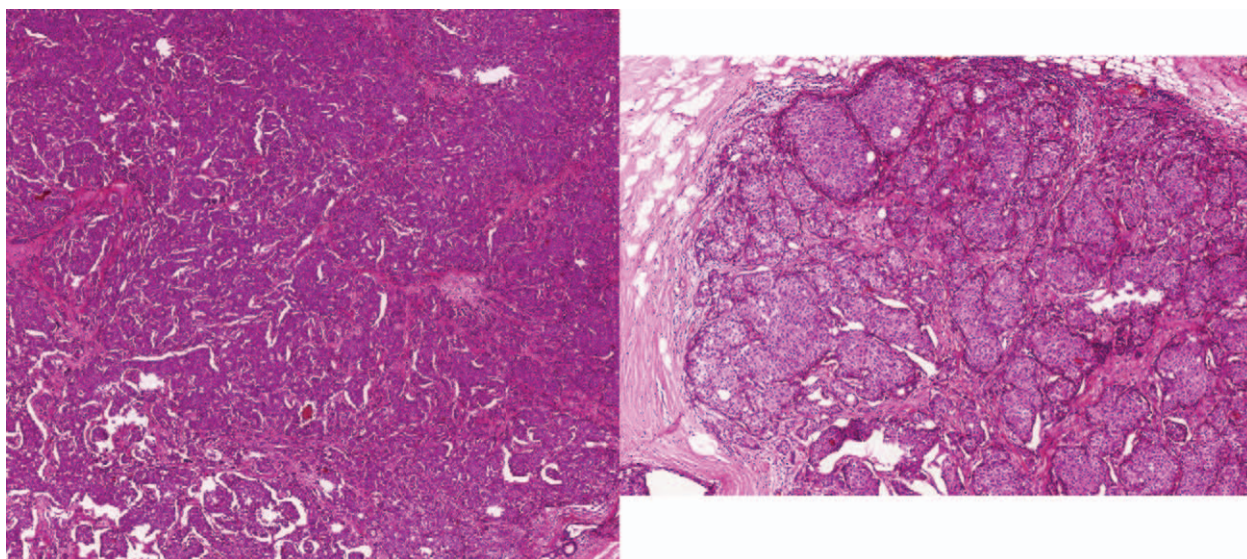


Figure 1. Invasive ductal carcinoma with strong lobular characteristics (hematoxylin and eosin, $\times 200$).

cancer development is unclear, some studies suggest that high levels of circulating androgens increase the risk of developing breast cancer, whereas others do not.^[2,3] FTM transsexuals generally receive androgen therapy and breast (gland) reducing surgery is performed. The question is the extent of prophylactic surgery, whether to perform prophylactic mastectomy or just breast reducing surgery and also the screening programs for these patients. In our case, the mastectomy was not performed because of personal will of the patient and systemic testosterone led to the reduction of breast size mediated by connective tissue shrinking and local fibrosis.^[4,5] Breast cancer in FTM is a rarity. Exogenously supplied testosterone stimulates the activity of hormone receptors in breast tissue.^[3] The age and duration of testosterone exposure are risk factors in the breast cancer development.^[6] The role of testosterone on breast tissue is not clear. The possible mechanism is that testosterone is aromatized into estrogens and higher circulating levels of testosterone may increase estrogen generation in mammary gland. Another mechanism can be the direct activation of androgen receptors.^[1,7] The therapeutic strategy of our case was based on surgery and adjuvant treatment similar to the treatment of female breast cancer; administration of estrogen receptor modulators was recommended.

4. Conclusion

Breast cancer in transsexuals appears to be rare. However, it is likely that there is underreporting of long-term complications of cross-sex hormones use.^[8] It is very important to report these cases to assess if the long-term administration of androgens is safe. As the past few decades have seen a better acceptance of transsexualism, there is the need for understanding of the particular health care needs for these patients.^[9]

Informed consent was obtained from the patient for publication of this case report and accompanying images. Institutional review board approved this article for publication.

Author contributions

Data curation: Ondrej Hes.

Supervision: Vlastimil Bursa.

Writing – original draft: Inka Treskova.

References

- [1] Shao T, Grossbard ML, Klein P. Breast cancer in female-to-male transsexuals: two cases with a review of physiology and management. *Clin Breast Cancer* 2011;11:417–9.
- [2] Gooren LJ, van Trotsenburg MA, Giltay EJ, et al. Breast cancer development in transsexual subjects receiving cross-sex hormone treatment. *J Sex Med* 2013;10:3129–34.
- [3] Katayama Y, Motoki T, Watanabe S, et al. A very rare case of breast cancer in a female-to-male transsexual. *Breast Cancer* 2016;23:939–44.
- [4] Slagter MH, Scorilas A, Gooren LJ, et al. Effect of testosterone administration on serum and urine kallikrein concentrations in female-to-male transsexuals. *Clin Chem* 2006;52:1546–51.
- [5] Burgess HE, Shousha S. An immunohistochemical study of the long-term effects of androgen administration on female-to-male transsexual breast: a comparison with normal female breast and male breast showing gynaecomastia. *J Pathol* 1993;170:37–43.
- [6] Gooren L, Bowers M, Lips P, et al. Five new cases of breast cancer in transsexual persons. *Andrologia* 2015;47:1202–5.
- [7] Brown GR, Jones KT. Incidence of breast cancer in a cohort of 5,135 transgender veterans. *Breast Cancer Res Treat* 2015;149:191–8.
- [8] Pattison ST, McLaren BR. Triple negative breast cancer in a male-to-female transsexual. *Intern Med J* 2013;43:203–5.
- [9] Corman V, Potorac I, Manto F, et al. Breast cancer in a male-to-female transsexual patient with a BRCA2 mutation. *Endocr Relat Cancer* 2016;23:391–7.