



En bloc excision of giant polycystic liver with hepatic cava and its auto-transplant caval reconstruction as a safe surgical procedure for liver transplantation

Koichiro Hata¹  | Takahiro Nishio¹ | Shoichi Kageyama¹ | Satoshi Ogiso¹  | Ken Fukumitsu¹ | Motoyuki Kumagai² | Hideo Kanemitsu² | Kazuhiro Yamazaki² | Kenji Minatoya² | Etsuro Hatano¹

¹Division of Hepato-Biliary-Pancreatic Surgery and Transplantation, Department of Surgery, Graduate School of Medicine, Kyoto University, Kyoto, Japan

²Department of Cardiovascular Surgery, Graduate School of Medicine, Kyoto University, Kyoto, Japan

Correspondence

Koichiro Hata, Division of Hepato-Biliary-Pancreatic Surgery and Transplantation, Department of Surgery, Graduate School of Medicine, Kyoto University, Kawahara-cho 54, Shogoin, Sakyo-ku, Kyoto city, Kyoto 606-8507, Japan.

Email: khata@kuhp.kyoto-u.ac.jp

Funding information This work was supported by the Medical Research and Development Programs Focused on Technology Transfer, Development of Advanced Measurement, and Analysis Systems (SENTAN) from the Japan Agency for Medical Research and Development, AMED (No. 21hm0102063h0004).

Keywords: autosomal dominant polycystic kidney disease (ADPKD), liver transplantation, polycystic liver, veno-venous bypass

1 | INTRODUCTION

A multiparous woman¹ in her mid-50s underwent liver transplantation (LTx) for a giant polycystic liver due to autosomal dominant polycystic liver/kidney disease. Due to a lack of potential living donors in her family, extremely scarce deceased donors in Japan, and characteristically preserved liver/kidney functions, she had waited for 12 years for a liver allocation, although her daily life had long been disrupted.

Before surgery, enormous hepatomegaly caused inferior vena cava (IVC) syndrome in the supine position, requiring a femoro-jugular veno-venous (VV) bypass (Figure 1A) that was initially prepared for combined excision of the giant liver with hepatic IVC. Total hepatectomy was extremely difficult due to little surgical space by the largest polycystic liver than ever reported² (24 kg, Figure 1A–E).

In cases with giant livers, it is difficult to safely excise the liver alone while leaving hepatic IVC intact, which sometimes causes IVC laceration and major bleeding.^{3,4} Split hepatectomies are sometimes useful^{3,4} but this procedure is difficult for extremely enlarged livers containing numerous infected cysts. Our current strategy is, therefore, to perform total hepatectomy including hepatic cava with VV-bypass assistance; easily and safely divide hepatic cava by reversing the dorsoventral side of the liver extracorporeally; and auto-transplant/re-anastomose the retrieved IVC to interpose the gap not reached by the liver-graft IVC under wide surgical view/field (Figure 2 and Video S1).

The patient was discharged just over a month after surgery without any surgical complications and is now enjoying an active life that she had lost for 20 years. In this hereditary, refractory, but not uncommon disease, the larger and heavier the liver, the more difficult the surgery, the higher the intraoperative risks,^{3,4} and the worse the

This is an open access article under the terms of the [Creative Commons Attribution-NonCommercial-NoDerivs](https://creativecommons.org/licenses/by-nc-nd/4.0/) License, which permits use and distribution in any medium, provided the original work is properly cited, the use is non-commercial and no modifications or adaptations are made.

© 2022 The Authors. *Journal of Hepato-Biliary-Pancreatic Sciences* published by John Wiley & Sons Australia, Ltd on behalf of Japanese Society of Hepato-Biliary-Pancreatic Surgery.

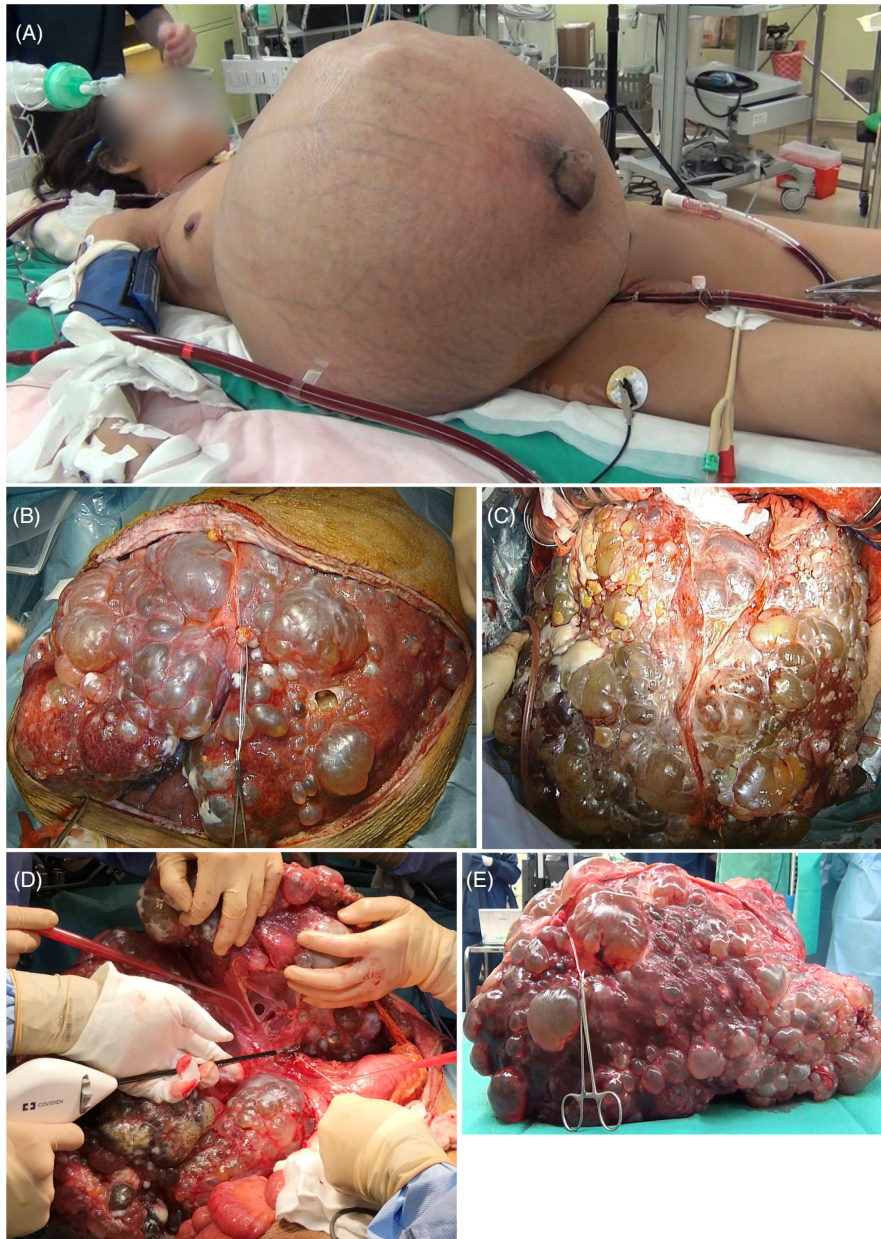

FIGURE 1 Macroscopic appearance of the patient's abdomen and the extremely enlarged polycystic liver. A. A photograph showing the patient on the operation table. Note that multiple cysts can be seen through her extremely distended abdomen, and that a femoro-jugular veno-venous bypass (VV-bypass) was required due to inferior vena cava (IVC) syndrome in the supine position caused by extremely heavy polycystic liver. B and C. Intra-operative view of the giant polycystic liver. D. Since multiple large cysts covered over the hepatic hilum, they were opened, aspirated, and resected to obtain surgical space for hilar preparation. E. Excised huge polycystic liver on a back table. The liver had overgrown enormously (24 kg) to about one-third of her body weight (77 kg with a height of 151 cm), which severely interfered with the patient's daily activities, let alone eating, and she became incontinent on a daily basis. Given the ascites volume of 9 liter (L) aspirated on laparotomy, the liver was equivalent to more than 35% of her preoperative net body weight. For reference, the patient weighs 41 kg at 2.5 months after discharge (lost 36 kg), and is able to ride a bicycle, drive a car, and go shopping. Operative time: 15 hours 58 minutes; blood loss: 28600 g including ascites (approx. 10 L in total) and cyst fluid (approx. 5 L in total); extracorporeal circulation time: 9 hours 43 minutes, which started 47 minutes before the start of the operation

patient's quality of life that extends over decades.¹⁻⁵ Not only intraoperative bleeding but also long-lasting malnutrition and resultant sarcopenia/frailty further deteriorate

patient prognosis.²⁻⁵ LTx should be considered before it's too late, for which this technique would facilitate safer LTx.

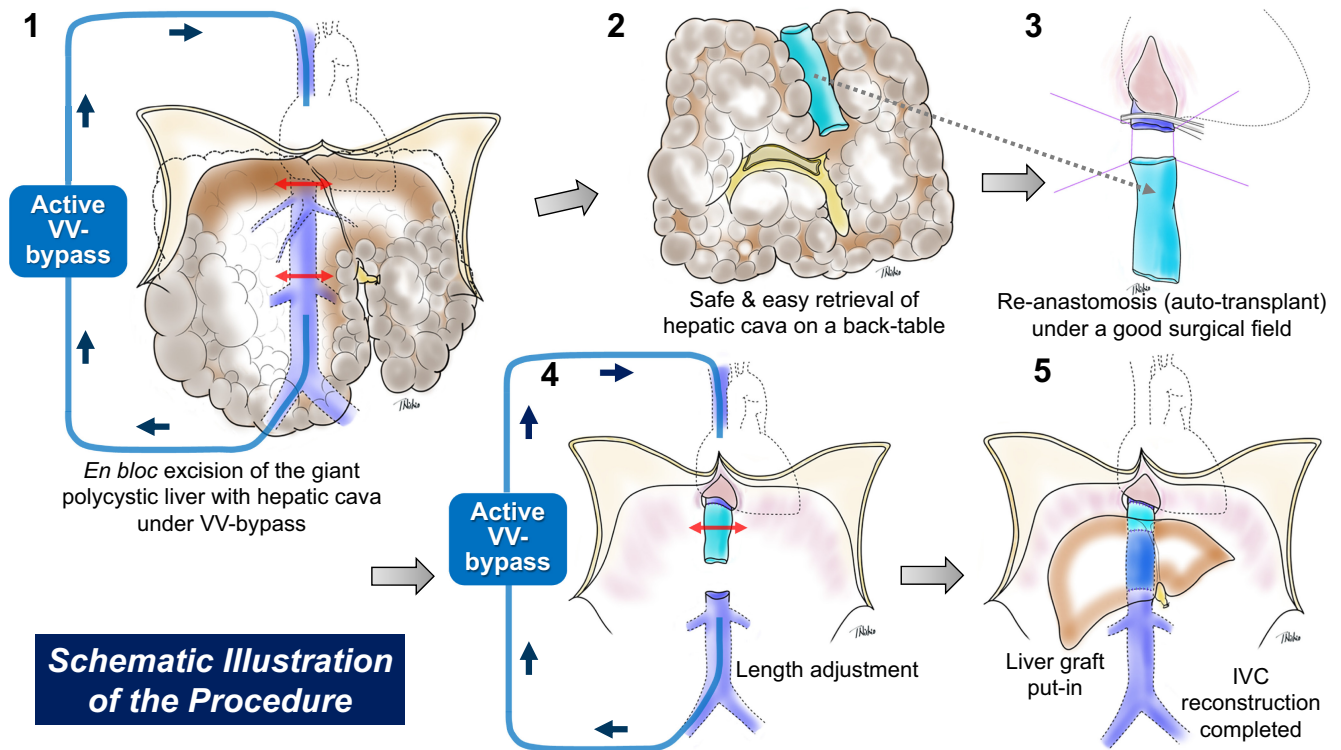


FIGURE 2 Schematic illustration of the surgical procedures. This technique is indicated for cases where it is difficult to safely excise the liver alone while leaving hepatic IVC intact, e.g. substantially enlarged livers such as ADP(L)KD. (1) En bloc excision of the giant liver with hepatic cava under VV-bypass assistance; (2) Hepatic cava is safely and easily retrieved from the excised liver by reversing the dorsoventral side of the liver on a back table; (3) Re-anastomosis of the harvested autologous hepatic cava with the IVC stump (auto-transplant) in a good surgical field where the giant liver is no longer present (Video S2); (4) In deceased-donor whole liver transplants, the length of the re-anastomosed auto-IVC is adjusted to interpose the gap not reached by the liver-graft IVC, while in living-donor partial liver transplants, it should be reconstructed to fill the whole gap of IVC; and (5) A liver graft is put in, and IVC reconstruction is completed. This procedure intrinsically reduces the risk of intraoperative IVC laceration, hepatic vein rupture/tearing, and subsequent massive bleeding. This technique and its variations are very useful for various pathological conditions, in which the liver cannot be safely divided from hepatic cava in situ in both living- and deceased-donor liver transplantation. Abbreviations: IVC, inferior vena cava; ADP(L)KD, autosomal dominant polycystic (liver) kidney disease; VV-bypass, veno-venous bypass

ACKNOWLEDGMENT

None.

CONFLICT OF INTEREST

The authors have no conflicts of interest to disclose.

AUTHOR CONTRIBUTIONS

K.H. performed the surgery, wrote the manuscript, and managed the patient in an outpatient setting. T.N., S.K., S.O., K.F., M.K., H.K., and K.Y. joined the surgery, managed the patient, and prepared the clinical details of the case including the video and images. K.M. and E.H. supervised the surgery and edited the manuscript. All authors reviewed the manuscript prior to submission.

ETHICAL STATEMENTS

All procedures performed in this study were in accordance with the Declaration of Helsinki and were approved

by the Ethics Committee of Kyoto University (No. 1571). Written informed consent was obtained from the patient for publication.

ORCID

Koichiro Hata  <https://orcid.org/0000-0002-3609-6396>

Satoshi Ogiso  <https://orcid.org/0000-0002-9577-330X>

REFERENCES

1. Gevers TJ, Drenth JP. Diagnosis and management of polycystic liver disease. *Nat Rev Gastroenterol Hepatol*. 2013;10(2):101–8. <https://doi.org/10.1038/nrgastro.2012.254>.
2. Acar S, Gencdal G, Tokac M, Eren E, Alkara U, Tellioglu G, et al. Liver transplantation for polycystic liver disease due to huge liver with related complications: a case report. *Transplant Proc*. 2017;49(3):603–5. <https://doi.org/10.1016/j.transproceed.2017.01.033>.
3. Thieme F, Fronck J. Sharp liver excision under hepatic vascular exclusion in case of liver transplant for large

- polycystic disease. Case report of a new surgical technique. *Int J Surg Case Rep.* 2018;44:143–7. <https://doi.org/10.1016/j.ijscr.2018.01.001>.
4. Le Roy B, Cauchy F, Sepulveda A, Yoh T, Dokmak S, Weiss E, et al. Modified technique of Total hepatectomy in polycystic liver disease with Caval flow preservation: the exposure left lateral Sectionectomy. *Transplantation.* 2019;103(7):1414–7. <https://doi.org/10.1097/TP.0000000000002538>.
 5. Takakusagi S, Masuda Y, Takagi H, Yokoyama Y, Kizawa K, Marubashi K, et al. A case of massive polycystic liver with a poor performance status successfully treated by ABO-incompatible adult living-donor liver transplantation while overcoming complications. *Intern Med.* 2019;61(6):841–9. <https://doi.org/10.2169/internalmedicine.8290-21>.

SUPPORTING INFORMATION

Additional supporting information may be found in the online version of the article at the publisher's website.

How to cite this article: Hata K, Nishio T, Kageyama S, Ogiso S, Fukumitsu K, Kumagai M, et al. *En bloc* excision of giant polycystic liver with hepatic cava and its auto-transplant caval reconstruction as a safe surgical procedure for liver transplantation. *J Hepatobiliary Pancreat Sci.* 2022;29:e104–e107. <https://doi.org/10.1002/jhbp.1138>