

Evidence that nerve surgery improves functional outcome for obstetric brachial plexus injury

Willem Pondaag and Martijn J. A. Malessy

Journal of Hand Surgery
(European Volume)
2021, Vol. 46(3) 229–236
© The Author(s) 2020



Article reuse guidelines:
sagepub.com/journals-permissions
DOI: 10.1177/1753193420934676
journals.sagepub.com/home/jhs



Abstract

The majority of children with obstetric brachial plexus injury show some degree of spontaneous recovery. This review explores the available evidence for the use surgical brachial plexus repair to improve outcome. So far, no randomized trial has been performed to evaluate the usefulness of nerve repair. The evidence level of studies comparing surgical treatment with non-surgical treatment is Level IV at best. The studies on natural history that are used for comparison with surgical series are also, unfortunately, of too low quality. Among experts, however, the general agreement is that nerve reconstruction is indicated when spontaneous recovery is absent or severely delayed at specific time points. A major obstacle in comparing or pooling obstetric brachial plexus injury patient series, either surgical or non-surgical, is the use of many different outcome measures. A requirement for multicentre studies is consensus on how to assess and report outcome, both concerning motor performance and functional evaluation.

Keywords

Brachial plexus surgery, Erb's palsy, brachial plexus birth injury, paralysis, obstetric

Date received: 9th September 2019; revised: 15th May 2020; accepted: 25th May 2020

Introduction

Around 20–30% of infants with obstetric brachial plexus injury (OBPI) do not show complete spontaneous recovery (Annika et al., 2019; Lagerkvist et al., 2010; Pondaag et al., 2004). Depending on the extent of the neurological deficit 2 weeks after birth, four different lesion groups were described by Narakas: Group 1: C5–C6; Group 2: C5–C6–C7; Group 3: C5–T1 without Horner syndrome; and Group 4: C5–T1 with Horner syndrome (Narakas, 1987). An increasing extent of the nerve lesion, namely a higher Narakas group, correlates negatively with the amount of spontaneous recovery (Al-Qattan et al., 2009). It is widely accepted that if elbow flexion occurs after 2 months of age then recovery will be incomplete, with outcome progressively worsening with later biceps recovery (Gilbert and Tassin, 1984; Lagerkvist et al., 2010; Smith et al., 2004; Strömbeck et al., 2000; Waters, 1999).

In cases of incomplete recovery the shoulder is always impaired, with poorer function in more extensive lesions and with later biceps recovery (Lagerkvist et al., 2010; Smith et al., 2004; Waters, 1999).

It is rare for active elbow flexion not to recover spontaneously (Bisinella and Birch, 2003; Chin et al., 2013; Hems et al., 2017). In Narakas Group 3 and 4 cases, wrist and finger extension may fail to recover. Finger flexion is only rarely completely deficient in some Narakas Group 4 cases, but functional grip is usually absent. Longer term deformities include flexion contracture of the elbow and limitation of forearm rotation.

The prognosis for useful hand function recovery in infants with a Group 4 lesion is poor (Al-Qattan et al., 2009; DiTaranto et al., 2004; Narakas, 1987; Sever, 1916). It is generally agreed that the indication for nerve surgery in these children is strong. In children with a Narakas Group 1–3 lesion type the indication for surgical intervention is less clear, but is often

Department of Neurosurgery, Leiden University Medical Center, Leiden, The Netherlands

Corresponding Author:

Willem Pondaag, Department of Neurosurgery (J-11), Leiden University Medical Center, PO Box 9600, 2300 RC Leiden, The Netherlands.

Email: w.pondaag@lumc.nl

considered when spontaneous recovery does not occur or is limited at the age of 3–6 months. There is no consensus among surgeons regarding the selection criteria and timing of surgery, although neurotmetic lesions and root avulsions precluding useful regeneration have been identified during OBPI surgery (Boome and Kaye, 1988; Boyer, 1912; Gilbert and Tassin, 1984). Nerve reconstruction is performed in these instances aiming at a significant improvement of function as compared with what would have recurred spontaneously.

So far, a strong scientific validation of the value of nerve reconstructive surgery, such as might be provided by a randomized trial, is lacking (Malessy et al., 2009). To address the issue, two different approaches can be used: (1) the results of nerve reconstruction can be compared directly with those of non-surgical treatment in the same series and (2) the results of non-surgical series from the literature can be used for comparison with series describing results after nerve reconstruction.

In order to outline the current way of thinking regarding nerve surgery for OBPI, we updated our previous analyses of the literature (Pondaag and Malessy, 2014; Pondaag et al., 2004) and reflect on the difficulties encountered with the comparisons published so far.

Results

Comparing results of nerve reconstruction with those of non-surgical treatment

In 2013, we performed a systematic review of patient series in which the results of nerve reconstruction were compared with non-surgical treatment in the same paper (Pondaag and Malessy, 2014). We identified nine studies that met these inclusion criteria (Al-Qattan, 2000; Badr et al., 2009; Boome and Kaye, 1988; Capek et al., 1998; Gilbert and Tassin, 1984; Lin et al., 2009; Strömbeck et al., 2000; Waters, 1999; Xu et al., 2000). We updated the search until July 2019 using the same bibliographic search strategy (Pondaag and Malessy, 2014), which resulted in one additional paper (Chantaraseno et al., 2014) (Table 1). It is striking that the scientific methodologies in these papers differ greatly. All studies are either observational case series, historically controlled or poor-quality cohort studies and thus provide only Level IV evidence. We will discuss the most frequently cited studies in more detail below and focus on how these children were selected, what was actually investigated, and what conclusions were drawn from the data by the authors.

The first comparison performed by Gilbert and Tassin (1984) was between a conservatively treated cohort ($n=44$) from Hôpital Saint Vincent and a surgically treated cohort ($n=38$) from Hôpital Trousseau, in Paris, France. In a subgroup analysis of C5-C6 lesions, 22 surgically treated and 18 conservatively treated patients were compared. In the surgical group, 14/22 patients (63%) reached a Mallet IV shoulder, while recovery in the conservatively treated group occurred to a maximum of Grade III (Mallet, 1972). In the non-surgical group, recovery was incomplete if biceps recovered after age 3 months. This observation led to the conclusion that surgical treatment is indicated if the biceps muscle has not recovered at the age of 3 months.

Clarke et al. (1996) performed a stepwise analysis of the patients of the Toronto Hospital for Sick Children, looking at natural history (Michelow et al., 1994), benefits of neurolysis (Clarke et al., 1996), and outcome of graft repair of conducting neuromas in 26 children (Capek et al., 1998). In 2009, results from a larger patient series with a longer follow-up (>4 years) led the authors to conclude that the eventual recovery after graft repair was better than after neurolysis (Lin et al., 2009). Recovery to Active Movement Scale (AMS) Grade 6 or 7 was statistically more robust in the surgical repair group than in the neurolysis group for shoulder abduction and external rotation, elbow flexion, supination and wrist/thumb extension. The interpretation of the findings of this study is hampered by the fact that a comparison was made between preoperative and postoperative AMS grading within the neurolysis and grafting group. A direct comparison between the end result of neurolysis and grafting was not provided.

Waters (1999) described 39 children who were evaluated before the age of 6 months. In six patients nerve surgery was performed because there was no recovery of the biceps muscle at the age of 6 months. The conservatively treated children were divided into five groups, depending on the month in which the biceps muscle recovered. Four of the five movements of the Mallet score for shoulder function were analysed separately: (1) abduction; (2) external rotation; (3) ability to bring the hand to the mouth; and (4) to the neck. It was concluded that these shoulder functions were better in the group that received nerve surgery at 6 months of age, as compared with non-surgically treated infants in whom the biceps recovered at 5 months. Unfortunately, the statistical method used for comparison of groups was not mentioned. We constructed figures from the patient data in the original paper, to illustrate the authors' findings and to make the results easier to understand (Figure 1). The authors concluded that when recovery

Table 1. Summary of papers included.

Paper	Population	Cons (n)	NR (n)	Selection criteria	Follow-up	Evaluation	Remarks
Gilbert and Tassin (1984)	Comparison of patients referred to two different hospitals with different treatment	44	38	Biceps force at 3 mo	2 y	Mallet score	First paper published, describes the 3-month biceps rule; no elaborate statistics; improved outcome for shoulder for C5-6 lesions after NR
Boome and Kaye (1988)	Patients selected and not selected for surgery	42 Cons + 2 neurolysis	18	Biceps and deltoid force	18 mo (1 mo-5 y)	MRC	Good spontaneous recovery if biceps recovers <3mo. No statistics
Capek et al. (1998)	Patients with nerve reconstruction compared with own historical cohort of neurolysis	16 neurolysis	26	AMS composite score	12 mo	AMS	Neuroma resection did not result in decrease of function after 3 months
Lin et al. (2009)	Same as above	16 neurolysis	92	AMS composite score	Min 4 y	AMS	Neurolysis did not improve postoperative function compared with preoperative, but NR did. No direct comparison of neurolysis versus NR
Waters (1999)	Patients selected and not selected for surgery	33	6	Biceps force at 6 mo	2-11 y	Mallet score	Increasing delay of biceps recovery results in poorer function. NR was superior to late recovery for shoulder function
Al-Qattan (2000)	Patients selected and not selected for surgery	30	3	Biceps force at 4 mo	Min 18 mo	AMS	Adequate recovery when biceps recovers at 3 months, but not when biceps recovers later than 4 months
Xu et al. (2000)	Late referrals treated conservatively vs neurolysis vs reconstruction	12 non op + 9 neurolysis	10	Biceps force at 3 mo	40-54 mo	Mallet score	Cons (including neurolysis) led to poorer results than NR
Strömbeck et al. (2000)	Patients selected and not selected for surgery excluding early recovery	53	59	Inconsistent	Min 5 y	Own scoring system	Early recovery (3 mo) has the best outcome; better shoulder function after NR in C5-6 compared with late recovery (6 mo)

(continued)

Table 1. Continued.

Paper	Population	Cons (n)	NR (n)	Selection criteria	Follow-up	Evaluation	Remarks
Badr et al. (2009)	Patients selected and not selected for surgery	155	16	No biceps or shoulder function at 7–10 mo	24 mo	Own scoring system	Only 50% of Cons patients had a good outcome. Descriptive study without analysis
Chantaraseno et al., 2014	Patients selected and not selected for surgery	59	22	No functional elbow flexion <9 mo	Mean 2.5y (1 mo–4y)	AMS	Descriptive study without own statistical analysis
El-Sayed (2017)	Conservative: parents refused nerve surgery versus equal number of randomly selected from surgical cohort (n = 107)	9	9	Biceps force at 4 mo	2y	Degrees of shoulder abduction, MRC for elbow flexion.	Children whose parents refused surgery had poorer outcome than NR

Cons: conservative treatment; NR: nerve reconstruction; mo: month(s); y: year(s); min: minimum; MRC: Medical Research Council; AMS: active movement scale.

was delayed to 4 or 6 months, the end-stage recovery was incomplete. Nerve surgery after 6 months yielded superior results for the shoulder in children in whom biceps recovery was delayed until the sixth month.

Strömbeck et al. (2000) described infants referred to a national OBPI clinic in Stockholm, Sweden. From a cohort of 470 children, only those with a follow-up of more than 5 years were selected, which left 247 children for analysis (only about half of their cohort). Seven years later a follow-up study was published (Strömbeck et al., 2007). Movements in these 247 children were assessed using a locally designed scoring system resulting in a sum score, which is difficult to interpret. In addition, the tactile sensibility, grip, bimanual activity and hand preference were scored and the pick-up and grip-tests were performed. The children who 'exhibited some muscle activity in their biceps or deltoid muscles at the first visit at 3 months of age' were considered as early recovery. Outcome after early recovery was compared with late recovery, and to recovery after nerve reconstruction. In the C5-C6 group, children who were surgically treated had better shoulder function than the non-surgically treated children with a delayed recovery, but not better elbow flexion. In children with a C5-C7 lesion, there was no difference in shoulder or elbow recovery between the late recovery and operated group. Both groups had worse function than the early recovery group. The major limitation in this paper was the inconsistent selection criterion for surgery (or cross-over in the treatment groups), which makes extrapolation to a generalizable rule for the indications for nerve reconstruction impossible.

Our search strategy did not identify one relevant paper, which has come to our attention (El-Sayed, 2017). The outcome of two patient groups with an upper plexus (C5-C6) lesions without biceps recovery at 4 months of age were compared. In one group surgery was proposed, but refused by the parents (n = 9). As a consequence, these patients were treated non-surgically. The other group consisted of nine patients who were randomly selected from the authors cohort of surgically treated children (n = 109). The authors concluded that nerve reconstruction provided superior results compared with conservative management. We feel, however, that the base for this conclusion is insufficient in view of the small numbers and lack of proof that both groups were really comparable in the absence of MRI diagnostics and surgical findings. In the non-surgical group, the authors reported that there was no useful recovery of elbow flexion in any patients, which is substantially different from other studies

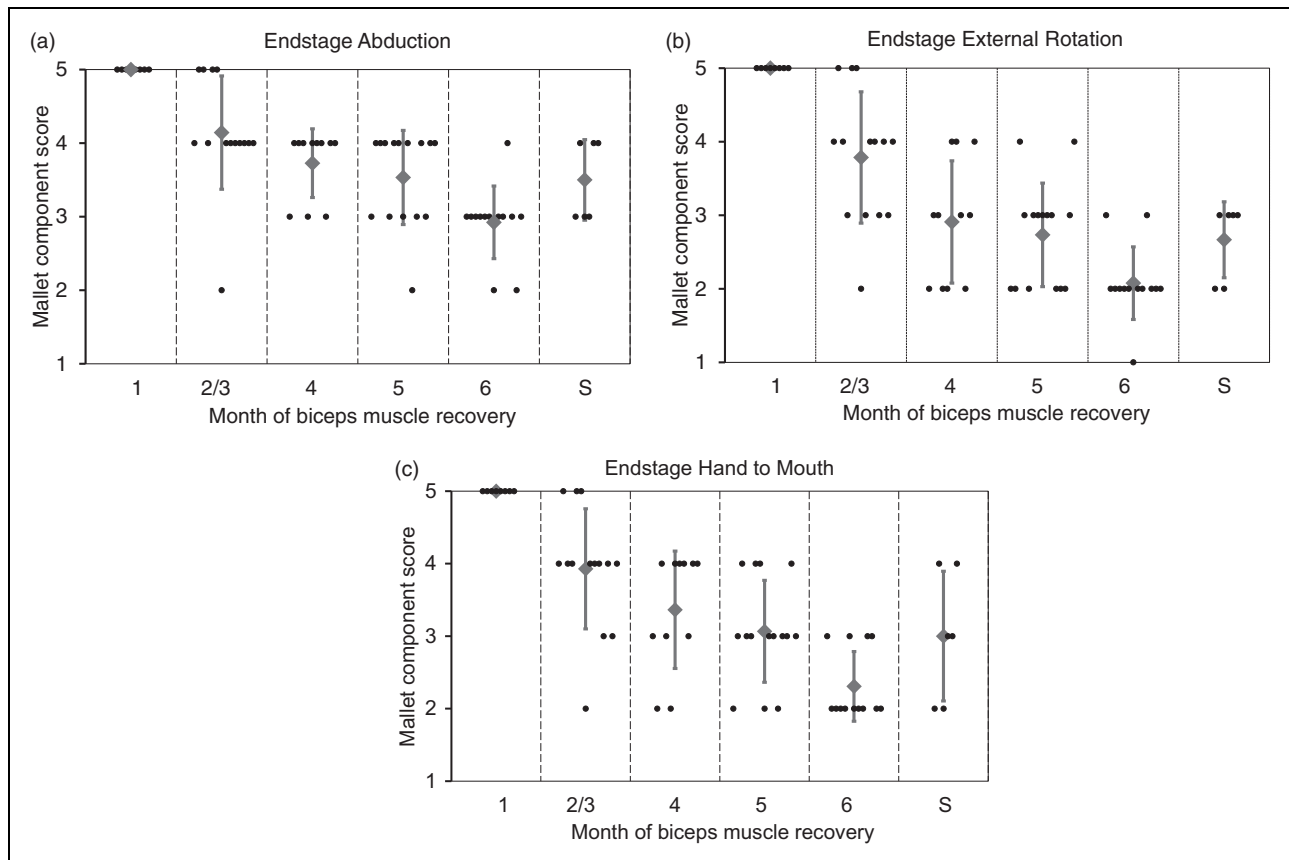


Figure 1. End stage of three components of the Mallet score related to timing of first biceps muscle recovery or after nerve surgery (Waters, 1999). (a) Abduction, (b) external rotation, (c) hand to mouth.

X-axis: composition of Groups 1 to 6 represents the month of first biceps recovery, compared with the surgical group (S); small dots represent a patient, large dots the mean score, with error bars of 1 standard deviation; graph reconstructed from published individual patient data.

of the natural history for spontaneous recovery after C5-C6 OBPI.

Comparing outcome of non-surgical series from the literature with those following nerve reconstruction

Another option to investigate the benefits of nerve reconstruction is to compare the outcome in surgical series with the outcome of spontaneous recovery in other series. The main difficulty in this comparison is that there are few natural history series for OBPI that assess and report outcome in a qualitatively good manner. We systematically reviewed the quality of natural history series by applying four quality criteria to 76 papers: prospective study design (not retrospective), population-based series (not selected populations from specific clinics or hospitals), proper follow-up and a well-defined system of outcome. None of the publications met three or four quality criteria (Pondaag et al., 2004). Only seven papers met two quality criteria.

Since 2004, two papers have appeared that described the outcome of a prospective, population-based cohort using a well-documented outcome after sufficient and complete follow-up. Both series originate in Sweden, and have a follow-up of 18 months (Lagerkvist et al., 2010) and 10–12 years (Annika et al., 2019). In these series, however, a small number of children were included who had been surgically treated, thereby confounding the natural history data. The proportion of children with residual impairment was around 20%.

Natural history descriptions could ideally be used as a standard to which results of surgical series could be compared. One approach is to identify those children who were eligible for nerve repair, but were treated non-surgically, and use these non-surgical results as a reference point to surgical outcome. Smith et al. (2004) reported long-term outcome in 28 children who had absent biceps function at 3 months of age (Gilbert's rule of thumb), 22 of whom did not have nerve repair. All except one with a C5-T1 lesion regained elbow flexion. Although

some of these children had good shoulder outcome, many had deficits in shoulder function and had undergone secondary operations.

A difficulty with comparing natural history and surgical series is that the latter harbour referral and inclusion bias. As OBPI is a rare disease, the number of patients in surgical series is generally small and studies may be insufficiently powered.

Surgical series differ in selection criteria, surgical technique and outcome assessment, which hampers summarizing the results. Regardless, it is our experience for shoulder function ($n=86$) that true glenohumeral external rotation does not recover after surgery in 40% of children, and only 20% of children can externally rotate beyond 20° (Pondaag et al., 2005). This roughly corresponds with the findings of Clarke's group ($n=177$) (Tse et al., 2011). 'Good' shoulder function was achieved in 33% of children in Birch's series (Birch et al., 2005). Poor recovery of elbow flexion after nerve surgery was occasionally seen in large groups: 5% of 51 children (Terzis and Kokkalis, 2009), 8% of 86 children (Pondaag et al., 2005) and 18% of 100 children (Birch et al., 2005). The main goal of surgery in the most severe lesions, namely useful hand function, was, depending on definition, achieved in 93% (Birch et al., 2005), 75% (Haerle and Gilbert, 2004), 69% (Pondaag and Malessy, 2006), 57% (Maillet and Romana, 2009) and 48% (Kirjavainen et al., 2008).

Discussion

The benefits of nerve repair in OBPI have not been investigated in a randomized fashion, thus the highest level of evidence cannot be reached. To date, the evidence that supports the value of surgical treatment is of low methodological quality. It would, however, be erroneous to conclude that there is no place for surgical treatment: 'Absence of evidence is not evidence of absence'.

Since the neurological prognosis without treatment is poor in cases of root avulsions and neurotmesis, brachial plexus surgery to improve outcome is justified, provided that it indeed does so. After nerve surgery recovery of shoulder function, elbow flexion and hand function has been obtained (Birch et al., 2005; Haerle and Gilbert, 2004; Lin et al., 2009; Pondaag and Malessy, 2006). For most physicians treating infants with OBPI, a severe lesion (Narakas Groups 3 and 4) with diminished hand function without speedy recovery is a strong indication for nerve reconstruction. This subgroup of patients, however, is only about 15% of patients in hospital-based series.

The most difficult decision making is in Narakas Group 1 and 2 injuries (C5-C6 or C5-C6-C7 lesion) that persists for at least 3 months (Bain et al., 2009). The specific lesion encountered is a neuroma-in-continuity of the superior trunk in which impaired, disorganized axonal regeneration may take place (Chen et al., 2008; van Vliet et al., 2015). Unfortunately, related clinical recovery is variable and unpredictable. Published results of conservatively treated children in various cohorts have frequently not been investigated with imaging to detect the presence of avulsions. Without surgical exploration, the exact type and extent of nerve lesion is not known, making comparison difficult. Cases where exploration and neurolysis only had been carried out have been regarded as the non-repair control group in at least one study (Lin et al., 2009). However, it is not known whether neurolysis has an effect on nerve recovery either beneficial or harmful.

The exact time point to select patients with an upper type lesion for nerve reconstruction cannot be determined with certainty, but is probable somewhere between the third and sixth month (Smith et al., 2004; Waters, 1999). It is important to realize that the start of recovery of the biceps muscle is employed as a proxy for prognostication of the shoulder in upper trunk lesions and not per se a predictor for the end stage of recovery of the biceps muscle itself: 'The biceps rule is not about the biceps'. With increasing delay of initial recovery, the prospect of a good eventual outcome for the shoulder decreases. The available comparative series (Gilbert and Tassin, 1984; Lin et al., 2009; Strömbeck et al., 2000; Waters, 1999) provide some evidence that shoulder function can be improved by nerve repair.

Especially external rotation of the shoulder recovers poorly, both after conservative treatment as well as after nerve repair (Manske et al., 2019; Waters, 1999). In those infants with otherwise good spontaneous recovery of elbow flexion, it is suggested to improve external rotation by using an accessory to suprascapular nerve transfer in a late stage (van Ouwerkerk et al., 2006). In the recent years, there has been a tendency to perform nerve transfers instead of brachial plexus reconstruction by grafting (O'Grady et al., 2017). Strong advantages of this shift of approach have not been shown (Tse et al., 2015).

An alternative to early nerve repair for OBPI is to await the end stage of natural neurological recovery, and to treat residual deficits with muscle/tendon transfers, rotation osteotomy or joint fusion (Socolovsky et al., 2016).

One of the major obstacles for improvement of treatment of OBPI is that many different outcome

measures are used (Chang et al., 2013; Sarac et al., 2015), which disables comparison. Pooling of data to obtain statistical differences in larger series is therefore not possible. Recently, a first step was made to define an internationally accepted set of outcome measures (Pondaag and Malessy, 2018). The most commonly employed outcome measures used so far concern motor function of the shoulder and arm (Chang et al., 2013; Sarac et al., 2015). Only rarely, has the *functional* outcome, for example, performance of daily activities, been assessed between treatment groups, even though this intuitively seems the most valuable way to measure outcome. In addition, one has to keep in mind that in many OBPI children the affected hand is, or has become, non-dominant (Yang et al., 2005).

In order to be able to push the field forwards, it is imperative that a set of functional outcome measures is agreed upon to assess functional outcome of children with OBPI, as well as consensus on how to measure motor outcome of these children (Pondaag and Malessy, 2018; Squitieri et al., 2013). Such a set of outcome measures should be applied to cohorts of patients that have been treated with different strategies, which could be either conservative versus early nerve surgery, or focus on nerve surgery versus secondary surgery. At first, retrospective analysis of different strategies could be undertaken, as proper functional evaluation can only be performed at a certain age. Depending on the results of such an analysis of prior treatment strategies, patients should be prospectively treated according to the best strategy or treated in a randomized fashion if optimal treatment strategies are still uncertain in given situations.

The support for brachial plexus surgery in OBPI infants is based on low-quality observational studies of patient series in which surgical to conservative therapy are compared. None of the individual studies provides enough scientific proof that nerve reconstruction is superior to conservative treatment. Additionally, pooling of the results is not possible due to different methodology and outcome measurement.

Based on the literature and our own experiences, it is our opinion that for a well-selected group of patients' nerve surgery is beneficial. Our own clinical paradigm is to advise early surgical exploration in children with Narakas Group 3 and 4 lesions. These children are investigated with MRI to look for nerve root avulsions at the age of 2–3 months, to enable surgery at 3–4 months. Children with Narakas Group 1 and 2 are followed for at least 3 months. The absence of anti-gravity elbow flexion using the biceps muscle at that age remains the main indicator to decide for MRI-analysis and afterwards surgery at

the age of 4–6 months, unless late recovery commences and MRI does not show root avulsions.

Declaration of conflicting interests The authors declare no potential conflicts of interest with respect to the research, authorship, and/or publication of this article.

Funding The authors received no financial support for the research, authorship, and/or publication of this article.

References

- Al-Qattan MM. The outcome of Erb's palsy when the decision to operate is made at 4 months of age. *Plast Reconstr Surg.* 2000; 106: 1461–5.
- Al-Qattan MM, El-Sayed AA, Al-Zahrani AY et al. Narakas classification of obstetric brachial plexus palsy revisited. *J Hand Surg Eur.* 2009; 34: 788–91.
- Annika J, Paul U, Anna-Lena L. Obstetric brachial plexus palsy – a prospective, population-based study of incidence, recovery and long-term residual impairment at 10 to 12 years of age. *Eur J Paediatr Neurol.* 2019; 23: 87–93.
- Badr Y, O'Leary S, Kline DG. Management of one hundred seventy-one operative and nonoperative obstetrical birth palsies at the Louisiana State University Health Sciences Center. *Neurosurgery.* 2009; 65: A67–73.
- Bain JR, Dematteo C, Gjertsen D, Hollenberg RD. Navigating the gray zone: a guideline for surgical decision making in obstetrical brachial plexus injuries. *J Neurosurg Pediatr.* 2009; 3: 173–80.
- Birch R, Ahad N, Kono H, Smith S. Repair of obstetric brachial plexus palsy: results in 100 children. *J Bone Joint Surg Br.* 2005; 87: 1089–95.
- Bisinnella GL, Birch R. Obstetric brachial plexus lesions: a study of 74 children registered with the British Paediatric Surveillance Unit (March 1998–March 1999). *J Hand Surg Br.* 2003; 28: 40–5.
- Boome RS, Kaye JC. Obstetric traction injuries of the brachial plexus. Natural history, indications for surgical repair and results. *J Bone Joint Surg Br.* 1988; 70: 571–6.
- Boyer GF. The complete histo-pathological examination of the nervous system of an unusual case of obstetrical paralysis forty-one years after birth, and a review of the pathology. *Proc R Soc Med.* 1912; 5: 31–58.
- Capek L, Clarke HM, Curtis CG. Neuroma-in-continuity resection: early outcome in obstetrical brachial plexus palsy. *Plast Reconstr Surg.* 1998; 102: 1555–62.
- Chang KW, Justice D, Chung KC, Yang LJ. A systematic review of evaluation methods for neonatal brachial plexus palsy: a review. *J Neurosurg Pediatr.* 2013; 12: 395–405.
- Chantaraseno N, Precha V, Supichyangur K, Cholpranee K. Brachial plexus birth palsy: the natural history, outcome of microsurgical repair and operative reconstruction. *J Med Assoc Thai.* 2014; 97 Suppl 11: S96–101.
- Chen L, Gao SC, Gu YD, Hu SN, Xu L, Huang YG. Histopathologic study of the neuroma-in-continuity in obstetric brachial plexus palsy. *Plast Reconstr Surg.* 2008; 121: 2046–54.
- Chin KF, Misra VP, Sicuri GM, Fox M, Sinisi M. Intra-operative neurophysiological prediction of upper trunk recovery in obstetric brachial plexus palsy with neuroma in continuity. *Bone Joint J Br.* 2013; 95: 699–705.
- Clarke HM, Al Qattan MM, Curtis CG, Zuker RM. Obstetrical brachial plexus palsy: results following neurolysis of conducting neuromas-in-continuity. *Plast Reconstr Surg.* 1996; 97: 974–82.

- DiTaranto P, Campagna L, Price AE, Grossman JA. Outcome following nonoperative treatment of brachial plexus birth injuries. *J Child Neurol*. 2004, 19: 87–90.
- El-Sayed AAF. Evidence of the effectiveness of primary brachial plexus surgery in infants with obstetric brachial plexus palsy-revisited. *Child Neurol Open*. 2017, 4: 2329048X17709395.
- Gilbert A, Tassin JL. Surgical repair of the brachial plexus in obstetric paralysis [in French]. *Chirurgie*. 1984, 110: 70–5.
- Haerle M, Gilbert A. Management of complete obstetric brachial plexus lesions. *J Pediatr Orthop*. 2004, 24: 194–200.
- Hems TEJ, Savaridas T, Sherlock DA. The natural history of recovery of elbow flexion after obstetric brachial plexus injury managed without nerve repair. *J Hand Surgery Eur*. 2017, 42: 706–9.
- Kirjavainen M, Remes V, Peltonen J, Rautakorpi S, Helenius I, Nietosvaara Y. The function of the hand after operations for obstetric injuries to the brachial plexus. *J Bone Joint Surg Br*. 2008, 90: 349–55.
- Lagerkvist AL, Johansson U, Johansson A, Bager B, Uvebrant P. Obstetric brachial plexus palsy: a prospective, population-based study of incidence, recovery, and residual impairment at 18 months of age. *Dev Med Child Neurol*. 2010, 52: 529–34.
- Lin JC, Schwentker-Colizza A, Curtis CG, Clarke HM. Final results of grafting versus neurolysis in obstetrical brachial plexus palsy. *Plast Reconstr Surg*. 2009, 123: 939–48.
- Maillet M, Romana C. Complete obstetric brachial plexus palsy: surgical improvement to recover a functional hand. *J Child Orthop*. 2009, 3: 101–8.
- Malessy MJ, Pondaag W, van Dijk JG. Electromyography, nerve action potential, and compound motor action potentials in obstetric brachial plexus lesions: validation in the absence of a “gold standard”. *Neurosurgery*. 2009, 65: A153–9.
- Mallet J. Obstetrical paralysis of the brachial plexus. II. Therapeutics. Treatment of sequelae. Priority for the treatment of the shoulder. Method for the expression of results [in French]. *Rev Chir Orthop Reparatrice Appar Mot*. 1972, 58(Suppl 1): 166–8.
- Manske MC, Bauer AS, Hentz VR, James MA. Long-term outcomes of brachial plexus reconstruction with sural nerve autograft for brachial plexus birth injury. *Plast Reconstr Surg*. 2019, 143: 1017e–26e.
- Michelow BJ, Clarke HM, Curtis CG, Zuker RM, Seifu Y, Andrews DF. The natural history of obstetrical brachial plexus palsy. *Plast Reconstr Surg*. 1994, 93: 675–80.
- Narakas A. Obstetric brachial plexus injuries. In: Lamb DW (ed.) *The paralysed hand*. Edinburgh, Churchill Livingstone, 1987: 116–35.
- O’Grady KM, Power HA, Olson JL et al. Comparing the efficacy of triple nerve transfers with nerve graft reconstruction in upper trunk obstetric brachial plexus injury. *Plast Reconstr Surg*. 2017, 140: 747–56.
- Pondaag W, de Boer R, van Wijlen-Hempel MS, Hofstede-Buitenhuis SM, Malessy MJ. External rotation as a result of suprascapular nerve neurotization in obstetric brachial plexus lesions. *Neurosurgery*. 2005, 57: 530–7.
- Pondaag W, Malessy MJ. Recovery of hand function following nerve grafting and transfer in obstetric brachial plexus lesions. *J Neurosurg* (1 Suppl). 2006, 105: 33–40.
- Pondaag W, Malessy MJ. The evidence for nerve repair in obstetric brachial plexus palsy revisited. *BioMed Res Int*. 2014, 2014: 434619.
- Pondaag W, Malessy MJ, van Dijk JG, Thomeer RT. Natural history of obstetric brachial plexus palsy: a systematic review. *Dev Med Child Neurol*. 2004, 46: 138–44.
- Pondaag W, Malessy MJA. Outcome assessment for brachial plexus birth injury. Results from the ipluto world-wide consensus survey. *J Orthop Res*. 2018, 36: 2533–41.
- Sarac C, Duijnsveld BJ, van der Weide A et al. Outcome measures used in clinical studies on neonatal brachial plexus palsy: a systematic literature review using the international classification of functioning, disability and health. *J Pediatr Rehabil Med*. 2015, 8: 167–85.
- Sever JW. Obstetric paralysis. An orthopedic problem. *J Bone Joint Surg Am*. 1916, s2-14: 456–75.
- Smith NC, Rowan P, Benson LJ, Ezaki M, Carter PR. Neonatal brachial plexus palsy. Outcome of absent biceps function at three months of age. *J Bone Joint Surg Am*. 2004, 86: 2163–70.
- Socolovsky M, Costales JR, Paez MD, Nizzo G, Valbuena S, Varone E. Obstetric brachial plexus palsy: reviewing the literature comparing the results of primary versus secondary surgery. *Childs Nerv Syst*. 2016, 32: 415–25.
- Squitieri L, Larson BP, Chang KW, Yang LJ, Chung KC. Understanding quality of life and patient expectations among adolescents with neonatal brachial plexus palsy: a qualitative and quantitative pilot study. *J Hand Surg Am*. 2013, 38: 2387–97.e2.
- Strömbeck C, Krumlinde-Sundholm L, Forssberg H. Functional outcome at 5 years in children with obstetrical brachial plexus palsy with and without microsurgical reconstruction. *Dev Med Child Neurol*. 2000, 42: 148–57.
- Strömbeck C, Krumlinde-Sundholm L, Remahl S, Sejersen T. Long-term follow-up of children with obstetric brachial plexus palsy I: functional aspects. *Dev Med Child Neurol*. 2007, 49: 198–203.
- Terzis JK, Kokkalis ZT. Elbow flexion after primary reconstruction in obstetric brachial plexus palsy. *J Hand Surg Eur*. 2009, 34: 449–58.
- Tse R, Kozin SH, Malessy MJ, Clarke HM. International federation of societies for surgery of the hand committee report: the role of nerve transfers in the treatment of neonatal brachial plexus palsy. *J Hand Surg Am*. 2015, 40: 1246–59.
- Tse R, Marcus JR, Curtis CG, Dupuis A, Clarke HM. Suprascapular nerve reconstruction in obstetrical brachial plexus palsy: spinal accessory nerve transfer versus C5 root grafting. *Plast Reconstr Surg*. 2011, 127: 2391–6.
- van Ouwerkerk WJ, Uitdehaag BM, Strijers RL et al. Accessory nerve to suprascapular nerve transfer to restore shoulder exorotation in otherwise spontaneously recovered obstetric brachial plexus lesions. *Neurosurgery*. 2006, 59: 858–67.
- van Vliet AC, Tannemaat MR, van Duinen SG, Verhaagen J, Malessy MJ, De Winter F. Human neuroma-in-continuity contains focal deficits in myelination. *J Neuropathol Exp Neurol*. 2015, 74: 901–11.
- Waters PM. Comparison of the natural history, the outcome of microsurgical repair, and the outcome of operative reconstruction in brachial plexus birth palsy. *J Bone Joint Surg Am*. 1999, 81: 649–59.
- Xu J, Cheng X, Gu Y. Different methods and results in the treatment of obstetrical brachial plexus palsy. *J Reconstr Microsurg*. 2000, 16: 417–20.
- Yang LJ-S, Anand P, Birch R. Limb preference in children with obstetric brachial plexus palsy. *Pediatr Neurol*. 2005, 33: 46–9.