

Case Report

Pediatric infratentorial subdural empyema: A case report

Eleftherios Neromyliotis, Dimitrios Giakoumettis¹, Evangelos Drosos¹, Ioannis Nikas², Alexios Blionas³, George Sfakianos, Marios S. Themistocleous

Department of Neurosurgery, Children's Hospital 'Aghia Sofia', ¹Department of Neurosurgery, University of Athens Medical School, "Evangelismos" General Hospital, ²Department of Imaging, Children's Hospital "Aghia Sophia", ³Department of Neurosurgery, G. Gennimatas General Hospital, Athens, Greece

E-mail: Eleftherios Neromyliotis - neromiliotis@med.uoc.gr; Dimitrios Giakoumettis - dgiakoumettis@gmail.com; Evangelos Drosos - drosose@gmail.com; Ioannis Nikas - ianikas@yahoo.com; Alexandros Blionas - ablionas@gmail.com; George Sfakianos - gsfakianos@gmail.com;

*Marios S. Themistocleous - mthemistocleous@gmail.com

*Corresponding author

Received: 26 October 17 Accepted: 26 March 18 Published: 24 May 18

Abstract

Background: Infratentorial subdural empyemas in children are extremely rare and potentially lethal intracranial infections. Delay in diagnosis and therapy is associated with increased morbidity and mortality.

Case Description: A 4-year-old boy presented with cerebellar signs following a failed treatment of otitis media. Imaging studies revealed a subdural empyema and left transverse and sigmoid sinus thrombosis. The empyema was evacuated operatively and antibiotic treatment was initiated and administered for 6 weeks. The patient recovered fully and was discharged 4 weeks following the evacuation of the empyema.

Conclusion: While prompt identification and treatment of subdural infratentorial empyemas are crucial for favorable outcomes, their diagnosis in children might be initially missed. This is, in part because they are so rare and in part, because imaging artifacts arising from the complex posterior fossa anatomy may obscure their presence in the computer tomography (CT) scan. Therefore, high level of suspicion is necessary, given the appropriate history and clinical presentation. In children, this is a recent history of protracted otitis media and central nervous system symptomatology—cerebellar or other.

Key Words: Child, empyema, infratentorial, pediatric, subdural

Access this article online

Website:

www.surgicalneurologyint.com

DOI:

10.4103/sni.sni_394_17

Quick Response Code:



INTRODUCTION

A subdural empyema is defined as the focal intracranial collection of purulent material between the dura and the arachnoid mater. Most often, it presents as a complication of other pathologies such as sinusitis, mastoiditis, and bacterial meningitis or posttraumatically.^[3] It is a medical emergency requiring prompt identification and treatment with surgical evacuation and intravenous antibiotics; delay in therapy is associated with increased morbidity and mortality.^[1] Subdural empyemas are only rarely located in the posterior fossa. Their rarity and the limitations of computed tomography (CT) imaging in the evaluation of the posterior fossa make

subdural empyema especially prone to delayed diagnosis. In this report, we present a case of infratentorial subdural empyema that was successfully treated in our institution.

This is an open access journal, and articles are distributed under the terms of the Creative Commons Attribution-NonCommercial-ShareAlike 4.0 License, which allows others to remix, tweak, and build upon the work non-commercially, as long as appropriate credit is given and the new creations are licensed under the identical terms.

For reprints contact: reprints@medknow.com

How to cite this article: Neromyliotis E, Giakoumettis D, Drosos E, Nikas I, Blionas A, Sfakianos G, et al. Pediatric infratentorial subdural empyema: A case report. *Surg Neurol Int* 2018;9:104.

<http://surgicalneurologyint.com/Pediatric-infratentorial-subdural-empyema:-A-case-report/>

CASE REPORT

A 4-year-old boy presented to the pediatric emergency department with symptoms of cerebellar ataxia and gait disturbances. Sixteen days prior to that, his parents had consulted a primary care physician due to left earache and fever. No purulent discharge from the ear was evident at the time. Then, the patient was diagnosed with otitis media and was prescribed oral amoxicillin-clavulanic acid. Due to symptoms persistence, treatment was subsequently switched to oral cefuroxime.

Upon presentation to our emergency department, a complete blood count showed leukocytosis and neutrophilia. The prominence of cerebellar symptoms raised suspicion for an intracranial pathology and thus an emergency contrast-enhanced CT scan was performed. The scan revealed a multilobular cystic lesion with peripheral contrast enhancement, located in the subdural space of the posterior fossa, in contact with the tentorium cerebelli superiorly [Figure 1]. The lesion was compressing the left cerebellar hemisphere, which appeared edematous and the cerebellar midline was displaced by 9 mm. Moreover, the left middle ear cavity, ipsilateral mastoid air cells, and partially the left ethmoid air cells were occupied by fluid. The left transverse sinus could not be recognized in the scan. Subsequently, in order to evaluate more accurately the extent of the posterior fossa collection and to address the CT findings suggesting left transverse sinus thrombosis, a magnetic resonance imaging (MRI) scan and a magnetic resonance venography (MRV) were conducted. MRI confirmed the presence of extensive infratentorial subdural empyema over the left cerebellar hemisphere, accompanied by displacement and edema of the left cerebellum. MRV revealed diminished flow through the left transverse sinus and no flow through the left sigmoidal sinus [Figure 2], and these findings were consistent with sinus thrombosis.

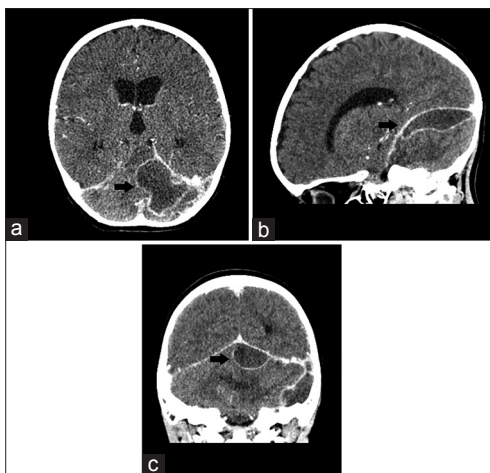


Figure 1: CT scan illustrating the extent and the location of the suppurative collection. (a) Transverse plane; (b) sagittal plane reconstruction; (c) coronal plane reconstruction

Consecutively, an emergency operation was scheduled. A left suboccipital craniotomy was performed. The transverse sinus was recognized and the dura was incised. Following traction of the cerebellum, the subdural space was expanded and the purulent collection was encountered. Cultures from the purulent fluid were obtained and the empyema was evacuated.

Intravenous antibiotic treatment with piperacillin-tazobactam and teicoplanin was initiated. After 4 days the patient had no fever, no neurological deficits, and was ambulatory. Follow-up MRI scan documented the successful evacuation of the empyema and subsiding inflammation [Figure 3]. Three weeks into the treatment, a morbilliform skin rash was developed on the patient's trunk, face, and limbs consistent with drug allergic reaction. The antibiotic treatment was then switched to oral clarithromycin, which was administered for 3 more weeks, for a total of 6 weeks of antibiotic treatment. The patient was discharged from the hospital 4 weeks after the operation.

DISCUSSION

Infratentorial subdural empyema is an extremely rare clinical entity both in children and in adults. Apart from the Madhugiri *et al.*^[6] case series, which consisted of 27 patients with mean age of 10 years, there is remarkable paucity in the literature. Sengul^[12] reports one such case in a 15-year-old boy, whereas Gupta *et al.*^[4] reported a case of 17-year-old patient. In both studies, the empyema followed a middle ear infection and presented mimicking pyogenic meningitis. There is also a case report^[5] of a posterior fossa subdural empyema in a 14-month old boy arising from a dermal sinus tract. Finally, the Farah *et al.*^[9] case series of 20 pediatric subdural empyemas includes just one case where posterior fossa was involved. The large Nathoo *et al.*^[8] case series of infratentorial empyemas aims to provide an

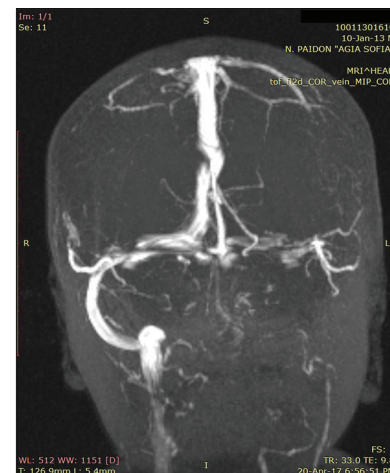


Figure 2: Preoperative MRV showing the deficient filling of the left transverse and sigmoid sinuses

estimate for the incidence of this clinical entity; their 13 cases of subdural infratentorial empyemas accounted for about 0.4% of all the intracranial suppuration cases they encountered during their study period. Table 1 provides an overview of all the cases of pediatric infratentorial subdural empyemas described in the literature.

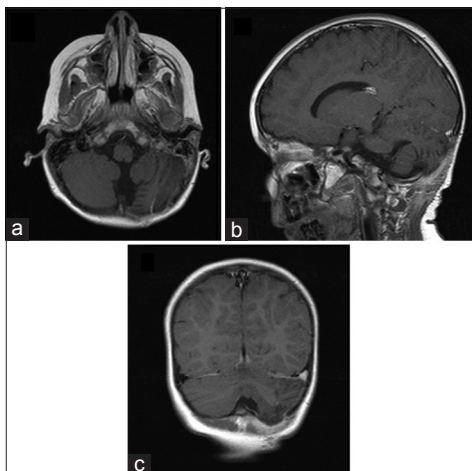


Figure 3: Postoperative (26 days following the operation) MRI (T1 weighted) documenting the successful evacuation of the purulent collection. (a) Transverse plane; (b) sagittal plane; (c) coronal plane

Our patient presented with cerebellar signs and a recent history of otitis media. In the Madhugiri series,^[6] 40% of the patients and just 13% of patients of the Nathoo^[8] series presented with cerebellar symptomatology. The most common presenting symptoms in both series were meningism, depressed level of consciousness, fever, and ear discharge. Seizures, hemiparesis, or cranial nerve palsy could also be part of the presentation. Furthermore, the patients of the Borovich^[2] and Morgan^[7] series described similar symptoms and signs. It is noteworthy that subdural empyemas without treatment are invariably fatal. Prompt diagnosis and treatment with intravenous antibiotics and neurosurgical intervention are necessary in order to not only increase the survival rates but also to decrease the gravity of any neurological sequelae.^[10]

The primary cause of infratentorial empyemas is a complicated otogenic infection. This is the case for our patient who underwent a prolonged antibiotic treatment for an otitis media infection that proved resistant. The same course was described in 19 out of 22 Nathoo's^[8] patients, 26 out of 27 Madhugiri^[6] patients, in all 3 Borovich^[2] cases, and 5 out of 7 Morgan's patients.^[7]

Table 1: Literature review of all reported cases of pediatric infratentorial subdural empyemas

Authors	No. of cases	Age	Cause	Preoperative imaging modality	Microbiology	Operation	Antibiotic Treatment	Complications	Outcome
Madhugiri <i>et al.</i> ^[6]	27	Mean age: 10 years old	Middle ear infection in all but one	CT scan in all MRI in one patient with sinus thrombosis	Sterile in 7 Polymicrobial in 5 Streptococci, Pneumoniococcus, Bacterioides and others	Burr holes in 7 patients (prone to recurrence) Craniotomy in 20 patients	6 weeks of antibiotics (cefotaxime or ceftriaxone, metronidazole, aminoglycoside)	Reoperation of 6 patients Hydrocephalus in 20 patients, permanent shunt in 6 Sinus thrombosis in 1 patient	GOS 5: 7 patients GOS 4: 18 patients GOS 2: 1 patient 1 death.
Sengul ^[12]	1	15 years old	Middle ear infection	CT and MRI	Sterile	Craniectomy	6 weeks of antibiotics (ceftriaxone, vancomycin)	Hydrocephalus (requiring EVD)	Recovery
Gupta <i>et al.</i> ^[4]	1	17 years old	Middle ear infection	CT (negative) and MRI	Sterile	Craniectomy	10 days of antibiotics	Hydrocephalus	Complete recovery
Kanev <i>et al.</i> ^[5]	1	14 months old	Dermal sinus tract	CT and MRI	Polymicrobial (<i>Staphylococcus aureus</i> and <i>Escherichia coli</i>)	N.S.	4 weeks of antibiotic treatment (nafcillin, ceftriaxone)	Hydrocephalus (permanent shunt)	Complete recovery
Osman Farah <i>et al.</i> ^[9]	1	N.S. <16 years old	Sinusitis with mastoid involvement	N.S.	Coag. negative <i>Staphylococcus</i>	Burr hole for evacuation of infratentorial collection Craniotomy for evacuation of supratentorial collection	12 weeks of antibiotic treatment (flucloxacillin)	Hydrocephalus (requiring EVD)	N.S.

GOS: Glasgow outcome score, EVD: External ventricular drainage, NS: Not specified

In terms of diagnosis, high clinical suspicion is the first step. Despite the greater accuracy of MRI scans in diagnosing intracranial pathologies, the initial imaging study of choice is CT scan, due to its speed and availability.^[2,6,8] However, the complex osseous posterior fossa anatomy produces imaging artifacts that may obscure the purulent collection. As a result, diagnosis of posterior fossa empyemas may be initially overlooked, thus delaying appropriate treatment.^[13,14] MRI scan is more time-consuming—a consideration that is taken into account for a patient with altered mental state^[6]—but it is the preferred imaging modality, especially diffusion weighted imaging sequences, which can distinguish suppurative collections from reactive subdural effusions.^[14]

The culture of the purulent collection we obtained intraoperatively did not identify any pathogens. This is a frequently encountered mischief in subdural empyemas. Sterile collections are reported in the Nathoo^[8] series (5 out of 22 cases), Madhugiri^[6] series (7 out of 27), and Morgan series^[7] (3 out of 7 cases). In other smaller reports, for example the two Taha patients, cultures of the suppurative fluid were sterile.^[13] Nevertheless, when a pathogen was to be isolated, *Proteus mirabilis* was the most frequent causative species in Nathoo *et al.* study, and polymicrobial culture was the second most frequent culture result. In the Madhugiri *et al.*^[6] study, polymicrobial cultures and nonhemolytic streptococci were the most prevalent results. Madhugiri *et al.*^[6] noted that cases with sterile cultures tended to have higher chance for re-accumulation of the suppuration and, thus, necessitating a second operation for re-evacuation. A repeat operation was required for 5 out of 7 cases with sterile cultures, compared to 1 out of 20 cases with nonsterile cultures. Agrawal *et al.*^[1] considered sterile culture of the subdural collection as one of the unfavorable prognostic factors.

Finally, the course of our patient was complicated with left transverse and sigmoid sinus thrombosis. Sinus thrombosis was encountered in one of the Madhugiri^[6] patients, two of Nathoo's^[8] patients, two of Morgan's^[7] patients, and in a case report by Sahjipaul.^[11] Nathoo *et al.*^[8] reported significant morbidity for their patients that exhibited this complication.

Infratentorial subdural empyemas compared to the more common supratentorial variants are associated with higher

mortality. This has been attributed to delays in diagnosis and treatment.^[14] Therefore, it is worth including this threatening clinical entity in the differential diagnosis list, despite its rarity and despite an initial negative or inconclusive CT scan.

Declaration of patient consent

The authors certify that they have obtained all appropriate patient consent forms. In the form the patient(s) has/have given his/her/their consent for his/her/their images and other clinical information to be reported in the journal. The patients understand that their names and initials will not be published and due efforts will be made to conceal their identity, but anonymity cannot be guaranteed.

Financial support and sponsorship

Nil.

Conflicts of interest

There are no conflicts of interest.

REFERENCES

1. Agrawal A, Timothy J, Pandit L, Shetty L, Shetty J. A review of subdural empyema and its management. *Infect Dis Clin Pract* 2007;15:149-53.
2. Borovich B, Johnston E, Spagnuolo E. Infratentorial subdural empyema: Clinical and computerized tomography findings. Report of three cases. *J Neurosurg* 1990;72:299-301.
3. Calfee DP, Wispelwey B. Brain abscess, subdural empyema, and intracranial epidural abscess. *Curr Infect Dis Rep* 1999;1:166-71.
4. Gupta A, Karanth SS, Raja A. Infratentorial subdural empyemas mimicking pyogenic meningitis. *J Neurosci Rural Pract* 2013;4:213-5.
5. Kanev PM, Salazar JC. Unusual CNS infection from a subtorcular dermal sinus. *Acta Paediatr* 2010;99:627-9.
6. Madhugiri VS, Sastri BV, Bhagavatula ID, Sampath S, Chandramouli BA, Pandey P. Posterior fossa subdural empyema in children – management and outcome. *Childs Nerv Syst* 2011;27:137-44.
7. Morgan DW, Williams B. Posterior fossa subdural empyema. *Brain* 1985;108(Pt 4):983-92.
8. Nathoo N, Nadvi SS, van Dellen JR. Infratentorial empyema: Analysis of 22 cases. *Neurosurgery* 1997;41:1263-8; discussion 1268-1269.
9. Osman Farah J, Kandasamy J, May P, Buxton N, Mallucci C. Subdural empyema secondary to sinus infection in children. *Childs Nerv Syst* 2009;25:199-205.
10. Renaudin JW, Frazee J. Subdural empyema – importance of early diagnosis. *Neurosurgery* 1980;7:477-9.
11. Sahjipaul RL, Lee DH. Infratentorial subdural empyema, pituitary abscess, and septic cavernous sinus thrombophlebitis secondary to paranasal sinusitis: Case report. *Neurosurgery* 1999;44:864-6; discussion 866-868.
12. Sengul G. Infratentorial subdural empyema. *Turk Neurosurg* 2009;19:200-2.
13. Taha MM, Hassanain S. Subtentorial subdural empyema: Report of two cases and review of the literatures. *Turk Neurosurg* 2011;21:669-673.
14. van de Beek D, Campeau NG, Wijdicks EF. The clinical challenge of recognizing infratentorial empyema. *Neurology* 2007;69:477-81.