

Current Concept of Stem Cell Therapy for Spinal Cord Injury: A Review

Sun Kyu Oh, MD, and Sang Ryong Jeon, MD, PhD

Department of Neurological Surgery, Asan Medical Center, University of Ulsan College of Medicine, Seoul, Korea

Spinal cord injury (SCI) is a catastrophic condition associated with significant neurological deficit, social, and financial burdens. Over the past decades, various treatments including medication, surgery, and rehabilitation therapy for SCI have been performed, but there were no definite treatment option to improve neurological function of patients with chronic SCI. Therefore, new treatment trials with stem cells have been studied to regenerate injured spinal cord. Among various types of stem cells, bone marrow derived mesenchymal stem cells is highly expected as candidates for the stem cell therapy. The result of the current research showed that direct intramedullary injection to the injured spinal cord site in subacute phase is most effective. Neurological examination, electrophysiologic studies, and magnetic resonance imaging are commonly used to assess the effectiveness of treatment. Diffusion tensor imaging visualizing white matter tract can be also alternative option to identify neuronal regeneration. Despite various challenging issues, stem cell therapy will open new perspectives for SCI treatment.

(Korean J Neurotrauma 2016;12(2):40-46)

KEY WORDS: Bone marrow · Cell therapy · Clinical trial · Mesenchymal stem cells · Spinal cord injury.

Introduction

Spinal cord injury (SCI) is a catastrophic disaster which can result in irreversible severe disability including motor and sensory loss. A recent review of SCI shows an incidence of average 29.5 cases per million per year and more than one million patients suffer from paralysis caused by SCI.⁷⁰ As a result, severe disability and medical costs has become a burden to the patients with SCI, their families and community.^{3,19,54} The primary causes of SCI by trauma are motor vehicle accidents, falls, violence, sports injuries, and industry-related injuries.¹¹ Most of the SCI pa-

tients are young men and the highest incidence of SCI is to individuals in the age range of 20 to 29.^{18,47} Over the past decades, numerous treatments including medication, surgery, and rehabilitation therapy for SCI have been performed, but there were no sovereign treatment options for chronic SCI. After SCI, various unfavorable environments for recovery including release of inhibitory molecules and glial scar formation were reported. This environment prevents axons regeneration across the site of SCI. Therefore, there have been many clinical trials using stem cell to regenerate damaged spinal cord. Here, the authors review the overview of SCI and consideration for current aspects of clinical stem cell therapy.

Pathophysiology of SCI

SCI is classified primary and secondary injury. Primary injury is caused by various external forces such as compression, contusion, or laceration. The most common types of SCI are contusion of the spinal cord by a burst fracture of fracture-dislocation of the spinal column.⁶² Secondary injury is series of chain reaction which caused by the pri-

Received: February 17, 2016 / **Revised:** April 10, 2016

Accepted: April 28, 2016

Address for correspondence: Sang Ryong Jeon
Department of Neurological Surgery, Asan Medical Center, University of Ulsan College of Medicine, 88 Olympic-ro, 43-gil, Songpa-gu, Seoul 05505, Korea
Tel: +82-2-3010-3562, Fax: +82-2-476-6738
E-mail: srjeon@amc.seoul.kr

© This is an Open Access article distributed under the terms of Creative Attributions Non-Commercial License (<http://creativecommons.org/licenses/by-nc/3.0/>) which permits unrestricted noncommercial use, distribution, and reproduction in any medium, provided the original work is properly cited.

mary injury and these events occur from a few minutes to several weeks after SCI. Immediately following injury, cascade events including edema, decreased blood flow, vasospasm, free radical production, inflammation, excitotoxicity, lipid peroxidation, and ischemia provoke cell apoptosis.^{43,58)} Astrocytes also contribute to glial scar formation and these glial scarring not only prevent inflammatory cells infiltration but also interfere axon regeneration.³⁷⁾ Moreover, tissue loss forms a fluid-filled cavity in which inhibitory molecules are upregulated and these result in a physical barrier to neuroregeneration.¹⁷⁾

Various Types and Characteristics of Candidates in Cell Therapy

Characteristics of stem cell

Two important features of stem cells are differentiation capability to differentiate into various cell types and renewing ability. Additionally, stem cells secrete substances such as cytokine, growth factor, and trophic factor which promote neuroprotection.²⁶⁾ There are a variety of stem cells according to the origin and differentiation capacity. Embryonic stem cells are pluripotent stem cells because of the ability to differentiate into three germ layers^{44,66)} and adult stem cells are multipotent stem cells because of the more limited ability to differentiate.^{8,31,67,71)} Stem cell therapy offers potential mechanisms such as replacement of neuronal cells, remyelination of axons, preservation of glial cells, and increased trophic molecules. Stem cells also have ability of angiogenesis, bridging of cavities, reducing inflammation, and stimulation of endogenous precursor cells for neuronal plasticity.⁴³⁾

Schwann cells

Schwann cells are the supportive glia in the peripheral nervous system and produce myelin sheath to peripheral axon. Schwann cells also support guidance bands for remyelination and axonal regeneration after nerve injury. Implanted Schwann cells in spinal cord can produce several neurotrophic factors that contribute to neuronal survival and to support axonal growth.⁷⁴⁾ It was the first cells used in SCI animal models for promoting axon regeneration and investigated in a lot of preclinical SCI studies.^{6,14)} Saberi et al.⁵⁷⁾ injected Schwann cells into the cavity around the damaged spinal cord in patients with complete chronic SCI. During a follow-up period, subtle improvement was observed in motor and sensory function. Safety of these cells was demonstrated and there were no malignant transformation or abnormal finding.

Olfactory ensheathing cells (OEC)

The neurogenesis continues to take place in distal part of olfactory nerve and OEC can be obtained from olfactory mucosa,⁴¹⁾ which surround the axons of the olfactory neuron. Moreover, OECs have the ability to differentiate into non-olfactory cell types and can be good candidates for stem cell therapy. However, the results of clinical studies were not promising. Mackay-Sim et al.⁴⁰⁾ reported the clinical study using these cells, but no significant neurological improvement was found after transplantation into injured spinal cord in human. Huang et al.²⁹⁾ also implanted fetal olfactory bulbs around the damaged spinal cord site in 656 patients with chronic SCI and the follow-up magnetic resonance image (MRI) did not reveal any changes in the spinal cord.

Embryonic stem cells

Embryonic stem cells are pluripotent cell which can differentiate into the 3 primary germ layers and these cells can develop into astrocytes, oligodendrocytes, or even neurons.⁴²⁾ However, even though these cells are the perfect candidates for stem cell therapy, there are some ethical issues in using human embryonic stem cells because human embryos are required to obtain these cells. Additionally, malignant transformation is another important problem. Because of the risk of teratoma or other malignancy,³⁸⁾ clinical studies using embryonic stem cells are not currently in progress.

Bone marrow derived mesenchymal stem cells (BM MSCs)

BM MSCs are multipotent progenitor cells which have the facility to differentiate into mesodermal lineages and induce trophic activities related to neural cells.⁹⁾ In addition, BM MSCs not only enhance neuronal protection but also reduce the inflammation and microglial reactivity by immunosuppressive feature.^{1,46)} Moreover, implanted BM MSCs can fill the cavity produced by the trauma in the spinal cord, producing bridge materials, enhancing axonal regeneration through the cavity.^{27,61)} The activation of intramedullary endogenous stem cell was known to occur by BM MSCs.⁴⁵⁾ In addition, BM MSCs can be harvested from BM at the bedside and the use of MSCs can overcome ethical problems or rejection complications because MSCs are extracted from the patients' own BM. Therefore, there have been many clinical studies using BM MSCs than other cell treatments. Park et al.⁵¹⁾ reported BM MSCs transplantation therapy in patients with SCI into the site of SCI and six of ten patients showed motor improvement of the upper ex-

tremities.

Strategies for Optimizing the Therapeutic Effect of Stem Cell

Administration route and location of injection

Determining the appropriate transplantation route for stem cells is important for the treatment efficacy. Intravenous, intrathecal and direct intramedullary injection are representative methods for transplantation of stem cells. Intravenous injection and intrathecal injection are less invasive than intramedullary injection. These methods use the homing effect: implanted stem cell can move to the injured area. According to the reports on animals, intrathecal injection is more effective for stem cell engraftment to the injured site compared to intravenous injection.^{2,53} However, intrathecal injection needs large stem cell numbers for them to reach in the injured spinal cord with the appropriate amount of cells, and subarachnoid adhesion may play as an obstacle for the cells which reach to the target site.⁴⁰ The chronic stage of SCI in which the wound-healing process has ended, does not have homing effect. Therefore, direct injection into the injured site is most effective method for delivering stem cells even though possibility of cerebrospinal fluid leakage, intramedullary hemorrhage or additional neuronal damage in chronic SCI.⁵¹

In case of intramedullary injection, it is important to decide the point of injection for stem cells implantation. Proximal spinal cord above the injured area is the favorable site for the survival of stem cells, but there is a limitation to inject an appropriate volume of stem cells because of high tissue pressure and the risk of normal spinal cord damage. On the contrary, a sufficient amount of MSCs can be injected in the cavity area at the injured level, but this area is hostile environment for the survival of MSCs due to lower vascular perfusion. In addition, the injection into the contused cavity is good for the resolution of glial scars and bridging for axonal regeneration. Therefore, Park et al.⁵¹ performed MSCs injection into both the normal proximal spinal cord and the injured area to take the advantages of both sites. In addition to intramedullary injection, they applied additional subdural stem cells to increase the cell numbers with the hypothesis that subdural stem cells would migrate into spinal cord by the homing effect that would be newly developed from intramedullary injection.

Timing of stem cells transplantation

Generally, acute phase is defined as the first three days after SCI and chronic phase is defined as more than 12

months after SCI. Subacute phase is defined as the period between acute and chronic phase. Spontaneous neurological recovery rise rapidly during the first three months and plateaued at 12 months after SCI.¹⁶ Immediately following the SCI in the acute phase, several secondary injury cascade by reactive oxygen free radical, excitatory transmitters, and inflammatory molecules produce cytotoxic environment for implanted stem cells.²⁵ In addition, hypoxic condition caused by hypoperfusion also is hostile to implanted stem cells.⁶⁴ In case of the chronic phase, glial scar tissue acts as a physical barrier which interfere with axonal regrowth and there are some reports about less axonal growth in the chronic stage compared to acute or subacute phase.^{28,65,72} In several reports which used rodent models revealed that decrease of neuronal growth and production of injury-induced growth stimulating proteins in chronic SCI.^{35,60} Thus, it is difficult for implanted stem cells to survive in chronic SCI. In contrast, in the subacute phase, the inflammatory response is reduced and the glial scar formation has not formed. The subacute phase also showed better cell survival when stem cells were injected rather than acute phase.^{49,52} Therefore, the subacute phase seems to be an optimal phase in the respect of timing of stem cell application.

Other strategies to improve survival and function of implanted stem cells

Park et al.⁵¹ previously described clinical trial using multiple BM MSCs injections and revealed that motor improvement in 60% of patients. However, the authors' phase II/III clinical trial using single BM MSCs showed disappointing results which showed motor improvement in only 2 of 16 patients even though we used the same amount of stem cells between previous and current phase II/III clinical trials. Therefore, multiple injections may be more effective than single injection therapy. Moreover, some strategies using supplement material for stem cell survival have been tried currently. For example, a combination of trophic factors including epidermal growth factor (EGF), fibroblast growth factor type 2 (FGF2) and platelet-derived growth factor (PDGF) enhanced the survival of implanted cells.^{23,30} In addition, granulocyte macrophage-colony stimulating factor,⁷² chondroitinase⁵ and gene modification of cells for secreting supportive molecules⁶¹ have been proposed as the alternative method.

Evaluation Tools of the Therapeutic Effect

Neurological examination and evaluation of an activity of daily living (ADL)

It is the most basic method of evaluation for significant neurologic recovery is to examine the strength of each joint segment objectively. Neurological motor examination is usually conducted according to the International Standards for Neurological Classification of Spinal Cord Injury³²⁾ Moreover, this neurological improvement is to assess whether they lead to improve an ADL. Various scales to evaluate ADL in SCI including Katz Index of Independence in ADL,⁶⁹⁾ functional independence measure,⁵⁰⁾ quadriplegia index of function,²¹⁾ and modified Barthel Index⁶⁸⁾ had been proposed.

Electrophysiological (EP) studies

EP studies such as somatosensory evoked potentials and motor evoked potentials can also use to identify the effect of stem cell treatment. In several animal studies, EP demonstrates close affinity between neurological recovery and EP change after cell therapy.^{13,22,48,56)} Similarly, in human clinical trials, EP was also used as a measurement for neurological improvement, and showed the relevance to the neurological outcome.^{12,33,63)} However, this association did not equally be observed in all studies.^{34,39,51)} In authors' pres-

ent clinical trials, some patients with motor improvement showed EP changes, while these changes also has been observed in patients without neurological improvement. Therefore, we assumed that the EP change is a necessary condition for significant motor improvement but not a sufficient condition.

Diagnostic imaging study

Imaging study is also performed by a MRI with T1-weighted images, T2-weighted images, and T1 contrast-enhanced imaging before and after stem cell therapy to evaluate a change caused by treatment. Previous several studies have reported various MRI finding after stem cell therapy. Park et al.⁵¹⁾ reported that some finding including widening of cord diameter, blurring of intramedullary cavity margin, and appearance of fiber-like streaks pattern at the injured spinal cord revealed in neurologically improved patients. Other authors reported that same finding of increases in the diameter of the spinal cord on MRI were more frequently seen in the stem cell therapy group than in the control group, but the difference was not statistically significant.⁷²⁾ Even though such changes in MRI findings tend to be detected in patients with neurological improvement, those findings could also occur in patients without neurological improvement. In order to improve these disadvantages of conventional MRI, the authors conducted diffusion tensor imaging (DTI) in current phase II/III clinical

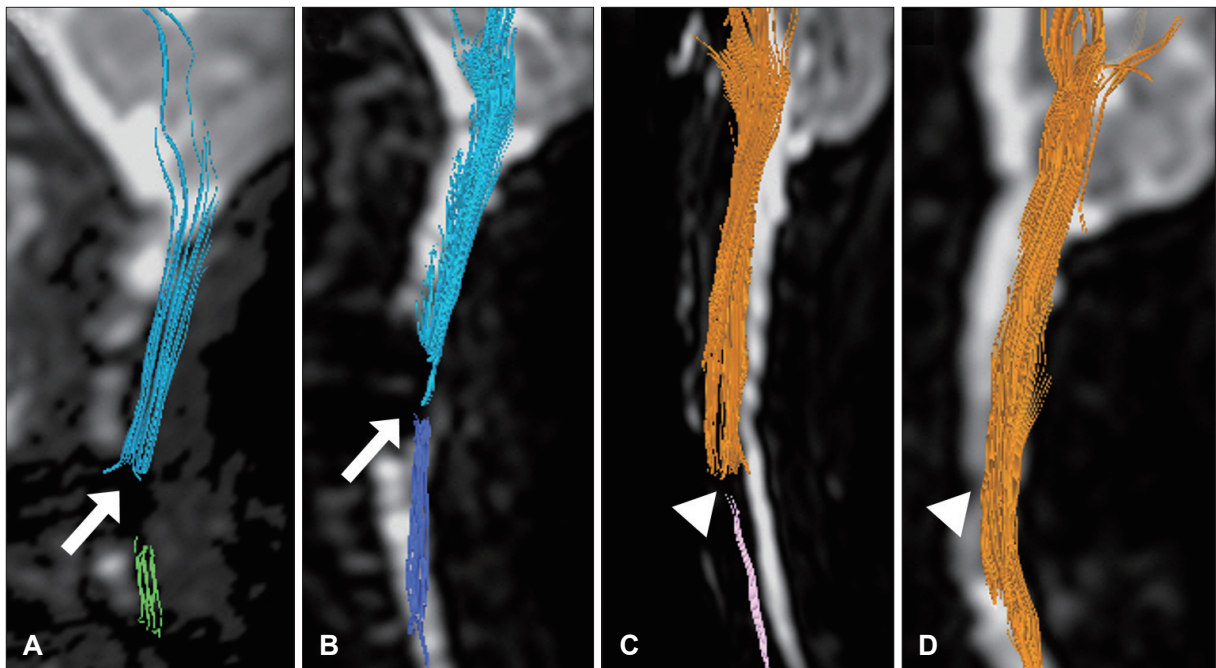


FIGURE 1. (A) Discontinuity of white matter fiber on pre-treatment diffusion tensor imaging (DTI) (arrow) (B) remained on DTI 6 months after mesenchymal stem cells injection (arrow). DTI evaluated at 6 months after the operation (D) revealed newly generated continuity in fiber signals (arrowhead) compared to preoperative DTI (arrowhead) (C).

trial. DTI can perform accurate visualization and assessment of white matter tracts and also discriminate differences between MRI and clinical status in central nervous system disorders such as stroke, multiple sclerosis, and various demyelinating diseases.³⁶⁾ DTI is also known to be useful for the prediction of neurological recovery in SCI patients.^{10,15,55)} In authors' present clinical trial, two patients who had neurological improvement showed appearance of fiber continuity at the injury site in the cord while there were no change in patients without neurological improvement (Figure 1). Therefore, the appearance of fiber continuity on DTI which was not seen before stem cell therapy may be an indicator of axonal regeneration in stem cell therapy.

Other evaluation techniques

Another important point in stem cell research is that it is hard to monitor the status of the transplanted stem cells in the body. In other words, it is difficult to determine the survival, migration, and the exact location of the implanted stem cells. Accordingly, cell labeling techniques for *in vivo* visualization using biological indicator or contrast agent has been recently studied. Typical examples are supermagnetic iron oxide (SPIO) particle by using MRI⁴⁾ and radionuclides by using positron emission tomography or single-photon emission computed tomography.⁵⁹⁾ In particular, many studies which use stem cells labeled with SPIO particle has been discussed in many animal experiments, clinical trials.^{7,20,24,73)} These studies are likely to be a future standard of stem cell treatment because it allows the *in vivo* identification of implanted stem cells.

Conclusion

Currently, there have been a numerous clinical and experimental studies showing positive results in terms of functional improvement with stem cell treatment in SCI. Even though the exact mechanism stem cell therapy is still unknown, various designs of SCI trials should be performed. Human SCI trials are very difficult to enforce easily because of some limitations. First, SCI is very heterogeneous in cause and severity, and design of randomized control trials is also complicated. Second, comparison between treatment and control group is probably impossible because of ethical aspects. At last, in terms of safety and efficacy, the result of animal experiments cannot be applied to the human directly.

However, stem cell therapy in SCI provides a clue to solve the challenges which modern medicine cannot treat. A lot of basic research and clinical trials has already been tried

using stem cell therapy and promising results have been also reported. If stem cell therapy in SCI is established, it will have a great progression on other incurable degenerative central nervous system disorders.

■ The authors have no financial conflicts of interest.

REFERENCES

- 1) Abrams MB, Dominguez C, Pernold K, Reger R, Wiesenfeld-Hallin Z, Olson L, et al. Multipotent mesenchymal stromal cells attenuate chronic inflammation and injury-induced sensitivity to mechanical stimuli in experimental spinal cord injury. *Restor Neurol Neurosci* 27:307-321, 2009
- 2) Bakshi A, Hunter C, Swanger S, Lepore A, Fischer I. Minimally invasive delivery of stem cells for spinal cord injury: advantages of the lumbar puncture technique. *J Neurosurg Spine* 1:330-337, 2004
- 3) Branco F, Cardenas DD, Svircev JN. Spinal cord injury: a comprehensive review. *Phys Med Rehabil Clin N Am* 18:651-679, 2007
- 4) Bulte JW, Kraitchman DL. Iron oxide MR contrast agents for molecular and cellular imaging. *NMR Biomed* 17:484-499, 2004
- 5) Bunge MB. Novel combination strategies to repair the injured mammalian spinal cord. *J Spinal Cord Med* 31:262-269, 2008
- 6) Bunge MB, Wood PM. Realizing the maximum potential of Schwann cells to promote recovery from spinal cord injury. *Handb Clin Neurol* 109:523-540, 2012
- 7) Callera F, de Melo CM. Magnetic resonance tracking of magnetically labeled autologous bone marrow CD34+ cells transplanted into the spinal cord via lumbar puncture technique in patients with chronic spinal cord injury: CD34+ cells' migration into the injured site. *Stem Cells Dev* 16:461-466, 2007
- 8) Caplan AI. Adult mesenchymal stem cells for tissue engineering versus regenerative medicine. *J Cell Physiol* 213:341-347, 2007
- 9) Caplan AI. Why are MSCs therapeutic? New data: new insight. *J Pathol* 217:318-324, 2009
- 10) Chang Y, Jung TD, Yoo DS, Hyun JK. Diffusion tensor imaging and fiber tractography of patients with cervical spinal cord injury. *J Neurotrauma* 27:2033-2040, 2010
- 11) Chen Y, Tang Y, Vogel LC, Devivo MJ. Causes of spinal cord injury. *Top Spinal Cord Inj Rehabil* 19:1-8, 2013
- 12) Curt A, Schwab ME, Dietz V. Providing the clinical basis for new interventional therapies: refined diagnosis and assessment of recovery after spinal cord injury. *Spinal Cord* 42:1-6, 2004
- 13) Deng YB, Liu XG, Liu ZG, Liu XL, Liu Y, Zhou GQ. Implantation of BM mesenchymal stem cells into injured spinal cord elicits de novo neurogenesis and functional recovery: evidence from a study in rhesus monkeys. *Cytotherapy* 8:210-214, 2006
- 14) Duncan ID, Aguayo AJ, Bunge RP, Wood PM. Transplantation of rat Schwann cells grown in tissue culture into the mouse spinal cord. *J Neurol Sci* 49:241-252, 1981
- 15) Ellingson BM, Ulmer JL, Kurpad SN, Schmit BD. Diffusion tensor MR imaging in chronic spinal cord injury. *AJNR Am J Neuroradiol* 29:1976-1982, 2008
- 16) Fawcett JW, Curt A, Steeves JD, Coleman WP, Tuszynski MH, Lammertse D, et al. Guidelines for the conduct of clinical trials for spinal cord injury as developed by the ICCP panel: spontaneous recovery after spinal cord injury and statistical power needed for therapeutic clinical trials. *Spinal Cord* 45:190-205, 2007
- 17) Fehlings MG, Tighe A. Spinal cord injury: the promise of translational research. *Neurosurg Focus* 25:E1, 2008
- 18) Furlan JC, Fehlings MG. The impact of age on mortality, impairment, and disability among adults with acute traumatic spinal cord injury. *J Neurotrauma* 26:1707-1717, 2009

- 19) García-Altés A, Pérez K, Novoa A, Suelves JM, Bernabeu M, Vidal J, et al. Spinal cord injury and traumatic brain injury: a cost-of-illness study. *Neuroepidemiology* 39:103-108, 2012
- 20) Gonzalez-Lara LE, Xu X, Hofstetrova K, Pniak A, Chen Y, McFadden CD, et al. The use of cellular magnetic resonance imaging to track the fate of iron-labeled multipotent stromal cells after direct transplantation in a mouse model of spinal cord injury. *Mol Imaging Biol* 13:702-711, 2011
- 21) Gresham GE, Labi ML, Dittmar SS, Hicks JT, Joyce SZ, Stehlik MA. The Quadriplegia Index of Function (QIF): sensitivity and reliability demonstrated in a study of thirty quadriplegic patients. *Paraplegia* 24:38-44, 1986
- 22) Guo JS, Zeng YS, Li HB, Huang WL, Liu RY, Li XB, et al. Co-transplant of neural stem cells and NT-3 gene modified Schwann cells promote the recovery of transected spinal cord injury. *Spinal Cord* 45:15-24, 2007
- 23) Guo X, Zahir T, Mothe A, Shoichet MS, Morshead CM, Katayama Y, et al. The effect of growth factors and soluble Nogo-66 receptor protein on transplanted neural stem/progenitor survival and axonal regeneration after complete transection of rat spinal cord. *Cell Transplant* 21:1177-1197, 2012
- 24) Guzman R, Uchida N, Bliss TM, He D, Christopherson KK, Stellwagen D, et al. Long-term monitoring of transplanted human neural stem cells in developmental and pathological contexts with MRI. *Proc Natl Acad Sci U S A* 104:10211-10216, 2007
- 25) Hall ED, Springer JE. Neuroprotection and acute spinal cord injury: a reappraisal. *NeuroRx* 1:80-100, 2004
- 26) Himes BT, Neuhuber B, Coleman C, Kushner R, Swanger SA, Kopen GC, et al. Recovery of function following grafting of human bone marrow-derived stromal cells into the injured spinal cord. *Neurorehabil Neural Repair* 20:278-296, 2006
- 27) Hofstetter CP, Schwarz EJ, Hess D, Widenfalk J, El Manira A, Prockop DJ, et al. Marrow stromal cells form guiding strands in the injured spinal cord and promote recovery. *Proc Natl Acad Sci U S A* 99:2199-2204, 2002
- 28) Houle JD, Tessler A. Repair of chronic spinal cord injury. *Exp Neurol* 182:247-260, 2003
- 29) Huang H, Chen L, Xi H, Wang Q, Zhang J, Liu Y, et al. Olfactory ensheathing cells transplantation for central nervous system diseases in 1,255 patients. *Zhongguo Xiu Fu Chong Jian Wai Ke Za Zhi* 23:14-20, 2009
- 30) Karimi-Abdolrezaee S, Eftekharpour E, Wang J, Schut D, Fehlings MG. Synergistic effects of transplanted adult neural stem/progenitor cells, chondroitinase, and growth factors promote functional repair and plasticity of the chronically injured spinal cord. *J Neurosci* 30:1657-1676, 2010
- 31) Kim SU. Human neural stem cells genetically modified for brain repair in neurological disorders. *Neuropathology* 24:159-171, 2004
- 32) Kirshblum S, Waring W, 3rd. Updates for the international standards for neurological classification of spinal cord injury. *Phys Med Rehabil Clin N Am* 25:505-517, 2014
- 33) Kirshblum SC, O'Connor KC. Predicting neurologic recovery in traumatic cervical spinal cord injury. *Arch Phys Med Rehabil* 79:1456-1466, 1998
- 34) Knoller N, Auerbach G, Fulga V, Zelig G, Attias J, Bakimer R, et al. Clinical experience using incubated autologous macrophages as a treatment for complete spinal cord injury: phase I study results. *J Neurosurg Spine* 3:173-181, 2005
- 35) Kobayashi NR, Fan DP, Giehl KM, Bedard AM, Wiegand SJ, Tetzlaff W. BDNF and NT-4/5 prevent atrophy of rat rubrospinal neurons after cervical axotomy, stimulate GAP-43 and Talphal-tubulin mRNA expression, and promote axonal regeneration. *J Neurosci* 17:9583-9595, 1997
- 36) Le Bihan D, Mangin JF, Poupon C, Clark CA, Pappata S, Molko N, et al. Diffusion tensor imaging: concepts and applications. *J Magn Reson Imaging* 13:534-546, 2001
- 37) Leal-Filho MB. Spinal cord injury: From inflammation to glial scar. *Surg Neurol Int* 2:112, 2011
- 38) Li JY, Christophersen NS, Hall V, Soulet D, Brundin P. Critical issues of clinical human embryonic stem cell therapy for brain repair. *Trends Neurosci* 31:146-153, 2008
- 39) Lima C, Escada P, Pratas-Vital J, Branco C, Arcangeli CA, Lazzari G, et al. Olfactory mucosal autografts and rehabilitation for chronic traumatic spinal cord injury. *Neurorehabil Neural Repair* 24:10-22, 2010
- 40) Mackay-Sim A, Féron F, Cochrane J, Bassingthwaite L, Bayliss C, Davies W, et al. Autologous olfactory ensheathing cell transplantation in human paraplegia: a 3-year clinical trial. *Brain* 131:2376-2386, 2008
- 41) Mariano ED, Batista CM, Barbosa BJ, Marie SK, Teixeira MJ, Morgalla M, et al. Current perspectives in stem cell therapy for spinal cord repair in humans: a review of work from the past 10 years. *Arq Neuropsiquiatr* 72:451-456, 2014
- 42) McDonald JW, Liu XZ, Qu Y, Liu S, Mickey SK, Turetsky D, et al. Transplanted embryonic stem cells survive, differentiate and promote recovery in injured rat spinal cord. *Nat Med* 5:1410-1412, 1999
- 43) Mothe AJ, Tator CH. Advances in stem cell therapy for spinal cord injury. *J Clin Invest* 122:3824-3834, 2012
- 44) Murry CE, Keller G. Differentiation of embryonic stem cells to clinically relevant populations: lessons from embryonic development. *Cell* 132:661-680, 2008
- 45) Neirinckx V, Cantinieaux D, Coste C, Rogister B, Franzen R, Wislet-Gendebien S. Concise review: Spinal cord injuries: how could adult mesenchymal and neural crest stem cells take up the challenge? *Stem Cells* 32:829-843, 2014
- 46) Neuhuber B, Timothy Himes B, Shumsky JS, Gallo G, Fischer I. Axon growth and recovery of function supported by human bone marrow stromal cells in the injured spinal cord exhibit donor variations. *Brain Res* 1035:73-85, 2005
- 47) Noonan VK, Fingas M, Farry A, Baxter D, Singh A, Fehlings MG, et al. Incidence and prevalence of spinal cord injury in Canada: a national perspective. *Neuroepidemiology* 38:219-226, 2012
- 48) Nori S, Okada Y, Yasuda A, Tsuji O, Takahashi Y, Kobayashi Y, et al. Grafted human-induced pluripotent stem-cell-derived neurospheres promote motor functional recovery after spinal cord injury in mice. *Proc Natl Acad Sci U S A* 108:16825-16830, 2011
- 49) Okada S, Ishii K, Yamane J, Iwanami A, Ikegami T, Katoh H, et al. In vivo imaging of engrafted neural stem cells: its application in evaluating the optimal timing of transplantation for spinal cord injury. *FASEB J* 19:1839-1841, 2005
- 50) Ota T, Akaboshi K, Nagata M, Sonoda S, Domen K, Seki M, et al. Functional assessment of patients with spinal cord injury: measured by the motor score and the Functional Independence Measure. *Spinal Cord* 34:531-535, 1996
- 51) Park JH, Kim DY, Sung IY, Choi GH, Jeon MH, Kim KK, et al. Long-term results of spinal cord injury therapy using mesenchymal stem cells derived from bone marrow in humans. *Neurosurgery* 70:1238-1247, 2012
- 52) Parr AM, Kulbatski I, Tator CH. Transplantation of adult rat spinal cord stem/progenitor cells for spinal cord injury. *J Neurotrauma* 24:835-845, 2007
- 53) Paul C, Samdani AF, Betz RR, Fischer I, Neuhuber B. Grafting of human bone marrow stromal cells into spinal cord injury: a comparison of delivery methods. *Spine (Phila Pa 1976)* 34:328-334, 2009
- 54) Polinder S, Meerding WJ, Mulder S, Petridou E, van Beeck E.

- Assessing the burden of injury in six European countries. *Bull World Health Organ* 85:27-34, 2007
- 55) Rajasekaran S, Kanna RM, Shetty AP. Diffusion tensor imaging of the spinal cord and its clinical applications. *J Bone Joint Surg Br* 94:1024-1031, 2012
 - 56) Ryu HH, Lim JH, Byeon YE, Park JR, Seo MS, Lee YW, et al. Functional recovery and neural differentiation after transplantation of allogenic adipose-derived stem cells in a canine model of acute spinal cord injury. *J Vet Sci* 10:273-284, 2009
 - 57) Saberi H, Firouzi M, Habibi Z, Moshayedi P, Aghayan HR, Arjmand B, et al. Safety of intramedullary Schwann cell transplantation for postrehabilitation spinal cord injuries: 2-year follow-up of 33 cases. *J Neurosurg Spine* 15:515-525, 2011
 - 58) Snyder EY, Teng YD. Stem cells and spinal cord repair. *N Engl J Med* 366:1940-1942, 2012
 - 59) Sohni A, Verfaillie CM. Mesenchymal stem cells migration homing and tracking. *Stem Cells Int* 2013:130763, 2013
 - 60) Storer PD, Houle JD. betaII-tubulin and GAP 43 mRNA expression in chronically injured neurons of the red nucleus after a second spinal cord injury. *Exp Neurol* 183:537-547, 2003
 - 61) Suh HI, Min J, Choi KH, Kim SW, Kim KS, Jeon SR. Axonal regeneration effects of Wnt3a-secreting fibroblast transplantation in spinal cord-injured rats. *Acta Neurochir (Wien)* 153:1003-1010, 2011
 - 62) Tator CH. Update on the pathophysiology and pathology of acute spinal cord injury. *Brain Pathol* 5:407-413, 1995
 - 63) Tator CH. Review of treatment trials in human spinal cord injury: issues, difficulties, and recommendations. *Neurosurgery* 59:957-982; discussion 982-987, 2006
 - 64) Tator CH, Fehlings MG. Review of the secondary injury theory of acute spinal cord trauma with emphasis on vascular mechanisms. *J Neurosurg* 75:15-26, 1991
 - 65) Tobias CA, Han SS, Shumsky JS, Kim D, Tumolo M, Dhoot NO, et al. Alginate encapsulated BDNF-producing fibroblast grafts permit recovery of function after spinal cord injury in the absence of immune suppression. *J Neurotrauma* 22:138-156, 2005
 - 66) Vazin T, Freed WJ. Human embryonic stem cells: derivation, culture, and differentiation: a review. *Restor Neurol Neurosci* 28: 589-603, 2010
 - 67) Verma A, Verma N. Induced pluripotent stem cells and promises of neuroregenerative medicine. *Neurol India* 59:555-557, 2011
 - 68) Wade DT, Collin C. The Barthel ADL Index: a standard measure of physical disability? *Int Disabil Stud* 10:64-67, 1988
 - 69) Wallace M, Shelkey M. Katz Index of Independence in Activities of Daily Living (ADL). *Urol Nurs* 27:93-94, 2007
 - 70) Wyndaele M, Wyndaele JJ. Incidence, prevalence and epidemiology of spinal cord injury: what learns a worldwide literature survey? *Spinal Cord* 44:523-529, 2006
 - 71) Xu L, Yan J, Chen D, Welsh AM, Hazel T, Johe K, et al. Human neural stem cell grafts ameliorate motor neuron disease in SOD-1 transgenic rats. *Transplantation* 82:865-875, 2006
 - 72) Yoon SH, Shim YS, Park YH, Chung JK, Nam JH, Kim MO, et al. Complete spinal cord injury treatment using autologous bone marrow cell transplantation and bone marrow stimulation with granulocyte macrophage-colony stimulating factor: Phase I/II clinical trial. *Stem Cells* 25:2066-2073, 2007
 - 73) Zhu J, Zhou L, XingWu F. Tracking neural stem cells in patients with brain trauma. *N Engl J Med* 355:2376-2378, 2006
 - 74) Zhu T, Tang Q, Gao H, Shen Y, Chen L, Zhu J. Current status of cell-mediated regenerative therapies for human spinal cord injury. *Neurosci Bull* 30:671-682, 2014