

# Supravalvular aortic stenosis in adult with anomalies of aortic arch vessels and aortic regurgitation

## *Estenose aórtica supravalvar em adulto com anomalia de vasos da base e insuficiência aórtica*

Acrisio Sales Valente<sup>1</sup>, MD, PhD; Polyanna Alencar<sup>2</sup>; Alana Neiva Santos<sup>2</sup>; Roberto Augusto de Mesquita Lobo<sup>1</sup>, MD; Fernando Antônio de Mesquita<sup>1</sup>, MD; Aloyra Guedis Guimarães<sup>1</sup>, MD

DOI: 10.5935/1678-9741.20130088

RBCCV 44205-1510

### *Abstract*

The supravalvular aortic stenosis is a rare congenital heart defect being very uncommon in adults. We present a case of supravalvular aortic stenosis in adult associated with anomalies of the aortic arch vessels and aortic regurgitation, which was submitted to aortic valve replacement and arterioplasty of the ascending aorta with a good postoperative course.

**Descriptors:** Aortic stenosis, supravalvular. Aortic valve insufficiency. Adult. Subclavian artery. Carotid artery, internal.

### *Resumo*

A estenose aórtica supravalvar é uma rara cardiopatia congênita, bastante incomum em adultos. Apresentamos um caso de estenose aórtica supravalvar em adulto com anomalia de vasos do arco aórtico, já com presença de insuficiência aórtica importante, tratado com êxito por meio de plastia da aorta ascendente e troca valvar aórtica.

**Descritores:** Estenose aórtica supravalvular. Insuficiência da valva aórtica. Adulto. Artéria subclávia. Artéria carótida interna.

## INTRODUCTION

The supravalvular aortic stenosis (SAS) is the least common form of obstruction of the left ventricular outflow tract, representing 0.05% of all congenital heart disease [1-3]. It is characterized as a congenital obstruction of the ascending aorta, most commonly involving the sinotubular junction and may occur as a dysmorphism like an “hourglass” or as a diffuse hyperplasia. This malformation can occur as an aspect of Williams syndrome, being the most common cardiac defect of this syndrome [4] an autosomal dominant inherited familial form not associated with Williams syndrome and may also occur in patients with no family history and patients with homozygous familial hypercholesterolemia, occurring in up to 44% of cases in this presentation [5].

The main clinical characteristics of the SAS are syncope, dyspnea and palpitations and the incidence of these symptoms is the earliest the progression of the disease. In general, the disease is most commonly diagnosed in children, due to the presence of blow associated to the obstruction [5]. The presence of adults with untreated SAS is even more unusual. This is due to failure to detect the disease or diagnostic inaccuracy. We believe that some associated diseases, such as aortic coarctation and malformations of the great vessels may contribute to diagnostic errors or questions that often postpone the appropriate definitive treatment.

Late diagnosis of SAS may result in progressive symptoms, damage to the aortic and mitral valve, and ventricular dysfunction, which draws attention to the need for knowledge of the forms of the disease and its variations.

<sup>1</sup>. São Raimundo Hospital, Fortaleza, CE, Brazil.  
<sup>2</sup>. Christus Medical School, Fortaleza, CE, Brazil.

Correspondence address:  
Acrisio Sales Valente  
Rua Alberto Feitosa Lima 180 – apt. 602 – Guararapes – Fortaleza, CE,  
Brazil – Zip code 60810-018  
E-mail: acrisiovalente@yahoo.com

This study was carried out at the São Raimundo Hospital, Fortaleza, CE, Brazil.

Financial support: São Raimundo Hospital.

Article received on May 12<sup>th</sup>, 2012  
Article accepted on July 13<sup>th</sup>, 2013

**Abbreviations, acronyms & abbreviations**

CPB	Cardiopulmonary bypass
ACo	Aortic Coarctation
SAS	Supravalvar aortic stenosis
LVM	Left ventricle mass
BCT	Brachiocephalic trunk
LV	Left ventricle

We present a rare case of SAS in adults, not related to Williams syndrome, already with aortic valve dysfunction and anomalous origin of the great vessels, which may have favored the diagnostic difficulties.

This study was submitted to the Research Ethics Committee of the Hospital São Raimundo and approved under registration 04/2012.

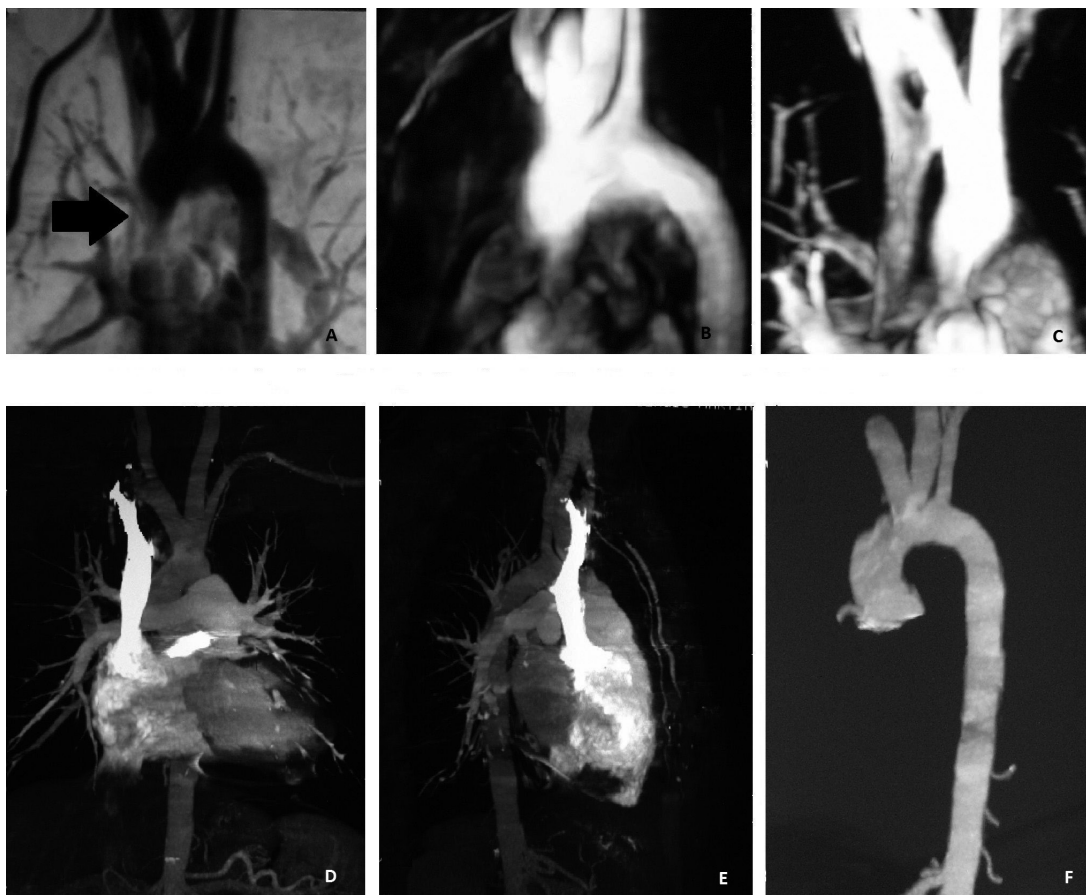
**CASE REPORT**

AST, male patient, 28 years old, with a history of heart murmur since birth, with no symptoms.

In 2006, performed an echocardiogram which showed mild left ventricular hypertrophy with left ventricular mass (LVM) of 277g, reference value 94-276g, and mild mitral and aortic regurgitation.

In 2008, performed another echocardiography, which showed mild dilation of the left ventricle (LV) with preserved function, mild mitral and moderate aortic regurgitation. Aortic coarctation (ACo) with peak systolic gradient of 49 mmHg was suggested.

Although asymptomatic, the patient did not seek medical treatment assistance, performing new echocardiogram the following year, being evidenced increased LVM of 293g, normal ventricular function, mild mitral regurgitation and moderate aortic coarctation and suggestive sign of the left subclavian artery, with gradient 49 mmHg.



*Fig 1 - CT angiography. Preoperative angiography. A: severe supravalvular aortic stenosis. B: anomalies of the great vessels with left common carotid artery originating from the BCT and hypoplastic left subclavian artery. C: Severe supravalvular aortic stenosis in another incidence. Post-operative images. D and E: good opening towards systemic output. F: external aspect of the aorta.*

In 2010, the patient came to our Service. A new echocardiogram was performed which showed: mild aortic regurgitation, aortic coarctation with a peak systolic gradient of 45 mmHg, located below the left subclavian artery, and LV concentric hypertrophy of mild degree.

The patient was asymptomatic, referring fatigue on exertion and occasional syncope. On physical examination, the patient was in good general condition, cardiac auscultation with regular cardiac rhythm with two clicks, normal heart sounds, presence of more audible systolic murmur in the aortic area, radiating to the neck. The presence of pulses in the lower and upper differential pressure between upper limbs called our attention, with higher right pressure. Then, we questioned the diagnosis of aortic coarctation.

Then, we performed angiography, which showed supravalvular aortic stenosis, severe aortic valve insufficiency and hypoplasia of the left subclavian artery with origin of the left carotid artery from the brachiocephalic trunk (BCT). For greater morphological detail, was also performed chest angiography, which showed patent ascending aorta, and showed significant supravalvular stenosis, 2.2 cm long, lying 2 cm from the emergence of the BCT (Figure 1).

Surgical treatment was indicated and performed in 2011.

### Surgical technique

The patient underwent surgery for expansion of the ascending aorta and aortic valve treatment. Surgery was performed with cardiopulmonary bypass (CPB), bicaval cannulation and ascending aorta, systemic and topical moderate hypothermia, aortic cross-clamping and administration of intermittent hypothermic blood cardioplegic solution every 30 minutes. The aortotomy was performed in inverted "Y", extending to the non-coronary sinus and the right coronary. The great thickening of the aortic wall drew attention. The valve had become thickened and deformed, with the presence of deposits of fat and calcium plaques.

We opted for the aortic valve replacement with a mechanical double-leaflet prosthesis type number 23 and enlargement of the ascending aorta with single bifurcated patch of bovine pericardium, extending from the ascending aorta to the right coronary and non-coronary sinus. It is important that the right coronary ostium is carefully viewed. The pericardial patch should be large enough to allow certain bulging in the region of the open sinuses of Valsalva, simulating the natural anatomical aspect. In our experience, the cropped patch seems to always be a little bigger than necessary.

After suturing, the final appearance is quite anatomical (Figure 2). Biological glue was used to enhance hemostasis. After rewarming, the patient was removed from CPB without difficulty and surgery was fully performed traditionally. The surgery was uneventful in 3 hours and 30 minutes, with 80 minutes of CPB and 40 minutes of aortic clamping.

### Evolution

The patient was extubated in the immediate postoperative period and remained three days in the intensive care unit and total hospital stay of seven days. In return fifteen days after the surgery, the patient was asymptomatic, in good recovery. With two months of surgery, control echocardiogram was performed, which showed: LVM 260g, cardiac chambers of normal dimensions, metallic prosthesis in the aortic position with good handling of its leaflets, the Doppler peak systolic gradient of 37 mmHg and mean of 21 mmHg with minimal central regurgitation.

Angiography showed patent ascending aorta, preserved gauge, showing mild irregularity of the contours in the cranial aspect of the distal segment, before the emergence of BCT (Figure 1). With six months after surgery, the patient remained asymptomatic and the echocardiogram showed LVM of 230g, normal cardiac cavities, prosthesis with peak systolic gradient of 25 mmHg and a minimum central "escape".

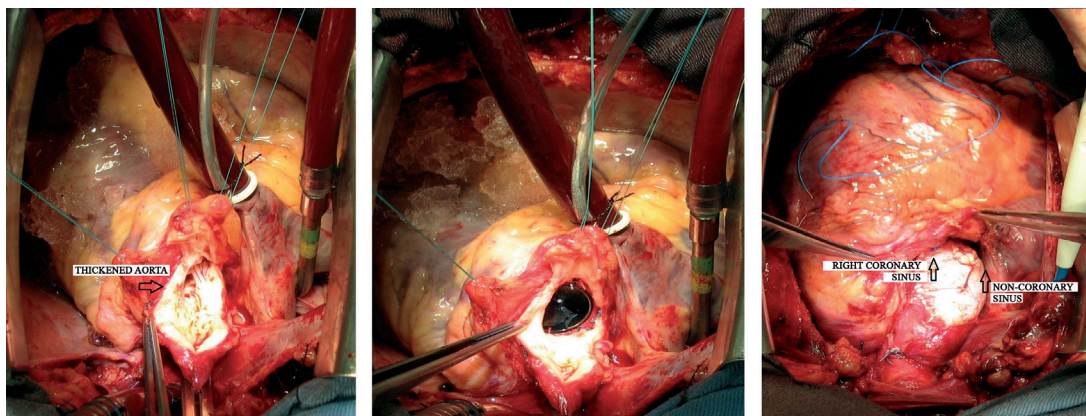


Fig. 2 - Images from the surgery. Aortotomy in inverted "Y", thickened aorta. Mechanical aortic prosthesis positioned. Final external appearance, with a pericardial patch extending to the right coronary and non-coronary sinus.

DISCUSSION

The SAS is an uncommon congenital heart disease and should be diagnosed early for surgical indication before its effects compromise other structures and, importantly, aortic valve and LV. When more commonly diagnosed in childhood, it allows early treatment planning and thus avoids major structural impairment of the heart. The coronary arteries, due to high pulse pressure which they are subjected under this condition can also undergo structural changes as described by Peterson et al. [6]. Thus, for all these peculiarities, invasive therapy in the SAS should be earlier than in aortic stenosis [5].

Since the initial reports of Usher et al. [7] and Weyman et al. [8], echocardiography has been the initial diagnostic examination in most cases. Some aspects related to abnormalities of the great vessels, poorly assessed by examination, may impair the diagnosis and make other complementary image tests necessary. The insidious symptoms, associated with diagnostic doubts along the clinical investigation transmitted to the patient, favors his more relaxed behavior, insecure and rejection of closer monitoring, delaying diagnosis, as reported to us in an interview later.

We believe that the hypoplastic subclavian artery caused false impression of aortic coarctation, described in various examinations performed by different operators. The same finest subclavian artery was also responsible for the differentiation of pulse and pressure between the upper limbs (high blood pressure in right arm in relation to the left), confusing the examiners. The diagnostic uncertainty should always raise the employment of more complex tests. The idea of coarctation raised such questioning, considering that the patient had lower limb pulses. Thus, we chose to perform angiography also to assess coronary arteries and CT.

We believed that progressive aortic insufficiency was related to obstruction immediately after the valve, causing its abnormal turbulence. Echocardiography suggested thickened valve with poor coaptation. The same impression we did not had of the mitral valve, which appeared thin at echocardiography with mild prolapse of its brochure. The patient also had begun to show symptoms, which led us to decide the immediate surgical treatment.

Surgical planning, considering that both carotid arteries leaves emerge from common trunk, we concerned about the possible need to cannulate the BCT through a tubular graft, what we have done regularly when we need to work freely in the ascending aorta and aortic arch. We feared that some ostium was not well perfused. However, if necessary, we may cannulate the femoral artery. During surgery, angiography confirmed the impression that there was space for safe cannulation of the ascending aorta before BCT, which was performed.

For the correction of the stenotic aortic segment,

techniques without the use of prosthetic material are attractive, especially in children, as suggested by Souza et al. [9]. In adult patients, the reduced elasticity of the aorta and stenotic segments sometimes more extensive has made us opt for enlargements using patches, which, in our experience, are more simple and fast techniques, and effective, especially considering that there are no adults in the concern with growth. In this particular case, after aortotomy, the valve seemed inadequate to the plastic, making us choose to replacement using a mechanical prosthesis, which was previously discussed with the patient.

In continuation, the anatomical aspect of the aorta, with apparently normal left coronary sinus, made us conclude that the expansion in inverted “Y” would be an excellent option in this case. This technique was originally described by Doty et al. [10] for moderate or severe supravalvular aortic stenosis not involving significant narrowing of the left coronary sinus of Valsalva, as in the reported case. In this case, we use large bovine pericardium patch. It could also be used a polytetrafluoroethylene patch, with the advantage of not presenting calcification, but have no such material available.

We believe that one should not dry the curvature of the left coronary sinus in order to leave the suture line straight at that point. Maintaining the natural design, or that is, the vertices of the inverted “Y”, while leaving a little longer suture line, helps shape the enlargement patch after release of aortic clamping. The final touch with biological glue has been a good additional factor in the hemostatic arsenal and we have used regularly.

The patient developed well after surgery. The earlier surgery might spare him the replacement of the native valve, but fortunately he had no ventricular dysfunction. The echocardiographic assessment also showed the satisfactory outcome of the surgery.

Authors' roles & responsibilities	
ASV	Study design, surgeon of the case supervisor
PA	Survey records, literature review, references research
ANS	Survey records, literature review, references research
RAML	Surgeon of the case, co-advisor
FAM	Surgeon of the case, co-advisor
AGG	Echocardiographer and cardiologist of the case, material collection

REFERENCES

1. Heper G, Kose S, Kilic A, Amasyali B, Isik E. Left ventricular apical aneurysm as a consequence of diffuse type congenital nonfamilial supravalvular aortic stenosis in a 30-year-old female. *Int Heart J.* 2005;46(1):153-9.



2. Micale L, Turturo MG, Fusco C, Augello B, Jurado LA, Izzi C, et al. Identification and characterization of seven novel mutations of elastin gene in a cohort of patients affected by supravalvular aortic stenosis. *Eur J Hum Genet.* 2010;18(3):317-23.
3. Bonini RCA, Palazzi EM, Chaccur P, Sousa LCB. Correção cirúrgica da estenose aórtica supravalvar com modificação da técnica de Sousa. *Rev Bras Cir Cardiovasc.* 2010;25(2):253-6.
4. Sugayama SMM, Moisés RL, Wagenfur J, Ikari MN, Abe KT, Leone C et al. Síndrome de Williams-Beuren. Anomalias cardiovasculares em 20 pacientes diagnosticados pela hibridização in situ por fluorescência. *Arq Bras Cardiol.* 2003;81(5):462-7.
5. Valente AS, Cirino CMF. Cardiopatia congênita no adulto. In: Croti UA, Mattos SS, Pinto Jr. VC, Aiello VD, eds. *Cardiologia e cirurgia cardiovascular pediátrica.* São Paulo: Roca; 2008.
6. Peterson TA, Todd DB, Edwards JE. Supravalvular aortic stenosis. *J Thorac Cardiovasc Surg.* 1965;50(5):734-41.
7. Usher BW, Goulden D, Murgu JP. Echocardiographic detection of supravalvular aortic stenosis. *Circulation.* 1974;49(6):1257-9.
8. Weyman AE, Caldwell RL, Hurwitz RA, Girod DA, Dillon JC, Feigenbaum H, et al. Cross-sectional echocardiographic detection of aortic obstruction. 2. Coarctation of the aorta. *Circulation.* 1978;57(3):498-502.
9. Souza LCB, Chaccur P, Dinkhuysen JJ, Fontes MA, Fontes VF, Abdulmassih Neto C, et al. Modificação técnica na cirurgia da estenose aórtica supravalvar. *Rev Bras Cir Cardiovasc* 1992;7(2):121-6.
10. Doty DB, Polansky DB, Jenson CB. Supravalvular aortic stenosis. Repair by extended aortoplasty. *J Thorac Cardiovasc Surg.* 1977;74(3):362-71.