



Educational Case: Smooth Muscle Tumors of the Uterus

Academic Pathology: Volume 7
DOI: 10.1177/2374289520932285
journals.sagepub.com/home/apc
© The Author(s) 2020



Xiomara Brioso Rubio, BS¹, Stacy G. Beal, MD¹ ,
Julia A. Ross, MD¹ and Jesse Kresak, MD¹

The following fictional case is intended as a learning tool within the Pathology Competencies for Medical Education (PCME), a set of national standards for teaching pathology. These are divided into three basic competencies: Disease Mechanisms and Processes, Organ System Pathology, and Diagnostic Medicine and Therapeutic Pathology. For additional information, and a full list of learning objectives for all three competencies, see <http://journals.sagepub.com/doi/10.1177/2374289517715040>.¹

Keywords

pathology competencies, organ system pathology, female reproductive uterus, uterine neoplasia, smooth muscle tumors of the uterus, leiomyoma, fibroid, leiomyosarcoma

Received May 30, 2019. Received revised February 17, 2020. Accepted for publication May 10, 2020.

Primary Objective

Objective FU1.4: Smooth Muscle Tumors of the Uterus. Discuss the natural history, clinical presentation, and management of benign smooth muscle tumors of the uterus and the risk for malignant transformation.

Competency 2: Organ System Pathology; Topic FU: Female reproductive: uterus, cervix, and vagina; Learning Goal 1: Uterine Neoplasia.

Secondary Objective

Objective N3.1: Morphologic Features of Neoplasia. Describe the essential morphologic features of neoplasms and indicate how these can be used to diagnose, classify, and predict biological behavior of cancers.

Competency 1: Disease Mechanisms and Processes; Topic N: Neoplasia; Learning Goal 3: Characteristics of Neoplasia.

Patient Presentation

A 42-year-old African American woman presents to her gynecologist with concerns about increased heaviness of her menses

and a feeling of pelvic fullness. Menses occur every 28 days and last for 7 days. She has no intercycle bleeding. She is otherwise healthy. Her routine pap smears have been normal. She does not report a family history of ovarian, uterine, or cervical cancer.

Diagnostic Findings, Part I

Bimanual pelvic examination shows a 16-week sized, irregular, anteverted, mobile uterus. The remaining physical examination is unremarkable.

¹ Department of Pathology, Immunology and Laboratory Medicine, University of Florida College of Medicine, Gainesville, FL, USA

Corresponding Author:

Xiomara Brioso Rubio, Department of Pathology, Immunology and Laboratory Medicine, University of Florida College of Medicine, 1600 SW Archer Road, Gainesville, FL 32610, USA.

Email: xiomarabrioso@ufl.edu



Table 1. Differential Diagnosis of an Irregular Enlarged Uterus.

Differential Diagnosis	Pathophysiology	Histology	Presentation
Leiomyoma	<ul style="list-style-type: none"> Abnormal proliferation of smooth muscle cells 	Elongated spindle cells with eosinophilic cytoplasm and cigar-shaped central nuclei arranged in intersecting fascicles	Presentation is based on location of leiomyoma but includes: <ul style="list-style-type: none"> Dysmenorrhea Menorrhagia Pelvic fullness Bowel or bladder abnormalities Infertility⁴
Adenomyosis	<ul style="list-style-type: none"> Endometrial tissue located within the myometrium² 	Endometrial glands and stroma seen within the smooth muscle (myometrium)	<ul style="list-style-type: none"> Presents in this age-group with heavy bleeding during menses Uniformly enlarged uterus² Irregular bleeding Tend to be small and protrude within endometrial cavity without distorting the uterine shape²
Endometrial polyp	<ul style="list-style-type: none"> Endometrial hyperplasia² 	Polypoid fragments of endometrium with at least 2 of 3 classic features: fibrous stroma, cystically dilated glands, thick-walled vessels	<ul style="list-style-type: none"> Tend to be small and protrude within endometrial cavity without distorting the uterine shape²
Endometrial carcinoma	<ul style="list-style-type: none"> Endometrial hyperplasia and atypia that may or may not be driven by estrogen² Many types exist including adenocarcinoma, endometrioid, mucinous² 	Crowded, back-to-back glands with limited intervening stroma	<ul style="list-style-type: none"> Typically presents in postmenopausal women Heavy bleeding, not always related to menses Irregularly enlarged uterus Ultrasound demonstrates a thickened endometrium
Leiomyosarcomas	<ul style="list-style-type: none"> Malignant smooth muscle tumor Spindle cells are noted, but may be associated with epithelioid or myxoid characteristics³ 	Nuclear atypia, coagulative type necrosis, increased mitoses	<ul style="list-style-type: none"> May be indistinguishable from leiomyomas by clinical presentation (bleeding and abdominal/pelvic pain) and imaging Diagnosis tends to occur after histological analysis³

Question/Discussion Points, Part 1

What Is the Differential Diagnosis of an Irregular, Enlarged Uterus?

Differential diagnosis can include the following: adenomyosis, endometrial polyp, leiomyoma, and uterine malignancies, such as leiomyosarcoma (see Table 1). Extraneous endometrial tissue can be found within the myometrium, also known as adenomyosis. Polyps result from hyperplastic growth of the endometrium. Leiomyomas are benign smooth muscle growths while leiomyosarcomas are malignant.^{2,3}

Diagnostic Findings, Part 2

The patient's ultrasound is shown in Figure 1.

Question /Discussion Points, Part 2

How Would You Describe the Findings of the Ultrasound (Figure 1)?

Transvaginal ultrasound demonstrates a single echogenic, well-defined intramural mass measuring approximately 5 cm.

On other ultrasound views, not shown on this manuscript, more hypoechoic and submucosal masses were noted, and bilateral adnexa demonstrated no abnormalities.

What Is Your Working Diagnosis?

Leiomyoma, also known as a fibroid, is the most likely diagnosis, based on the patient's race and age, presenting complaints of

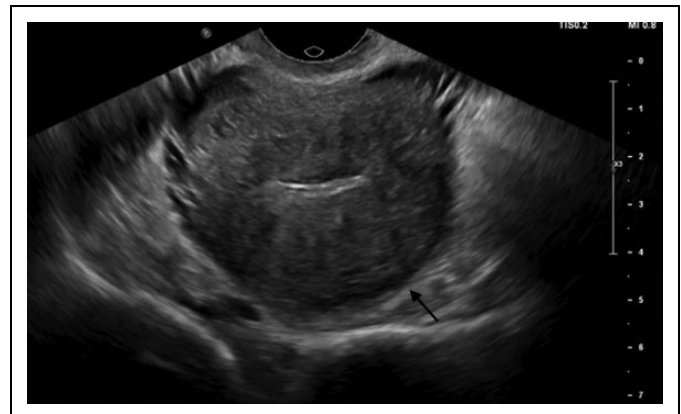


Figure 1. Transvaginal ultrasound showing a single echogenic, well-defined intramural mass (arrow).

heavy bleeding and pelvic fullness, examination revealing an enlarged but irregular uterus, and ultrasound findings.

What Is the Clinical Presentation of Leiomyomas?

The presentation is varied and patient-dependent, guided by the size, location, and amount of masses. If detected on physical examination, they are described as solid, mobile masses with irregular contours.² The most common complaints are of dysmenorrhea, or painful bleeding, and menorrhagia, or heavy bleeding. Pelvic fullness or compression of the bladder or rectum, leading to constipation or urinary urgency or retention, can occur in patients with subserosal or large intramural leiomyomas. Infertility has also been noted as a complaint,

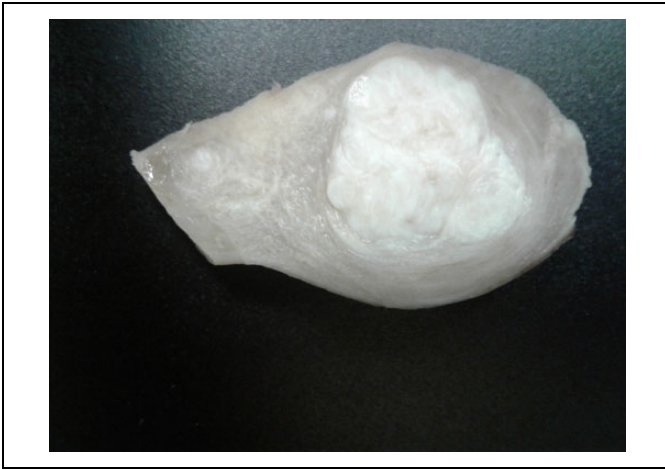

Figure 2. Gross image of a leiomyomata. Well-circumscribed, white whorled nodule.

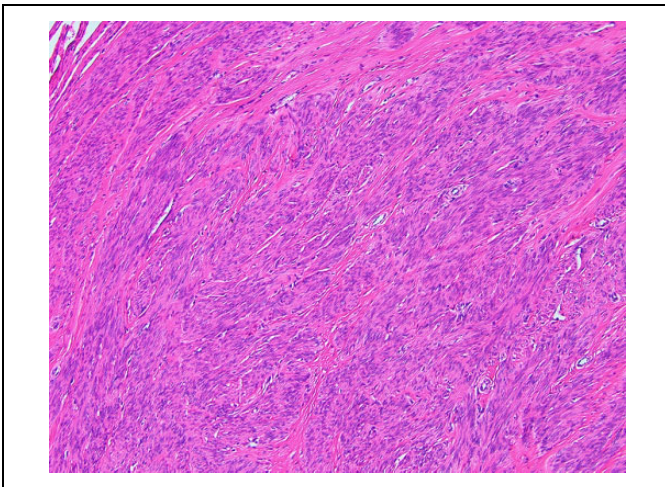


Figure 3. Microscopic image of leiomyoma. Smooth muscle cells in fascicular bundles with bland nuclei and absence of mitotic figures or necrosis. Hematoxylin and eosin stained section at $\times 100$ magnification.

especially in those with submucosal leiomyomas. It is important to note that some women remain asymptomatic.^{4,5}

On gross inspection, leiomyomas are rubbery, well-circumscribed, widely variable in size, and are usually white with a whorled appearance (Figure 2). Color of the mass may change depending on its composition, such as in yellow or tan if adipocytes are present, or due to changes in its blood supply, such as red in a pregnant patient.³ Leiomyomas are characterized by their location: subserosal, intramural, submucosal.

What Is the Natural History of Leiomyomas?

Uterine leiomyomas arise from the myometrium. They are found in reproductive-aged women, as they respond to the action of estradiol and progesterone. Mature smooth muscle cells, under estrogen and progesterone influence, exert a

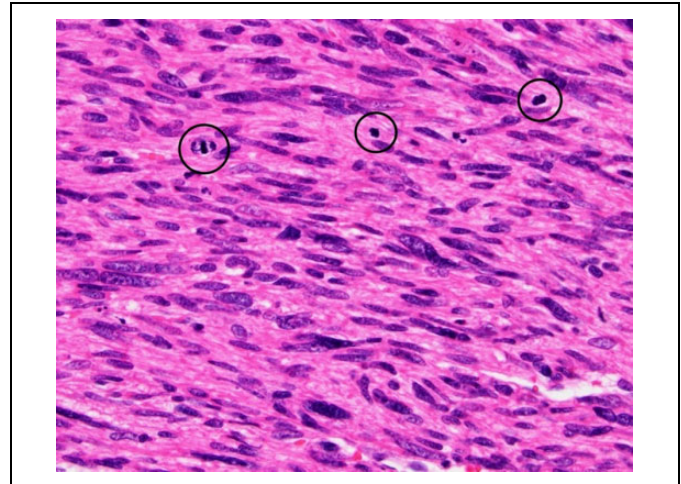


Figure 4. Leiomyosarcoma. Cells with cigar-shaped nuclei and at least moderate nuclear atypia are seen with numerous mitotic figures evident (circles). Tumor cells necrosis was seen in other areas of the tumor (not pictured). Immunostains for smooth-muscle actin (SMA) and desmin were positive in the pictured cells, supporting the smooth muscle origin. Hematoxylin and eosin stained section at $\times 400$ magnification.

paracrine effect on immature cells resulting in their proliferation and creation of the smooth muscle mass.⁶

Each leiomyoma has been noted to grow at its own rate. They have also been shown to undergo periods of spontaneous growth and/or regression, straying away from the idea that they grow in a linear manner during a woman's reproductive life. In pregnant women, leiomyomas were noted to maintain this non-linear growth, with the biggest size increase noted within the first trimester. With decrease of sex steroid hormones, they regress after menopause.⁷

What Is the Histologic Appearance of a Leiomyoma?

Histology demonstrates a well-circumscribed lesion composed of elongated spindle cells with eosinophilic cytoplasm and cigar-shaped central nuclei arranged in intersecting fascicles (Figure 3). Mitotic figures are rare. Occasionally infarct-type necrosis, as opposed to coagulative-type tumor cell necrosis, is seen.³ Presence of tumor cell necrosis should trigger a search for increased mitotic figures and leiomyosarcoma should be considered (Figure 4). It should be noted, there are uterine smooth muscle tumors that fall into a category between benign leiomyoma and malignant leiomyosarcoma. The tumors, called smooth muscle tumor of uncertain malignant potential, look clinically and grossly like leiomyoma; however, they contain increased mitotic activity and mild nuclear atypia that falls short of a designation of malignant.

What Treatments Can We Offer Patients With Leiomyomata Uteri?

There are many options for the management of fibroids, both medical and surgical (see Tables 2 and 3). Medical options,

Table 2. Medical Treatment Options for Leiomyoma.

Treatment	Description
Nonsteroidal anti-inflammatory drugs (NSAIDs) Oral contraceptive pills (OCPs)	<ul style="list-style-type: none"> • First-line treatment of dysmenorrhea and heavy bleeding • Decreases heavy bleeding • Provides contraception
Levonorgestrel intrauterine device	<ul style="list-style-type: none"> • Decreases heavy bleeding • Provides contraception for 5 years
Gonadotropin releasing hormones (GnRH) agonists	<ul style="list-style-type: none"> • Might not be amenable for women with heavily distorted intrauterine cavities • Continuous administration inhibits the hypothalamic–pituitary–ovarian axis resulting in a decrease of fibroid size • May be used as a bridge treatment for women near menopause • May be used preoperatively to improve hemoglobin levels and decrease fibroid size • Fibroid size increases with cessation of treatment
Tranexamic acid	<ul style="list-style-type: none"> • Antifibrinolytic • Decreases heavy bleeding
Others: Selective estrogen receptor modulators (SERMs), mifepristone, ulipristal acetate, aromatase inhibitors	

Table 3. Surgical Treatment Options for Leiomyoma.

Treatment	Description
Myomectomy	<ul style="list-style-type: none"> • Removal of the leiomyomas, leaving the uterus behind • Best suited for submucosal fibroids with easy access via a hysteroscope
Uterine artery embolization (UAE)	<ul style="list-style-type: none"> • Least invasive • Results in decreased blood supply to the leiomyoma, consequently decreasing its size
Hysterectomy	<ul style="list-style-type: none"> • Only definitive treatment • Uterus and fibroid size determine approach: vaginal, abdominal, laparoscopic

such as nonsteroidal anti-inflammatories, oral contraception, tranexamic acid, and levonorgestrel intrauterine devices, can be used to decrease the bleeding. Other medical treatments such as gonadotropin releasing hormones agonists and selective estrogen receptor modulators may decrease the size of the leiomyomas in preparation for surgical management. Surgical options include removal of the leiomyoma or removal of the whole uterus as well as decreasing the blood supply to the leiomyomas via uterine artery embolization.

It is important to tailor the treatment to the patient's needs, including permanent resolution of symptoms and fertility wishes.^{4,5}

What Is a Leiomyosarcoma?

A leiomyosarcoma is a malignant smooth muscle tumor. Grossly, they appear as large, fleshy masses that are irregularly shaped with visible hemorrhage or necrosis.³ Histologic evaluation shows cells with cigar-shaped nuclei, nuclear atypia, and numerous mitotic figures (Figure 4). Necrosis and hemorrhage can often be observed. Immunostains for SMA and desmin can be used to support the smooth muscle origin of a leiomyosarcoma.

What Is the Risk for Malignant Transformation of a Leiomyoma?

Leiomyosarcoma is an uncommon diagnosis thought to occur sporadically; that is to say, leiomyosarcoma does not arise from a preexisting leiomyoma. However, there are reported cases contradicting this argument. Alterations in chromosome 1, such as loss of the short arm or mutations resulting in abnormal proteins, have been identified in these rare instances. Overall, the incidence of leiomyosarcoma has been noted to increase in those who are on tamoxifen treatment for breast cancer.^{3,8,9}

Teaching Points

- Leiomyomas are smooth muscle neoplasms which are commonly found in the uterus of reproductive age women. Masses grow at their own rate and regress after menopause.
- Uterine leiomyomas can be in the following locations: submucosal, subserosal, or intramural.
- The clinical presentation of leiomyomas varies per patient and includes an occult presentation, heavy bleeding, pelvic pain/fullness, and bowel and/or bladder symptoms.
- The diagnosis is made via a thorough history and physical examination, with assistance of ultrasound imaging. Pathologic evaluation of the mass gives a definitive diagnosis.
- Grossly, leiomyomas appear as white, well-circumscribed masses. On histology, spindle cells arranged in intersecting fascicles are appreciated.
- Treatment approach is patient dependent. Multiple options can be used and include medical or surgical treatment.
- Leiomyosarcomas are malignant smooth muscle masses that mostly arise de novo.


Declaration of Conflicting Interests

The author(s) declared no potential conflicts of interest with respect to the research, authorship, and/or publication of this article.

Funding

The author(s) disclosed receipt of the following financial support for the research, authorship, and/or publication of this article: The article processing fee for this article was funded by an Open Access Award given by the Society of '67, which supports the mission of the Association of Pathology Chairs to produce the next generation of outstanding investigators and educational scholars in the field of pathology. This award helps to promote the publication of high-quality original scholarship in *Academic Pathology* by authors at an early stage of academic development.

ORCID iD

Stacy G. Beal  <https://orcid.org/0000-0003-0862-4240>

References

1. Knollmann-Ritschel BEC, Regula DP, Borowitz MJ, Conran R, Prystowsky MB. Pathology competencies for medical education and educational cases. *Acad Pathol*. 2017;4. doi:10.1177/2374289517715040
2. Beckmann CRB, Herbert W, Laube D, Ling F, Smith R. *Obstetrics and Gynecology*. 7th ed. Lippincott, Williams & Wilkins; 2014.
3. Kurman RJ, Carcangiu ML, Herrington CS, Young RH. *WHO Classification of Tumours of Female Reproductive Organs*. Vol. 6. 4th ed. WHO Series on Histological and Genetic Typing of Human Tumours. International Agency for Research on Cancer/World Health Organization; 2014.
4. De La Cruz MS, Buchanan EM. Uterine fibroids: diagnosis and treatment. *Am Fam Physician*. 2017;95:100-107.
5. Drayer SM, Catherino WH. Prevalence, morbidity, and current medical management of uterine leiomyomas. *Int J Gynaecol Obstet*. 2015;131:117-122.
6. Reis FM, Bloise E, Ortega-Carvalho TM. Hormones and pathogenesis of uterine fibroids. *Best Pract Res Clin Obstet Gynaecol*. 2016;34:13-24.
7. Ghosh S, Naftalin J, Imrie R, Hoo WL. Natural history of uterine fibroids: a radiological perspective. *Curr Obstet Gynecol Rep*. 2018;7:117-121.
8. Hodge JC, Morton CC. Genetic heterogeneity among uterine leiomyomata: insights into malignant progression. *Hum Mol Genet*. 2007;16:R7-13. doi:10.1093/hmg/ddm043
9. Verit FF, Yucel O. Endometriosis, leiomyoma and adenomyosis: the risk of gynecologic malignancy. *Asian Pac J Cancer Prev*. 2013;14:5589-5597.