







Eastchester clapping sign and networks related to spatial attention

Sinal de palmas de Eastchester e redes relacionadas à atenção espacial

Gustavo José Luvizutto¹  Gabriel Pereira Braga²  Luiz Eduardo Gomes Garcia Betting³ 
Rodrigo Bazan³ 

¹ Universidade Federal do Triângulo Mineiro, Departamento de Fisioterapia Aplicada, Uberaba MG, Brazil.

² Universidade Federal do Mato Grosso do Sul, Hospital Universitário Maria Aparecida Pedrossian, Campo Grande MS, Brazil.

³ Universidade Estadual Paulista Júlio de Mesquita Filho, Faculdade de Medicina de Botucatu, Departamento de Neurologia, Psicologia e Psiquiatria, Botucatu SP, Brazil.

Address for correspondence Gustavo José Luvizutto (e-mail: gluvizutto@gmail.com).

Arq. Neuropsiquiatr. 2022;80(10):1077–1078.

A 53-year-old right-handed man developed left hemiparesis (of grade 2 in the Medical Research Council Scale) and right head deviation due to ischemic stroke. When instructed to clap his hands, he brought his right hand to the midline and searched for the other hand (► **Video 1**). Fluid-attenuated inversion recovery (FLAIR) magnetic resonance imaging (MRI) scans, the unilateral spatial neglect (USN) test, and the blood-oxygen-level-dependent (BOLD) functional magnetic resonance imaging (fMRI) study are presented in ► **Figure 1**.

video.mov Online content including video sequences viewable at: <https://www.thieme-connect.com/products/ejournals/html/10.1055/s-0042-1758394>.

The Eastchester clapping sign provides evidence of USN phenomena.^{1,2} Frequently, patients with USN can ignore problems with the affected limb. This patient presented bilateral activation in the networks related to spatial attention (mainly parietal posterior lobes), and fMRI patterns indicated maladaptive plasticity.^{3,4}

Video 1



Eastchester clapping sign (ECS-1 = searching in the contralateral hemispace for the other hand). In the video, the neurologist dictates the following command to the patient: “Please clap your hands.”

Link: <https://www.arquivosdeneuropsiquiatria.org/wp-content/uploads/2022/04/ANP-2022.0020->

Authors' Contributions

GJL, GPB, LEGGB, RB: substantial contributions to the conception or design of the work, acquisition, analysis, and interpretation of data, drafting and critical revision of the manuscript for important intellectual content, and final approval of the version to be published.

received
January 26, 2022
accepted
March 29, 2022

DOI <https://doi.org/10.1055/s-0042-1758394>.
ISSN 0004-282X.

© 2022. Academia Brasileira de Neurologia. All rights reserved. This is an open access article published by Thieme under the terms of the Creative Commons Attribution-NonDerivative-NonCommercial-License, permitting copying and reproduction so long as the original work is given appropriate credit. Contents may not be used for commercial purposes, or adapted, remixed, transformed or built upon. (<https://creativecommons.org/licenses/by-nc-nd/4.0/>)
Thieme Revinter Publicações Ltda., Rua do Matoso 170, Rio de Janeiro, RJ, CEP 20270-135, Brazil

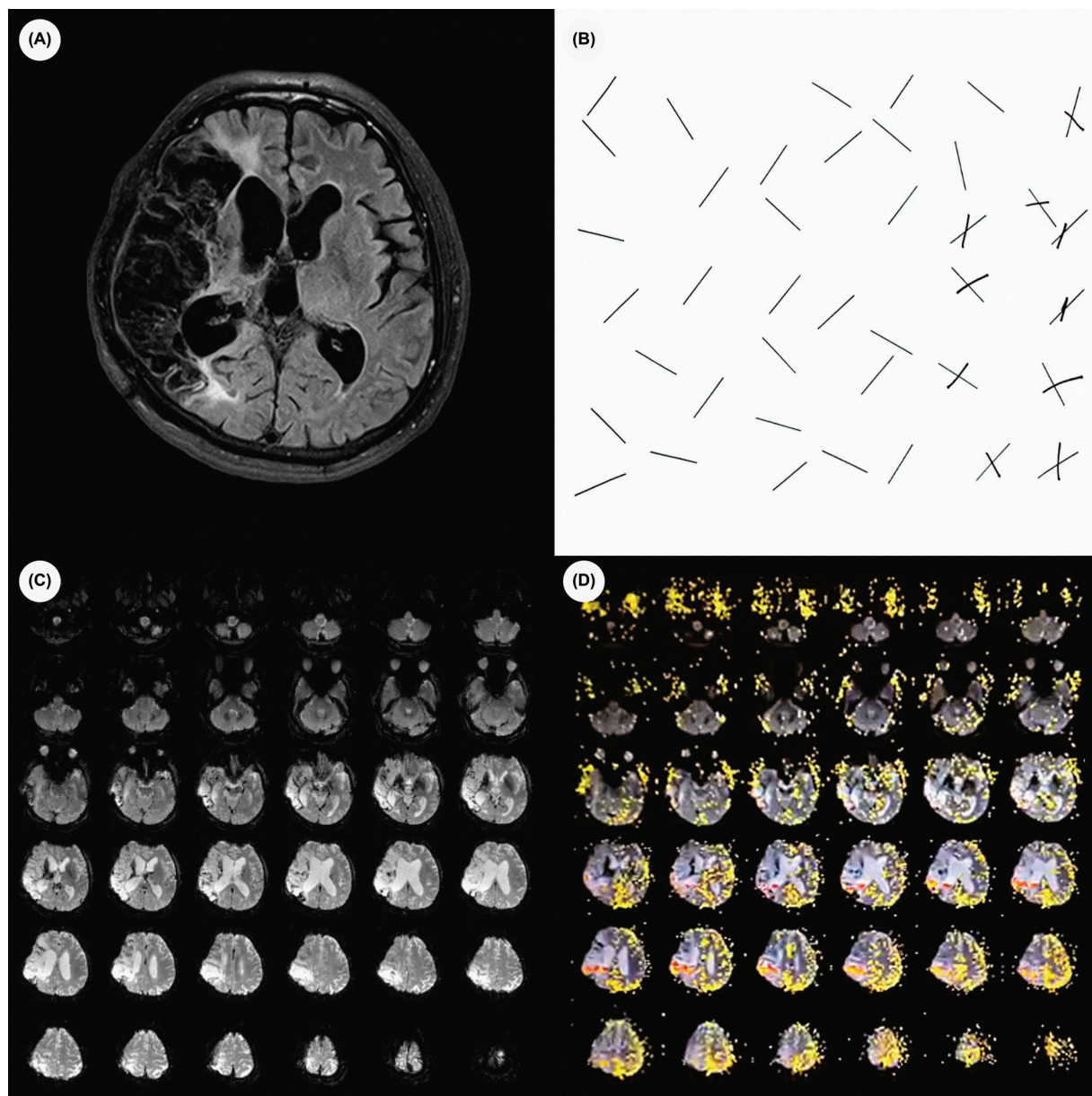


Figure 1 (A) FLAIR MRI scan showing extensive ischemic stroke in the right hemisphere; (B) line cancellation test (Albert test) indicating presence of unilateral spatial neglect; (C) BOLD fMRI study at rest showing no activation; (D) BOLD fMRI study showing bilateral activation of the parietal cortex during sensory stimulation (face-hand test).

Conflict of Interest

The authors have no conflict of interests to declare.

References

- 1 Ostrow LW, Llinás RH. Eastchester clapping sign: a novel test of parietal neglect. *Ann Neurol* 2009;66(01):114–117
- 2 Mukerji SS, Bevers MB, Prasad S. Eastchester clapping sign. *Neurol Clin Pract* 2014;4(02):178–179
- 3 Corbetta M, Shulman GL. Spatial neglect and attention networks. *Annu Rev Neurosci* 2011;34:569–599
- 4 Rema V, Ebner FF. Lesions of mature barrel field cortex interfere with sensory processing and plasticity in connected areas of the contralateral hemisphere. *J Neurosci* 2003;23(32):10378–10387