

# Acute concentrated phenol dermal burns: Complications and management

Tapan Jayantilal Parikh

## Abstract

Phenol burns can result in multiple organ failure. This is a case report of acute severe phenol dermal burn after accidental splash of 94% phenol on 35-year-old patient's body who was brought to hospital after 90 min of exposure. Decontamination was done with high-density water and glycerol. Early complications in form of metabolic acidosis and acute renal failure required hemodialysis. Extensive protein denaturation was managed with IV albumin and high protein diet. Patient also developed pleural effusion and acute respiratory distress syndrome, but these were successfully managed by intercostal drain tube insertion and noninvasive ventilation. The patient survived after multiple organ failures and widespread burns despite the fact that it has been observed that outcome of phenol burns with >60<sup>2</sup> inches of skin affected or two or more organs failure involving renal system is nearly fatal.

**Keywords:** Acute respiratory distress syndrome, phenol burns, protein denaturation, renal failure

## Access this article online

Website: [www.ijccm.org](http://www.ijccm.org)

DOI: 10.4103/0972-5229.156481

Quick Response Code:



## Introduction

Concentrated phenol may cause second or third degree burns due to its caustic and defatting properties.<sup>[1]</sup> Deaths have been reported if 25% or more of body surface area is involved. A high and rapid penetration through skin necessitates the thorough removal of all the phenol particles on the body surface as soon as possible.

This is the case report of a 35-year-old male, who presented with 37% burns by highly concentrated phenol (94%). This is unique case in regard to burns with high concentration of phenol involving wide area of skin and management of the patient was compounded by multiple organ failure and the fact that the patient presented to the hospital 1.5 h after the exposure.

## Case Report

A 35-year-old truck driver (height 177 cm, weight 80 kg),

had an accidental splash of phenol (94%). He was brought to hospital 90 min after the incident. On presentation, the patient was conscious with skin discoloration, hypertension (150/96 mm Hg) and myoclonic jerks in the left thigh. High-density shower of warm water was given for 20 min which resulted in desquamation of >80% of the burnt skin. Eye irrigation was performed, and Glycerol was applied for decontamination. The 2<sup>nd</sup> degree burns were observed all over except in the lower limb above the knee where 3<sup>rd</sup> degree burns were present.

Blood and urine investigations, chest X-rays and electrocardiography, were normal except HCO<sub>3</sub> that was 12 mmol/L. Sodium bicarbonate was given intravenously. After 24 h, urine output reduced to <30 ml/h. A volume of 1000 ml bolus fluid was administered intravenously and serum creatinine, sodium, potassium, creatine phosphokinase total and protein were found to be 5 mg/dl, 145 mmol/L, 5.42 mmol/L, 87 units/L, 5.10 g/dl respectively. Oral liquid and protein supplements had already been started on the 2<sup>nd</sup> day. As urine output failed to rise, injection furosemide (40 mg) was administered intravenously, and the urine output increased for 5–6 h, but subsequently decreased. So, the dose was increased to thrice a day. Opioids were given as the

### From:

Department of Anaesthesiology and Intensive Care, Satyamev Hospital, Ahmedabad, Gujarat, India

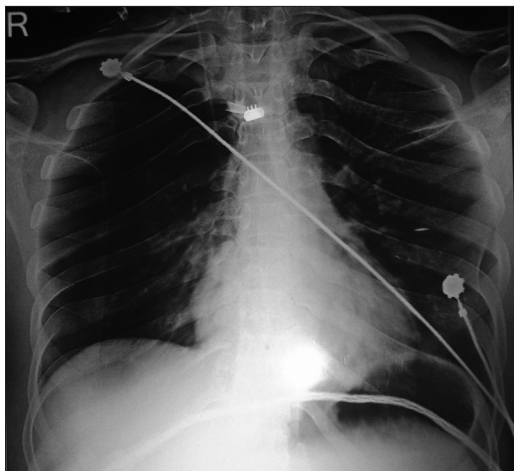
### Correspondence:

Dr. Tapan Jayantilal Parikh, Unit 24/44 Cape Street, Osborne Park, Western Australia 6017, Australia.  
E-mail: [tapanpainclinic@gmail.com](mailto:tapanpainclinic@gmail.com)

patient had started to feel pain after the initial period of numbness. On the 4<sup>th</sup> day, the patient had tachycardia, tachypnea and low SpO<sub>2</sub> (<90%). Oxygen therapy was started via nasal prongs. Pleural effusion (right > left) on chest X-ray, high creatinine (5.9 mg/dl) and low protein levels (3.8 mg/dl) were observed. Human albumin (25%) was started (and repeated on the next day), and Intercostal drain was inserted on the right side with > 1000 ml of fluid was drained. Furosemide was started as an infusion.

On the 7<sup>th</sup> day, patient again had a severe breathlessness, tachypnea (>40/min) and tachycardia (>130/min). Hemoglobin decreased from 13 mg/dl on the 1<sup>st</sup> day to 8.5 mg/dl. The patient was placed under noninvasive ventilator (NIV) support. X-rays displayed signs of acute respiratory distress syndrome (ARDS) and pleural effusion on the left side. Intercostal drainage tube was inserted and >700 ml of fluid per day was drained which decreased to <30 ml per day over period of 9 days. Serum creatinine was 7.9 mg/dl. Hence, hemodialysis was advised and repeated after 3 days. NIV was given continuously for 3 days and then on and off for the next 8 days. Lung injury resolved after 9 days, and the serum creatinine level started to decrease after 15 days. A heavy protein diet, enriched with vitamins and minerals was provided throughout the patient stay in the hospital. Blood, urine and pleural fluid culture were sterile at all times.

On day 17 and 18, the intercostal drainage tubes were removed one by one. On 24<sup>th</sup> day of hospital stay, serum creatinine was 1.6 mg/dl with adequate urine output, serum protein was 5.9 g/dl with normal chest X-ray and the patient was discharged [Figure 1].



**Figure 1:** Chest X-ray on 2<sup>nd</sup> day with no significant findings

## Discussion

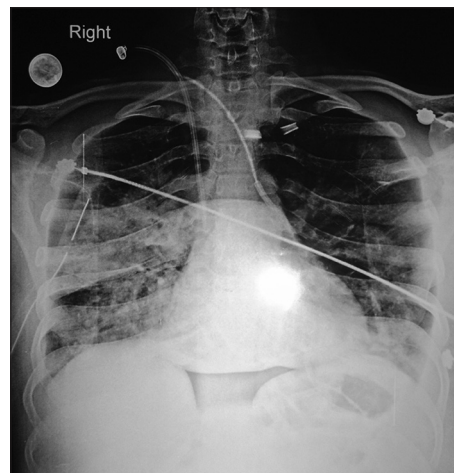
Phenol poisoning can occur by skin absorption, vapor inhalation or ingestion that can result in detrimental health effects.<sup>[2]</sup> Fry stated that the failure of two organ systems plus the kidney was nearly always fatal.<sup>[3]</sup> Here, >37% of the total body surface area was burnt by 94% of phenol, along with multiple organ failure involving kidney.

Decontamination must begin as soon as possible to minimize hydrophobic phenol absorption as it impairs stratum corneum.<sup>[4]</sup>

Phenol-induced acute renal failure results from excretion of unconjugated phenol damaging the glomeruli and renal tubules, renal ischemia, formation of casts due to hemoglobin precipitation and depleted glutathione.<sup>[5]</sup> Profound acidosis results from renal excretion of base during the initial respiratory alkalosis, the acidic nature of phenol and disturbed carbohydrate metabolism due to functional defects in enzyme.<sup>[3]</sup>

In this case the urine output started to drop after 24 h and acidosis was apparent within 2 h of the accident. Dramatic increase in creatinine levels despite the use of diuretics led to hemodialysis. Sodium bicarbonate was given to raise the pH of the patient's urine and decrease precipitation of hemoglobin in the renal tubules.<sup>[5]</sup>

A significant hypoproteinemia occurred in the initial 72 h with the presence of pleural effusion due to extensive denaturation of tissue protein by phenol.<sup>[6]</sup> 25% human albumin was given intravenously for 2 days. A combination of colloids (25% albumin) and diuretics may be considered in patients with hypo-oncotic acute lung injury-ARDS.<sup>[7]</sup> High protein diet continued as it is recommended that up to 1.7 g of amino



**Figure 2:** Chest X-ray showing changes of acute respiratory distress syndrome and pleural effusion on left side

acids/kg/day be given to patients receiving dialysis who are hypercatabolic.<sup>[8]</sup> After 7 days, the patient developed ARDS, which was evidenced by bilateral pulmonary infiltrate and  $\text{PaO}_2/\text{FIO}_2 \leq 100$  mmHg [Figure 2]. NIV support was given as NIV in nonhypercapnic patient with acute hypoxemic respiratory failure may reduce intubation and mortality rate.<sup>[9]</sup>

## References

1. Lin TM, Lee SS, Lai CS. Phenol Burn. *Burns* 2005;32:517-21. Available from: [http://www.researchgate.net/publication/7159558\\_Phenol\\_burn](http://www.researchgate.net/publication/7159558_Phenol_burn). <http://dx.doi.org/10.1016/j.burns.2005.12.016>. [Last access on 2015 Apr 18]
2. Bruce RM, Santodonato J, Neal MW. Summary review of the health effects associated with phenol. *Toxicol Ind Health* 1987;3:535-68.
3. Lin CH, Yang JY. Chemical burn with cresol intoxication and multiple organ failure. *Burns* 1992;18:162-6.
4. Agency for Toxic Substances and Disease Registry. Medical Management Guidelines for Phenol. 2014. Available from: <http://www.atsdr.cdc.gov/mmg/mmg.asp?id=144&tid=27>. [Last access on 2015 Apr 18].
5. Pardoe R, Minami RT, Sato RM, Schlesinger SL. Phenol burns. *Burns* 1976;3:29-41.
6. Sugden P, Levy M, Rao GS. Onychocryptosis-phenol burn fiasco. *Burns: Journal of the International Society for Burn Injuries* 2001;27:289.
7. University Hospital Consortium. (2010). GUIDELINES FOR USE OF ALBUMIN. *Archives of Internal Medicine*. 2010. Available from: [https://www.universityhealthsystem.com/files/frontEnd/pharmacy/Albumin\\_Guidelines\\_UHS\\_April\\_2010.pdf](https://www.universityhealthsystem.com/files/frontEnd/pharmacy/Albumin_Guidelines_UHS_April_2010.pdf). [Last access on 2015 Apr 18]
8. Lewington A, Kanagasundaram S. Renal Association Clinical Practice Guidelines on acute kidney injury. *Nephron Clin Pract* 2011;118 Suppl 1:c349-90.
9. Ferrer M, Esquinas A, Leon M, Gonzalez G, Alarcon A, Torres A. Noninvasive ventilation in severe hypoxemic respiratory failure: A randomized clinical trial. *Am J Respir Crit Care Med* 2003;168:1438-44.

**How to cite this article:** Parikh TJ. Acute concentrated phenol dermal burns: Complications and management. *Indian J Crit Care Med* 2015;19:280-2.

**Source of Support:** Nil, **Conflict of Interest:** None declared.

## Staying in touch with the journal

### 1) Table of Contents (TOC) email alert

Receive an email alert containing the TOC when a new complete issue of the journal is made available online. To register for TOC alerts go to [www.ijccm.org/signup.asp](http://www.ijccm.org/signup.asp).

### 2) RSS feeds

Really Simple Syndication (RSS) helps you to get alerts on new publication right on your desktop without going to the journal's website. You need a software (e.g. RSSReader, Feed Demon, FeedReader, My Yahoo!, NewsGator and NewzCrawler) to get advantage of this tool. RSS feeds can also be read through FireFox or Microsoft Outlook 2007. Once any of these small (and mostly free) software is installed, add [www.ijccm.org/rssfeed.asp](http://www.ijccm.org/rssfeed.asp) as one of the feeds.