

Original Research Article

Efficient Colonoscopic Identification of Colonic Bleeding Diverticulum Using Intradiverticular Water Injection with a Nontraumatic Tube

Yoshinori Sato, Satoko Nakatsu-Inaba, Yasumasa Matsuo, Masaki Yamashita, Hiroki Ikeda, Hiroshi Yasuda and Fumio Itoh

Division of Gastroenterology and Hepatology, St. Marianna University School of Medicine, Kawasaki, Japan

Abstract

Objectives: The colonoscopic identification of stigmata of recent hemorrhage (SRH) in patients with colonic diverticular bleeding (CDB) is difficult. Factors that influence the identification of SRH in the diagnosis of CDB were investigated.

Methods: This was a retrospective study of 487 early colonoscopy patients with acute lower gastrointestinal bleeding who were diagnosed with CDB. Comorbidities, medications, bowel preparation, use of a transparent cap, use of a water-jet scope, colonoscopy by an expert colonoscopist, and use of a nontraumatic (NT) tube were assessed. A multivariate analysis was used to estimate the odds ratio and 95% confidence interval.

Results: Of the 487 colonoscopy patients diagnosed with CDB, 191 (39%) were definitively identified with SRH. The use of a transparent cap, a water-jet scope, an expert colonoscopist, and an NT tube were independent predictive factors for SRH on univariate analysis. A multivariable logistic regression model showed that colonoscopy by an expert colonoscopist and the use of an NT tube were predictive factors for SRH.

Conclusions: Intradiverticular water injection with an NT tube by an expert colonoscopist is useful in identifying CDB, and may help achieve effective endoscopic hemostasis.

Keywords

colonic diverticular bleeding, colonoscopy, nontraumatic tube, stigmata of recent hemorrhage, identification

J Anus Rectum Colon 2021; 5(3): 313-318

Introduction

Colonic diverticular bleeding (CDB) is the most common cause of lower gastrointestinal bleeding, accounting for approximately 40% of episodes of hematochezia[1]. Atherosclerosis has been considered the main cause of diverticular bleeding. Nonsteroidal anti-inflammatory drugs[2], anticoagulants including aspirin, and hypertension are significant predictor factors for diverticular bleeding[3]. CDB stops spontaneously in over 80% of cases but often recurs[4]. Colectomy is still necessary in extreme settings when less invasive procedures are unsuccessful or unavailable. Urgent

colonoscopy is recommended to identify a definite source of severe hematochezia[5]. Patients with major stigmata treated medically have high rates of rebleeding and intervention for hemostasis[6]. The detection of bleeding diverticula often requires a careful examination of multiple potential lesions. The identification of stigmata of recent hemorrhage (SRH) or definitive diagnosis of the source of bleeding in patients with CDB is more difficult to diagnose than SRH in peptic ulcers[7].

We previously reported that extravasation on contrast-enhanced computed tomography (CE-CT) helps to identify the presence and location of active diverticular bleeding dur-

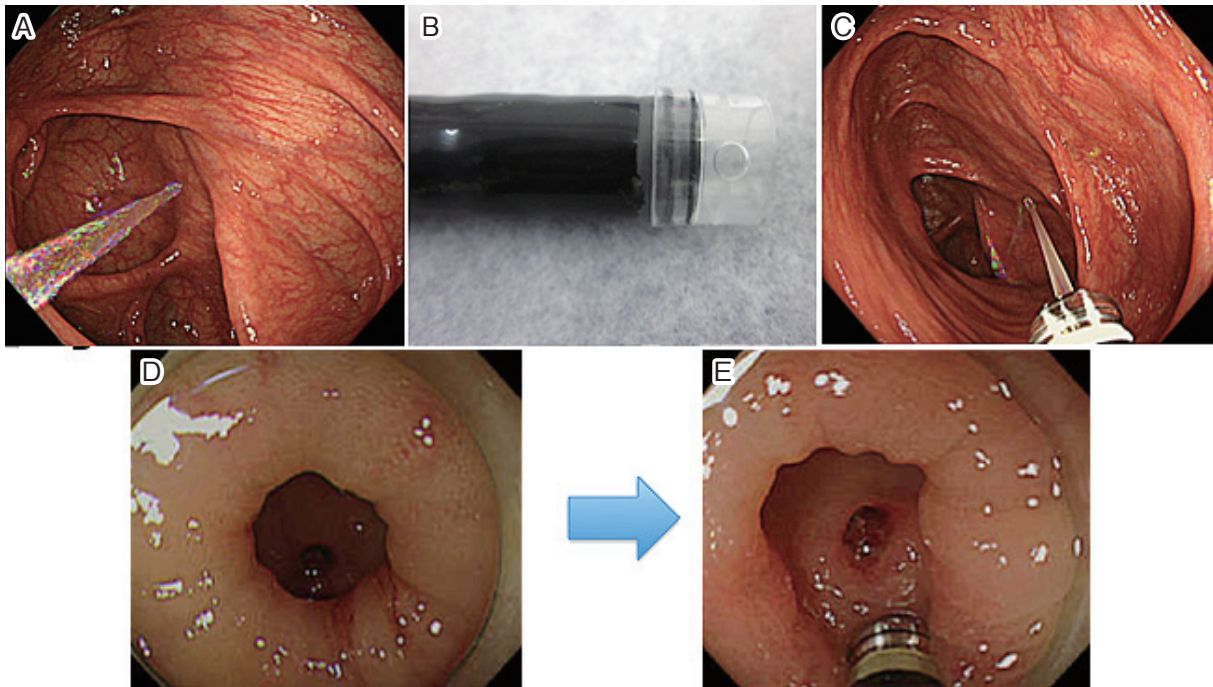


Figure 1. (A) Water-jet function, (B) a transparent cap attached on the tip of the endoscope, (C) water injection with a nontraumatic (NT) tube, (D) endoscopic finding of an exposed vessel in a colonic diverticulum with a small orifice, and (E) the use of an NT tube is effective in detecting an exposed vessel.

ing colonoscopy[8]. A contrast medium cannot be used in all patients, such as those with renal inefficiency. A nontraumatic (NT) tube is an endoscopic device originally designed for chromoendoscopy. In patients with CDB, we have been using this device for the removal of intradiverticular feces and blood clots to detect an exposed vessel. In the present study, we evaluated the predictive factors, including the use of an NT tube, that aid in detecting a bleeding source during early colonoscopy.

Methods

Patients

This was a retrospective study performed at a single institution. From September 2004 to December 2013, 969 colonoscopies were performed for acute hematochezia within 24 h of presentation at St. Marianna University Hospital (Kawasaki, Japan). This study cohort partly overlapped with those in a previous report[8]. In our institution, if upper gastrointestinal bleeding was ruled out in patients with acute onset painless hematochezia, colonoscopy was considered after vital sign stabilization. Shock was defined as a shock index of >1 because of bleeding. The shock index is defined as the ratio of heart rate to systolic blood pressure. Of these, 487 patients were diagnosed with SRH positive or presumptive CDB. Diverticula were considered a definitive source (SRH-positive) if active bleeding or SRH was seen

during colonoscopy.

Diagnosis of CDB

A definitive diagnosis of diverticulosis as the source of bleeding requires the finding of one of the following after vigorous irrigation of diverticula: active bleeding, a non-bleeding visible vessel, or an adherent clot[9]. Diverticula were considered a presumptive source if diverticulosis was present without the identification of other potential bleeding sites on colonoscopy[9]. We evaluated these 487 colonoscopy patients diagnosed with SRH positive or presumptive CDB. Of these, CE-CT was performed in 350 patients. The study protocol was approved by the institutional review board of St. Marianna University School of Medicine on February 10, 2014 (No. 2632). According to the rules of our institution, informed consent was obtained in the form of opt-out on the website.

Endoscopic procedures

When the patient's general condition was stable, colonoscopy was performed after preparation with colonic lavage (complete ingestion of 2 L polyethylene glycol [PEG]-based lavage solution) over 2-4 h. A standard video colonoscope (PCF-Q260I, PCF-Q260AZI; Olympus Optical, Tokyo, Japan) or a colonoscope with a water-jet function was used (PCF-Q260JI) for all procedures (Figure 1A). A transparent cap (D201-12704, MG-163; Olympus Optical) was attached on the tip of the endoscope (Figure 1B). An expert colono-

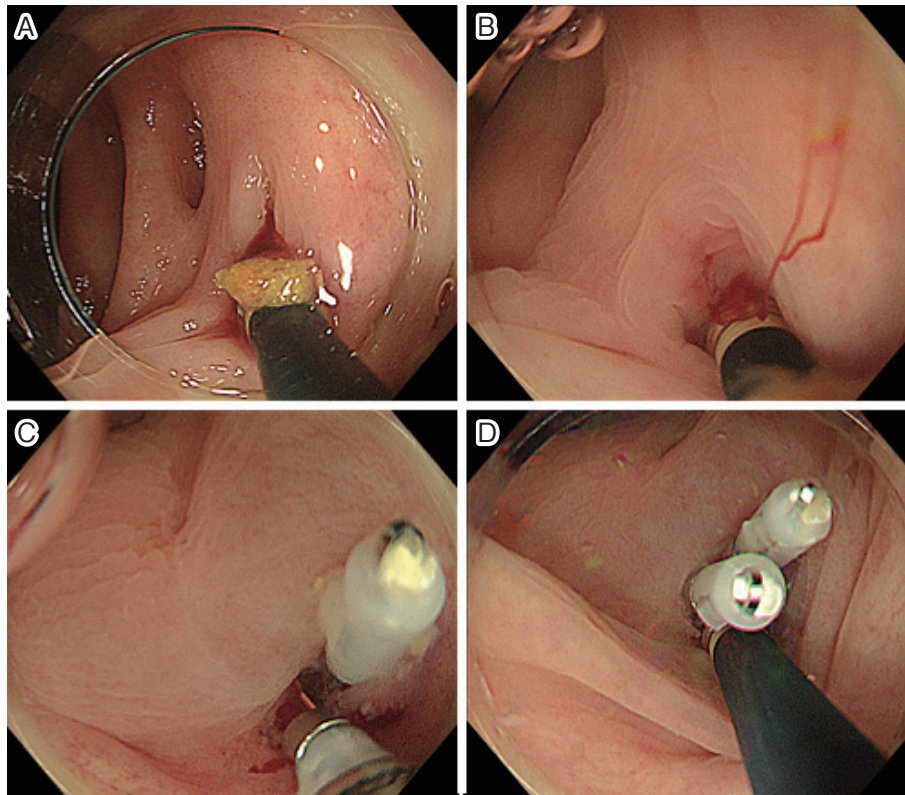


Figure 2. Detection of colonic diverticular bleeding with an NT tube. (A) Feces were removed easily by water-jet injection with an NT tube. (B) Active bleeding was detected with an NT tube. (C) Effectiveness of the first hemoclip was probed with an NT tube. Slight oozing was still observed. (D) Effective hemostasis was achieved with an additional hemoclip.

scopist was characterized as having conducted >1000 colonoscopies[10]. We also used an NT tube (Olympus Optical) for the removal of intradiverticular feces and blood clots to detect an exposed vessel, washing each diverticulum as much as possible (Figure 1C-E, 2A-D). The transparent cap, water-jet scope, and NT tube were used according to the physician's preferences throughout the study period. A water-jet scope has been used for CDB since 2010, and an NT tube has been used since 2006.

Statistical analyses

Univariate analysis was used for the evaluation of predictive factors, which were categorized into two groups and analyzed using χ^2 tests. Factors with $p < 0.05$ in the univariate analysis were further included in multivariate logistic regression analysis. The odds ratio (OR) and 95% confidence interval (CI) were estimated. SPSS Statistics 13.0 (SPSS, Inc., Chicago, IL, USA) was used for all statistical analyses.

Results

Baseline characteristics of the patients

Of 487 patients who underwent colonoscopy, 191 were

diagnosed as SRH positive and 296 with presumptive CDB (Table 1). Of the 191 SRH-positive patients, 138 were males and 53 were females. The SRH-positive types included active bleeding in 118 patients, visible vessels in 30 patients, and adhesive clots in 43 patients. The mean \pm standard deviation age of SRH-positive patients was 69.0 ± 12.7 years. Eighty-eight patients (46%) had comorbidities, and several had multiple diseases. The most common comorbidity was ischemic heart disease in 58 patients, followed by diabetes mellitus in 34 patients and cerebrovascular disease in 16 patients. Sixty-seven patients (35%) were taking antithrombotic drugs. The most common site of CDB was the right-side colon in 121 patients, followed by the left-side colon in 42 patients and transverse colon in 28 patients. Once the bleeding site was successfully identified, endoscopic hemostasis was performed with various techniques, including endoclip placement ($n = 174$) and hypertonic saline-epinephrine (HSE) injection ($n = 2$). When endoscopic hemostasis failed, transcatheter arterial embolization was performed to stop the bleeding in two patients and surgical intervention in four patients.

Colonoscopic detection of bleeding diverticula

Of the 487 patients presenting with CDB, the factors that

Table 1. Clinical Characteristics of Colonoscopy Patients with Definitive Colonic Diverticular Bleeding.

	SRH positive (n = 191)	Presumptive (n = 296)	
Gender (male/female)	138/53	200/96	
Age (years)	69.0 ± 12.7	68.7 ± 13.6	
Comorbidities [n]	88 (46%)	146 (49%)	
Ischemic heart disease	58	67	
Diabetes mellitus	34	63	
Cerebrovascular disease	16	34	
Renal disease	13	15	
Rheumatoid arthritis	13	9	
Bleeding site			
Right side	121		
Transverse colon	28		
Left side	42		
Hemostatic procedures	Active bleeding (n = 118)	Visible vessels (n = 30)	Adhesive clot (n = 43)
Endoclip	101	30	43
HSE injection	2	0	0
Operation	4	0	0
TAE	2	0	0
Others	9	0	0

Data are means ± standard deviations or numbers with percentages in parentheses, unless otherwise indicated. Left side: descending colon and distal; right side: ascending colon and cecum; HSE: hypertonic saline-epinephrine; SRH: stigmata of recent hemorrhage

Table 2. Univariate Analysis of Factors Contributing to the Colonoscopic Detection of Definitive Bleeding Diverticula.

	SRH positive	Presumptive CDB	p-Value
Gender (male/female)	138/53	186/78	0.314
Age (years)	69.1 ± 12.9	68.7 ± 13.8	0.191
Shock index (>1)	11/162 (6.8%)	18/212 (8.5%)	0.706
With comorbidities	88/191 (46%)	142/296 (50.0%)	0.711
Antithrombotic agent use	67/191 (35.0%)	91/296 (30.7%)	0.323
Preparation with PEG	173/191 (90.6%)	262/296 (88.5%)	0.549
Use of a water-jet scope	96/191 (50.3%)	118/296 (39.9%)	0.025
Expert colonoscopist	120/191 (62.8%)	161/296 (54.5%)	0.037
Use of a transparent cap	110/191 (57.6%)	131/296 (44.6%)	0.005
Use of an NT tube	170/191 (89.0%)	228/296 (77.0%)	0.001

CDB: colonic diverticular bleeding; PEG: polyethylene glycol; NT: nontraumatic

contributed to the detection of bleeding diverticula were analyzed according to definitive and presumptive diagnoses (Table 2). Univariate analyses were performed for sex, age, shock index, presence of comorbidities, antithrombotic agents, pretreatment with PEG, and the use of a water-jet colonoscope, a transparent cap attached on the tip of the endoscope, colonoscopy by an expert colonoscopist, and an NT tube. The use of a water-jet function colonoscope, a transparent cap attached on the tip of the endoscope, and an NT tube were significantly effective in identifying bleeding

diverticula. Using these four factors, multivariate analyses were performed, in which the use of an NT tube (OR, 1.976; 95% CI, 1.113-3.508; p = 0.020) and colonoscopy by an expert colonoscopist (OR, 1.697; 95% CI, 1.143-2.519; p = 0.009) retained statistical significance (Table 3).

Discussion

In the present study, we investigated the factors that influence the identification of SRH in the diagnosis of CDB. We

Table 3. Multivariate Analyses of Predictive Factors for the Detection of Definitive Bleeding Diverticula for Detection in SRH-Positive Patients.

Procedure	Odds ratio (95% CI)	p-value
Expert colonoscopist	1.697 (1.143–2.519)	0.009
Use of a water-jet scope	1.029 (0.622–1.702)	0.912
Use of a transparent cap	1.580 (0.930–2.682)	0.09
Use of an NT tube	1.976 (1.113–3.508)	0.02

CI: confidence interval; NT: nontraumatic

found that intradiverticular water injection with an NT tube and early colonoscopy by an expert colonoscopist are useful in the identification of CDB during early colonoscopy. Once the site of CDB is located, effective endoscopic therapies, including endoclip placement, HSE injection, and endoscopic band ligation, are effective in most cases[11]. In a randomized clinical trial, patients undergoing endoscopic hemostasis for diverticular stigmata did not demonstrate a reduced need for surgery[12]. A recent study, however, demonstrated that patients with major stigmata treated medically have high rates of rebleeding and intervention for hemostasis[6].

Urgent colonoscopy is reportedly useful for the detection of SRH in CBD. In addition, Niikura et al. reported that colonoscopy performed by an expert, the use of a cap, and the use of a water-jet scope improve the identification of SRH[10]. Similarly, this study found that the use of a transparent cap, a water-jet scope, colonoscopy by an expert colonoscopist, and the use of an NT tube were independent predictive factors for the identification of SRH on univariate analyses. A multivariable analysis showed that colonoscopy by an expert colonoscopist and the use of an NT tube were significant predictive factors for the identification of SRH during urgent colonoscopy for CDB.

An NT tube has a metallic, round, small, “nontraumatic” head, and was originally designed for chromoendoscopy. We have used this device to cleanse intradiverticular feces and clots during colonoscopy for CDB. The detection of SRH often requires the careful removal of clotted blood from each diverticulum in every part of the colon during colonoscopy. An intradiverticular adherent clot is often resistant to endoscopy using water-jet injection, which is otherwise useful for the removal of luminal feces and clots. Once an NT tube is inserted into a diverticulum, water-jet irrigation through the head of the NT tube is effective in removing clots, and can detect an exposed vessel. An NT tube is useful in the diagnosis of nonbleeding visible vessels and adherent clots. Cleaning the diverticulum with an NT tube may cause the clot to peel off and induce bleeding, contributing to identifying the responsible diverticulum. Even in patients with active bleeding, an NT tube is useful for the detection of intradiverticular vessels. An NT tube is also ef-

fective in a diverticulum with a small orifice, in which it is usually difficult to observe intradiverticular clots or vessels. Of 191 patients with definitive CDB, 170 (89%) had undergone colonoscopy to localize SRH with an NT tube. As we reported previously, extravasation on CE-CT helps to identify SRH[8]. CE-CT was performed in 172 of the 191 patients with definitive CBD. There was no significant difference in the rate of detection of responsible diverticula by using NT tubes with or without CE-CT prior to colonoscopy. Of 300 patients with CDB in whom an NT tube was used during colonoscopy, SRH was identified in 103 patients (34%). This was comparable to reported rates of SRH identification that vary widely from 6% to 42%[6,10,13]. In SRH-positive groups, non-experts used NT tubes in 91% of cases, whereas experts used them in 87% of cases. NT tubes are also useful devices for non-experts. Recently, a useful method has been reported when extravasation is recognized on CE-CT but SRH cannot be detected by colonoscopy. Tamari et al. reported that the target lesion can be navigated efficiently and treated endoscopically by comparing CT images after “step clipping” in patients with CBD[14]. A disadvantage of NT tube use for CDB is that it may reduce the suction power of the colonoscope for intestinal fluid, when the NT tube is inserted into the forceps channel. Colonoscopes with a larger forceps channel can overcome this deficiency.

Our results are encouraging, despite the fact that several limitations are to be noted in the present study. First, as this was a single-center observational study, multicenter prospective studies are needed to evaluate the usefulness of NT tubes for CDB. Second, we analyzed not urgent colonoscopy cases but early colonoscopy cases performed within 24 h of presentation of hematochezia. Our detection rate of SRH was still comparable to urgent colonoscopy when an NT tube was used.

In conclusion, intradiverticular water injection with an NT tube is useful for the identification of CBD, and may achieve effective endoscopic hemostasis.

Acknowledgements

We would like to thank Editage (www.editage.com) for English language editing.

Conflicts of Interest

There are no conflicts of interest.

Source of Funding

This work was supported in part by a Grant-in-Aid for Scientific Research from the Ministry of Education, Culture, Sports, Science, and Technology of Japan (20K07812; HY).

Author Contributions

YS and SN contributed equally to the manuscript.

Concept-YS, SN, HY; design-YS, SN, HY; supervision-HY; resources-SN, YS, YM, MY; materials-SN, YS; data collection and/or processing-SN, YS, HY; analyses and interpretation-HI; literature search-YS, SN, HY; writing manuscript-YS, SN, HY; critical review-FI.

Approval by Institutional Review Board (IRB)

The study protocol was approved by the institutional review board of St. Marianna University School of Medicine on February 10, 2014 (No. 2632).

Informed Consent

According to the rules of our institution, informed consent was obtained in the form of opt-out on the website.

References

1. Longstreth GF. Epidemiology and outcome of patients hospitalized with acute lower gastrointestinal hemorrhage: a population based study. *Am J Gastroenterol.* 1997 Mar;92(3):419-24.
2. Laine L, Connors LG, Reicin A, et al. Serious lower gastrointestinal clinical events with nonselective NSAID or coxib use. *Gastroenterol.* 2003 Feb;124(2):288-92.
3. Yamada A, Sugimoto T, Kondo S, et al. Assessment of the risk factors for colonic diverticular hemorrhage. *Dis Colon Rectum.* 2008 Jan;51(1):116-20.
4. Cirocchi R, Grassi V, Cavaliere D, et al. New trends in acute management of colonic diverticular bleeding: a systematic review. *Medicine (Baltimore).* 2015 Nov;94(44):e1710.
5. ASGE Standards of Practice Committee, Pasha SF, Shergill A, et al. The role of endoscopy in the patient with lower GI bleeding. *Gastrointest Endosc.* 2014 Jun;79(6):875-85.
6. Jensen DM, Ohning GV, Kovacs TO, et al. Natural history of definitive diverticular hemorrhage based on stigmata of recent hemorrhage and colonoscopic Doppler blood flow monitoring for risk stratification and definitive hemostasis. *Gastrointest Endosc.* 2016 Sep;83(2):416-23.
7. Jensen DM. The ins and outs of diverticular bleeding. *Gastrointest Endosc.* 2012 Feb;75(2):388-91.
8. Nakatsu S, Yasuda H, Maehata T, et al. Urgent computed tomography for determining the optimal timing of colonoscopy in patients with acute lower gastrointestinal bleeding. *Intern Med.* 2015 Jun;54(6):553-8.
9. Jensen DM, Machicado GA, Jutabha R, et al. Urgent colonoscopy for the diagnosis of severe diverticular hemorrhage. *N Engl J Med.* 2000 Jan 13;342(2):78-82.
10. Niikura R, Nagata N, Aoki T, et al. Predictors for identification of stigmata of recent hemorrhage on colonic diverticula in lower gastrointestinal bleeding. *J Clin Gastroenterol.* 2015 Mar;49(3):e24-30.
11. Yamada A, Niikura R, Yoshida S, et al. Endoscopic management of colonic diverticular bleeding. *Dig Endosc.* 2015 Nov;27(7):720-5.
12. Green BT, Rockey DC, Portwood G, et al. Urgent colonoscopy for valuation and management of acute lower gastrointestinal hemorrhage: a randomized controlled trial. *Am J Gastroenterol.* 2005 Nov;100(11):2395-402.
13. Ishii N, Setoyama T, Deshpande GA, et al. Endoscopic band ligation for colonic diverticular hemorrhage. *Gastrointest Endosc.* 2012 Feb;75(2):82-7.
14. Tamari H, Aoyama T, Shigita K, et al. The 'step-clipping' method: a guide for identifying a previously bleeding colonic diverticulum. *Endosc Int Open.* 2020 Jan;8(1):E64-9.

Journal of the Anus, Rectum and Colon is an Open Access journal distributed under the Creative Commons Attribution-NonCommercial-NoDerivatives 4.0 International License. To view the details of this license, please visit (<https://creativecommons.org/licenses/by-nc-nd/4.0/>).