

De Novo Arteriovenous Malformation after Aneurysm Clipping

Satoka Shidoh,¹ Masahito Kobayashi,² Kazunori Akaji,¹ Tadashige Kano,³ Yoshio Tanizaki,¹ and Ban Mihara⁴

We report a 73-year-old woman with de novo arteriovenous malformations (AVMs) that developed in the ipsilateral parietal lobe after craniotomy and aneurysm clipping. While intracerebral AVMs are considered to be congenital lesions, there have been several reported cases of acquired AVM arising after ischemic or traumatic episodes. We summarize previously reported cases of such acquired 'de novo' AVMs with a discussion of some pathophysiological responses or factors suggested to promote their development.

Keywords: de novo arteriovenous malformation, post-craniotomy, pathophysiological response, vasculogenesis, angiogenesis

Introduction

Arteriovenous malformations (AVMs) arise in the early stage of fetal development due to capillary or venous dysplasia.^{1,2} However, an increasing number of reports of de novo AVMs have been questioning the notion that this clinical entity is purely congenital. Twenty cases of de novo AVM have been reported, suggesting that some episodes such as stroke, hemorrhage, or radiation could trigger an inflammatory process leading to this form of pathology. Most of the patients affected have been children or young adults. Here, we report an elderly patient with a de novo AVM that developed ipsilaterally but remotely in the right parietal lobe after clipping of the right middle cerebral artery.

Case Report

A 69-year-old woman was referred to our hospital because of an unruptured aneurysm. Angiography revealed a right middle cerebral artery (MCA) aneurysm but no other vascular lesions (Fig. 1). The patient underwent successful aneurysmal clipping surgery via a right frontotemporal craniotomy. The craniotomy was performed using a conventional pterional approach, as shown in Fig. 2, which also indicates the points of the head fixation pins. The dural incision and arachnoid

dissection were done within the area of craniotomy, away from the site of the de novo AVM. Five years after surgery, when the patient was 73 years old, follow-up magnetic resonance (MR) imaging revealed a de novo AVM in the right postcentral gyrus (Fig. 3). Angiography demonstrated a de novo AVM with a diameter of 17 mm fed from the right middle cerebral artery and draining into a cortical vein (Fig. 4). Gamma knife (GK) surgery was performed for the 2.0-ml nidus, with a marginal dose of 18 Gy. Another 5 years after the radiosurgery, GK was repeated for a residual nidus of 0.2 ml with a marginal dose of 20 Gy. Follow-up MR imaging performed 2 years after the second GK showed complete obliteration of the AVM without any adverse effects. Although we did not monitor the plasma level of vascular endothelial growth factor (VEGF) during the clinical course, it was 40.4 pg/ml, i.e. almost normal, two years after GK.

Discussion

Intracerebral AVMs are congenital lesions most usually arising between the third and eighth weeks of embryonic life due to abnormal capillary or venous formation. Only 20 cases of acquired or de novo AVM have been reported, probably because of the increasing use of MRI worldwide^{3–19} (Table 1). There was no significant gender difference in the incidence of these de novo AVMs; the mean patient age at diagnosis was 17 years, and only one occurred in a patient over 60 years of age. The mean interval between the primary disease and the diagnosis of de novo AVM was 7.4 years (median 5 years). There was no significant relationship between this interval and patient age. Seven of these 20 reported cases of de novo AVM had not been visualized by previous angiography but by MR imaging (Table 1). These seven patients might have had small AVMs that were undetectable with the previous MR images. This seemed rather unlikely in our present patient, who underwent angiography twice before and after the clipping surgery, but no AVM lesions were detected on those occasions. As the AVM in our patient developed between the age of 70 and 73 years, this is the oldest such patient to have been reported to date.

Among the 20 reported cases, 10 patients had undergone previous neurosurgical procedures, including 7 involving craniotomy and three with ventriculoperitoneal (VP) shunts. In two cases (Cases 3 and 7), de novo AVMs occurred within their surgical fields, and in one case (Case 6) in the area close to the surgical field. In one case (Case 4), a de novo AVM occurred in the same side with the surgery. In the 4 cases (Cases 1, 2, 5, and 8), de novo AVM occurred in areas distant from the previous surgical fields. In the other two

¹Department of Neurosurgery, Institute of Brain and Blood Vessels, Mihara Memorial Hospital, Isesaki, Gunma, Japan

²Department of Neurosurgery, Saitama Medical University, Iruma-gun, Saitama, Japan

³Department of Neurosurgery, Gunma University, Gunma, Japan

⁴Department of Neurology, Institute of Brain and Blood Vessels, Mihara Memorial Hospital, Isesaki, Gunma, Japan

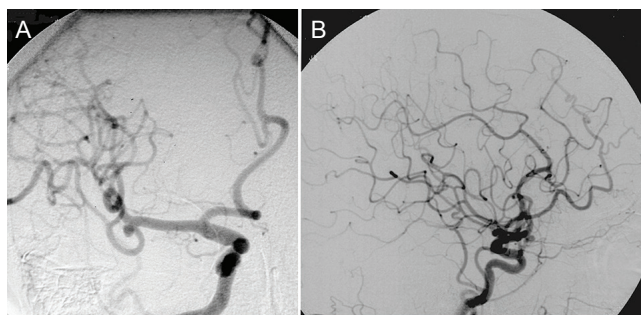


Fig. 1 Preoperative digital subtraction right common carotid angiography showing a right middle cerebral artery aneurysm, but no other vascular lesion. A: anterior-posterior view; B: lateral view.

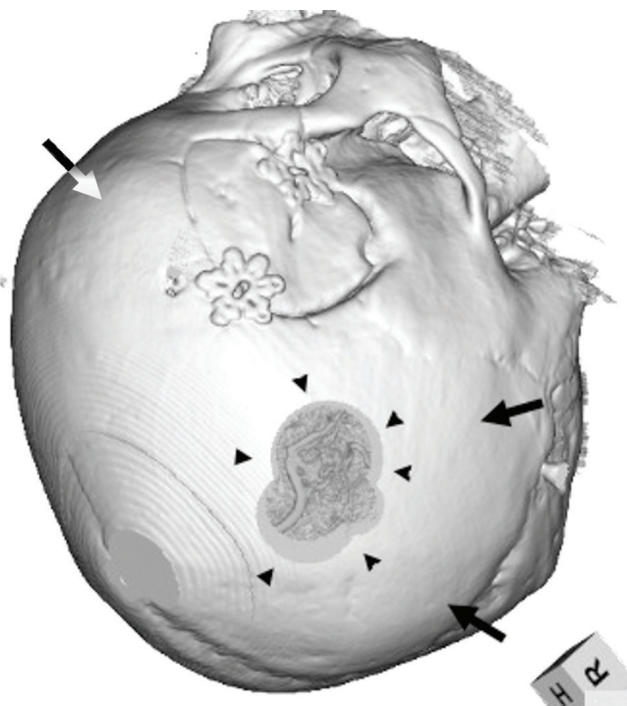


Fig. 2 The range of craniotomy for aneurysm clipping and the de novo AVM. Three head fixation pins are shown by arrows.

cases (Cases 9 and 10), the areas of previous neurosurgery were not described. Radiation therapy including stereotactic radiosurgery (SRS) was performed prior to the development of de novo AVM in Cases 1, 8, and 11. In Case 11, SRS was performed for a dural AVF, and the de novo AVM arose close to the irradiation field. In the present case, the range of craniotomy and arachnoid dissection did not include the site of the de novo AVM (Fig. 2). Mayfield skull clamp placement was used, and even the head fixation pins would not have caused bone and dural injury at the AVM site.

Koch et al. have proposed a new classification of AVMs, i.e. primary, syndromic, and secondary AVMs. Primary AVMs are those that occur congenitally, and syndromic AVMs are those associated with genetic syndromes such as hereditary hemorrhagic telangiectasia (HHT) and cerebrofacial metameric syndromes. Secondary AVMs are considered to occur as a result of an abnormal response to vascular insults such as stroke, hemorrhage, radiation or injury.⁹⁾

It has been proposed that there are two processes of blood vessel formation: vasculogenesis and angiogenesis. Vasculogenesis is the process of formation of new blood vessels and angiogenesis is the process of formation of new branches from existing blood vessels. Some molecular factors play a role in these processes, such as vascular endothelial growth factor (VEGF), transforming growth factor- β (TGF- β), endoglin, neuropilin, and Delta. TGF- β functions in angiogenesis and is suspected to play a critical role in de novo AVM formation.^{20,21)} VEGF also regulates angiogenesis, and its expression is high during the embryonic state, whereas it is suppressed in the adult cerebral vasculature.²¹⁾ Such changes in VEGF expression would support the observation that de novo AVMs arise preferentially among young patients. In the adult brain, however, VEGF would be produced by astrocytes during cerebral hypoxia,^{20,21)} and angiogenesis could be reactivated by physiological stimulation including chronic hypoxia and shear stress,^{22,23)} leading to the evolution of de novo AVMs. Interestingly, in adult patients with AVMs, the endothelial cells of the AVM show high expression of VEGF in comparison with normal individuals.^{24,25)} In addition, it has been reported that an increase in the plasma VEGF level reflects vascular remodeling in AVM patients.²⁶⁾ Although the plasma VEGF level in

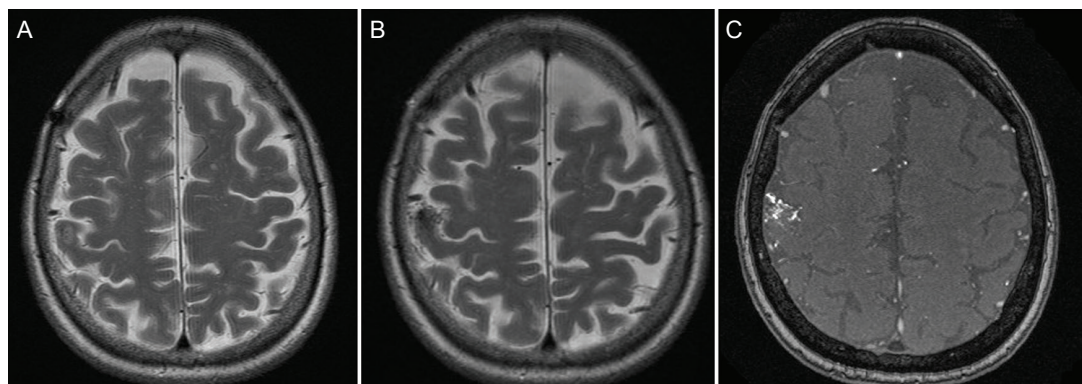


Fig. 3 Postoperative magnetic resonance imaging (MRI). A: T2-weighted axial section MR image three years after craniotomy; B: Five years after craniotomy, spotty lesions with low intensity appeared in the right post-central gyrus; C: Time-of-flight sequence MRI axial section detected a newly developed lesion with high-flow vasculature in the right post-central gyrus, indicating de novo arteriovenous malformation.

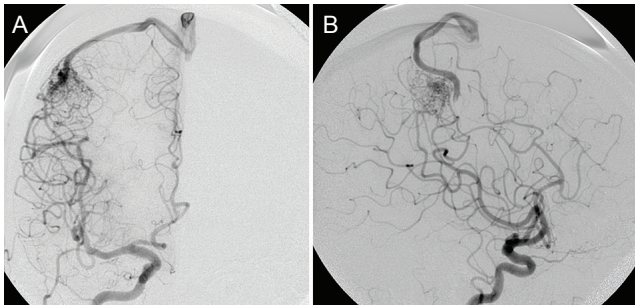


Fig. 4 Postoperative digital subtraction angiograms 5 years after the craniotomy, showing a right frontal lobe nidus fed from the right middle cerebral artery and cortex, draining into a cortical vein. A: anterior-posterior view; B: lateral view.

our patient was not significantly high after radiosurgery, she may have developed asymptomatic brain ischemia or insult in her MCA area after clipping surgery, and angiogenesis in her right parietal lobe may have been reactivated, leading de novo AVM formation. Some reported cases of de novo AVM have arisen in the adult brain, distant from sites of prior craniotomy. For such patients after craniotomy, follow-up MR scans covering the whole brain should be considered.

Conclusion

We have reported the most elderly patient to date with de novo AVM after craniotomy. It should be noted that such AVMs can occur after head injury, stroke, irradiation or brain surgery.

Table 1 Patient characteristics of 20 patients with de novo arteriovenous malformations

Case	Age/sex	Age at initial scan	Preceding surgery	Preceding radiotherapy	Angiography at initial scan	Primary disease
1	9/M ³⁾	5 yr	Craniotomy	+	–	Medulloblastoma
2	14/F ⁴⁾	10 yr	Craniotomy	–	+	Moyamoya disease
3	15/M ⁵⁾	10 yr	Craniotomy	–	+	Intracerebral hemorrhage
4	18/M ⁵⁾	8 yr	Craniotomy	–	+	Intracerebral hemorrhage
5	27/F ⁶⁾	10 yr	Craniotomy	–	+	Intraventricular hemorrhage
6	58/F ⁷⁾	50 yr	Craniotomy	–	+	Intracerebral hemorrhage
7	8/M ⁸⁾	6 yr	Craniotomy	–	–	Cavernous and venous malformation
8	19/F ⁹⁾	16 mo	VP shunt	+	+	Ependymoma
9	5/M ⁵⁾	17 dy	VP shunt	–	+	Intracerebral hemorrhage
10	11/M ¹⁰⁾	7 mo	VP shunt	–	–	Hydrocephalus
11	63/M ¹¹⁾	61 yr	–	+	+	Dural AVF
12	5/M ¹²⁾	5 mo	–	–	+	Hemorrhagic telangiectasia
13	11/M ¹³⁾	2 yr	–	–	+	Moyamoya disease
14	32/F ¹⁴⁾	26 yr	–	–	+	Inflammation or demyelination
15	35/F ¹⁵⁾	31 yr	–	–	+	Hepatic encephalopathy
16	56/M ¹⁵⁾	42 yr	–	–	+	Transient ischemic attack
17	6/F ¹⁶⁾	3 yr	–	–	–	Sickle cell disease
18	7/F ¹⁷⁾	3 yr	–	–	–	Cerebral contusion
19	9/F ¹⁸⁾	6 yr	–	–	–	Continuous band heteropia
20	30/F ¹⁹⁾	16 yr	–	–	–	Bell's palsy

dy: days, mo: months, yr: years.

Conflicts of Interest Disclosure

The authors have no personal, financial, or institutional interest in any of the drugs, materials, or devices described in this article.

References

- 1) Leblanc GG, Golanov E, Awad IA, Young WL: Biology of vascular malformations of the brain. *Stroke* 40: e694–e702, 2009
- 2) Lasjaunias P: A revised concept of the congenital nature of cerebral arteriovenous malformations. *Interv Neuroradiol* 3: 275–281, 1997
- 3) Mathon B, Blauwblomme T, Bolle S, Dufour C, Nagarra O, Brunelle F, Puget S: De novo arteriovenous malformation after brain radiotherapy for medulloblastoma in a child. *Neurology* 81: 398–399, 2013
- 4) Fujimura M, Kimura N, Ezura M, Niizuma K, Uenohara H, Tominaga T: Development of a de novo arteriovenous malformation after bilateral revascularization surgery in a child with moyamoya disease. *J Neurosurg Pediatr* 13: 647–649, 2014
- 5) Jeffree RL, Stoodley MA: Postnatal development of arteriovenous malformations. *Pediatr Neurosurg* 45: 296–304, 2009
- 6) Akimoto H, Komatsu K, Kubota Y: Symptomatic de novo arteriovenous malformation appearing 17 years after the resection of two other arteriovenous malformations in childhood: case report. *Neurosurgery* 52: 228–231; discussion 231–232, 2003
- 7) Miyasaka Y, Nakahara K, Takagi H, Hagiwara H: Development of multiple cerebral arteriovenous malformations documented in an adult by serial angiography. Case report. *J Neurosurg* 98: 190–193, 2003
- 8) Alvarez H, Perry V, Solle M, Castillo M: De novo cerebral arteriovenous malformation in a child with previous cavernous malformation and developmental venous anomaly. *J Neurosurg Pediatr* 9: 327–330, 2012
- 9) Koch MJ, Agarwalla PK, Stapleton CJ, Ogilvy CS, Loeffler JS: De novo development of a cerebral arteriovenous malformation following radiation therapy: Case report and an update to classical arteriovenous malformation nomenclature. *J Clin Neurosci* 28: 162–167, 2016
- 10) Kilbourn KJ, Spiegel G, Killory BD, Kureshi I: Case report of a de novo brainstem arteriovenous malformation in an 18-year-old male and review of the literature. *Neurosurg Rev* 37: 685–691, 2014
- 11) Friedman JA, Pollock BE, Nichols DA: Development of a cerebral arteriovenous malformation documented in an adult by serial angiography. Case report. *J Neurosurg* 93: 1058–1061, 2000
- 12) Shimoda Y, Osanai T, Nakayama N, Ushikoshi S, Hokari M, Shichinohe H, Abumiya T, Kazumata K, Houkin K: De novo arteriovenous malformation in a patient with hereditary hemorrhagic telangiectasia. *J Neurosurg Pediatr* 17: 330–335, 2016
- 13) Schmit BP, Burrows PE, Kuban K, Goumnerova L, Scott RM: Acquired cerebral arteriovenous malformation in a child with moyamoya disease. Case report. *J Neurosurg* 84: 677–680, 1996
- 14) Bulsara KR, Alexander MJ, Villavicencio AT, Graffagnino C: De novo cerebral arteriovenous malformation: case report. *Neurosurgery* 50: 1137–1140; discussion 1140–1141, 2002
- 15) Morales-Valero SF, Bortolotti C, Sturiale C, Lanzino G: Are parenchymal AVMs congenital lesions? *Neurosurg Focus* 37: E2, 2014
- 16) O’Shaughnessy BA, DiPatri AJ, Parkinson RJ, Batjer HH: Development of a de novo cerebral arteriovenous malformation in a child with sickle cell disease and moyamoya arteriopathy. Case report. *J Neurosurg* 102: 238–243, 2005
- 17) Gonzalez LF, Bristol RE, Porter RW, Spetzler RF: De novo presentation of an arteriovenous malformation. Case report and review of the literature. *J Neurosurg* 102: 726–729, 2005
- 18) Stevens J, Leach JL, Abruzzo T, Jones BV: De novo cerebral arteriovenous malformation: case report and literature review. *AJNR Am J Neuroradiol* 30: 111–112, 2009
- 19) Mahajan A, Manchandia TC, Gould G, Bulsara KR: De novo arteriovenous malformations: case report and review of the literature. *Neurosurg Rev* 33: 115–119, 2010
- 20) Rangel-Castilla L, Russin JJ, Martinez-Del-Campo E, Soriano-Baron H, Spetzler RF, Nakaji P: Molecular and cellular biology of cerebral arteriovenous malformations: a review of current concepts and future trends in treatment. *Neurosurg Focus* 37: E1, 2014
- 21) Moftakhar P, Hauptman JS, Malkasian D, Martin NA: Cerebral arteriovenous malformations. Part I: cellular and molecular biology. *Neurosurg Focus* 26: E10, 2009
- 22) Leblanc GG, Golanov E, Awad IA, Young WL; Biology of Vascular Malformations of the Brain NINDS Workshop Collaborators: Biology of vascular malformations of the brain. *Stroke* 40: e694–e702, 2009
- 23) Plate KH: Mechanisms of angiogenesis in the brain. *J Neuropathol Exp Neurol* 58: 313–320, 1999
- 24) Sammons V, Davidson A, Tu J, Stoodley MA: Endothelial cells in the context of brain arteriovenous malformations. *J Clin Neurosci* 18: 165–170, 2011
- 25) Jabbour MN, Elder JB, Samuelson CG, Khashabi S, Hofman FM, Giannotta SL, Liu CY: Aberrant angiogenic characteristics of human brain arteriovenous malformation endothelial cells. *Neurosurgery* 64: 139–146, 2009
- 26) Sandalcioğlu IE, Wende D, Eggert A, Müller D, Roggenbuck U, Gasser T, Wiedemayer H, Stolke D: Vascular endothelial growth factor plasma levels are significantly elevated in patients with cerebral arteriovenous malformations. *Cerebrovasc Dis* 21: 154–158, 2006

Corresponding author:

Satoka Shidoh, MD, PhD, Department of Neurosurgery, Institute of Brain and Blood Vessels, Mihara Memorial Hospital, 366 Otamachi, Isesaki, Gunma 372-0006, Japan.

✉ blskslsatok77@gmail.com