

 **Original Article** 

# New Method of Flush Saphenofemoral Ligation that is Expected to Inhibit Varicose Vein Recurrence in the Groin: Flush Ligation Using the Avulsion Technique Method

Masaki Kokubo, MD, PhD, Tetsuya Nozaka, MD, and Yoshifumi Takahashi, MD


Recently, with the spread of laser ablation therapy, it has been called into question whether flush ligation of the great saphenous vein (GSV) reduces varicose vein recurrence after surgery. Because we thought such recurrence was caused by a narrow branch resection area, we developed a new method of flush ligation (the avulsion technique method). **Materials and Methods:** A total of 214 limbs in 180 patients whose GSV had become varicose were studied. In our procedure, we dissect the GSV, lift its proximal stump, and expose the tributaries. We pull out the distal side of the tributaries without ligation as far as possible. We evaluate the area of subcutaneous ecchymosis within a 15-cm radius of the inguinal incision visually on the third post-operative day. **Results:** We were able to pull out over 10 cm per branch by this method. The area of subcutaneous ecchymosis was mostly less than 10%. No hematoma or pain was observed after the operation. **Conclusion:** This method was safe, with subcutaneous ecchymosis occurring only rarely. We expect this method to reduce saphenofemoral junction recurrence after the operation. (This is a translation of *Jpn J Phlebol* 2017; 28: 11–16.)

**Keywords:** avulsion technique, high ligation, neovascularization, varicose recurrence, stripping

---

*Department of Surgery, Memuro Public Hospital, Kasai-gun, Hokkaido, Japan*

Received: July 31, 2018; Accepted: August 1, 2018  
Corresponding author: Masaki Kokubo, MD, PhD. Department of Surgery, Memuro Public Hospital, Higashi 4-jo, Memuro-cho, Kasai-gun, Hokkaido, Japan  
Tel: +81-155-62-2811, Fax: +81-155-62-5843  
E-mail: masaki-kokubo@hokkaido.med.or.jp  
This is a translation of *Jpn J Phlebol* 2017; 28: 11–16.

 ©2018 The Editorial Committee of Annals of Vascular Diseases. This article is distributed under the terms of the Creative Commons Attribution License, which permits use, distribution, and reproduction in any medium, provided the credit of the original work, a link to the license, and indication of any change are properly given, and the original work is not used for commercial purposes. Remixed or transformed contributions must be distributed under the same license as the original.

## Introduction

Radical high ligation (HL) of the great saphenous vein (GSV) (GSVHL) was first proposed by Babcock and has held an established position as a basic procedure for prevention of the recurrence in the groin for the last 100 years.<sup>1)</sup> However, because endovenous laser ablation (EVLA) is becoming popular, and its long-term results have been revealed in recent years, EVLA with HL has been reported to be more likely to cause angiogenesis<sup>2)</sup> and is raising concerns about its effect in preventing recurrence after HL.<sup>3)</sup> GSVHL basically requires a large incision in the skin and a reliable resection up to the second branch.<sup>1)</sup> However, the procedure is now performed with a minimum incision from a cosmetic point of view, and therefore, with a smaller range of branch resection in many cases.

Assuming that angiogenesis after GSVHL is caused due to a narrow branch resection range, we designed a new HL procedure by using the avulsion technique, which is expected to prevent recurrence in the groin. We confirmed the safety of this procedure and report the results herein.

## Materials and Methods

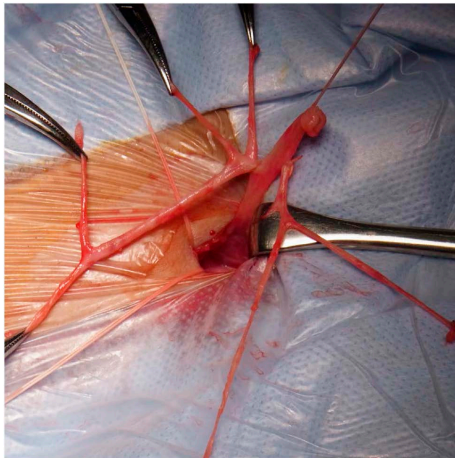
The study included 180 patients, for a total of 214 legs affected with primary varicose vein, who underwent day surgery without hospital stay between November 2015 and August 2016. All patients had primary GSV varices; 196 legs underwent GSVHL and stripping, whereas 18 legs underwent GSVHL and EVLA. The study population consisted of 58 men with 68 legs treated and 122 women with 146 legs treated. The mean age ( $\pm$  standard deviation) was  $63 \pm 9.4$  years (range, 27–87 years).

**Methods:** The patients were anesthetized with tumescent local anesthesia (TLA) in combination with intravenous propofol anesthesia. When this did not provide sufficient pain control, the inhalation anesthetic sevoflurane was administered for up to 15 min.

**HL by avulsion technique:** The position of the saphenofemoral junction (SFJ) was confirmed by intraoperative sonography. To minimize scar formation, transverse incision of approximately 1.0cm was made on the skin along an inguinal crease inside the femoral artery in all patients. Incision was made in the shallow fascia of the thigh to expose GSV, which was ligated and dissected. This dissection allows reliable HL from a small incision. The central end of GSV was pulled up to sequentially expose merging branches; the proximal end was ligated, whereas the distal end was stripped out and removed as long as possible using mosquito forceps without ligation (avul-

sion technique). Avulsion should be performed carefully to prevent nerve damage and lymph fistula. Thick branch and venous aneurysm are the main causes of recurrence, and these should be eliminated completely. Any avulsion of the accessory saphenous vein should be performed immediately after stripping when the deepest anesthesia level is achieved. This reduces pain during vein removal and makes it easier to strip out a sufficient length of vein in case the vein keeps trafficking to GSV. Avulsion is contraindicated for branches that go under the fascia. This is due to a risk of hemorrhage because these branches may directly flow into a deep vein although such cases are rare. Avulsion was repeated with all branches until the femoral vein was completely exposed from SFJ (Fig. 1). Double ligation was performed at SFJ, and GSVHL was complete.

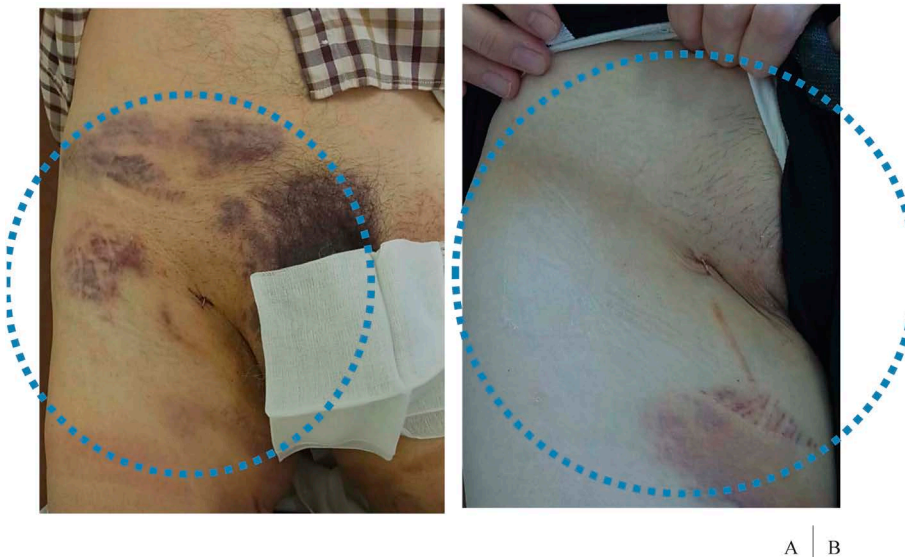
After operation, the patient was observed for the absence of any problem for 1 h and discharged (day surgery). A telephonic follow-up was conducted by a nurse on the following day. Further, 3 days after the operation, the patient made an outpatient visit, where the physician visually examined the inguinal region of 15 cm in diameter centered at the surgical wound site for the area ratio of the subcutaneous ecchymosis and for any induration by palpation (Fig. 2).



**Fig. 1** New flush ligation by the avulsion technique method. Some tributaries 10 cm long or longer were removed.

## Results

The avulsion technique allowed vein removal of at least 10 cm per branch on an average and approximately 50 cm in total. The longer the removed branch was, the lesser



**Fig. 2** On the third postoperative day, we visually determine the area ratio of subcutaneous ecchymosis within a 15-cm radius of the inguinal incision and evaluate the presence of hematoma by palpation. **Figure A** shows approximately 50%, and **Fig. B** shows approximately 10%.

was the blood contamination of the surgical field. Even when a branch broke, it was easy to arrest the bleeding. Pain control during vein removal was a procedural issue. Additional TLA failed to control the pain in some cases, and the inhalation anesthetic sevoflurane was required for operating 20 (9.3%) of 214 legs. Nevertheless, the frequency of postoperative inguinal pain was similar to that after standard HL, and none of the patients required additional analgesics.

The mean area of subcutaneous ecchymosis was 11.7%  $\pm$  13.3%, with 74% of the patients having  $\leq$ 10% area of ecchymosis. None of the patients had induration or hematoma formation. Inguinal hemorrhage did not occur, and additional surgery was not required immediately after operation for any patient. The ecchymosis disappeared in about 2 weeks after operation. None of the patients experienced complications, such as wound infection, lymphorrhea, deep venous thrombosis, and pulmonary infarction. The avulsion technique was not applicable to 12 legs of 7 patients due to severe obesity (4 patients with a body mass index  $>$  28.0 kg/m<sup>2</sup>), concomitant anticoagulant use (2 patients), and a risk of hemorrhage from vessel wall thinning (1 patient).

## Discussion

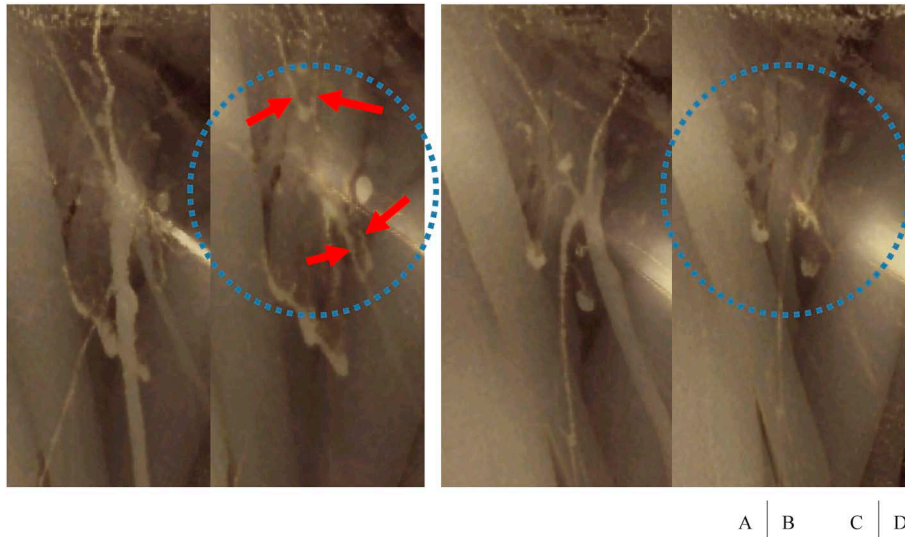
In 1970, Babcock proposed a radical HL, which consists of extensive branch resection to the second-order branches and exposure of the deep vein approximately 1 cm surrounding SFJ, as a procedure for the prevention of recurrence in the groin.<sup>1)</sup> Babcock's HL has been approved as a gold standard over a period of more than 80 years since its publication, and any postoperative recurrence in the groin was concluded to be due to incomplete initial HL.<sup>4)</sup> In 1987, however, Glass<sup>5)</sup> confirmed newly formed, markedly tortuous veins between the common femoral vein and the varicose vein on phlebography. He named this "neovascularization" and reported that neovascularization is the major cause of recurrence as opposed to the previously accepted theory. Subsequently, Jones et al.<sup>6)</sup> published a similar report, suggesting that neovascularization is a possible biological response to complete blockage of blood circulation by HL. With these reports, people suddenly became less confident about the effectiveness of HL for suppressing varicose recurrence. However, El Wajeh et al.<sup>7)</sup> reported in 2004 that their histological and immunological study did not find evidence of neovascularization in inguinal recurrent varicose veins and speculated that the recurrent veins may be enlarged remnant branches as a result of adaptation to abnormal hemodynamics. Furthermore, Egan et al.<sup>8)</sup> reported in 2006 that neovascularization accounted for only 8.2% of all causes of recurrence and that incomplete HL was the most common cause of

recurrent varicose veins, leaving the debate deadlocked. In 2005, Geier et al.<sup>9)</sup> compared histological criteria for the identification of neovascularization (incomplete wall structure, venous valve deficiency, intramural nerve fiber deficiency, unusual morphology of intravascular space, and the presence of scar tissue) with macroscopic criteria (anomalous vessel origin from the femoral vein, presence of scar tissue, vascular torsion, anomalous branching, thinner vascular wall, avulsion difficulty in vessel detachment, and venous valve deficiency). They reported that the macroscopic identification of neovascularization had a sensitivity of merely 42.1% and that the etiology of recurrence in the groin should not be based solely on macroscopic findings. However, when laser therapy not requiring HL started to become widely used, Theivacumar et al.<sup>10)</sup> reported that neovascularization was observed only in 1% of patients who underwent laser therapy and in 18% of patients who underwent stripping, concluding that surgically invasive HL itself is a cause of neovascularization. Later, Disselhoff et al.,<sup>2)</sup> O'Donnell et al.,<sup>11)</sup> and Gauw et al.<sup>12)</sup> reported similar opinions. In 2015, Mariani et al.<sup>3)</sup> speculated that neovascularization occurs from surgical trauma of ligation, but the fundamental causes are tissue inflammation and the removal of venous drainage network. They proposed a selective ligation that conserves drainage veins, as opposed to Babcock's idea, and reported its usefulness. In these circumstances, people are now widely accepting the idea that recurrence in the groin represents neovascularization that is attributed to a trauma of HL and blockage of blood circulation, rather than to incomplete initial ligation.

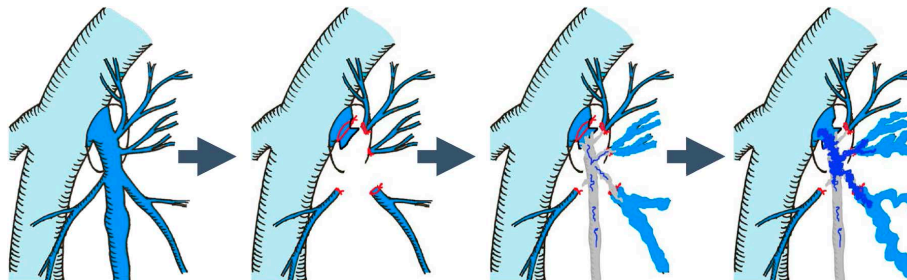
Although the cause of neovascularization is still unclear, Heim et al.<sup>13)</sup> speculated that exposed endothelial cells at the incised end of GSV at SFJ may be involved in neovascularization. They attempted a procedure consisting of complete resection of exposed endothelial cells and suture closure at the site where the deep vein merges, but reported no suppression of neovascularization. Other groups tried to cover SFJ with a polytetrafluoroethylene patch to suppress neovascularization, but their findings were inconsistent, with both negative<sup>14)</sup> and positive<sup>15)</sup> results.

Figure 3 shows the comparison of the time-course changes in conventional HL and avulsion-based HL captured using three-dimensional computed tomographic venography at our hospital. At 6 months after operation, branches that seem to be in continuity with SFJ are observed abundantly in patients treated with conventional HL but rarely in patients who underwent avulsion. Based on this finding, we propose a hypothesis for neovascularization. First, in case of conventional HL, GSV stripping is followed by granulation at the stripped site. Then, microvessels form within the granulation, and the branches left after stripping start to enlarge by abnormal hemody-





**Fig. 3** 3DCTV images comparing the change over time between the conventional HL and the avulsion HL. At six months after surgery, several remnant branches are shown in the case of conventional HL (A, B), whereas hardly any are shown in the avulsion case. **A:** conventional GSV-HL. Preoperative, **B:** conventional GSV-HL. Postoperative 6 months, **C:** Avulsion GSV-HL. Preoperative, **D:** Avulsion GSV-HL. Postoperative 6 months.



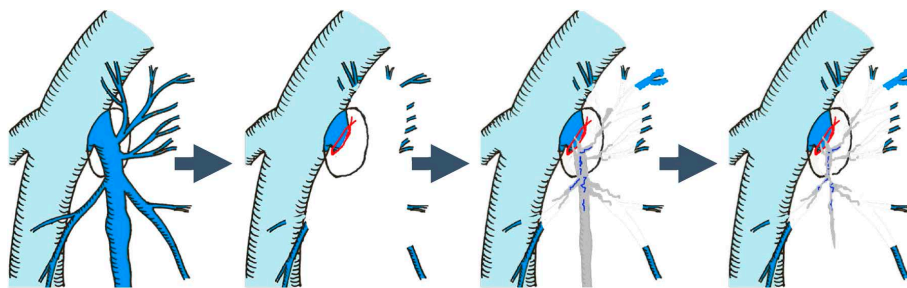
**Fig. 4** In the case of conventional HL and stripping, granulation is formed in place of the removed portion of the GSV. Microvessels are gradually formed in the granulation, and remnant tributaries begin to extend in response to abnormal hemodynamic forces. Microvessels in the granulation and the remnant expanded tributaries are slowly connected in close proximity and are speculated to form neovascularization.

namics.<sup>7)</sup> Currently, HL is performed with branch resection in a narrow range; therefore, the incised branch ends are left close to the SFJ. Enlarged branches gradually connect with microvessels within the granulation to increase aberrant blood circulation, which then seem to grow into new blood vessels (Fig. 4). When branches are in continuity with SFJ, they look like remnant branches and are mistaken as the evidence of incomplete initial treatment. In case of the avulsion technique, GSV stripping is similarly followed by the granulation at the stripped site, formation of microvessels, and enlargement of branches by abnormal hemodynamics. However, these enlarged branches do not make a connection because the branches are far from SFJ. Granulation eventually heals with scar formation, and microvascularization is expected to terminate without

leading to neovascularization (Fig. 5).

As frequently experienced by vascular surgeons, we sometimes encounter a case wherein some branches are left unresected even after a complete HL. Such cases are known as “inappropriate HL,” and the cause is unknown. This can be fully understood if the above-mentioned hypothesis is considered. Previous studies have given priority to ligation of all branches; however, we consider that the branch resection range is more important.

Our present technique is a safe and simple method, but intraoperative pain control is an issue that must be acknowledged. Propofol anesthesia is less analgesic and sometimes fails to fully control pain at avulsion. In such cases, we additionally use mask ventilation with the inhalation anesthetic sevoflurane that is gradually reduced



**Fig. 5** In the case of the avulsion technique method, granulation is also formed. Microvessels in the granulation and remnant tributaries begin to extend, but they do not connect because they are too far from each other. Therefore, we believe that neovascularization does not occur.

from 5%. We consider this method useful because it has not caused postoperative nausea and vomiting, probably because of the duration of use that is as short as 15 min and the concomitant use of propofol, and provided stable hemodynamics without respiratory arrest.

Bleeding is naturally a cause of concern in performing our procedure. When the patient is obese such that the inguinal crease is hidden under the large lower abdomen in the supine position, HL is difficult by itself, and implementing bleeding control measures is often difficult because SFJ is located deeper and higher. When the patient uses an anticoagulant, postoperative bleeding from the incised branch end is a concern. We avoid the use of avulsion in such patients for safety. We experienced another patient whose vessels were fragile and prone to break. In this case, the avulsion technique is not indicated not only because the operation becomes difficult due to blood contamination of the surgical field but also because it will be less useful as the length of stripped vein will be shorter.

Lately, with the widespread use of laser therapy, surgeons tend to avoid the HL procedure. Many reports support the applicability of ablation, even in patients with a large varicose vein thicker than 10mm and a venous aneurysm, by extending the indication of EVLA without HL. However, recurrence and recanalization from the accessory saphenous veins are becoming long-term problems.<sup>2,11)</sup> For these cases, we want to stress the usefulness of EVLA in combination with our proposed procedure. This is because we think the avulsion technique is not only capable of preventing the most common cause of recurrence in EVLA but also suppressing the development of endovenous heat-induced thrombus.

Although we consider that radical HL is indispensable for the prevention of recurrent varicose veins, we propose this new ligation procedure in line with the principle of adhering to the basic procedure by Babcock.<sup>1)</sup> To the best of our knowledge, no report to date has described a surgical procedure similar to ours. We hope that our procedure is tested and validated by many surgeons specialized in

varicose vein treatment.

## Conclusion

Our new HL method for GSV by using the avulsion technique allows an extensive branch resection to the second-order branches with a small skin incision. This procedure is simple and safe with minimum subcutaneous ecchymosis. It is expected to be effective in suppressing recurrence in the groin because it also removes the accessory saphenous vein, which becomes the main cause of recurrence.

## Disclosure Statement

None of the authors have any conflict of interest.

## Additional Note

A summary of this report was presented at the 36th Annual Meeting for Japanese Society of Phlebology on June 24, 2016, in Hirosaki, and received recommendation by the chairperson.

## References

- 1) Babcock WW. A new operation for the extirpation of varicose veins of the legs. *New York Medical Journal* 1907; **86**: 153-6.
- 2) Disselhoff BCVM, der Kinderen DJ, Kelder JC, et al. Five-year results of a randomised clinical trial of endovenous laser ablation of the great saphenous vein with and without ligation of the saphenofemoral junction. *Eur J Vasc Endovasc Surg* 2011; **41**: 685-90.
- 3) Mariani F, Mancini S, Bucalossi M, et al. Selective high ligation of the sapheno-femoral junction decreases the neovascularization and the recurrent varicose veins in the operated groin. *Int Angiol* 2015; **34**: 250-6.
- 4) Lofgren EP, Lofgren KA. Recurrence of varicose veins after the stripping operation. *Arch Surg* 1971; **102**: 111-4.
- 5) Glass GM. Neovascularization in recurrence of the varicose great saphenous vein following transection. *Phlebology*

- 1987; 2: 81-91.
- 6) Jones L, Braithwaite BD, Selwyn D, et al. Neovascularisation is the principal cause of varicose vein recurrence: results of a randomised trial of stripping the long saphenous vein. *Eur J Vasc Endovasc Surg* 1996; 12: 442-5.
  - 7) El Wajeh Y, Giannoukas AD, Gulliford CJ, et al. Saphenofemoral venous channels associated with recurrent varicose veins are not neovascular. *Eur J Vasc Endovasc Surg* 2004; 28: 590-4.
  - 8) Egan B, Donnelly M, Bresnihan M, et al. Neovascularization: an "innocent bystander" in recurrent varicose veins. *J Vasc Surg* 2006; 44: 1279-84; discussion, 1284.
  - 9) Geier B, Olbrich S, Barbera L, et al. Validity of the macroscopic identification of neovascularization at the saphenofemoral junction by the operating surgeon. *J Vasc Surg* 2005; 41: 64-8.
  - 10) Theivacumar NS, Darwood R, Gough MJ. Neovascularisation and recurrence 2 years after varicose vein treatment for sapheno-femoral and great saphenous vein reflux: a comparison of surgery and endovenous laser ablation. *Eur J Vasc Endovasc Surg* 2009; 38: 203-7.
  - 11) O'Donnell TF, Balk EM, Dermody M, et al. Recurrence of varicose veins after endovenous ablation of the great saphenous vein in randomized trials. *J Vasc Surg Venous Lymphat Disord* 2016; 4: 97-105.
  - 12) Gauw SA, Lawson JA, van Vlijmen-van Keulen CJ, et al. Five-year follow-up of a randomized, controlled trial comparing saphenofemoral ligation and stripping of the great saphenous vein with endovenous laser ablation (980 nm) using local tumescent anesthesia. *J Vasc Surg* 2016; 63: 420-8.
  - 13) Heim D, Negri M, Schegel U, et al. Resecting the great saphenous stump with endothelial inversion decreases neither neovascularization nor thigh varicosity recurrence. *J Vasc Surg* 2008; 47: 1028-32.
  - 14) Winterborn RJ, Earnshaw JJ. Randomised trial of polytetrafluoroethylene patch insertion for recurrent great saphenous varicose veins. *Eur J Vasc Endovasc Surg* 2007; 34: 367-73.
  - 15) van Rij AM, Jones GT, Hill BG, et al. Mechanical inhibition of angiogenesis at the saphenofemoral junction in the surgical treatment of varicose veins: early results of a blinded randomized controlled trial. *Circulation* 2008; 118: 66-74.