

Severe Proctitis, Perforation, and Fatal Rectal Bleeding Secondary to Cytomegalovirus in an Immunocompetent Patient: Report of a Case

IMRAN ALAM¹, DIVINA SHANON¹, ALI ALHAMDANI¹, A. BOYD³, A.P. GRIFFITHS², and J.N. BAXTER¹

Departments of ¹Surgery and ²Pathology, Morriston Hospital, Swansea SA6 6NL, UK
³Department of Pathology, University Hospital Wales, Heath Park, Cardiff, UK

Abstract

Cytomegalovirus (CMV) infection is associated with significant morbidity and mortality in immunocompromised patients. In immunocompetent individuals, the infection is usually subclinical but it can sometimes be life threatening. We describe a case of fatal CMV proctitis in a 71-year-old man following an Ivor–Lewis esophagectomy. After surgery he developed renal failure, methicillin-resistant *Staphylococcus aureus* pneumonia, and acute respiratory distress syndrome. He recovered but developed melena and massive fresh rectal bleeding. Sigmoidoscopy revealed severe proctitis and a biopsy was consistent with ischemia. Despite undergoing a proctectomy he continued to bleed and died despite every effort. The final histological examination of the rectum revealed a CMV infection.

Key words Cytomegalovirus · Proctitis · Rectal perforation · Hemorrhage

Introduction

Cytomegalovirus (CMV) infection in immunocompromised patients is often a major cause of morbidity and mortality. We herein describe a case of fatal CMV proctitis with no prior evidence of immunodeficiency or inflammatory bowel disease.

Case Report

A 71-year-old man was diagnosed as having esophageal adenocarcinoma. He was evaluated by a multidisciplinary

team and a decision was made to proceed with an Ivor–Lewis esophagectomy. Other co-morbidities included diabetes mellitus and 2nd-degree heart block.

Following surgery, he developed renal failure, methicillin-resistant *Staphylococcus aureus* (MRSA) pneumonia, and acute respiratory distress syndrome (ARDS). A computed tomography (CT) scan of the abdomen and pelvis was normal. He recovered but thereafter developed melena. The gastroscopy findings were normal. He continued to have intermittent heavy melena and fresh rectal bleeding. The hemoglobin level dropped to 5.0 g/l and he received 15 units of blood.

An emergency EUA (examination under anesthesia) and flexible sigmoidoscopy revealed a lot of blood, severe inflammation, and multiple ulcers in the rectum and sigmoid colon, but no active bleeding. Multiple biopsies were taken and the rectum was packed over two big drains to keep the bowel decompressed. He was initially treated by steroids and broad-spectrum antibiotics. A repeat CT scan revealed severe proctitis. After 48 h the packs were removed and repeat EUA did not show any evidence of any further bleeding. A rectal biopsy histology revealed nonspecific inflammation and ulceration, which was probably ischemic.

He continued to deteriorate, developing sepsis and multiorgan failure but without any further bleeding until 10 days when an episode of profuse rectal bleeding caused his hemoglobin to drop to 5.1 g/dl. An emergency proctectomy and colostomy were performed. Postoperatively, he developed secondary hemorrhaging and thus underwent a re-exploration. There was no active bleeding but generalized oozing in the peritoneum cavity that could not be controlled despite using all possible means. At that stage it was decided to pack the wound for 24–48 h, correct the coagulation abnormalities, sepsis, and re-explore under a more controlled situation. However, he continued to bleed into the abdominal drains, despite all attempts to correct the

Reprint requests to: I. Alam

Received: November 24, 2005 / Accepted: July 25, 2006

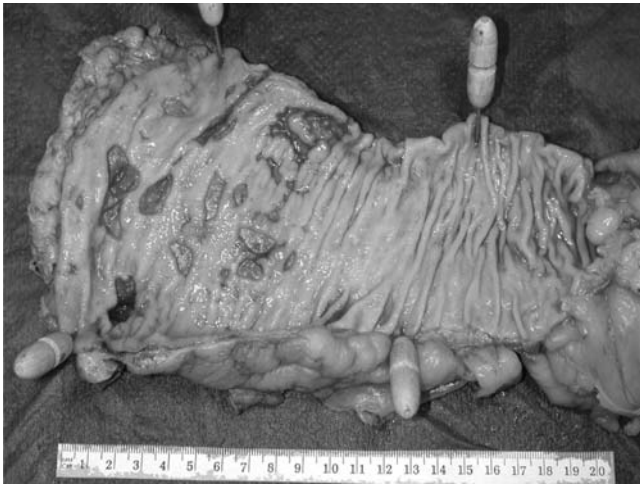

Fig. 1. Formalin-fixed colon showing deep irregular ulcers with sharp edges and a perforation in the lower left area

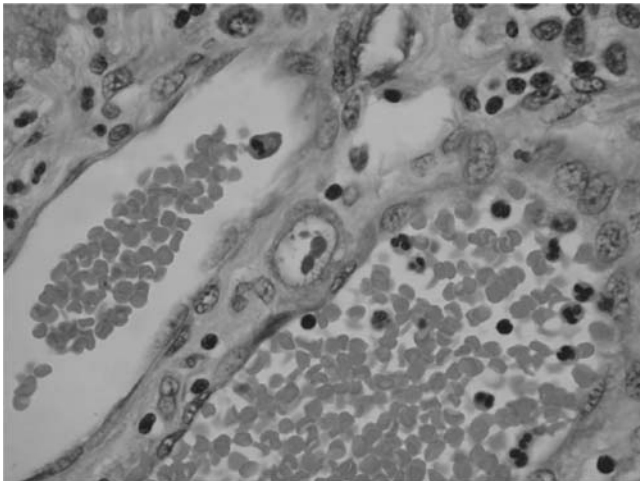


Fig. 2. Hematoxylin–eosin stained section showing typical intranuclear cytomegalovirus (CMV) inclusion bodies

coagulation abnormalities, and the outcome was fatal. A histological examination of the rectum demonstrated severe inflammation, multiple ulcers, one perforation (Fig. 1), and evidence of CMV infection with abundant characteristic nuclear inclusion bodies on hematoxylin–eosin staining (Fig. 2) and immunohistochemistry (Fig. 3). These were found almost exclusively in the bases of the ulcers, and they were associated with endothelial swelling, perivascular inflammation, and vascular occlusion with microthrombi.

Discussion

Cytomegalovirus is a DNA virus (herpes virus group). After an initial infection, the genome of the virus per-

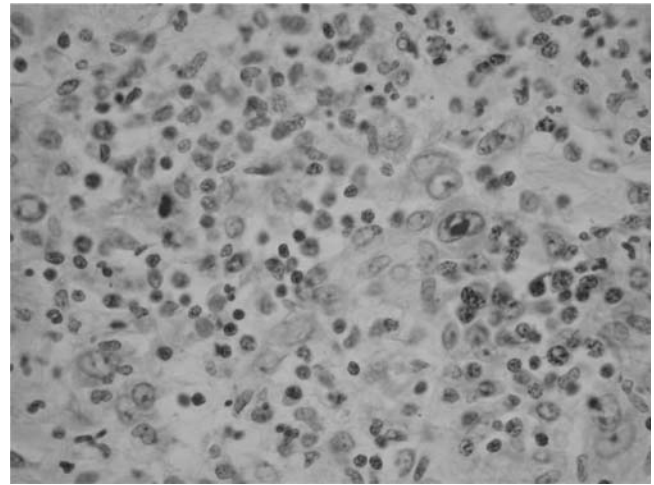


Fig. 3. A mucosal biopsy from an ulcer base containing two CMV nuclear inclusion bodies demonstrated by immunohistochemistry. The right-hand body is in an endothelial cell

sists in the host and may spontaneously reactivate later. Approximately 50%–80% of the general population becomes seropositive by the age of 35 years.¹ Clinically significant infections are usually found when immunological mechanisms have been altered or suppressed by neoplasia, chronic infections, immunosuppressive therapy, or autoimmune deficiency syndrome (AIDS).²

A CMV infection is increasingly common because of rising number of patients with immunodeficiency conditions such as AIDS and organ transplantation. Lesions attributable to focal or widespread CMV infection can involve many organs, including the retina, liver, lung, and the gastrointestinal tract.³ In immunocompetent individuals it is rare but it can affect patients with diabetes⁴ and severe trauma.⁵

Gastrointestinal CMV disease is not infrequently encountered in seemingly immunocompetent patients without a human immunodeficiency virus (HIV) infection. It can affect any part of the gastrointestinal tract, with esophagus and colon being the most common sites.⁶ The clinical manifestations include malaise, anorexia, fever, nausea, diarrhea, abdominal pain, ileus, gastrointestinal bleeding, and perforation.⁷ The mortality is high and the prognosis is particularly poor in elderly individuals (over 65 years).

Cytomegalovirus also tends to be complicated with pre-existing inflammatory bowel diseases, particularly steroid-resistant cases. In one study, Yashihisa et al.⁸ found CMV to be present in 21% of surgical specimens of ulcerative colitis, and all cases were steroid resistant.

Rectal ulcerations leading to life-threatening hemorrhaging and perforation can be due to a benign process (idiopathic, inflammatory bowel disease, infective, drug induced, traumatic) and malignancy (Table 1). The dif-

Table 1. Etiology of rectal ulcers

Benign causes
Idiopathic
Acute hemorrhagic rectal ulcer syndrome
Solitary rectal ulcer
Stercoral ulcer of rectum
Secondary to inflammatory bowel disease
Ulcerative proctocolitis
Crohn's proctocolitis
Infective
CMV proctitis
AIDS
Amoebic proctitis
Tuberculous proctitis
Gonococcal proctitis
Lymphogranuloma inguinale
Syphilitic proctitis
Strawberry lesions of rectum
(<i>Spirochaeta vincenti</i> and <i>Bacillus fusiformis</i>)
Rectal bilharziasis
(<i>Schistosoma mansoni</i>)
Ischemic proctitis
Drug-induced proctitis
(Enema, NSAIDs)
Radiation-induced proctitis
Trauma
Malignant causes of rectal ulcer
Rectal, anorectal, and rectosigmoid cancer

CMV, cytomegalovirus; AIDS, acquired immunodeficiency syndrome; NSAIDs, nonsteroidal anti-inflammatory drugs

ferential diagnosis of CMV proctitis includes acute hemorrhagic rectal ulcer syndrome, solitary rectal ulcer, stercoral ulcers, infective proctitis secondary to amoebiasis, tuberculosis and syphilis, ischemic proctitis, radiation- and drug-induced proctitis, and trauma.

Acute hemorrhagic rectal ulcer syndrome is almost nonexistent in the Western world, while few cases have been reported in Japan.⁹ It affects the elderly population and is characterized by a sudden onset of massive, painless hemorrhaging from rectal ulcers and serious medical illness for which other causes are excluded.⁹ Rectal ulcers are usually above the dentate line, and can be solitary or multiple without significant inflammation or ecchymosis.¹⁰ It may be difficult to differentiate this disease from infective rectal ulcers. However, a negative culture of stool and biopsy specimen and absence of intranuclear inclusion bodies (typical of CMV infection) in biopsy tissue specimens can help in making an accurate diagnosis.^{2,10}

Solitary rectal ulcer syndrome (mucosal prolapse syndrome) is a clinical condition associated with functional anorectal evacuatory disorders.¹¹ The diagnosis is based on the patient history, the endoscopic appearance, and a histological examination of the biopsy specimen. The macroscopic appearance ranges from hyperemia to ulceration or even a polypoid lesion, and the lesions are not necessarily solitary. The microscopic features

include mucosal thickening, fibrosis, and extension of smooth muscle fibers upward between the crypts, and full thickness rectal histology reveals architectural derangements.¹²

Stercoral ulceration is the loss of bowel integrity from the pressure effects of inspissated feces.¹³ Such lesions usually occur in constipated, bedridden patients and present as an isolated lesion in the rectosigmoid area, and a solid fecal mass is usually adherent to the margin of the ulcer.¹⁰ Perforation and hemorrhaging are the principal complications resulting in a high mortality if not diagnosed early.^{13,14} The diagnosis of perforated stercoral ulceration should be considered in any patient with a long-standing history of constipation who presents with acute abdominal pain and clinical findings consistent with a perforation of a hollow viscus. Macroscopically the lesions are round or oval and the microscopic characteristics are represented by superficial ischemic necrosis of the rectal wall.¹⁵

The rectal wall is usually inflamed and edematous, and characterized by multiple, shallow, serpiginous ulcerations in amoebic proctitis. The diagnosis is confirmed by a history, stool culture, biopsy (detection of trophozoites), and serology.⁷ Rectal tuberculosis is rare in the absence of other lesions in the chest and small and large intestine.¹⁶ Radiation- and drug-induced proctitis can readily be excluded based on the patient's history.¹⁰

Ischemic proctitis is often associated with clearly identifiable precipitating factors (aortoiliac procedure, shock, and sepsis) and lesions are characterized by edema and erythema either with or without ulceration. It can be ruled out by a negative stool culture, endoscopic findings, and the absence of inclusion bodies in the biopsy specimen.¹⁰

Cytomegalovirus colitis is usually associated with mucosal lesions that are probably due to vascular endothelial infection, thus leading to endothelial cell swelling, capillary occlusion, thrombosis, ischemia, and ulceration, and presenting clinically as hemorrhagic enteritis, colitis, or occasionally it causing full thickness damage and a perforation of the colon.¹⁷ Perivascular inflammation or vasculitis may also develop. The role of CMV as a primary colonic pathogen is disputed and it is uncertain whether the virus can initiate infection or simply prevent the healing of ulcers.¹⁸

Endoscopy with a biopsy is the investigation of choice. The ulcers are usually numerous, round, or serpiginous, often reaching the muscular layer, and occasionally perforating. The best approach is to confirm the presence of CMV by histological examinations and thus rule out any other pathogens using microbiological techniques. The CMV inclusion bodies are typically round, eosinophilic, intranuclear, or intracytoplasmic, and they are seen in endothelial and mucosal cells or fibroblasts surrounding the ulcer.²

Diagnostic success is influenced by the number of biopsies and the expertise of the pathologist. Immunohistochemical techniques, such as immunoperoxidase staining and in situ DNA hybridization, increase the sensitivity of the histological diagnosis,³ particularly when the organisms are present in low concentrations.

The application of polymerase chain reaction (PCR), serology, and culture of mucosal biopsy, blood, urine, stool, and throat are not helpful in diagnosis of CMV infection.³ However, advances have been made in searching for markers of CMV disease in HIV-infected hosts. Prospective studies in AIDS patients have proven CMV PCR to be a sensitive surrogate marker for active disease, but these techniques have not been studied in non-HIV cases.³

The radiological investigations (barium enema and CT scan) are usually nonspecific. A high index of suspicion can lead to early diagnosis and treatment. Antiviral therapy (gancyclovir 10–15 ml/kg daily) for 2–3 weeks can reduce mortality, morbidity, and the need to perform surgical intervention.

Our patient was more vulnerable because of his age, the presence of diabetes, and postoperative complications. The autopsy histological findings revealed the presence of a CMV infection. If the histology of the initial biopsy had confirmed the diagnosis, then the outcome might have been different.

Conclusions

Cytomegalovirus infection leading to proctitis, massive rectal bleeding, and perforation is a rare event but it carries a high mortality if not properly treated. Although clinical signs such as persistent spiking pyrexia, lymphadenopathy, and bone marrow suppression are also seen in other forms of colitis, particularly steroid-resistant Crohn's colitis, the possibility of CMV should be included in the differential diagnosis, and if CMV is diagnosed, then aggressive treatment is immediately called for.

References

- Stein H, Sleek SD. The incidence of infection with cytomegalovirus in a normal population: a serological study in Greater London. *J Hyg* 1965;63:79–87.

- Speigel JS, Schwabe AD. Disseminated cytomegalovirus infection with gastrointestinal involvement. The role of altered immunity in the elderly. *Am J Gastroenterol* 1980;73:37–44.
- Ng KL, Jean H, Ng HS, Luman W. Gastrointestinal cytomegalovirus infection in non-human immunodeficiency virus infected patients. *Med J Malaysia* 2003;58(3):337–44.
- Henson D. Cytomegalovirus inclusion bodies in the gastrointestinal tract. *Arch Pathol* 1972;93:477–82.
- Machens A, Bloechle C, Achilles EG, Bause HW, Isbicki JR. Toxic megacolon caused by cytomegalovirus colitis in multiple injury patients. *J Trauma* 1996;40:644–6.
- Bang S, Park YB, Kang BS, Park MC, Kim HK, Lee SK. CMV enteritis causing ileal perforation in underlying lupus enteritis. *Clin Rheumatol* 2004;23:69–72.
- Lee CS, Low AH, Ender PT, Bodenheimer HC. Cytomegalovirus colitis in an immunocompetent patient with amoebiasis: case report and review of the literature. *Mount Sinai J Med* 2004;71(5):347–50.
- Takahashi Y, Tange T. Prevalence of cytomegalovirus infection in inflammatory bowel disease patients. *Dis Colon Rectum* 2004;47(5):722–6.
- Takeuchi K, Tsuzuki Y, Ando T, Sekihara M, Hara T, Ohno Y, et al. Clinical characteristics of acute haemorrhagic rectal ulcers. *J Clin Gastroenterol* 2001;33(3):226–8.
- Tseng CA, Chen LT, Tsai KB, Su YC, Wu DC, Jan CM, et al. Acute haemorrhagic rectal ulcer syndrome: A new clinical entity? Report of 19 cases and review of the literature. *Dis Colon Rectum* 2004;47:895–905.
- Choi HJ, Shin EJ, Hwang YH, Weiss EG, Noguera JJ, Wexner SD. Clinical presentation and surgical outcome in patients with solitary rectal ulcers syndrome. *Surg Innov* 2005;12(4):307–13.
- Kang YS, Kamm MA, Engel AF, Talbot IC. Pathology of the rectal wall in solitary rectal ulcer syndrome and complete rectal ulcer prolapse. *Gut* 1996; 38:587–90.
- Mauil KI, Kinning WK, Kay S. Stercoral ulceration. *Am J Surg* 1982;48(1):20–4.
- Shinkawa H, Yasuhara, Naka S, Yanagie H, Nojiri T, Furuya Y, et al. Factors affecting the early mortality of patients with non-traumatic colorectal perforation. *Surg Today* 2003;33:13–7.
- Tokunaga Y, Hata K, Nishitai R, Kaganoi J, Nanbu H, Ohsumi K. Spontaneous perforation of the rectum with possible stercoral etiology: report of a case and review of the literature. *Surg Today* 1998;28:937–9.
- Puri AS, Vij JC, Chaudhary A, Kumar N, Sachdev A, Malhotra V, et al. Diagnosis and outcome of isolated rectal tuberculosis. *Dis Col Rectum* 1996;39(10):1126–9.
- Mueller GP, Williams RA. Surgical infections in AIDS patients. *Am J Surg* 1995;169(suppl):375–85.
- Goodman ZD, Boitnott JK, Yardley JH. Perforation of the colon associated with cytomegalovirus infection. *Dig Dis Sci* 1979;24:376–80.