

Comparative study between staples and eight plate in the management of coronal plane deformities of the knee in skeletally immature children

Arvind Kumar¹ · Sahil Gaba¹ · Alok Sud² · Pushpvardhan Mandlecha³ · Lakshay Goel² · Mayur Nayak¹

Received: 26 May 2016 / Accepted: 5 July 2016 / Published online: 14 July 2016
© The Author(s) 2016. This article is published with open access at Springerlink.com

Abstract

Purpose To compare two commonly used methods of temporary hemiepiphysiodesis (staples and figure of eight plate) in the management of coronal plane deformities of the knee in skeletally immature children.

Methods This prospective study was conducted between November 2012 and November 2015. A total of 40 patients with 67 affected knee joints, having at least 1 year of skeletal growth remaining, were included in the study. Angular correction was measured by recording the mechanical lateral distal femoral angle (mLDFA), mechanical medial proximal tibial angle (mMPTA), and anatomical tibio-femoral angle (TFA) (for the overall alignment of lower limbs). Implant removal was done after 5° of overcorrection was achieved. The rate of correction

(° per month) and complications related to each technique were recorded.

Results The most common diagnosis was idiopathic genu valgum. The overall rate of correction (TFA) was 1.2° for staples and 1.4° for eight plate ($p = 0.70$, not statistically significant). The correction in mLDFA was statistically better in the eight plate group, whereas an opposite trend was recorded in mMPTA. Implant-related complications were present in two cases of the staples group.

Conclusion Although the overall correction rate was similar in both groups, implant-related complications were lower with figure of eight plate. In idiopathic genu valgum (the most common diagnosis), the correction was statistically better in the eight plate group. We recommend figure of eight plate over staples in managing these deformities.

✉ Arvind Kumar
arvindmamc@gmail.com

Sahil Gaba
drsahilgaba@gmail.com

Alok Sud
avimukta2@gmail.com

Pushpvardhan Mandlecha
drpushp@gmail.com

Lakshay Goel
lakshaygoel@gmail.com

Mayur Nayak
mayur.nayak86@gmail.com

¹ Department of Orthopaedics, All India Institute of Medical Sciences, New Delhi, India

² Department of Orthopaedics, Lady Hardinge Medical College, New Delhi, India

³ Department of Orthopaedics, Bombay Hospital, Mumbai, India

Keywords Angular deformities around knee · Hemiepiphysiodesis · Staples · Figure of eight plate

Introduction

Angular deformities around the knee joint are common in the pediatric population. Physiological deformities account for the majority of these cases [1]. While physiological deformities usually correct with growth, pathological deformities can cause functional impairment in the form of abnormal gait, painful joint, and a potential risk of developing osteoarthritis of the knee. Temporary hemiepiphysiodesis, timed permanent hemiepiphysiodesis, corrective osteotomy, and Ilizarov ring fixator application are the various surgical modalities for the correction of angular deformities around the knee joint [2–7]. Corrective osteotomies provide desired correction immediately but are

associated with complications like increased blood loss, risk of compartment syndrome, neurovascular injury, and growth disturbance if the growth plate is damaged [2–4]. Prolonged period of immobilization following corrective osteotomy may also cause joint stiffness. Permanent hemiepiphysiodesis has unpredictable results, as the timing of the procedure is never precise. Overcorrection and undercorrection are common complications [7]. Limb length discrepancy can also occur, which may later require correction [7]. Staples, percutaneous screws, or figure of eight plate (tension band plate) can be used for temporary hemiepiphysiodesis [8–10]. It is a less invasive technique compared to osteotomy. The results are more predictable and the process is reversible. The implants can be removed after the desired correction is achieved. Figure of eight plates and epiphyseal staples are both widely used methods of temporary hemiepiphysiodesis [8, 9]. Complications related to the use of staples include breakage, extrusion, and permanent physal damage [9, 11, 12]. Eight plates have been shown to have fewer complications [9, 13]. Although costlier, figure of eight plates are considered a better alternative to staples because of the fewer complications in comparative studies [14–16]. In this study, we have shared our experience with use of figure of eight plates (Orthofix) and staples (locally manufactured stainless steel staples) for the correction of coronal plane deformities around the knee joint.

Materials and methods

This prospective study was conducted between November 2012 and November 2015. The included patients had coronal plane angular knee deformities (genu varum and valgum) with at least 1 year of skeletal growth remaining. The following cases were excluded: physiological deformities, deformities due to metabolic disorders that improved with medical management, deformities as a result of infection or neoplasm, post-traumatic deformities, dynamic deformities as in neuromuscular disorders and contractures, non-ambulatory patients.

The placement of implant in the distal femur, proximal tibia, or both was based on the location of the primary deformity as assessed by abnormality in the mechanical lateral distal femoral angle (mLDFA) and mechanical medial proximal tibial angle (mMPTA). One staple was placed on each side of the midsagittal plane in a submuscular position, with care taken to preserve the periosteum. Intraoperative imaging was used to verify satisfactory hardware placement in both the anteroposterior and lateral planes. Similarly, one eight plate was placed in the midsagittal plane (or slightly posterior to it to avoid future recurvatum deformity), with one screw proximal and one

distal to the physis. The entire procedure was extraperiosteal, and care was taken to avoid damage to the physis. Figure 1 depicts intraoperative clinical and radiographic photos. Knee range of motion and full weight-bearing were

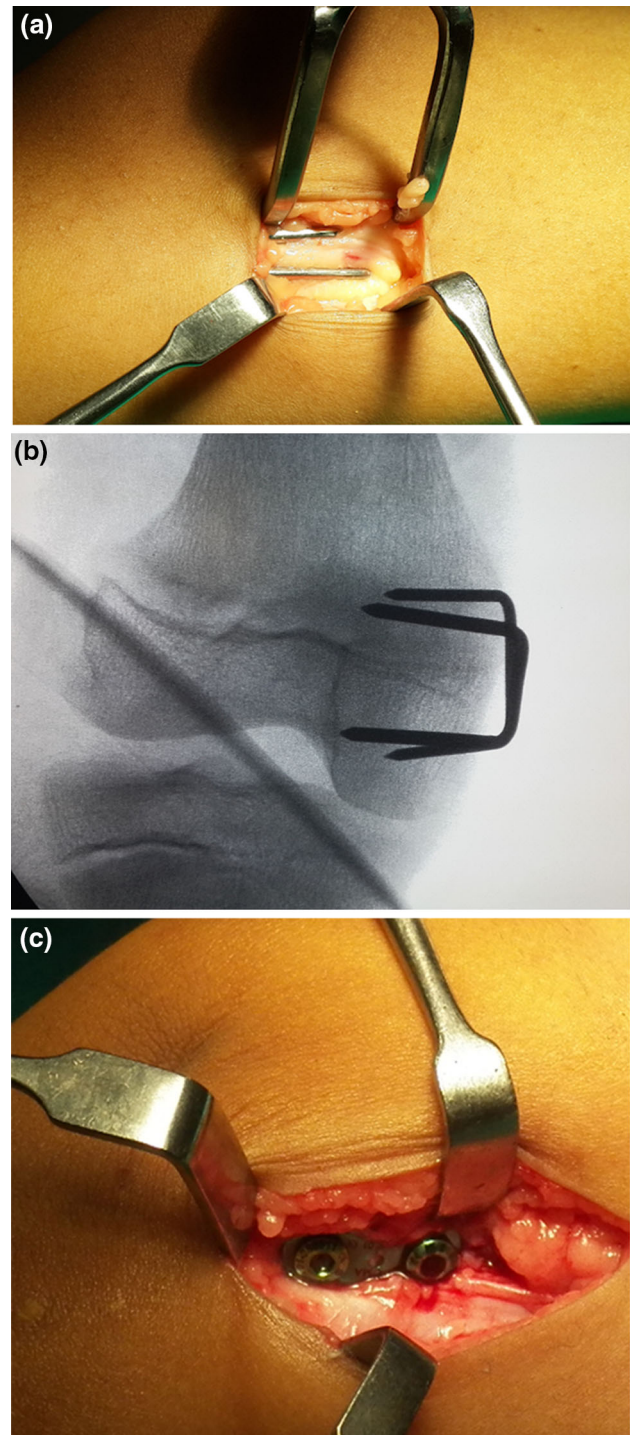


Fig. 1 a Extrapariosteal placement of staple (intraoperative photograph). b Checking correct placement and avoiding physal penetration under image intensifier. c Extrapariosteal placement of eight plate (intraoperative photograph)

allowed from the first post-operative day. Crutches or a walker were used to assist in walking in the initial few days. Unassisted weight-bearing was begun as pain subsided. Early return to daily activities was encouraged. The implants were removed after 5° of overcorrection was achieved.

Standing orthoroentgenograms were used to measure the angles. This view allowed assessment of the overall mechanical alignment, mLDFA, mMPTA, and anatomical tibio-femoral angle (TFA). Documentation of these radiological parameters was done at 4-monthly intervals in order to avoid crowding of insignificant observations.

All patients were observed for complications, including wound-related complications, failure to document any improvement after 4 months, implant breakage, implant extrusion, overcorrection (more than 5° in the opposite direction), and physeal penetration. Persistence of deformity 2 years post-surgery was considered as a failure and indication for an alternative procedure in the form of corrective osteotomy.

The end point of correction (time of implant removal) was planned taking into account the “rebound phenomenon”. TFA, mLDFA, and mMPTA were measured, as they are more accurate than clinical examination findings. Aiming for 5° of overcorrection in order to compensate for rebound growth, we kept our end point at $92 \pm 3^\circ$ for mLDFA and $82 \pm 3^\circ$ for mMPTA for valgus deformity

correction and $82 \pm 3^\circ$ of mLDFA and $92 \pm 3^\circ$ of mMPTA for varus deformity correction. All patients approaching correction were closely followed every 2 weeks to prevent more than the desired overcorrection. After implant removal, all patients included in the study were closely followed every 2 months to document any recurrence.

SPSS version 20.0 was used for calculation of the mean and standard deviation within the two groups. An independent samples *t* test was used for the comparison of means. A *p*-value of less than 0.05 was considered to be statistically significant.

The institutional review board and ethics committee approved the study. Ethical standards according to the Helsinki declaration of 1964 (and its later amendments) were conformed to. Informed consent was obtained from all patients.

Results

Forty patients with 67 affected knee joints were included in the study. Three patients were lost to follow-up. Thirty-seven patients (63 knee joints) with a minimum follow-up of 2 years were available for final assessment. Thirty-one knee joints were included the figure of eight plate group (19 patients), while 32 were included in the epiphyseal

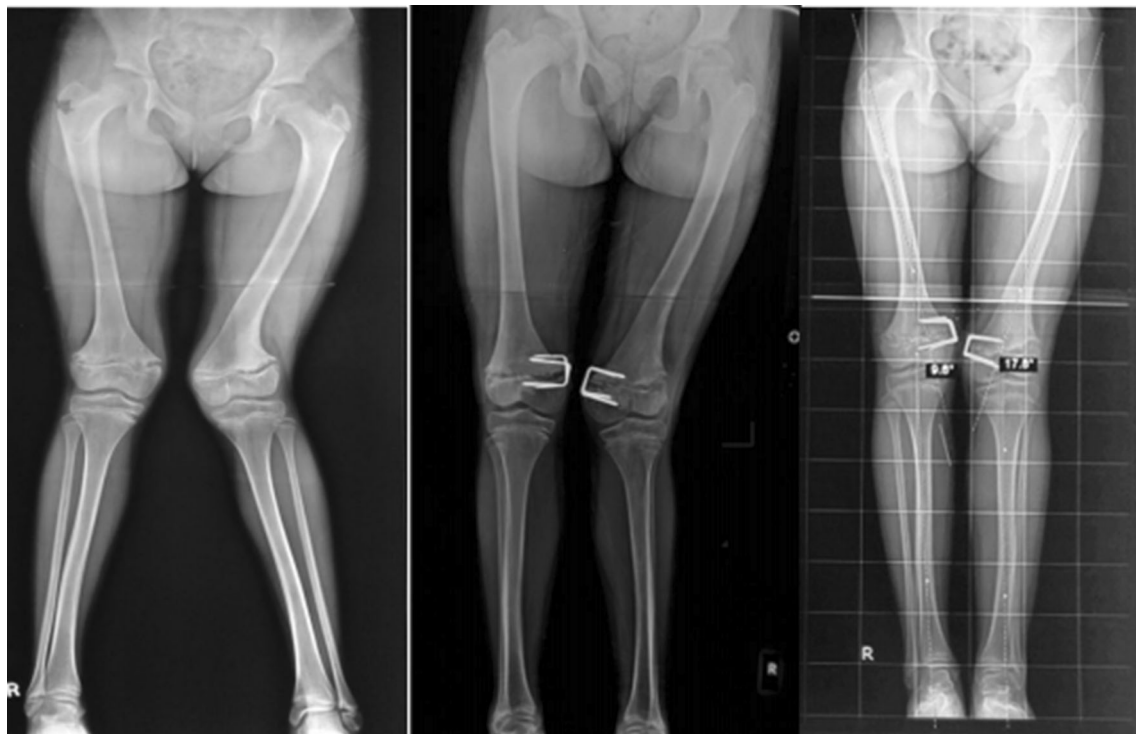

Fig. 2 Radiological correction of deformity at 4-monthly intervals with staples

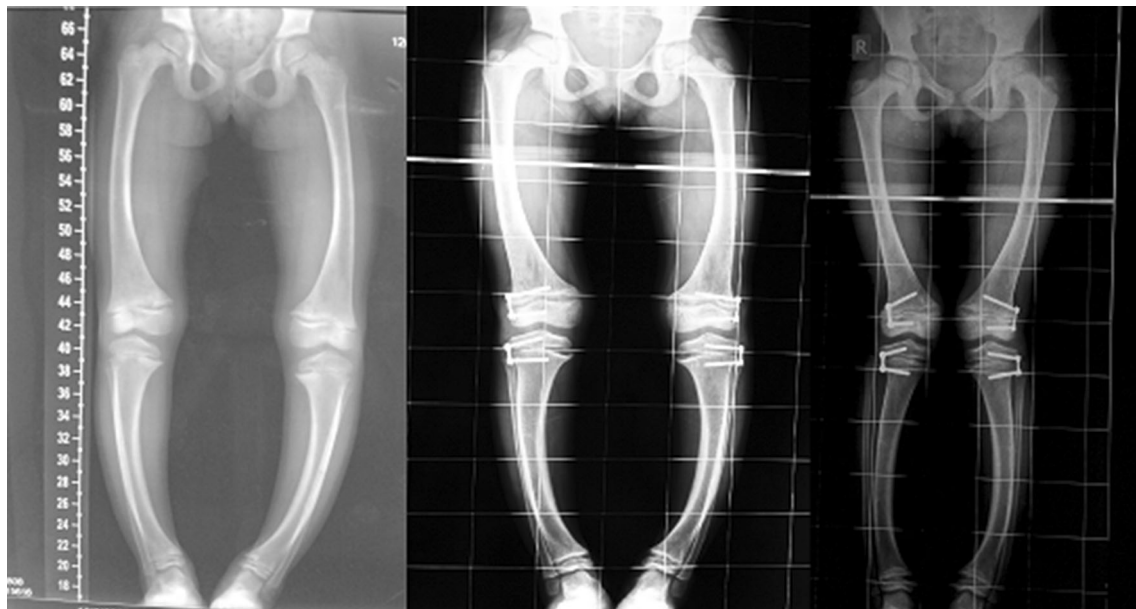


Fig. 3 Radiological correction of deformity at 4-monthly intervals with eight plate

Table 1 Demographic profile

Parameters	Staple group	Eight plate group	Remarks
1. Age distribution (years)	Mean = 7.3 (range: 3.5–12)	Mean = 7.8 (range: 4–12)	p -value = 0.53 (NS)
2. Sex distribution	Male = 8 Female = 10	Male = 8 Female = 11	p -value = 1 (NS)
3. Varus/valgus deformity	Varus = 8 knee joints Valgus = 24 knee joints	Varus = 4 knee joints Valgus = 27 knee joints	p -value = 0.33 (NS)
4. Etiology	Skeletal dysplasia = 2 Idiopathic genu valgum = 20 Post-rachitic genu valgum = 4 Post-rachitic genu varum = 6	Skeletal dysplasia = 2 Idiopathic genu valgum = 18 Post-rachitic genu valgum = 7 Post-rachitic genu varum = 2 Associated with congenital deformity = 2	
5. Bilateral vs. unilateral	Bilateral = 14 patients Unilateral = 4 patients	Bilateral = 12 patients Unilateral = 7 patients	p -value = 0.48 (NS)
6. Femoral and tibial components involvement	Femur = 32 Tibia = 8	Femur = 31 Tibia = 4	p -value = 0.36 (NS)

NS not statistically significant difference, SIG statistically significant difference

staples group (18 patients). Figure 2 shows radiological correction in a case managed with staples and Fig. 3 shows a case managed with eight plate.

A total of 75 hemiepiphysestomies were performed on 37 patients (63 in the distal femur, 12 in the proximal tibia). The age and sex distribution, laterality, and number of varus and valgus deformities were similar in both groups (Table 1). The mean age was 7.3 years (range: 3.5–12 years) in the staple group and 7.8 years (range:

4–12.0 years) in eight plate group. The male:female ratio was 8:10 in the staple group and 8:11 in the eight plate group. Idiopathic genu valgum followed by post-rachitic deformity were the most common underlying etiologies. One patient in the eight plate group had bilateral genu valgum deformity after successful treatment of congenital knee dislocation. The mean rate of correction was 1.2° per month in the staples group and 1.4° per month in the eight plate group (Table 2). This difference was not statistically

Table 2 Post-operative evaluation

Parameters	Staple group	Eight plate group	Remarks
Correction rate of mechanical lateral distal femoral angle (° per month)	1.0° per month (SD = 0.35) Range: 0.75–1.25	1.3° per month (SD = 0.16) Range: 0.81–2.25	<i>p</i> -value = 0.004 (SIG)
Correction rate of mechanical medial proximal tibial angle (° per month)	0.9° per month (SD = 0.10) Range: 0.75–1.11	0.8° per month (SD = 0.29) Range: 0.56–1.12	<i>p</i> -value = 0.001 (SIG)
Correction rate of anatomical tibio-femoral angle (° per month)	1.2° per month (SD = 0.37) Range: 0.75–2.33	1.4° per month (SD = 0.30) Range: 1–2	<i>p</i> -value = 0.71 (NS)
Etiology-wise correction rate (° per month)	Skeletal dysplasia = 1.1° (<i>n</i> = 2)	Skeletal dysplasia = 1.0° (<i>n</i> = 2)	<i>p</i> -value = 0.31 (NS)
	Idiopathic genu valgum = 1.0° (<i>n</i> = 18)	Idiopathic Genu valgum = 1.3° (<i>n</i> = 18)	<i>p</i> -value = 0.0001 (SIG)
	Post rachitic genu valgum = 1.1° (<i>n</i> = 4)	Post rickets genu valgum = 1.4° (<i>n</i> = 7)	<i>p</i> -value = 0.14 (NS)
	Post rachitic genu varum = 1.9° (<i>n</i> = 6)	Post rachitic genu varum = 1.9° (<i>n</i> = 2)	<i>p</i> -value = 0.83 (NS)
Time of implant removal	Mean = 12 months	Mean = 10.3 months	<i>p</i> -value = 0.54 (NS)

NS not statistically significant difference, SIG statistically significant difference

Table 3 Complications

Complication	Staple group	Eight plate group	Remarks
Wound healing-related complications	NIL	NIL	<i>p</i> -value = 1.0 (NS)
No correction in first 4 months	NIL	NIL	All joints studied have measurable correction after 4 months <i>p</i> -value = 1.0 (NS)
Physeal penetration	NIL	NIL	<i>p</i> -value = 1.0 (NS)
Implant migration/extrusion	Two knee joints (6.25 %)	NIL	<i>p</i> -value = 0.49 (NS)
Implant breakage	NIL	NIL	<i>p</i> -value = 1.0 (NS)
Failure of correction after 2 years	Two knee joints (6.3 %) both belonging to skeletal dysplasia (abnormal physes)	Two knee joints (6.5 %) both belonging to skeletal dysplasia (abnormal physes)	<i>p</i> -value = 1.0 (NS)
Requirement of additional procedure (osteotomy)	Four knee joints (12.5 %)	Two knee joints (6.5 %)	<i>p</i> -value = 0.43 (NS)
Overcorrection more than 5°	NIL	NIL	<i>p</i> -value = 1.0 (NS)
Recurrence	NIL	NIL	<i>p</i> -value = 1.0 (NS)
Limb length discrepancy more than 1 cm	Three cases, all unilateral (two idiopathic and one post-rickets genu valgum)	Two cases, both unilateral (both belonged to idiopathic genu valgum)	<i>p</i> -value = 1.0 (NS)
Total	7 (22 %)	4 (13 %)	<i>p</i> -value = 0.51 (NS)

NS not statistically significant difference, SIG statistically significant difference

significant (*p* = 0.75). One female patient with bilateral genu valgum managed with staples developed an early complication (implant extrusion) at 4 months and was not considered for calculation of the correction rate. There were no wound-related complications in either group. None of the patients had more than the desired overcorrection at

the time of implant removal. A total of four knee joints (two in each group) did not achieve correction by 2 years (Table 3; Fig. 4). The underlying etiology in all these patients was skeletal dysplasia. Thus, an additional procedure was needed in four knee joints (12.5 %) in the staple group (two with failure of correction, two with implant

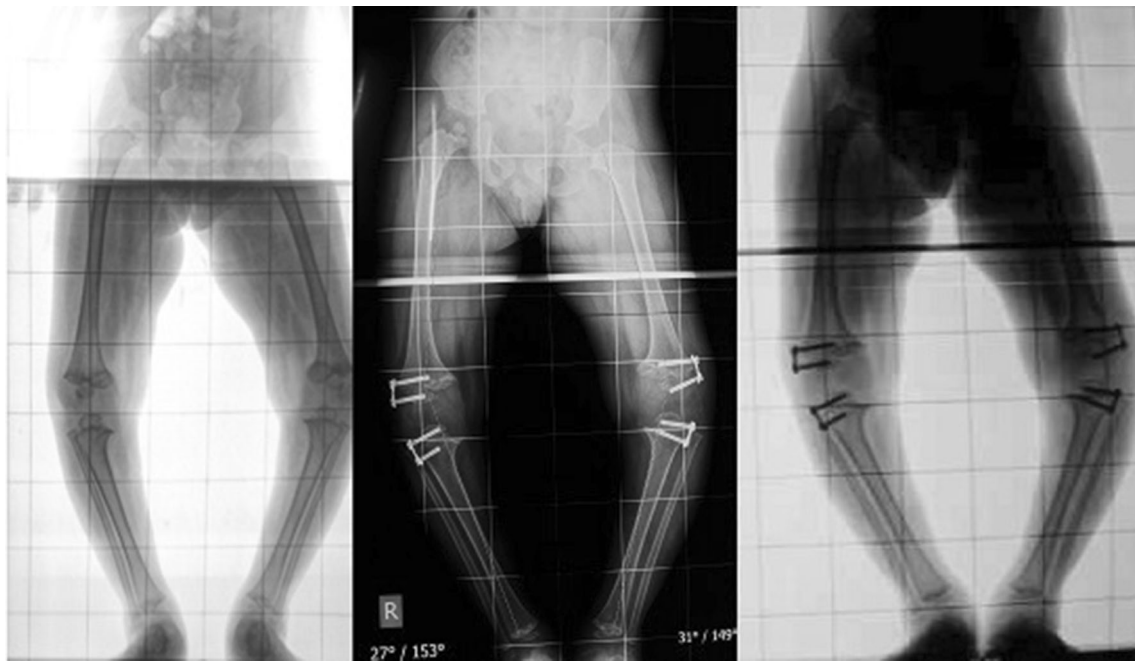

Fig. 4 Radiographs showing failure of correction of deformity in a case of skeletal dysplasia managed with eight plate (8 months and 2 years post-operatively)

extrusion). Two knee joints (6.5 %) in the eight plate group required additional procedure because of failure of correction. Continuing staples for more than 2 years carries the risk of permanent physal failure [9]. This complication has not been reported with figure of eight plate. Thus, we consider it wise to remove the implants if deformity persists for more than 2 years. All patients were screened for limb length discrepancy pre-operatively. Pre-operatively, no patient had discrepancy of more than 1 cm. Three patients in the staple group (two unilateral idiopathic genu valgum, one unilateral post rachitic genu valgum) developed shortening of the affected limb of more than 1 cm, while in the eight plate group, two patients with unilateral idiopathic genu valgum developed limb length discrepancy of more than 1 cm. However, this was statistically insignificant. These patients were given appropriate shoe raise and were advised to wait till skeletal maturity for appropriate intervention. A few patients/parents were concerned about implant prominence, and reassurance was all that was required. Staple extrusion occurred in two knees (Fig. 5), while the eight plate group did not show any implant-related complications.

Discussion

Blount (1948) introduced staples as a means to achieve temporary hemiepiphysiodesis [4]. Although widely used and considered safe, several reports have documented the

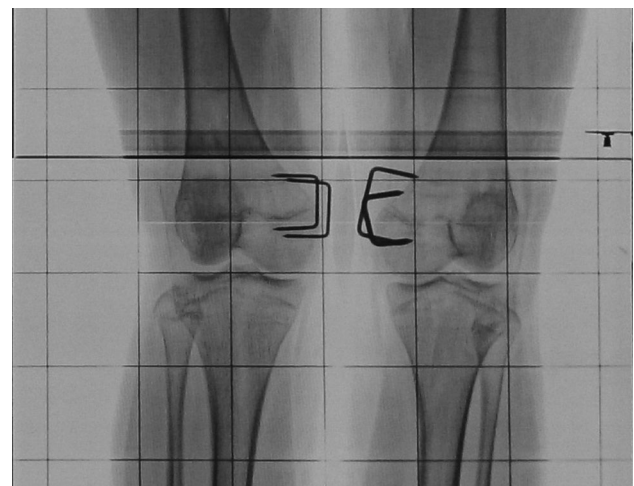

Fig. 5 Radiograph showing complication of stapling (migration) 4 months post-operatively

occurrence of complications with the use of staples [9, 11, 12]. Eight plate was introduced by Stevens as a means to avoid these complications [9]. Hemiepiphysiodesis is based on the Hueter–Volkman principle, which states that compression and tension forces at the physis can cause physal growth inhibition and acceleration, respectively [17]. Contrary to staples, which make a rigid construct providing compression to the physis throughout its length, eight plates act as a dynamic construct with scope for mobility at the screw–plate interface. This is the reason

Table 4 Summary of previous studies comparing the results of staples and eight plates application

	Wiemann et al. [15]	Jelinek et al. [14]	Gottliebsen et al. [16]	Our study
Number of knee joints studied	Staple = 39 Eight plate = 24	Staple = 32 Eight plate = 33	Staple = 10 Eight plate = 10	Staple = 32 Eight plate = 31
Age distribution (in years)	Staple group = 12.6 (range: 8.5–16.7) Eight plate group = 11.1 (range: 5.2–16) <i>p</i> = 0.04 (NS)	Staple group = 11.6 (range: 2.9–16) Eight plate group = 13 (range: 10.5–15.2) <i>p</i> = 0.053 (NS)	Staple group = 11.1 (range: 6–13) Eight plate group = 10.1 (range: 8–14) <i>p</i> > 0.05 (SIG)	Staple group = 7.3 (range: 3.5–12) Eight plate group = 7.8 (range: 4–12) <i>p</i> = 0.53 (NS)
Male:female ratio	Staple group = 24:15 Eight plate group = 11:13 <i>p</i> = 0.298 (NS)	Staple group = 11:7 Eight plate group = 8:9 <i>p</i> = 0.50 (NS)	Staple group = 3:7 Eight plate group = 8:2 <i>p</i> < 0.05 (SIG)	Staple group = 8:10 Eight plate group = 8:11 <i>p</i> = 1 (NS)
Abnormal physes	Staple = 11 Eight plate = 7 <i>p</i> = 1.0 (NS)	Staple = 5 Eight plate = 4 <i>p</i> = 1.0 (NS)	NIL	Staple = 2 Eight plate = 2 <i>p</i> = 1.0 (NS)
Mean correction rate (° per month)	mLDFA = NA mMPTA = NA TFA = 0.825° for staples, 0.925° for eight plate <i>p</i> = 0.489 (NS)	mLDFA = 1° (range: 0–2) for both staples and eight plate <i>p</i> = 0.35 (NS) mMPTA = 1° (range: 0–2) for both staples and eight plate <i>p</i> = 0.56 (NS) TFA = NA	mLDFA = NA mMPTA = NA TFA = NA	mLDFA = 1.0° (range: 0.75–1.25) for staples and 1.3° (range: 0.81–2.25) for eight plate <i>p</i> = 0.004 (SIG) mMPTA = 0.9° (range: 0.75–1.11) for staples and 0.8° (range: 0.56–1.12) for eight plate <i>p</i> = 0.001 (SIG) TFA = 1.2° (range: 0.75–2.33) for staples and 1.4° (range: 1–2) for eight plate <i>p</i> = 0.70 (NS)
Mean time of implant removal	NA	Eight plate 11.9 ± 6.8 months (range: 1.9–27.9 months) Staple 11.0 ± 6.2 months (range: 4.5–28.1 months) <i>p</i> = 0.555 (NS)	Eight plate 11.33 months (range: 9.5–13.1 months) Staple 11.63 months (range: 8.76–14.5 months) <i>p</i> = 0.8 (NS)	Eight plate 10.31 months Staple 12.03 months <i>p</i> = 0.543 (NS)
Complications	Eight plate: Screw breakage = 1 Failure to correct = 3 Staples: Implant migration = 1 Failure to correct = 2 Overcorrection = 3 <i>p</i> = 1.0 (NS) Limb length discrepancy = NA	Eight plate: Overcorrection = 4 Staples: Post-operative wound site infection = 1 Implant migration = 2 <i>p</i> > 0.005 (NS) Failure to correct = NA	Eight plate: Rebound growth = 1 Staples: None	Eight plate: Failure = 2 Limb length discrepancy >1 cm = 2 Staples Failure = 2 Limb length discrepancy >1 cm = 3 Implant migration = 2 <i>p</i> = 0.51 (NS)

NA not mentioned in study, NS not statistically significant difference, SIG statistically significant difference, mMPTA mechanical medial proximal tibial angle, mLDFA mechanical lateral distal femoral angle, TFA anatomical tibio-femoral angle

for staples having a higher risk of breakage and extrusion. In eight plate, maximum compression acts on the peripheral part of the physis at the screw plate junction, where it is actually required. Temporary hemiepiphysiodesis is

applicable to skeletally immature children with open physes and having at least 1 year of growth remaining. Past studies had included a wide range of age groups, from as young as 2 years to those approaching skeletal maturity. In

our study also, we had maintained this wide range (3.5–12 years in the staples group and 4–12 years in the eight plate group). To the best of our knowledge, only three previous studies have compared the results of staples with eight plate [14–16]. These are summarized in Table 4. In a retrospective study by Jelinek et al., during the period 1999–2008, a total of 33 knee angular deformities were treated with figure of eight plate and 32 with staples [14]. The rate of correction was similar in both treatment groups. They reported overcorrection in four cases of eight plate, which we avoided by close follow-up after correction was achieved. This is an avoidable complication. Migration of staples occurred in two cases, which is similar to our series.

In a retrospective study by Wiemann et al. [15], among 38 patients (24 extremities treated with eight plate and 39 with Blount staple temporary hemiepiphyodesis), the rate of correction was higher in the eight plate group, but the difference was not statistically significant. Notably, they reported one case of eight plate screw breakage. The deformity correction rates in our study were comparable to past studies. The tibio-femoral angle (TFA) is a simple and reproducible measurable parameter on standing ortho-röntgenogram. The overall correction rate of TFA in our study was 1.2° per month for the staple group and 1.4° per month for the eight plate group, the difference being statistically insignificant. The improvement in mMPTA was significantly lower in the eight plate group. This could be due to the small number of cases with deformity involving the proximal tibia. In skeletal dysplasia patients with abnormal physes, the correction rate was low in both groups. In idiopathic genu valgum, the correction rate was significantly lower in the staple group.

There were two knee joints with abnormal physis (skeletal dysplasia) in each group. Complications were similar to previous studies. The complication rate was slightly higher in the staple group, but this was statistically insignificant. There was no implant breakage in our series. Implant extrusion was seen in two joints in the staple group. Two failures (persistence of deformity at 2 years) were seen in both groups. Limb length discrepancy of more than 1 cm was seen in three cases in the staple group and two cases in the eight plate group. This has not been described in previous studies [14–16]. There was no case of sagittal plane deformity (flexion deformity or recurvatum deformity) in either group.

Early physiotherapy was recommended to ensure rapid return to daily activities and limit absence from school [18, 19].

Our study was not without limitations. There was an unequal distribution of varus and valgus knees, with valgus knees outnumbering varus knees in both groups. In our study, the minimum follow-up period was 2 years. Long-term follow-up studies for outcomes of eight plate are still

needed. The patients with abnormal mMPTA were fewer than those with abnormal mL DFA. A larger number of the former could have helped in the better analysis of correction of mMPTA.

Conclusion

Both staples and eight plates have similar potential for the correction of angular deformity around the knee in skeletally immature children. However, eight plates have a significantly higher rate of correction in idiopathic deformities. Allowing some overcorrection before implant removal (5° in our study) can prevent rebound deformity. Unlike eight plates, staples carry a risk of migration and extrusion. Abnormal physes as in skeletal dysplasias can lead to inferior outcomes in both groups.

Compliance with ethical standards

Funding None.

Conflict of interest None. No author has any financial conflict of interest with the implant, implant manufacturer, or implant distributor.

Ethical approval All procedures performed in this study were in accordance with the ethical standards of the institution and with the 1964 Helsinki declaration and its later amendments.

Informed consent Informed consent was obtained from all individual participants included in the study.

Open Access This article is distributed under the terms of the Creative Commons Attribution 4.0 International License (<http://creativecommons.org/licenses/by/4.0/>), which permits unrestricted use, distribution, and reproduction in any medium, provided you give appropriate credit to the original author(s) and the source, provide a link to the Creative Commons license, and indicate if changes were made.

References

1. Saini UC, Bali K, Sheth B, Gahlot N, Gahlot A (2010) Normal development of the knee angle in healthy Indian children: a clinical study of 215 children. *J Child Orthop* 4(6):579–586
2. Rang M (1966) *Anthology of orthopaedics*. E & S Livingstone Ltd., Edinburgh
3. Garipey R (1964) Genu varum treated by high tibial osteotomy. *J Bone Joint Surg Br* 46:783–784
4. Blount WP, Clarke GR (1949) Control of bone growth by epiphyseal stapling; a preliminary report. *J Bone Joint Surg Am* 31A(3):464–478
5. Macewen W (1880) *Osteotomy with an inquiry into the aetiology and pathology of knock-knee, bow-leg, and other osseous deformities of the lower limbs*. Churchill, London
6. Smith JO, Wilson AJ, Thomas NP (2013) Osteotomy around the knee: evolution, principles and results. *Knee Surg Sports Traumatol Arthrosc* 21(1):3–22

7. Stevens PM (2006) Guided growth: 1933 to the present. *Strateg Trauma Limb Reconstr* 1(1):29–35
8. Raab P, Wild A, Sellaer K, Krauspe R (2001) Correction of length discrepancies and angular deformities of the leg by Blount's epiphyseal stapling. *Eur J Pediatr* 160(11):668–674
9. Stevens PM (2007) Guided growth for angular correction: a preliminary series using a tension band plate. *J Pediatr Orthop* 27:253–259
10. Métaizeau J-P, Wong-Chung J, Bertrand H, Pasquier P (1998) Percutaneous epiphysiodesis using transphyseal screws (PETS). *J Pediatr Orthop* 18(3):363–369
11. Fraser RK, Dickens DRV, Cole WG (1995) Medial physeal stapling for primary and secondary genu valgum in late childhood and adolescence. *J Bone Joint Surg Br* 77(5):733–735
12. Mielke CH, Stevens PM (1996) Hemiepiphyseal stapling for knee deformities in children younger than 10 years: a preliminary report. *J Pediatr Orthop* 16(4):423–429
13. Stevens PM, Klatt JB (2008) Guided growth for pathological physes: radiographic improvement during realignment. *J Pediatr Orthop* 28(6):632–639
14. Jelinek EM, Bittersohl B, Martiny F, Scharfstädt A, Krauspe R, Westhoff B (2012) The 8-plate versus physeal stapling for temporary hemiepiphysiodesis correcting genu valgum and genu varum: a retrospective analysis of thirty five patients. *Int Orthop* 36(3):599–605
15. Wiemann JM 4th, Tryon C, Szalay EA (2009) Physeal stapling versus 8-plate hemiepiphysiodesis for guided correction of angular deformity about the knee. *J Pediatr Orthop* 29(5):481–485
16. Gottlieb M, Rahbek O, Hvid I, Davidsen M, Hellfritsch MB, Møller-Madsen B (2013) Hemiepiphysiodesis: similar treatment time for tension-band plating and for stapling: a randomized clinical trial on guided growth for idiopathic genu valgum. *Acta Orthop* 84(2):202–206
17. Stokes IAF (2002) Mechanical effects on skeletal growth. *J Musculoskelet Neuronal Interact* 2(3):277–280
18. Fillingham YA, Kroin E, Frank RM, Erickson B, Hellman M, Kogan M (2014) Post-operative delay in return of function following guided growth tension plating and use of corrective physical therapy. *J Child Orthop* 8(3):265–271
19. Fillingham YA, Luthringer T, Erickson BJ, Kogan M (2015) Does physical therapy prevent post-operative delay in return of function following tension-band plating? *J Child Orthop* 9(6):483–487