



Since January 2020 Elsevier has created a COVID-19 resource centre with free information in English and Mandarin on the novel coronavirus COVID-19. The COVID-19 resource centre is hosted on Elsevier Connect, the company's public news and information website.

Elsevier hereby grants permission to make all its COVID-19-related research that is available on the COVID-19 resource centre - including this research content - immediately available in PubMed Central and other publicly funded repositories, such as the WHO COVID database with rights for unrestricted research re-use and analyses in any form or by any means with acknowledgement of the original source. These permissions are granted for free by Elsevier for as long as the COVID-19 resource centre remains active.

Emergency Medicine of the Ferret

Christal Pollock, DVM, DABVP-Avian

30 Severance Circle, Apartment 206, Cleveland Heights, OH 44118, USA

Ferrets most commonly require supportive and critical care for gastrointestinal disease, cardiac disease, neoplasia, or endocrinopathy. The emergency veterinarian must be familiar with anatomy and husbandry that differs from cats and dogs. Various emergency procedures and diagnostics are discussed here, along with diseases most commonly encountered in emergency situations.

The average small animal veterinarian may easily become comfortable with ferrets. Ferrets are hardy and relatively stoic, and as members of the order Carnivora, ferrets are predator species that approach the world in a manner similar to cats and dogs. A small number of medical problems are seen very commonly in ferrets. Careful study of these conditions and attention to the unique aspects of ferret anatomy and behavior prepare the small animal veterinarian for basic emergency care of the ferret.

“Ferret-centric” information

Taxonomy

Ferrets are members of the order Carnivora and family Mustelidae, making them close relatives to the mink, skunk, weasel, and otter. The scientific name of the ferret *Mustela putorius furo* literally translates as “stinky thief.” This name reflects the curious, sometimes mischievous, nature of the ferret and their distinctive musky odor. Most ferrets seen in clinical practice have been de-scented and neutered, which reduces but does not totally eliminate this musky scent. This scent is much more pungent in the intact ferret, particularly the intact male.

The pet ferret is not an exotic animal whose natural environment must be duplicated in captivity [1]. Ferrets have been domesticated for more than 2000 years. In the United Kingdom and Canada, ferrets are generally

E-mail address: christal7@mac.com

outdoor pets used for hunting rabbits, groundhogs, and other small mammals. Their long, skinny shape allows ferrets to follow prey down into burrows and flush them out so they may be captured with nets or snares. Ferrets are popular indoor pets in the United States. Most American ferrets come from large ferret farms or ranches where they are neutered and de-scented at an early age. Despite their domesticity and popularity, ferrets are poorly understood. There are many state, county, or city laws that describe them as “wild,” “non-domestic,” or “dangerous” animals [2].

Vocabulary terms and physiologic values

A female ferret is a “jill,” and a male ferret is a “hob.” Probably the most common term used by pet owners is “kit,” which designates a neonatal or juvenile ferret. Less commonly used by pet owners are terms such as “gib” (neutered male) and “sprite” (neutered female) [2]. Selected physiologic values for the domestic ferret are given in Table 1.

Anatomy

Knowledge of basic carnivore anatomy is an excellent starting point for dealing with the ferret; however, there are some unique anatomic characteristics of the ferret. First, the ferret spine is extremely flexible, allowing 180° turns within narrow passageways. The vertebral formula is C7 T15 L5 (6 or 7) S3 Cd18 [2].

As strict carnivores designed to eat small, whole prey, ferrets possess a short, simple gastrointestinal tract with no cecum or ileocolic valve.

Table 1
Basic biologic characteristics of the ferret [36]

Life stage	
Achieve adult size	3–4 months
Puberty	4–5 months
Sexual maturity	6–12 months
Lifespan	6–8 years (maximum, 10–12 years)
Adult body weight	0.6–1.2 kg*
Temperature	100°F–103°F
Pulse	170–250 bpm
Respiratory rate	32–36 bpm
Litter size	1–18 kits (average, 8)
Gestation	41–43 days
Birth weight	6–12 g
Eyes and ears open	32 and 24 days
Weaning age	6–8 weeks
Body weight	Males 0.8–1.2 kg; females 0.6–1.0 kg
Dental formula	2 (I 3/3 C1/1 P3/3 M1/2 = 34
Urine volume	26–28 mL/24 h
Vertebral formula	C7 T15 L5 (6 or 7) S3 Cd18

* Males are larger, weighing 0.8 to 1.2 kg, while females are smaller and more petite.

Transit time is rapid and may be as brief as 3 hours. The presence of only minimal microbial flora means the ferret gut handles most antibiotics well. This same lack of microbial flora means that carbohydrates are digested poorly and fiber not at all. The dental formula of the ferret is $2 (I\ 3/3\ C1/1\ P3/3\ M1/2) = 34$ [2,3].

Husbandry

Nutrition

Ferrets require high quality, animal-based dietary protein. Diets should contain 30% to 35% crude protein and 15% to 20% fat. Typical diets fed to pet ferrets in the United States include commercial ferret foods and good quality cat foods.

When feeding the hospitalized ferret, always learn about the home diet, because some individuals may resist sudden dietary changes. Also ask if the ferret drinks from a water bottle or bowl. Dishes should be heavy enough to prevent the curious ferret from overturning them. Unless drastically overfilled, a large bowl makes it difficult for the ferret to access the food, so small or shallow dishes work best. Food should be available at all times unless the ferret is being fasted, because the normal ferret eats small amounts of food frequently [4].

Good choices for feeding the anorectic ferret include Prescription Diet a/d (Hill's Pet Nutrition; Topeka, KS), Carnivore Care (Oxbow Pet Product; Murdock, NE), and Eukanuba Maximum-Calorie (The Iams Company; Dayton, OH). Chicken baby food is readily accepted and may be fed on a short-term basis [2,4]. Warming food may increase acceptability. Nutri-Cal (Tomyln; EVSCO Pharmaceuticals; Buena, NJ), Ferrotone (8-in-1 Pet Products; Hauppauge, NY) and other sugar-containing formulations can cause rebound hypoglycemia in ferrets with insulinoma and should be avoided in those animals.

Illness quickly leads to minimal body fat stores and then cachexia. Hepatic lipidoses develops quickly in the ferret, and therefore enteral nutrition is recommended after initial stabilization with fluids. The ferret is easily force-fed by holding the ferret by the "scruff" in one hand and force-feeding with the other hand. When syringe feeding a ferret, begin with 5 to 10 mL per feeding at least three to four times daily. Small, extremely weak, or highly resistant ferrets should be offered a minimum of 2 to 3 mL more frequently. Large ferrets with good appetites may take up to 20 mL per meal. Try offering water to debilitated ferrets in a shallow crock, even if the individual normally drinks from a water bottle.

For long-term management, esophagostomy or pharyngostomy tubes may be considered in rare instances. Place an 8- to 10-Fr feeding tube using the same method described for cats. Apply a butterfly tape piece to the tube, suture it into place, and add a light wrap around neck [5,6]. Gastric feeding tubes have been placed experimentally in the ferret, but not in clinical

patients [7]. When the gut must be bypassed, partial or total parenteral nutrition may also be used [6].

Housing the pet ferret

Ferrets are often kept in large, multilevel cages at home. They also require supervised exercise outside of the cage within “ferret-proofed” rooms. Ferret proofing includes all measures taken to keep the pet ferret safe. Holes to the outside or to areas from which ferrets cannot be retrieved are blocked. The bottoms of all couches, chairs, and mattresses are covered with a thin piece of wood or hardware cloth to prevent burrowing and chewing in soft foam rubber. Access to foam or latex rubber should also be avoided, because ferrets often chew such items, including athletic shoe soles, rubber bands, stereo speakers, and headphones. Reclining chairs have been implicated in the death of many ferrets and should be removed from any ferret-proofed environment [2,6].

In the hospital, maintain ferrets in escape-proof enclosures, because they can squeeze through openings as small as 1 inch in diameter if there is any give to the material. Probably the best choice for ferret housing is a standard stainless steel cage with small spacing between vertical bars. Cages with larger bar spacing may be adapted by attaching a piece of Plexiglas to the cage front at least half the height of the door or taller. This Plexiglas cover prevents escape and is easily removed for cleaning. Hospitalized ferrets may also be maintained in plastic rabbit cages, avian hospital cages, or incubators. Monitor ferrets closely in avian cages or incubators, because they may easily overheat [4,6].

Always provide burrowing material, such as a large towel or pillowcase, unless the patient requires an intravenous or urinary catheter. In these cases, remove burrowing material or provide something small like a surgical towel, otherwise the line will invariably become entangled as the ferret burrows.

Ferrets often use a back corner of the cage as a latrine; therefore, place the litter box in the back of the cage. Offer a pan with one very low side for weak or ataxic ferrets [4].

Handling and restraint

Except for their natural, exuberant wiggleness, most ferrets are easily handled using minimal restraint. Gently grasp the ferret around the chest with one hand while lightly supporting the rump with the other hand. Most ferrets also relax when held snugly but gently against the body with a flexed arm. With the exception of kits, most ferrets rarely bite when handled gently [4].

Manual restraint is required for uncomfortable procedures such as checking body temperature. There are two main methods of physical restraint of the ferret: scruffing and stretching. To scruff, gently yet firmly grasp the ferret by the loose skin at the nape of the neck (Fig. 1). Then allow the ferret to hang from its scruff with all four feet suspended off the ground. In many

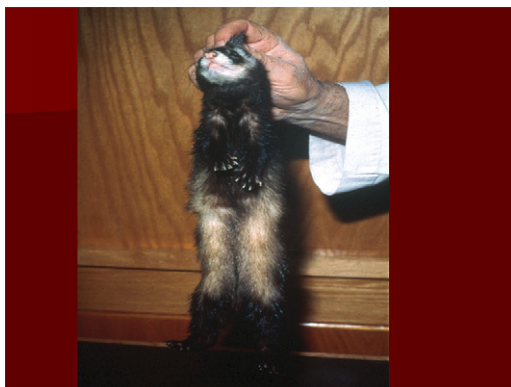

Fig. 1. Scruff the ferret by gently yet firmly grasping the loose skin at the nape of the neck, then suspend all four feet off the ground.

ferrets, this causes total and complete relaxation, including a jaw-popping yawn.

To stretch, hold the ferret in lateral recumbency while grasping the scruff in one hand and placing the other hand securely around the pelvis. Do not hold the rear limbs, as one would in a cat, because this always makes ferrets struggle. A distraction, like Nutri-Cal or meat baby food, may also prove helpful as long as the ferret is not being restrained to check blood glucose levels.

Hospital personnel with influenza should avoid contact with ferrets [6].

Anamnesis

Signalment and history are crucial in developing an initial differential diagnosis list (Tables 2 and 3) [6]. After discussing the reason for presentation, including onset and progression of clinical signs, obtain a detailed general history. What diet is fed at home, including treats? Low quality cat food containing plant-based protein promotes development of struvite crystalluria. Does the ferret drink from a water bottle or bowl? What is the housing set-up? Is the ferret usually caged? Anecdotally, lack of time outside the cage for exercise and play has been correlated with increased incidence of *Helicobacter* gastritis. This is most likely related to increased boredom and stress when playtime is not offered. When out of the cage, is the ferret supervised and is the environment ferret-proofed? Is the pet a chewer? Have any toys or household items been recently destroyed? Younger ferrets commonly chew rubber and sponge material with increased risk for foreign body ingestion. And who is the primary caretaker? Whenever a young child is in the household, the risk for trauma increases greatly.

Discuss details of the ferret's medical history, including appetite, activity level, and eliminations. Has there been any vomiting or diarrhea? What is the vaccination status? Although the incidence of disease is

Table 2
Important differentials in the ferret based on clinical signs

Clinical sign	Differential diagnoses	Comments
Alopecia		
Metabolic	Adrenal disease Ovarian remnant disease Seasonal alopecia	(Tail); hair typically regrows in several weeks, may be more common in males
Anorexia		
Metabolic	Cardiomyopathy Ovarian remnant disease Urethral obstruction	
Neoplasia	Lymphosarcoma	
Idiopathic	Myofasciitis	
Infectious, inflammatory	Epizootic catarrhal enteritis Proliferative bowel disease	
Trauma	Gastrointestinal foreign body	
Ascites		
Metabolic	Cardiomyopathy	
Neoplasia	Lymphosarcoma	
Ataxia		
Metabolic	Insulinoma Cardiomyopathy	
Idiopathic	Myofasciitis	
Collapse	See <i>Weakness</i>	
Constipation		Rare in the ferret, more likely stranguria or dysuria
Depression		
Metabolic	Insulinoma Cardiomyopathy Urethral obstruction	
Neoplasia	Lymphosarcoma	
Idiopathic	Myofasciitis	
Infectious, inflammatory	Epizootic catarrhal enteritis	
Trauma	Gastrointestinal foreign body Traumatic household injury Heat stroke	
Diarrhea		
Metabolic	(Ovarian remnant disease) (Renal disease) (Liver disease)	(Melena)
Nutritional	Dietary indiscretion	
Infectious, inflammatory	Helicobacter gastritis Proliferative bowel disease Lymphocytic-plasmacytic gastroenteritis Eosinophilic gastroenteritis	(Large bowel)

(continued on next page)

Table 2 (continued)

Clinical sign	Differential diagnoses	Comments
	Epizootic catarrhal enteritis	(Green, mucoid; "bird seed" appearance)
	Influenza	(Transient diarrhea sometimes occurs)
	<i>Campylobacter</i>	Hematochezia, fever
	<i>Salmonella</i>	Hematochezia, fever
	(<i>Giardia</i>)	
	(Coccidiosis)	
Trauma	Gastrointestinal foreign body	
	Trichobezoar	
	Heat stroke	Melena, bloody diarrhea
Toxin	(Toxin exposure)	
Dyspnea		
Metabolic	Cardiomyopathy	
Neoplasia	Lymphosarcoma	Cranial mediastinal mass or pulmonary involvement
Infectious, inflammatory	Influenza virus	
Trauma	Traumatic household injury	
	Heat stroke	Associated with tachypnea
Dysuria	See <i>Stranguria</i>	
Ecchymosis	See <i>Petechia</i>	
Fever		
Idiopathic	Myofasciitis	
Infectious, inflammatory	Influenza virus	
	Canine distemper virus	
Trauma	Overheating, including heat stroke or exhaustion	
Lethargy	See <i>Depression</i>	
Lymphadenopathy		
Neoplasia	Lymphosarcoma	
Nausea, vomiting		
Metabolic	Insulinoma	
	Renal disease ^a	
	Hepatic disease ^a	
Inflammatory, infectious	<i>Helicobacter gastritis</i>	
	Lymphocytic-plasmacytic gastroenteritis	
	Eosinophilic gastroenteritis	
	Epizootic catarrhal enteritis	
Trauma	Gastrointestinal foreign body ^a	
	Heat stroke	
Petechia		
Metabolic	Ovarian remnant disease	
Pruritus		
Metabolic	Adrenal disease	
Inflammatory, infectious	(Ectoparasites) Cardiomyopathy	

(continued on next page)

Table 2 (continued)

Clinical sign	Differential diagnoses	Comments
Rear limb weakness^b		
Metabolic	Insulinoma Cardiomyopathy	
Idiopathic	Myofasciitis	
Trauma	Traumatic household injury	
Rectal prolapse		
Inflammatory, infectious	Proliferative bowel disease (Coccidiosis) (Neoplasia)	
Respiratory signs		
Metabolic	Cardiomyopathy	
Inflammatory, infectious	Influenza	
Seizure activity		
Metabolic	Insulinoma	
Trauma	Heat stroke	
Skin mass		
	Mast cell tumor	
Stranguria		
Nutritional	Struvite crystalluria	
Metabolic	Prostatomegaly secondary to adrenal disease	
Inflammatory, infectious	(Cystitis) (Prostatic abscess)	
Vulvar swelling		
Metabolic	Adrenal disease Ovarian remnant disease Intact female	
Weakness		
Metabolic	Insulinoma Ovarian remnant disease	
Neoplasia	Lymphosarcoma	
Idiopathic	Myofasciitis	

The most important or common differentials are **bolded**.

^a Vomiting is rare, but may occur intermittently.

^b Anything that causes generalized weakness may initially manifest as rear limb weakness in the ferret.

rare, ferrets are exquisitely sensitive to canine distemper virus. Ferrets are also prone to vaccination reactions. Has there been exposure to a new animal recently, or has the ferret visited a show or pet store? Epizootic catarrhal enteritis may develop after exposure with a young, newly acquired ferret.

Know ferret-specific signs of disease. Signs of nausea in the ferret may include copious drooling (ptyalism) and pawing vigorously at the mouth, in addition to retching and gagging. Signs of abdominal pain may include bruxism or teeth grinding.

Table 3
Important differentials in the ferret based on clinical pathologic findings

Test result	Differential diagnoses	Comments
Hypoglycemia		
Metabolic	Insulinoma (Liver disease) Heat stroke	
Inflammatory, infectious	Sepsis	
Anemia		
Metabolic	Ovarian remnant disease Adrenal disease	Pancytopenia Mild to moderate nonregenerative
Neoplasia	Lymphosarcoma	Nonregenerative
Inflammatory, infectious	<i>Helicobacter</i> gastritis	Regenerative anemia
Trauma	Gastrointestinal foreign body Flea bite infestation	Regenerative anemia
Azotemia		
Metabolic	Urethral obstruction Heat stroke	
Hyperkalemia		
Metabolic	Urethral obstruction Heat stroke	
Elevated ALT		
Metabolic	Hepatic lipidosis secondary to insulinoma Cardiomyopathy	
Creatine kinase, elevated		
Metabolic	Heat stroke	
Idiopathic	Myofasciitis	

Physical examination

Cardiopulmonary arrest requires immediate treatment (see the article on shock and fluid resuscitation elsewhere in this issue).

Modify the length of the physical examination based on the ferret's cardiopulmonary status. Place any ferret showing signs of respiratory distress in an oxygen-rich environment. Carefully observe the ferret's breathing pattern and auscult respiratory sounds. The long, thin chest of the ferret places the apex heart beat more caudally than in the cat or dog. The heart sits between the sixth and eighth ribs, usually three to four ribs caudal to the elbow. Auscult the entire length of the thoracic cavity, ideally with the use of a pediatric or infant stethoscope. A common finding in the ferret is a prominent respiratory sinus arrhythmia. There are five different breathing patterns associated with audible or auscultated sounds that help to localize the cause of respiratory distress.

Breathing patterns

An upper airway lesion creates a normal breathing pattern with a loud inspiratory wheeze [8–10]. Referred upper airway sounds are heard on auscultation of the chest. Potential causes of laryngeal obstruction include foreign body, neoplasia, or abscess of the upper airway. Laryngeal paralysis has not been reported in the ferret. Perform an oral examination to identify the obstruction for biopsy, culture and sensitivity, or removal of the foreign body.

Lower airway lesions such as tracheal obstruction also create a normal breathing pattern, but this is associated with soft expiratory stridor, pronounced gagging, and swallowing. Upper airway sounds are present on auscultation.

Small airway disease creates a soft expiratory wheeze with synchronous movement of the chest and abdomen. There is a wheezing sound on auscultation of the chest. The lesion is located within the small bronchi and is usually secondary to a small airway inhalant toxin or asthma. This is very rare in the ferret.

There are no audible respiratory sounds in parenchymal disease; however, there is synchronous movement of the chest and abdomen. Respiratory wheezes are heard on auscultation of the chest. Differentials include pulmonary edema secondary to heart disease (see Cardiovascular disease) and pneumonia (see Respiratory disease).

Pleural space disease creates no audible respiratory sounds, but a dyssynchronous breathing pattern is observed with the chest and abdomen moving opposite to each other. Dull lung sounds are heard on auscultation of the chest. The pleural space is filled with air (pneumothorax) or blood (hemothorax) in cases of trauma, or pleural effusion in cases of cardiac disease or lymphosarcoma (see Cardiac disease and Neoplasia).

When the cardiovascular and pulmonary systems are normal, physical examination may be continued in a systematic fashion. Normal physiologic parameters are given in [Table 1](#). Evaluate the moistness of the mucous membranes for evidence of dehydration and treat with fluids as described in the article on shock and fluid therapy by Lichtenberger elsewhere in this issue. Ferrets derived from a ferret farm have two small dots tattooed in the pinna of the right ear. This tattoo signifies that the ferret has been de-scented and neutered. Within the ears, it is common to find dark brown, waxy discharge. Excessive wax or more commonly granular ear discharge may be associated with *Otodectes cyanotis* mite infestation [11]. Broken canines are a common finding in older ferrets.

Lymph nodes may feel enlarged in big male or overweight ferrets because of the presence of surrounding fat, but the nodes still feel soft and pliable. Firmness or asymmetry of the lymph nodes suggests lymphadenopathy and warrants fine-needle aspiration. Enlargement of two or more nodes justifies a full diagnostic workup.

Palpate the abdomen while lifting the front half of the ferret off the table. Ferrets normally have relaxed abdomens that are easy to palpate. The normal ferret spleen is large for the size of the animal, measuring approximately 5 cm long, 2 cm wide, and 1 cm thick [6]. Palpate the spleen gently for clean edges and homogenous consistency. Splenomegaly is a common incidental finding in ferrets older than 1 year of age, most frequently caused by extramedullary hematopoiesis. Even a spleen so big and pendulous that the animal has difficulty lifting its abdomen off the ground may not be pathologic in origin. Ultrasonography and fine-needle aspirate cytology may be indicated for evaluation of the enlarged spleen [2,6,11].

Examine the hair coat for evidence of alopecia, particularly over the flanks, shoulders, and tail base. Seasonal alopecia is a common finding in which fur falls out, typically along the tail, and then regrows within several weeks. Also check for evidence of skin excoriations, which may be created in the pruritic ferret.

Ferrets are easy to sex. The prepuce is on the ventral abdomen just caudal to the umbilicus, and the os penis is readily palpable. Check the prepuce for redness, which may be seen with excessive licking when urogenital disease leads to discomfort. The female urogenital opening is a slit in the perineal region just ventral to the anus. Always check for vulvar swelling, which may be observed with estrus, ovarian remnant syndrome, or adrenal disease (Fig. 2).

Allow the ferret to walk around the room at the end of the examination. Signs of generalized weakness may include a loss of the normal hump in the back while in motion and rear limb weakness or ataxia. A ferret allowed to explore an examination room often eliminates in one corner. Normal stool is slightly soft and formed.

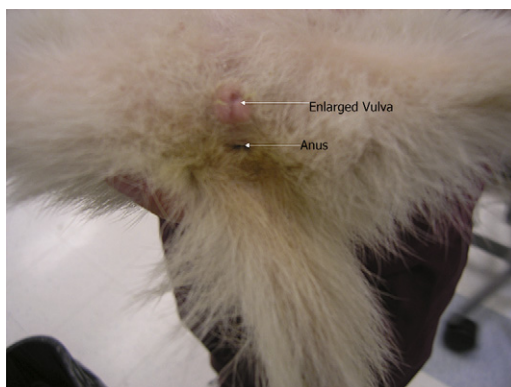


Fig. 2. This figure shows vulvar swelling in the female ferret. Female ferrets should always be evaluated for vulvar swelling on physical examination. Vulvar swelling may develop with estrus, ovarian remnant syndrome, or adrenal disease.

Diagnostics and therapeutics

Clinical pathology

Ideally one should obtain a biochemistry panel and complete blood count, including reticulocyte count, in the debilitated ferret. Minimum stat blood work should include hematocrit, total protein, blood glucose level, and blood urea nitrogen (BUN).

Normal hematocrit is higher in the ferret (46%–61%), and erythrocyte counts may be as high as 17.4×10^6 cells/ μ L. The normal mean reticulocyte count for female albino ferrets is 5.3% and 4% for male albino ferrets. Reticulocyte counts may be as high as 10% or even exceed 12% with regenerative anemia. The white cell count in ferrets normally ranges from 2500 to 8000 cells/cm. Typically neutrophils predominate, with lymphocyte counts usually less than 50%. Normal total protein is 5.1 to 7.4 g/dL [12].

Isoflurane and sevoflurane significantly decrease hematocrit, hemoglobin, plasma protein, red blood cell count, and white cell count. Maximum effects occur 15 minutes after induction. Values should return to their original state 45 minutes after anesthesia [13–15].

Biochemistry panel

Ferret biochemistry values are similar to those found in other mammals with few exceptions. For instance, liver enzyme values and serum bile acids are similar to those of dogs and cats. Alanine aminotransferase (ALT), serum alkaline phosphatase (ALP), total bilirubin levels, and serum bile acids increase with liver disease and liver dysfunction.

Blood glucose levels normally range from 90 to 120 mg/dL in the fasting ferret. Insulinoma is a very common disease of middle-aged to older ferrets, leading to hypoglycemia. Blood glucose levels less than 90 mg/dL are suspicious for insulinoma in the fasting ferret, whereas levels less than 70 mg/dL are strongly suggestive of insulinoma. Ferrets suspected of having insulinoma do not necessarily need to be fasted. When fasting is performed, it should last for no more than 2 to 3 hours, and the patient should be carefully monitored during that time.

Normal serum creatinine in the ferret is usually half that seen in the dog and cat. Creatinine often ranges from 0.1 to 0.3 mg/dL and is almost always less than 0.5 mg/dL. Elevations in creatinine may be incremental, if they occur at all [16]. Creatinine levels between 0.7 to 1.0 mg/dL signify azotemia in the ferret. Always be sure to evaluate serum phosphorus and urine specific gravity (USG) in any ferret suspected of having renal disease. Elevations in BUN and phosphorus are common with renal disease. Ferret urine is usually isosthenuric with a USG between 1.010 and 1.115 in chronic renal failure [2].

Normal electrolyte values are similar to those in a cat. Lactate measurements are normally between 1 and 3 mmol/dL. Electrolyte values are

elevated in the poorly perfused ferret and decrease with fluid resuscitation as in the dog and cat (M. Lichtenberger, personal communication, 2007).

Venipuncture

Restraint for venipuncture is challenging in the conscious ferret. Practice venipuncture on healthy anesthetized patients or cadavers. Inhalant anesthesia lowers hematocrit and white blood cell count and is not recommended for the purpose of collecting a blood sample in the critically ill patient.

Use a 1- to 3-mL syringe paired with a 25- to 27-gauge needle in most ferrets. In large males, a 22- or 23-gauge needle may also be used for jugular venipuncture. A small 0.3- to 0.5-mL insulin syringe with a 28- to 30-gauge needle may be used for small vessels. The thick skin of the ferret necessitates use of a new, sharp needle with every venipuncture attempt. The maximum volume of blood that may be collected in healthy ferrets is 1% of body weight in grams. Place samples in microtainers (Calgary Laboratory Services; Calgary, AB, Canada) [2,12].

There are several options for venipuncture sites. The jugular vein and cranial vena cava are the most popular sites for collection of large blood volumes. The jugular vein lies in a more lateral position than in the cat and dog. The thick skin over the neck can sometimes make it difficult to find the vessel.

Blood collection from the cranial vena cava is easily done on the conscious ferret with practice. The heart is located caudal in the chest, making caval venipuncture safe. Lay the ferret on its back with its forelimbs extended straight down toward its tail. Palpate a slight depression or notch between the manubrium and first rib. Slowly insert a 25-gauge needle attached to a 1- or 3-mL syringe at a 45° angle to the skin. Aim the needle at the opposite hip and slowly insert the needle to the level of the hub while gently applying negative pressure. Then slowly withdraw the needle until the syringe begins to fill with blood (Fig. 3). If the patient moves, remove the needle quickly to avoid lacerating the vessel. Avoid caval sticks in patients in which pancytopenia is suspected [11].

The lateral saphenous is a good alternative, especially for collection of smaller blood volumes. This vessel may be easiest to access when using the straight segment of the vessel, which lies proximal to the tarsus, as in the dog.

Venous catheterization

The cephalic vein is the best site for intravenous catheter placement. This vessel is usually visible, but the overlying skin may be thick. A 22-gauge needle with the bevel side up may be used to make a small nick in the skin to prevent burring of the catheter. Ferrets rarely chew at catheter sites. Alternative sites for catheter placement include the lateral saphenous vein and the jugular vein [6,11].

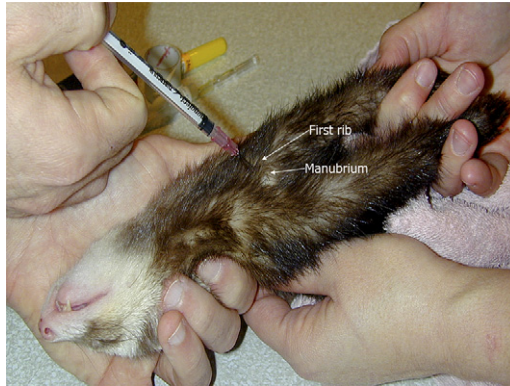

Fig. 3. The cranial vena cava is an alternate site for collection of large blood volumes. The ferret is wrapped in a towel and both forelegs are pulled back. The second person extends the neck and inserts a 25-gauge needle with an attached 1 mL syringe between the manubrium and first rib at a 45° angle and directed toward the opposite back leg. Insert the needle to the hub and pull back on plunger as the needle is slowly withdrawn until blood begins to fill the syringe.

An intraosseous catheter can be placed when intravenous catheterization fails. The lateral tibia and proximal femur are the most common sites for placement. Use a 22-gauge spinal needle with a stylet or a 20- or 18-gauge hypodermic needle. Use sterilized orthopedic wire within the hypodermic needle as a stylet to prevent occlusion with bone marrow. Aseptically prepare the skin and inject 0.1 mL of lidocaine 2% with 0.1 mL bupivacaine 0.5% into the periosteum, subcutaneous tissue, and skin.

Urinalysis

As in dogs and cats, there are multiple options for urine collection. Cystocentesis, when indicated, may be performed by palpation or guided by ultrasound. Insert the needle through the lateral body wall as in the cat. Use a 3- to 6-mL syringe attached to a 1-inch, 22- to 25-gauge needle. Some ferrets may be manually restrained, whereas others may require sedation with buprenorphine or butorphanol (see the article on analgesia/anesthesia elsewhere in this issue). Repeated cystocentesis is not recommended because of the thin bladder wall.

Radiology

Whole body radiographs are generally taken in ferrets using tabletop technique, high-speed film, and fine screen cassettes. The appearance of the normal ferret radiograph is similar to that of other carnivorous species [11].

The long, lean body shape of the ferret means that the heart is positioned more caudally within the thoracic cavity. The normal ferret heart may seem

slightly more globoid on survey radiographs. On lateral films, the right ventricle may seem slightly elevated from the sternum because of the accumulation of fat around the ligament, which extends from heart to sternum. This normal finding should not be confused with the presence of pneumothorax. When evaluating the thoracic cavity, be sure to include the cranial thorax [6,11]. The size of the cardiac silhouette can be quantified by use of the modified vertebral heart score (VHS), which measures heart length and width on the right lateral radiograph. These measurements are added together and expressed in centimeters. Normal mean VHS value in the ferret is 4.00 cm (range, 3.75–4.07 cm) (Fig. 4) [17].

There is normally a large amount of fat outlining abdominal organs in the ferret. Splenomegaly is a common finding. The stomach is normally devoid of gas, whereas there is little to no gas in the intestinal tract [16,18].

Contrast radiography

Give barium at 8 to 15 mL/kg by mouth or by stomach tube for upper gastrointestinal evaluation. Strawberry flavored barium is readily accepted by ferrets. When a gastrointestinal perforation is suspected, use iohexol mixed with tap water at a 1:1 ratio at the same dose. Take radiographs immediately and then at 5, 10, 20, 40, 60, 90, 120, and 150 minutes after the barium is administered. Gastric emptying usually begins immediately, although total emptying of the stomach takes longer in sedated ferrets than in awake ferrets (130 ± 40 minutes and 75 ± 54 minutes, respectively). The barium-filled small intestines are best visualized at 20 and 40 minutes. The width of the small bowel does not normally exceed 5 to 7 mm [11,16].

When performing an excretory urogram, the recommended intravenous dosage is 2 mL/kg of iodinated contrast agent [2].

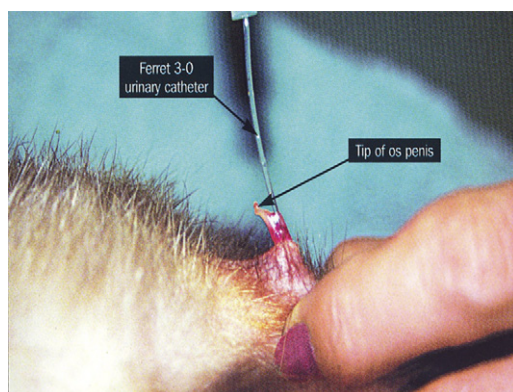


Fig. 4. Urethral catheterization of a male ferret using a 3-French urinary catheter. The S shape of the tip of the penis is shown.

Ultrasonography

Ultrasound is commonly performed to evaluate abdominal organs as in cats and dogs. Measurements that differ from those in cats are kidneys measuring 3×3 cm and adrenal gland width less than 3 mm [2].

Normal echocardiographic measurements have also been evaluated in the ferret (Table 4) [19,20]. The most common heart disease in the ferret is dilated cardiomyopathy, although hypertrophic cardiomyopathy, mitral valvular disease, and heartworm disease have been described.

Electrocardiogram

Apply flattened ECG clips to these small patients. Also use ECG coupling gel for awake ferrets, because they often object strongly to the use of alcohol. It may help to distract the ferret by slowly giving Nutri-Cal or chicken baby food by syringe. The most common ECG results include sinus arrhythmia and sinus tachycardia. For more information on monitoring, see the article by Lichtenberger elsewhere in this issue.

Lymph node aspiration

A good, representative lymph node aspirate may be difficult to obtain because of the large amount of fat that often surrounds peripheral lymph nodes in the ferret. Carefully palpate the enlarged, firm node to distinguish it from the surrounding fat. Use a 25- to 22-gauge needle and stab the gland multiple times [11]. Attach an air-filled 6-mL syringe to the needle and push the sample onto the slide, then spread the sample gently and evenly across the slide.

Although a lymph node biopsy is not an emergency procedure, popliteal nodectomy may be indicated if lymph node aspiration cannot be used to

Table 4
Echocardiographic variables in the normal, anesthetized, male ferret [26]

Parameter	Mean value \pm SD	Range
Age (months)	10–20	—
Gender	—	—
Body weight (kg)	1.4 ± 0.2	—
Heart rate (bpm)	196.0 ± 26.5	140–240
Mean electrical axis, frontal plane (degrees)	$+86.13 \pm 2.50$	79.6–90.0
Lead II measurements		
P amplitude (mV)	n/a	n/a
P duration (sec)	n/a	n/a
PR interval (sec)	0.0560 ± 0.0086	0.04–0.08
QRS duration (sec)	0.0440 ± 0.0079	0.035–0.060
R amplitude (mV)	2.21 ± 0.42	1.4–3.0
QT interval (sec)	0.109 ± 0.018	0.08–0.14

Abbreviation: n/a, not available.

achieve a representative cytologic sample. Popliteal nodectomy is generally associated with minimal, if any, bleeding [2].

Splenic aspiration

Clip a small region of fur, aseptically clean the site, then palpate and immobilize the spleen. Splenic aspiration may be performed on awake ferrets with good restraint, although anesthesia or sedation may be indicated for ultrasound-guided aspiration of a focal lesion. Use a 22- to 25-gauge needle and a 3-mL syringe [11].

Bone marrow aspiration

Bone marrow aspiration is performed as in cats and dogs under anesthesia. Potential sites include the iliac crest, humerus, and the proximal femur, with the proximal femur being the most popular site. Clip a small area of overlying fur, aseptically prepare the site, and make a small skin incision using a 15 blade. Use an 18- to 20-gauge, 1.5-in spinal needle or a Jamshidi biopsy needle attached to a 6-mL syringe [11].

Tracheal wash

Tracheal wash is best performed as in the cat, through a sterile endotracheal tube with a red rubber catheter. Infuse at least 2 to 3 mL of sterile saline [11].

Urinary catheter placement

Urinary catheter placement may be challenging in the male ferret because of its small size and a J-shaped os penis. Anesthesia is required for adequate muscle relaxation and restraint in the form of gas anesthesia or parenteral combinations (see the article by Lichtenberger and Ko on analgesia/anesthesia elsewhere in this issue). Avoid high-dose ketamine in ferrets that have urethral obstruction. Most ferrets should be intubated and maintained on isoflurane or sevoflurane when anesthetized for extended periods. Using a 24-gauge catheter with the needle removed may be helpful in finding and dilating the urethral opening. Afterward, a 3-Fr 11-in ferret urinary catheter (Slippery Sam, Global Veterinary Products; New Buffalo, MI) or a 22- or 20-gauge jugular catheter may be placed in most ferrets (Fig. 5). Use a 3.5-Fr red rubber catheter in larger males. Pre-measure the length of red rubber or jugular catheters. Keeping red rubber catheters in the freezer until time of placement may enhance ease of insertion. Leaving the jugular catheter stylet in place may also facilitate careful passage. Resistance most often occurs as the catheter is passed around the pelvic flexure. Gently flush the urethra with sterile saline solution to help the catheter pass.

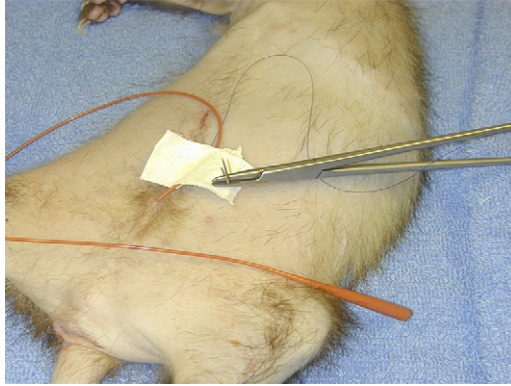


Fig. 5. Urethral catheterization using a 3.5-French red rubber catheter and suturing in place using a tape butterfly.

When urinary catheterization proves difficult, removing a small amount of urine once by way of cystocentesis can reduce pressure and allow passage of the urinary catheter. Repeated cystocentesis is not recommended because of the thin and possibly necrotic bladder wall, which may easily rupture. When catheter placement fails, a percutaneous cystostomy may be performed (see later discussion on urethral obstruction).

Suture butterfly tape strips near the prepuce to secure the catheter, then fasten the catheter or attached tubing to the tail base to minimize tension on the line (Fig. 6). Bandaging the ferret's abdomen may also minimize risk for rotation. Attach a closed collection system using a small intravenous bag

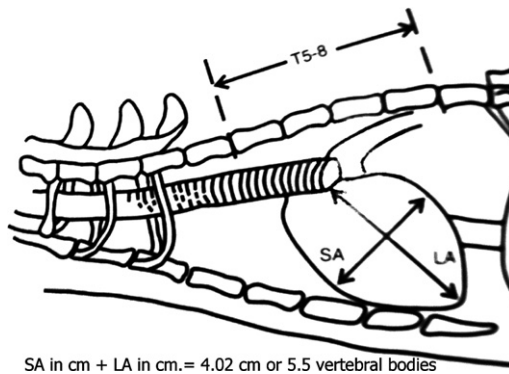


Fig. 6. Drawings of lateral (*right*) views of the thorax indicating measurements of the cardiac silhouette in long axis (*LA*) and short axis (*SA*). The sum of the *LA* and *SA* measurements is expressed in centimeters or in vertebrae length, beginning at the cranial edge of the fifth thoracic vertebrae (*T5*) and estimated to the nearest 0.25 vertebrae. The vertebrae width and length measurements are added to obtain a vertebrae heart score. (*Adapted from* Stepien RL, Benson KG, Forrest LJ. Radiographic measurement of cardiac size in normal ferrets. *Vet Radiol Ultrasound* 1999;40:606–10).

and monitor urine production. The normal ferret produces 26 to 28 mL of urine over a 24-hour period (range, 8–48 mL) [11,21].

Female ferret

Place the female ferret in ventral recumbency and elevate the rear quarters with a rolled towel. Aseptically prepare the vulva and perivulvar region, and then insert a vaginal speculum or otoscope. Locate the urethral opening on the floor of the vestibule 1 cm cranial to the clitoral fossa. Introduce a 3.5-Fr red rubber catheter, which may be fitted with a wire stylet [6].

Thoracocentesis

Use a 21- to 23-gauge butterfly catheter attached to a 12-mL syringe and stopcock to remove air or fluid for cytologic evaluation and culture. Ultrasonography may be helpful in guiding needle insertion. Ferrets rarely allow thoracocentesis with manual restraint alone, and needle laceration of the lung may occur when the ferret struggles. Consider chemical restraint using isoflurane, sevoflurane, or etomidate (2 mg/kg intravenously) with midazolam (0.25–0.50 mg/kg intravenously) before this procedure (M. Lichtenberger, personal communication, 2006). Repeat survey radiographs and echocardiogram afterward for more detailed evaluation of the thoracic cavity.

Pain management

As a general rule, ferrets are stoic animals. Anticipate procedures and conditions that should be painful and provide preemptive analgesia. Signs of pain in the ferret may include anorexia, lethargy, crying, stiff movements, inability to sleep in a natural, curled position, and squinting (see the article by Lichtenberger and Ko on analgesia and anesthesia elsewhere in this issue) [11].

Drug therapy

Dosages for medications administered to ferrets are often extrapolated from small animal medicine (Table 5). Ferrets are difficult to pill, and the recommended form of oral drug administration is liquid, especially sweet pediatric suspensions or syrups. Avoid fish flavors. Many drugs available only in tablet form may be compounded with the help of a pharmacist or crushed and mixed with a small amount of Nutri-Cal or baby food. Even when the formulation should be palatable, the ferret may still need to be scruffed for successful drug administration. It is common for ferrets to drool or paw violently at the mouth after bitter medications such as metronidazole are given [11].

Metabolism of acetaminophen is slow in ferrets. Activity of the hepatic enzyme, glucuronosyltransferase, is similar to that of cats [22].

Table 5
Drug dosages for ferrets [7,5,15,24]

Drug	Dosage	Route	Frequency	Comments
Amoxicillin	10–20 mg/kg	PO	Every 12 h	Give with metronidazole and for management of <i>Helicobacter</i> gastritis
Amoxicillin/clavulanate	22 mg/kg	PO	Every 8 h	Respiratory or UTI
Cephalexin	15 mg/kg	PO	Every 12 h	Antibiotic well suited for respiratory or urinary tract infections
Chloramphenicol	50 mg/kg	PO, SC, IM	Every 12 h	Careful to warn owners of aplastic anemia (see text on PBD)
Chlorpheniramine	1–2 mg/kg	PO	Every 8–12 h	Antihistamine that may relieve some symptoms of upper respiratory tract disease
Cisapride	0.5 mg/kg	PO	Every 8–24 h	
Dexamethasone sodium phosphate	0.2 mg/kg	IV		Slow bolus with insulinoma
Diazoxide	5–30 mg/kg	PO	Every 12 h	
Digoxin	0.01mg/kg	PO	Every 12–24 h	
Diphenhydramine	0.5–2.0 mg/kg	IM, IV	Every 8–12 h	Hypersensitivity reaction
	2–4 mg/kg	PO		Upper respiratory disease
Enalapril	0.5 mg/kg	PO	Every 48 h	
Enrofloxacin	5 mg/kg	PO	Every 12 h	
Etomidate	1–2 mg/kg	IV		Always combined midazolam/diazepam
Famotidine	0.25–0.50 mg/kg	PO, IM, IV	Every 24 h	Histamine blocker
Fipronil (Frontline)	1 pump of spray or 1/5 th of cat tube	Topical	Every 30–60 d	
Furosemide	1–4 mg/kg	PO, SC, IM	Every 8–12 h	
Human chorionic gonadotropin	100 IU	IM		Repeat in 7d if vulvar swelling has not resolved with estrogen toxicity
Imidacloprid (Advantage)	1 cat dose	Topical	Every 30 d	

Ivermectin	0.2–0.4 mg/kg 0.05 mg/kg	PO, SC PO, SC	Once Every 30 d	Repeat in 14 d for anthelmintic treatment Heartworm prevention
Leuprolide acetate	125 ug/kg 250–400 ug/kg	IM IM		Adrenal disease Urethral obstruction secondary to adrenal disease
Lufenuron	30–45 mg/kg	PO	Every 30 d	
Metoclopramide	0.2–1.0 mg/kg	PO, SC	Every 6–8 h	
Metronidazole	20 mg/kg	PO	Every 12 h	Give with amoxicillin and bismuth in the management of <i>Helicobacter</i> gastritis
Prednisolone sodium succinate	22 mg/kg	IV		Slow bolus
Prednisone, prednisolone	0.5–2.0 mg/kg	PO, SC	Every 12–24 h	Insulinoma (be sure to use an alcohol-free formulation such as Pediapred)
Ranitidine	0.25–1.00 mg/kg	PO, SC	Every 12 h	Inflammatory bowel disease
Selamectin	2–4 mg/kg	PO	Every 8 h	Histamine blocker
Sucralfate	6 mg/kg 25–100 mg/kg	Topical PO	Every 6–8 h	Stagger administration of sucralfate with other drugs and feedings that must be absorbed orally and so sucralfate is given on an empty stomach
Terbutaline	0.01 mg/kg	SC, IM		
Trimethoprim/sulfa	30 mg/kg	PO	Every 12 h	

Abbreviations: IM, intramuscular; IV, intravenous; IT, intratracheal; PO, per os; SC, subcutaneous.

Acetaminophen ingestion leads to methemoglobinemia and seizure activity. Treatment for intoxication is similar to that in a cat.

Care must be given when administering any nonsteroidal anti-inflammatory drug (NSAID) to the debilitated ferret. NSAIDs promote a reduction in renal blood flow, gastrointestinal ulceration, and platelet dysfunction. Because of the salicylate present in the preparation, use of bismuth subsalicylate (Pepto-Bismol, Proctor & Gamble; Cincinnati, OH) is not recommended in the treatment of *Helicobacter* gastritis (M. Lichtenberger, personal communication, 2007).

Common diseases of the ferret

Gastrointestinal diseases

In addition to gagging and retching, signs of nausea in the ferret may include heavy drooling and clawing vigorously at the mouth. A unique sign of abdominal pain in the ferret is bruxism or teeth grinding.

Gastrointestinal foreign body

Gastrointestinal (GI) foreign bodies are common in young ferrets younger than 1 to 2 years of age. Ferrets enjoy chewing foam, sponge, or soft rubber items, such as shoe soles or latex rubber toys. Linear foreign bodies are rare. When outside of the cage, affected ferrets may go unsupervised in a home that is not ferret-proofed (see earlier section on housing the pet ferret).

The most consistent clinical signs of GI foreign body are anorexia and subsequent weight loss and lethargy. Depending on the location of the foreign body, the poor appetite may wax and wane. Signs of nausea and abdominal pain and diarrhea, potentially including melena, are variably seen. Vomiting is rare.

Some foreign bodies may be palpable on physical examination, especially intestinal foreign bodies. A foreign body may be associated with variable amounts of gas within the gut and evidence of segmental ileus on survey radiographs. Obstruction is typically associated with gaseous distension of the stomach or a pronounced intestinal gas pattern [16]. A barium series may also help to identify complete obstruction; however, the soft, spongy materials usually eaten by the ferret are rarely identified directly on films.

Treatment of GI foreign body depends on the location of the object and the clinical signs of the patient. Initially the patient should be rehydrated (see the article by Lichtenberger elsewhere in this issue). Some partial obstructions may pass after fluid therapy, but many foreign body obstructions require surgical removal.

Helicobacter gastritis

One of the reasons ferrets are kept as laboratory animals is for the study of the commensal microbe, *Helicobacter mustelae*. In many individuals, *Helicobacter* is not associated with disease; however, this organism may

overgrow with stress or concurrent disease leading to gastritis and ulcers. *Helicobacter* gastritis may be reported in any age ferret. There may have been a recent change in the ferret's environment, such as introduction of a new ferret or moving to a new home. The incidence of disease may also be higher in ferrets that are caged continuously. Ferrets require at least a couple of hours of exercise daily.

Onset of clinical signs of *Helicobacter* gastritis may be acute or chronic. Nonspecific signs of illness, such as anorexia, lethargy, and weight loss, as well as vomiting, ptyalism, pawing at the mouth, bruxism, and diarrhea, including melena, may be observed.

Diagnosis of *Helicobacter* gastritis is often presumptive. Complete blood count results may include regenerative anemia and microcytosis. Radiographic findings may be similar to those seen with gastrointestinal foreign body (variable amounts of gas, segmental ileus).

Specific treatment for *Helicobacter* gastritis in the ferret is based on amoxicillin and metronidazole paired with sucralfate and the histamine (H₂) blocker, ranitidine or famotidine. Combination of metronidazole and amoxicillin is much more effective than any one of these drugs alone, and in fact, use of a single drug may promote microbial resistance. Because of the presence of salicylate, bismuth subsalicylate is not recommended (M. Lichtenberger, personal communication, 2007). The newer generation macrolide, clarithromycin, may be used in ferrets nonresponsive to antibiotics, H₂ blockers, and sucralfate. Supportive care should include fluid therapy and force-feeding (see earlier discussion on nutritional support).

Epizootic catarrhal enteritis

First recognized in the early 1990s, epizootic catarrhal enteritis or ECE is strongly believed to be caused by coronavirus [23]. Although all ages may be affected, clinical disease is generally mild in young ferrets and most severe in middle-aged to older ferrets. History with ECE may involve exposure to a new, young ferret that may have had mild, transient diarrhea.

Clinical signs of ECE include nonspecific signs of illness (anorexia, lethargy), vomiting, and diarrhea. Diarrhea may be variable in appearance; however, stool may be profuse, green, and mucoid or brown with many mucosal shreds (also known as "bird seed stool"). Diagnosis is usually one of exclusion, although definitive diagnosis requires biopsy and histopathology. Radiographic evidence of profound gastrointestinal ileus may be observed.

Treatment focuses on aggressive fluid therapy and kaolin-pectin or sucralfate. Antibiotics are a reasonable part of empiric treatment, because bacteria such as *Campylobacter* may also cause enteritis. Isolate all ferrets that are suspected to have ECE [2].

Proliferative bowel disease

The obligate intracellular bacteria, *Lawsonia intracellularis*, cause proliferative bowel disease or PBD. Although prevalence of disease is low, PBD is

most commonly seen in young ferrets, particularly those ranging from 10 to 16 weeks of age. Improvement in ferret nutrition is believed to be responsible for the decreasing incidence of PBD.

Clinical signs include anorexia, weight loss, and large bowel diarrhea (blood, mucus, excessive straining, and increased frequency of defecation). Severe tenesmus may lead to rectal prolapse in some kits. Thickened loops of bowel may be palpated on physical examination. Perform fecal parasite testing to exclude the presence of coccidia. Survey radiographs and baseline blood work may also be indicated.

Rehydrate ferrets and administer antibiotics, such as metronidazole, amoxicillin, or chloramphenicol, if diarrhea is present. Provide latex gloves for the owner administering chloramphenicol, and warn of the potential for rare, idiosyncratic aplastic anemia in humans. In rare instances, a dose-related, reversible anemia has also been reported in other species [20]. Mild rectal prolapse may resolve with antibiotic treatment alone, while the delicate tissue is protected with a gentle, topical zinc oxide preparation. In rare instances, purse-string sutures are required for more severe prolapses. Stay sutures may be left in place up to 3 days [2].

Lymphocytic-plasmacytic gastroenteritis and eosinophilic gastroenteritis

Infiltrative or inflammatory bowel diseases are generally seen in middle-aged to older ferrets. Although no clinical studies have been performed, eosinophilic gastroenteritis is theorized to be associated with parasite infestation or food allergy. Clinical signs may include anorexia, chronic weight loss, chronic diarrhea, and vomiting, as well as signs of nausea and abdominal pain. Some ferrets treated for presumptive ECE, *Helicobacter* gastritis, or PBD may develop chronic gastrointestinal signs caused by inflammatory bowel disease. Physical examination may reveal thickened intestinal loops and enlarged mesenteric lymph nodes. Stabilize ferrets with fluids before obtaining a definitive diagnosis through pediatric endoscopy or surgical gastric and intestinal biopsies. Although the anthelmintic, ivermectin, may be administered to ferrets with eosinophilic gastroenteritis, prednisone seems to be the mainstay of treatment for both conditions. Other medications that have been tried include azathioprine and metronidazole [2,3].

Endocrine diseases of ferrets

Insulinoma

Insulinoma or pancreatic beta cell tumor is commonly seen in middle-aged to older pet ferrets in the United States. Presentation of clinical signs varies. Affected ferrets may exhibit acute onset, intermittent episodes of hypoglycemia, or clinical signs that may develop slowly and insidiously. Signs of hypoglycemia frequently include depression, a dazed or glazed appearance in the eyes (star-gazing), posterior paresis and ataxia, and signs of nausea (copious drooling, pawing at the mouth, retching, and gagging).

Affected ferrets may begin to sleep longer and harder. If hypoglycemia becomes severe enough the ferret may collapse. Seizure activity may be seen with severe hypoglycemia.

Physical examination is often unremarkable except for evidence of generalized weakness, such as posterior paresis, ataxia, or collapse, and possible weight loss. Signs of concurrent illness are common in middle-aged to older ferrets, particularly signs of adrenal disease discussed later.

Diagnosis of insulinoma generally relies on history, clinical findings, and persistent hypoglycemia. Normal fasting blood glucose levels range from 90 to 120 mg/dL. Fasting blood glucose less than 90 mg/dL is suspicious for insulinoma; blood glucose less than 70 mg/dL is strongly suggestive. If insulinoma is suspected, it is not necessary to fast the ferret; however, if fasting is performed, do so for no more than 2 to 3 hours while monitoring the ferret closely and carefully. Until proven otherwise, a ferret with persistent hypoglycemia almost invariably has insulinoma. Insulin/glucose ratios are not useful for diagnosing insulinomas in ferrets. Starvation may also lead to hypoglycemia. Other, rare causes of hypoglycemia in the ferret include liver disease, neoplasia, sepsis, starvation, and heatstroke.

The remainder of the biochemistry panel is usually normal in ferrets with insulinoma. Liver enzyme elevation may occur with secondary hepatic lipodosis, or much less commonly, metastasis of the beta cell tumor to the liver.

Survey whole-body radiographs are usually unremarkable, although incidental splenomegaly may be observed. Abdominal ultrasonography may reveal nodular enlargements near the stomach that can, in rare instances, be large beta cell tumor nodules. More commonly these nodules represent lymphadenopathy of the prominent lymph nodes that lie along the lesser curvature of the stomach.

Mild to moderate hypoglycemic episodes may be managed on an outpatient basis. If the ferret is alert enough to swallow, feed an easily digestible, animal protein-based food such as Oxbow Carnivore Care or Hill's prescription diet a/d. Avoid sugar-based products such as Nutri-Cal, because they may promote rebound hypoglycemia.

Hospitalization is recommended for severe hypoglycemic episodes that do not respond to oral treatments or that include profound signs of hypoglycemia, such as collapse or seizure activity. Administer 0.25 to 0.50 mL of 50% dextrose slow bolus intravenously over at least 10 to 15 minutes. Dilute 50% dextrose in a 1:1 concentration with saline or sterile water. If dextrose is administered alone, the functional beta cell tumor may be stimulated to secrete more insulin. This can lead to an ever-worsening cycle of hypoglycemia, dextrose administration, and subsequent insulin secretion; therefore, also administer dexamethasone sodium phosphate (0.1 mg/kg intravenously) to facilitate entry of glucose into the cells (M. Lichtenberger, personal communication, 2007).

Depending on clinical response to intravenous dextrose bolus, the ferret may then be fed a high-protein meal or the patient may require constant rate

infusion containing 2.5% to 5% dextrose. When a ferret with insulinoma is maintained on intravenous fluids, it is essential that infusion truly be continuous. Starting and stopping fluids containing dextrose only stimulates insulin secretion and potentially worsens the patient's condition.

Concurrent administration of prednisolone solution or syrup (1 mg/kg orally every 12 hours) also promotes uptake of glucose by cells. Use an alcohol-free formulation (Pediapred Oral Liquid, Celltech Pharmaceuticals; Rochester, NY), because alcohol lowers blood glucose. Diazoxide is a secondary drug used for the treatment of insulinoma. Diazoxide is frequently ineffective in ferrets that have not already responded to medical management. It is rarely used in emergency situations unless the ferret continues to be unresponsive. Adverse effects of diazoxide may include nausea and vomiting.

When a ferret presents with hypoglycemic seizures nonresponsive to dextrose administration, give midazolam (0.2–0.5 mg/kg intravenously) or diazepam (1–2 mg intravenously to effect). If additional anticonvulsant therapy is needed, administer phenobarbital (4 mg/kg intravenously every 20 minutes for two doses), and continue the patient on oral phenobarbital (2 mg/kg every 12 hours) if need be. Oral phenobarbital may be given for up to 6 weeks and then slowly tapered off over a 2-week period (M. Lichtenberger, personal communication, 2007).

If the ferret continues to suffer from persistent and severe hypoglycemia, then constant rate infusion dexamethasone (0.5–1.0 mg/kg slow bolus intravenously over 6 hours, repeat every 12–24 hours as needed) may prove helpful [24]. The rare ferret suffering from severe signs of insulinoma does not respond to medical management and requires surgical debulking of the pancreas for clinical signs to resolve. Although only a palliative measure, surgical debulking of the beta cell tumor is the treatment of choice. Exploratory laparotomy should always be performed at this time, because many ferrets have concurrent adrenal gland disease.

Client education is crucial for owners of affected ferrets. Teach owners to recognize signs of hypoglycemia and to prevent hypoglycemic episodes from occurring. Owners (and clinicians) should recognize situations that may use blood glucose and may precipitate a hypoglycemic crisis, such as stress, travel, and exercise. Minimize stressors whenever possible and ensure that the ferret eats afterward. Other important preventive measures include feeding high-protein, meat-based foods frequently and avoiding foods containing simple sugars and carbohydrates.

Ovarian remnant syndrome

Ferrets are induced ovulators. Approximately half of estrous females remain in heat until bred or artificially stimulated to ovulate. Persistent estrus leads to estrogen toxicity of hematopoietic tissue and subsequent severe, potentially fatal, pancytopenia. Persistent estrus used to be a common

problem; however, now that ferret farms routinely spay ferrets before they are purchased, this condition is much less common. Today, persistent estrus is most commonly observed in spayed female ferrets less than 2 years of age when a portion of the ovary is accidentally left at the time of the early spay procedure.

Clinical signs include lethargy, weakness, pallor, vulvar swelling, and possibly vulvar discharge. Severe disease is also associated with evidence of bleeding (melena, petechia, ecchymoses) secondary to thrombocytopenia and endocrine alopecia.

Diagnosis relies on physical examination, complete blood count, and reticulocyte count. Abdominal ultrasound and bone marrow aspirate cytology are also recommended. Affected ferrets require aggressive supportive care. Ferrets with severe anemia benefit from oxygen administration and intravenous Oxyglobin (Biopure; Cambridge, MA) (11–15 mL/kg over 4 hours) until a blood transfusion is available (see article by Lichtenberger elsewhere in this issue) [25,26]. Leuprolide acetate or human chorionic gonadotropin may prove effective in reducing estrogen levels. Definitive treatment is exploratory surgery to excise the ovarian remnant.

Adrenal disease

Adrenal disease of the ferret involves hyperplasia, benign neoplasia, or malignant neoplasia of the zona reticularis. Disease of this adrenal tissue leads to an increase in sex hormones (estrogens, progestins, and androgens) and not glucocorticoids. Adrenal disease is extremely common in middle-aged to older neutered ferrets in the United States. Adrenal disease is common in ferrets in the United States. Pathogenesis of disease in the United States is likely multifactorial and is theorized to include early sterilization, consumption of processed diets, and exposure to artificial photoperiods [2].

The most consistent clinical sign of adrenal disease is dorsally symmetric endocrine alopecia, which typically begins over the tail base and flanks or less commonly over the shoulders. Approximately one third of affected ferrets also display intense pruritus. Approximately 75% of affected females have vulvar swelling. Affected males occasionally develop dysuria or stranguria secondary to androgen-induced prostatomegaly. Adrenomegaly may be palpable on physical examination in some cases [2].

Minimum database findings are frequently unremarkable. Ferrets with long-standing adrenal disease may have mild to moderate nonregenerative anemia. Survey whole-body radiographs are usually not helpful. Calcification is rare, and only profoundly enlarged adrenals may be seen on survey films [2].

Ultrasonography is a diagnostic test of choice. The width of the normal adrenal gland is usually 3 mm or less. Adrenal gland disease is associated with widening of the adrenal gland from a classic lentil bean shape to a football shape that often measures at least 3.5 mm across. Diagnosis of adrenal

disease in the ferret may also be based on the University of Tennessee's adrenal hormone panel, which measures three sex hormones, including estradiol, 17-hydroxyprogesterone, and androstenedione. Levels that exceed normal are highly suggestive of adrenal disease, although false negatives are possible [2].

The treatment of choice for adrenal disease is surgery. When surgery is not an option because of poor condition, extreme old age, or financial concerns, medical management involves use of hormonal manipulation, such as leuprolide acetate or melatonin [2,27].

Diabetes

Diabetes mellitus is uncommon in the ferret. The condition is most commonly a transient sequela to surgical pancreatic debulking for insulinoma. Treatment is rarely necessary in this scenario, but when initiated it is extrapolated directly from care of cats and dogs [28].

Neoplasia

The most common neoplasms of the ferret are adrenal disease and insulinoma (see section on endocrinology).

Lymphosarcoma

Lymphosarcoma or lymphoma is the third most common neoplasm of the ferret. Neoplasia involving mature, well-differentiated lymphocytes or lymphocytic lymphoma is most common in older ferrets. Disease most commonly affects lymph nodes, followed by spread to parenchyma. Affected ferrets may be presented for chronic or intermittent lethargy, anorexia, and subsequent weight loss. The most common physical examination finding is generalized lymphadenopathy in which lymph nodes feel firm or asymmetric instead of soft and pliable.

Young ferrets younger than 2 years of age are more commonly afflicted with lymphoblastic lymphosarcoma. Cranial mediastinal masses frequently lead to pleural effusion and dyspnea. On physical examination, the chest is noncompressible, and no heart murmurs or arrhythmias are detected. Although uncommon, pulmonary metastasis may occur with lymphocytic or lymphoblastic lymphosarcoma [2].

Diagnosis of lymphosarcoma relies on cytologic or histologic evaluation of lymph nodes or pleural fluid. Because splenic lymphoma is uncommon in the ferret, splenic aspirates generally reveal extramedullary hematopoiesis. White blood counts are variable, and lymphocyte counts may be markedly elevated. Nonregenerative anemia may be mild to marked. Biochemistry panel results may reflect neoplastic infiltration of organs or concurrent illness.

Chemotherapy protocols in the ferret have been extrapolated from the care of cats and dogs. Ferrets tolerate chemotherapy well; however, only

approximately 10% experience remission. If traditional multiagent chemotherapy is not an option, palliative treatment with prednisone (2.2 mg/kg orally every 24 hours) may reduce tumor burden for several months (M. Lichtenberger, personal communication, 2007).

Dermatologic neoplasia

The most common skin tumor of middle-aged to older ferrets is the basal cell tumor. Basal tumors often appear as small, white or pink growths that may have a depressed center. Mast cell tumors are the second most common skin neoplasm. Mast cell tumors are typically small, round, and slightly raised; lesions often bleed and scab over. Both of these tumors are typically benign in ferrets; surgical excision and biopsy is recommended and considered curative [2,29].

Hematopoietic

Anemia

After confirming the presence of anemia, examine the peripheral blood smear for microcytosis or polychromasia, evaluate red blood cell indices, such as mean corpuscular volume (MCV) and mean corpuscular hemoglobin concentration (MCHC), and perform a reticulocyte count. Changes observed with regenerative anemia may include microcytosis or microcytosis and an elevated reticulocyte count. Nonregenerative anemia is associated with normocytic–normochromic red blood cells.

Regenerative anemia in the ferret is most commonly caused by gastrointestinal bleeding secondary to *Helicobacter* gastritis. Heavy flea infestation may also cause regenerative anemia, particularly in juvenile ferrets. Immune-mediated hemolytic anemia has not been identified in ferrets.

The most common cause of nonregenerative anemia in the ferret is anemia of chronic disease caused by adrenal disease. Anemia is generally mild to moderate in adrenal disease. Although incidence is uncommon, estrogen toxicity secondary to ovarian remnant syndrome is the most important cause of profound pancytopenia, including nonregenerative anemia (see section on endocrine disease). Neoplastic infiltration of bone marrow by lymphoma (see section on neoplasia) is another potential cause of pancytopenia.

Thrombocytopenia

Primary immune-mediated thrombocytopenia has not been reported in the ferret. Thrombocytopenia has been reported with estrous-induced pancytopenia.

Coagulopathies

Coagulopathies are rarely reported in the ferret, perhaps because normal coagulation parameters are rarely available (see earlier discussion on blood

work for coagulation normals). Coagulopathy secondary to warfarin ingestion has been seen (M. Lichtenberger, personal communication, 2007).

Cardiovascular disease

Heart disease is frequently reported in middle-aged to older ferrets. The most common cardiac disease is dilated cardiomyopathy (DCM). Other heart conditions reported in the ferret include valvular heart disease, hypertrophic cardiomyopathy, and heartworm disease. Because of the small size of the ferret heart, even the presence of one *Dirofilaria immitis* worm can lead to heart failure.

Clinical signs of heart disease in the ferret are similar to those observed in cats and dogs. Nonspecific signs of illness often predominate, such as lethargy, anorexia, weight loss, pallor, and weakness. These signs may not be appreciated until disease is advanced. Additional signs of heart disease may include evidence of generalized weakness, such as posterior paresis or ataxia, and dyspnea or tachypnea.

On physical examination, ascites may be detected in addition to the aforementioned clinical signs. Auscultation may identify a heart murmur, tachycardia, or arrhythmia. Muffled heart sounds may be recognized with pleural effusion, whereas pulmonary edema may lead to harsh lung sounds. Coughing is usually absent.

Stabilize any ferret that presents in distress before performing diagnostic tests. Provide cage rest in an oxygen-rich environment. Low-dose butorphanol (0.4 mg/kg subcutaneously, intramuscularly, intravenously) may help to relieve stress and anxiety.

When heart failure results in a parenchymal disease breathing pattern (see earlier discussion on respiratory distress) and harsh lung sounds, treat for pulmonary edema with furosemide (2–3 mg/kg intravenously, intramuscularly, subcutaneously). Repeat furosemide in 30 minutes if there is no improvement. Nitroglycerine paste (NitroBID, Hoechst Marion Roussel, Kansas City, Missouri) 1/8th inch is placed on the gums or tongue. Continue the ferret on continuous rate infusion furosemide (0.2 mg/kg/h intravenously) for 12 hours.

If respiratory distress is present with a dyssynchronous breathing pattern (see earlier discussion on respiratory distress) and muffled breath sounds, pleural disease is most likely. Perform thoracocentesis under anesthesia. Induce with midazolam (0.5 mg/kg intravenously) and etomidate (1–2 mg/kg intravenously) and then intubate the patient. During the brief anesthesia, other additional diagnostics may be performed (M. Lichtenberger, personal communication, 2006).

Obtain radiographs, echocardiography, electrocardiography, and blood pressure readings when the ferret is stable. Complete blood count and biochemistry panel should also be obtained. If only a limited amount of blood is available, be sure to evaluate electrolytes, BUN, creatinine, blood glucose, and hematocrit.

Although there are several tests to diagnose heartworm disease in small animals, none of these tests are validated for use in ferrets. Microfilarias are identified on blood smears in only 25% to 50% of cases. Antigen and antibody testing used in cats may be met with false negative results. Echocardiography is currently the most reliable test in the ferret to confirm the presence of adult worms within the heart [10,19].

Base treatment protocols for heart disease on diagnostic test results. Enalapril, digoxin, and furosemide dosages have all been extrapolated from cats and dogs. Treatment of heartworm disease includes ivermectin (0.05 mg/kg orally, subcutaneously monthly) and prednisone (1 mg/kg orally every 24 hours) until disease has been cleared. Melarsomine (Immiticide, Merial; Duluth, GA) (2.5–3.25 mg/kg deep intramuscularly once under isoflurane sedation, followed 30 days later by two doses at 2.5–3.25 mg/kg 24 hours apart) also seems to be effective and its use may hasten recovery [30,31]. Some ferrets develop complications including anaphylaxis, however, so premedicate with diphenhydramine (0.5–2.0 mg/kg). Heartworm preventive medication (such as once-monthly ivermectin) is recommended for ferrets in climates where such medication is also recommended for the pet cat.

Respiratory disease

Human influenza virus

Several strains of human influenza virus can infect ferrets. Flu may be transmitted from people to ferrets, from ferrets to people, and from ferret to ferret. Disease can appear within 48 hours of exposure, so always ask if anyone in the household has been ill.

Clinical disease most consistently includes signs of upper respiratory infection: nasal discharge, sneezing, severe congestion, fever, and profound lethargy and anorexia. Lower respiratory involvement is less common and often leads to secondary bacterial pneumonia. Ferrets with the flu often seem moribund; however, the death rate in adults is fortunately low. Course of disease typically lasts 7 to 14 days. Treatment frequently includes intensive supportive care (feeding and fluid therapy) and antihistamines such as diphenhydramine (2–4 mg/kg orally every 8–12 hours) to help relieve severe congestion [2].

Bacterial pneumonia

Although bacterial pneumonia may occur secondary to influenza virus infection, primary bacterial pneumonia is uncommon in the ferret.

Anterior mediastinal masses

Cranial mediastinal masses caused by lymphosarcoma are often associated with pleural effusion and dyspnea in young ferrets (as seen earlier in the discussion on lymphosarcoma). Definitive diagnosis is with ultrasound or computer tomography-guided aspiration of the mass, laparoscopy, or surgical biopsy.

Canine distemper virus

Ferrets are exquisitely sensitive to canine distemper virus (CDV). Although the incidence of CDV is rare in pet ferrets in the United States, this disease should always be considered in any unvaccinated individual with consistent signs. Clinical signs include fever, anorexia, oculonasal discharge, coughing, hyperkeratosis of footpads, and a rash involving the lips and chin. Vomiting and diarrhea are uncommon in the ferret with CDV, whereas neurologic signs may be seen with advanced infection. The mortality rate is 100% [2].

Urogenital disease

The two most important causes of urinary tract disease in the male ferret are prostatomegaly secondary to adrenal disease. Struvite uroliths used to be common problems before commercial ferret diets were improved. Urolithiasis was most commonly seen in adult males on a plant-based protein diet such as poor quality cat food. Plant-based protein promotes the development of alkaline urine and the precipitation of magnesium ammonium phosphate or struvite crystals [2].

Currently the most important cause of urethral obstruction is prostatomegaly secondary to adrenal disease. An increase in androgens leads to squamous metaplasia of prostatic glandular epithelium and the development of thick-walled prostatic cysts. In some cases the cysts become infected. Prostatic disease unrelated to adrenal disease, such as abscesses and neoplasia, is rare in the ferret [2].

Clinical signs associated with urolithiasis or prostatic disease may include pollakiuria, stranguria, or dysuria. Owners may misinterpret the straining observed as "constipation." Frequent dribbling may create a wet, urine-stained perineum, and the prepuce may be red from frequent licking. Ferrets are frequently depressed, weak, and very painful. In some instances, these nonspecific signs of illness may be observed without noticeable signs of dysuria [2,6,11].

Diagnosis of urogenital disease relies on signalment, history, and clinical findings. With urethral obstruction, a distended bladder is readily palpable on physical examination.

In the case of urethral obstruction, urinary catheterization is an emergency procedure (see earlier discussion on urethral catheterization and anesthesia). When catheter placement fails, temporary percutaneous cystostomy may be performed to provide cutaneous urinary diversion until definitive treatment may be performed. Temporary cystostomy tube placement is performed as in the dog and cat (Fig. 7). The cystostomy tube may be maintained for 1 to 3 days with use of sedation such as continuous rate infusion fentanyl-ketamine (see the article by Lichtenberger and Ko on analgesia and anesthesia elsewhere in this issue) (Fig. 8). Surgery for the treatment of prostatomegaly is performed only when the ferret is stable. The

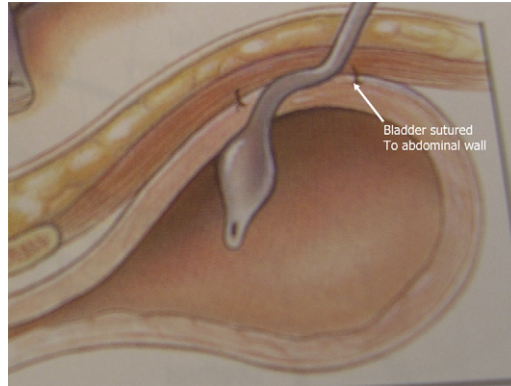


Fig. 7. Placement of a percutaneous cystostomy tube. The diagram shows the Foley catheter in place within the bladder. The bladder wall is sutured to the abdominal wall.

cystostomy catheter is removed following medical or surgical treatment and after the ferret is urinating on its own. Remove the catheter by simply removing skin sutures and deflating the Foley catheter. Allow the wound to heal by secondary intention [32,33].

While placing the urinary catheter under anesthesia, carefully monitor the electrocardiogram for evidence of hyperkalemia. Signs of hyperkalemia include loss of the P wave, widening of the QRS complex, peaked T waves, and a short QY interval. Relief of obstruction and forced diuresis is usually sufficient in the management of hyperkalemia. Medical treatment of hyperkalemia is indicated if an arrhythmia is present in addition to poor perfusion or altered mentation. Give calcium gluconate (50–100 mg/kg slowly bolus intravenously) while carefully monitoring the ECG to temporarily stabilize myocardium, or administer regular insulin (0.2 U/kg intravenously) followed by glucose (1–2 g intravenously for every unit of insulin) to prevent



Fig. 8. The ferret is shown with a percutaneous catheter bandaged in place. The ferret is maintained on fluids for support and on a continuous rate infusion (CRI) of fentanyl/ketamine.

hypoglycemia. A patient given insulin/dextrose should initially receive 2.5% dextrose when forced diuresis is begun [2,32].

Blood and urine samples should be collected at the same time as urinary and intravenous catheter placement. Perform urinalysis, urine culture and sensitivity, complete blood count (CBC), and biochemistry panel. If the amount of blood collected is limited, at least evaluate BUN, creatinine, electrolytes, blood glucose, and packed cell volume/total protein. Hyperkalemia and metabolic acidosis are common [2].

On survey radiographs, evaluate the entire length of the urinary tract for radiodense uroliths. Calculi lodged at the os penis may be particularly difficult to detect. Prostatomegaly may appear as a mass lesion dorsal to the urinary bladder, ventrally displacing the bladder [2].

Abdominal ultrasound can be used to identify cystic prostatic hyperplasia or struvite calculi. At the same time, perform ultrasonographic evaluation of the kidneys, bladder, and adrenal glands.

Use crystalloids and colloids to first correct perfusion abnormalities, such as hypotension, and then to rehydrate the patient (see the article by Lichtenberger elsewhere in this issue). Surgical management of adrenal gland disease is performed only after hydration and urine production are restored and laboratory values are normal. Adrenalectomy is the treatment of choice for adrenal disease and associated prostatic cysts. Stabilization before surgery generally requires approximately 24 to 36 hours.

Ferrets with adrenal disease and prostatic cysts should receive high-dose leuprolide acetate (250 µg/kg intramuscularly). Administration of this synthetic gonadotropin-releasing hormone analog may lead to a subsequent reduction in prostatic tissue within 12 to 48 hours of drug administration. This allows better flow of urine through, and even voluntary micturition around, the urinary catheter [2]. Although leuprolide acetate may temporarily or permanently mask clinical signs, growth of the adrenal gland is not affected.

In the treatment of struvite crystalluria, dietary conversion is ineffective in ferrets, because they will not eat a struvite-dissolving diet like Prescription Diet Feline s/d. Begin forced diuresis and schedule surgical removal of urinary calculi as needed.

Trauma

Traumatic injury is a common problem in ferrets because of their curious nature and their propensity for burrowing. Reclining chairs are a common cause of traumatic injury, while household accidents like being stepped on, run over by a wheeled object, falling, or being dropped are additional common complaints. Ferrets may also fight with larger species leading to serious bite or crush injuries [12].

Sequelae to traumatic injury may include conditions that are not particularly common in the ferret, such as pneumothorax and fractures. When fractures do occur, the appendicular skeleton is usually affected. Spinal

and pelvic fractures are uncommon. Treatment of fractures and other traumatic injuries may be extrapolated from emergency care of the kitten [2].

Immune-mediated disease

Vaccine reactions

There are many anecdotal reports of vaccine reaction in the ferret. These reactions are usually immediate (within 30 minutes of injection). Less severe reactions can be seen up to several hours after vaccine administration. Reactions are most common when more than one vaccine is given at the same time.

Clinical signs may include vomiting and retching, diarrhea, fever, and red, itchy skin. Some ferrets may also become hyperactive although this behavior is quickly followed by collapse. Diphenhydramine and fluid therapy may be sufficient for the treatment of vaccine reaction. Additional medications that may be used include epinephrine and corticosteroids.

Idiopathic myofasciitis

Idiopathic myofasciitis is a ferret disease first recognized in 2003. Although the pathogenesis is not understood, administration of a specific canine distemper vaccine may be a common factor (see later discussion for additional information) [34].

Immune-mediated hemolytic anemia

Immune-mediated hemolytic anemia has not been identified in ferrets.

Musculoskeletal disease

Idiopathic myofasciitis

Idiopathic myofasciitis or spontaneous inflammatory polymyopathy of the ferret was first recognized in 2003. The cause of this condition is unknown, although it may be immune-mediated. Young ferrets are most commonly affected, although there has been one report in a middle-aged individual [34].

Clinical signs include high fever, lethargy, recumbency, anorexia, posterior paresis and ataxia, pain with movement, and abnormal stools. Minimum database results include leukocytosis with a mature neutrophilia, mild to moderate nonregenerative anemia, mild to moderate elevation in ALT, mild hyperglycemia, and hypoalbuminemia [34].

Although a wide variety of drugs have been tried, including antibiotics, anti-inflammatory agents, glucocorticoids, analgesics, interferon, and cyclophosphamide, all regimens have thus far led to treatment failure. All patients have died or been euthanized [34].

Heat stroke

Because of their long, thin bodies and lack of sweat glands, ferrets are very susceptible to temperature extremes. They may easily develop heat

exhaustion or heat stroke when environmental temperature exceeds 80°F. This is particularly true with high humidity in geriatric ferrets or in ferrets with concurrent illness.

The first signs of heat exhaustion in the ferret may include open-mouth breathing and lying prone. Affected ferrets are often profoundly lethargic, and the footpads and mucous membranes may be bright red at first. Signs of nausea, diarrhea, and vomiting, sometimes with blood, may also be seen. Additional clinical findings may include tachycardia, arrhythmia, and tachypnea, but not necessarily an elevated body temperature by the time of presentation. The more severe form of heat illness, heat stroke, may also be associated with signs of central nervous system dysfunction, such as opisthotonus, fixed and dilated pupils, seizure activity, collapse, and even coma, as well as evidence of disseminated intravascular coagulation, such as purpura, conjunctival hemorrhage, melena, bloody diarrhea, hemoptysis, and hematuria. Ferrets may also become oliguric or anuric [2,35].

CBC and coagulation testing may provide evidence of coagulation disorders and hemoconcentration. Biochemistry panel abnormalities may occur with organ damage. The most consistent finding includes elevations in creatine kinase (CK), aspartate aminotransferase (AST), and ALT levels. Azotemia, hyperkalemia, and acid–base imbalance may also be seen. Hypoglycemia may occur secondary to increased use of glucose or hepatic damage. Urinalysis may reveal proteinuria, hematuria, myoglobinuria, or granular casts [2,35].

Immediate cooling is essential. Apply tepid or cool, not cold, water to the patient until temperature is 103°F–104°F. Begin aggressive fluid therapy for perfusion resuscitation and rehydration and to correct and maintain blood pressure. These measures may prevent serious sequelae, such as disseminated intravascular coagulation and renal failure (see the article by Lichtenberger elsewhere in this issue).

Ophthalmologic disease

Ophthalmologic disease is uncommon in the ferret. *Staphylococcus* sp. and *Corynebacterium* sp. are normally isolated from conjunctival and eyelid margins in adult ferrets. Healthy ferrets have a normal mean intraocular pressure of 14.50 ± 3.27 mm Hg, normal mean Schirmer tear test of 5.31 ± 1.32 mm/min, and a mean central corneal thickness of 0.337 ± 0.020 mm [36].

Summary

Ferrets are delightful animals that approach the world in a friendly, often fearless, manner. Even when ill, ferrets are often still very wiggly. The clinician able to use scruffing and stretching techniques is at a distinct advantage

for completing important diagnostic or therapeutic procedures. When clinical condition allows, however, also consider chemical restraint in the form of inhalant anesthesia or short-term parenteral anesthesia to collect diagnostic samples or perform procedures. Common emergency conditions seen in the ferret include insulinoma, cardiomyopathy, and urethral obstruction. When developing a diagnostic and therapeutic plan, the ferret veterinarian must seek a balance between species-specific information discussed in this article and information extrapolated from cat and dog medicine. The therapeutic plan must always include close and careful monitoring. Significant changes in the status of these small patients can occur extremely quickly in the course of providing basic supportive care such as intravenous fluids or supplemental heat.

References

- [1] Boyce SW, Zingg BM, Lightfoot TL. Behavior of *Mustela putorius furo*. *Vet Clin North Am Exot Anim Pract* 2001;4:697–712.
- [2] Quesenberry KE, Carpenter JW, editors. Ferrets, rabbits, and rodents: clinical medicine and surgery. 2nd edition. St. Louis (MO): WB Saunders Co.; 2003. p. 2–134.
- [3] Johnson-Delaney CA. Anatomy and physiology of the gastrointestinal system of the ferret and selected exotic carnivores. In: *Proc Annu Meet Assoc Ex Mammal Vet* 2006;29–38.
- [4] Ball RS. Husbandry and management of the domestic ferret. *Lab Anim* 2002;31:37–42.
- [5] Fisher PG. Esophagostomy tube placement in the ferret. *Exotic DVM* 2001;2:23–5.
- [6] Orcutt CJ. Emergency and critical care of ferrets. *Vet Clin North Am Exot Anim Pract* 1998; 1:99–126.
- [7] Benson KG, Paul-Murphy J, Carr A. Percutaneous placement of a gastric feeding tube in the ferret. *Lab Anim* 2000;29:44–6.
- [8] Atkins LB. Respiratory patterns (ST7A). In: *Proc Annu West Vet Conf* 2006.
- [9] Rudloff E. The first 5 minutes: assessment of the emergency patient. *Proceedings, Western Veterinary Conference*; 2006.
- [10] Vastenburg MH, Boroffka SA, Schoemaker NJ. Echocardiographic measurements in clinically healthy ferrets anesthetized with isoflurane. *Veterinary Radiology and Ultrasound* 2004;45:228–32.
- [11] Castanheira de Matos RE, Morrisey JK. Common procedures in the pet ferret. *Vet Clin North Am Exot Anim Pract* 2006;9:347–65.
- [12] Fudge AM. Ferret hematology. In: Fudge AM, editor. *Laboratory medicine: avian and exotic pets*. Philadelphia: WB Saunders Co.; 2000. p. 269–72.
- [13] Lawson AK, Lichtenberger M, Day T, et al. Comparison of sevoflurane and isoflurane in domestic ferrets (*Mustela putorius furo*). *Vet Ther* 2006;7:207–12.
- [14] Marini RP, Callahan RJ, Jackson LR, et al. Distribution of technetium 99m-labeled red blood cells during isoflurane anesthesia in ferrets. *Am J Vet Res* 1997;58:781–5.
- [15] Marini RP, Jackson LR, Esteves MI, et al. Effect of isoflurane on hematologic variables in ferrets. *Am J Vet Res* 1994;55:1479–83.
- [16] Schwarz LA, Solano M, Manning A, et al. The normal upper gastrointestinal examination in the ferret. *Vet Radiol Ultrasound* 2003;44:165–72.
- [17] Stepien RI, Benson KG, Forrest LJ. Radiographic measurement of cardiac size in normal ferrets. *Vet Radiol Ultrasound* 1999;40:606–10.
- [18] Sirois M. Advances in clinical chemistry. *Proceedings, American College of Veterinary Internal Medicine*; 2002.

- [19] Stepien RI, Benson KG, Wenholz LJ. M-mode and Doppler echocardiographic findings in normal ferrets sedated with ketamine hydrochloride and midazolam. *Vet Radiol Ultrasound* 2000;41:452–6.
- [20] Turton JA, Fagg R, Sones WR, et al. Characterization of the myelotoxicity of chloramphenicol succinate in the B6C3F1 mouse. *Int J Exp Pathol* 2006;87(2):101–12.
- [21] Esteves MI, Marini RP, Ryden EB, et al. Estimation of glomerular filtration rate and evaluation of renal function in ferrets (*Mustela putorius furo*). *Am J Vet Res* 1994;55:166–72.
- [22] Court MH. Acetaminophen UDP-glucuronosyltransferase in ferrets: species and gender differences, and sequence analysis of ferret UGT1A6. *Journal of Veterinary Pharmacology and Therapeutics* 2001;24:415–22.
- [23] Williams BH, Kiupel M, West KH, et al. Coronavirus-associated epizootic catarrhal enteritis in ferrets. *J Am Vet Med Assoc* 2000;217:526–30.
- [24] Nelson RW. Disorders of the endocrine pancreas. In: Nelson RW, Couto CG, editors. *Small animal internal medicine*. 3rd edition. St. Louis (MO): Mosby; 2003. p. 769–75.
- [25] Manning DD, Bell JA. Lack of detectable blood groups in the domestic ferrets: implications for transfusion. *J Am Vet Med Assoc* 1990;197:84–6.
- [26] Orcutt C. Update on oxyglobin use in ferrets. *Exotic DVM* 2001;3(3):29–30.
- [27] Ramer JC, Benson KG, Morrisey JK, et al. Effects of melatonin administration on the clinical course of adrenocortical disease in domestic ferrets. *J Am Vet Med Assoc* 2006;229(11):1743–8.
- [28] Benoit-Biancamano MO, Morin M, Langlois I. Histopathologic lesions of diabetes mellitus in a domestic ferret. *Can Vet J* 2005;46:895–7.
- [29] Parker GA, Picut CA. Histopathologic features and post-surgical sequelae of 57 cutaneous neoplasms in ferrets (*Mustela putorius furo*). *Vet Pathol* 1993;30(6):499–504.
- [30] Antinoff N. Clinical observations in ferrets with naturally occurring heartworm disease, and preliminary evaluation of treatment with ivermectin with and without melarsomine. In: *Proceedings Symposium American Heartworm Society: Recent Advances in Heartworm Disease*. 2002;45–7.
- [31] Supakorndej P, McCall JW, Supakorndej, et al. Evaluation of melarsomine dihydrochloride as a heartworm adulticide for ferrets. *Proceedings Symposium American Heartworm Society: Recent Advances in Heartworm Disease*. 2002;49–55.
- [32] Lichtenberger M. Treatment of urinary obstruction in the male ferret. *Proceedings of the Annual Meet International Conf Ex*, 2006.
- [33] Nolte DM, Carberry CA, Gannon KM, et al. Temporary tube cystostomy as treatment for urinary obstruction secondary to adrenal disease in four ferrets. *J Am Anim Hosp Assoc* 2003;38:527–32.
- [34] Garner MM, Ramsel K, Sidor I, et al. Idiopathic myofasciitis in the domestic ferret. In: *Proceedings Annual Meet Assoc Ex Mammal Vet* 2006; 65–6.
- [35] Wingfield WE. *Veterinary emergency medicine secrets*. Fort Collins (CO): Hanley & Belfus; 2000.
- [36] Montiani-Ferreira F, Mattos BC, Russ HH. Reference values for selected ophthalmic diagnostic tests of the ferret (*Mustela putorius furo*). *Vet Ophthalmol* 2006;9:209–13.