



Contents lists available at ScienceDirect

Journal of Hand Surgery Global Online

journal homepage: www.JHSGO.org

Case Report

Total Joint Arthroplasty of a Proximal Interphalangeal Joint with Proximal Metal Surface Replacement and Distal Hemi-Hamate Autograft: A Long-Term Follow-Up

Caroline Wu, BS,^{*} Matthew Drake, MD,[†] Kenneth R. Means Jr., MD[‡]^{*} Georgetown University School of Medicine, Washington, DC[†] The Department of Orthopedic Surgery and Sports Medicine, The University of Kansas, Lawrence, KS[‡] The Curtis National Hand Center, MedStar Union Memorial Hospital, Baltimore, MD

ARTICLE INFO

Article history:

Received for publication January 10, 2022

Accepted in revised form February 4, 2022

Available online March 3, 2022

Key words:

Arthroplasty

Hemi-hamate arthroplasty

Joint reconstruction

Osteochondral graft

Proximal interphalangeal joint

A 28-year-old female recreational athlete presented with middle finger proximal interphalangeal joint pain, stiffness, and ulnar deviation deformity 2 years after internal fixation of a middle phalanx base fracture-dislocation. Radiographs revealed posttraumatic changes on both sides of the proximal interphalangeal joint. Having failed nonsurgical measures, she elected to proceed with surgical reconstruction. Intraoperatively, we confirmed substantial articular damage on both sides of the joint. We proceeded with hemi-hamate autograft for 80% of the middle phalanx base. We used a cobalt chrome proximal phalanx component. After healing, the patient returned to all daily-living and athletic activities with resolution of preoperative pain, stiffness, and deformity. Twelve years after surgery, she had no pain or substantial limitations because of the finger. We measured 80° of proximal interphalangeal joint motion. The grip and fingertip-pinch strength were 91% and 73%, respectively, of the contralateral dominant hand. Radiographs showed no progressive changes compared to 3 years after surgery.

Copyright © 2022, THE AUTHORS. Published by Elsevier Inc. on behalf of The American Society for Surgery of the Hand.
This is an open access article under the CC BY-NC-ND license (<http://creativecommons.org/licenses/by-nc-nd/4.0/>).

The treatment of proximal interphalangeal (PIP) joint degeneration following middle phalanx (P2) base injuries is varied and nuanced, especially for young patients and patients with high physical demands. Standard operative treatments include hemi-hamate arthroplasty, total joint arthroplasty, and arthrodesis.^{1–6} Hemi-hamate arthroplasty restores the P2 base and its function and is traditionally considered when the proximal phalanx (P1) head is in good condition.^{1–3} Total joint arthroplasty with mono-block or 2-component options can maintain PIP joint motion, with risks of loosening, instability, and hardware or phalanx fractures.^{4,5} Two-component arthroplasty in particular carries concerns of implant failure and joint dislocation, especially at P2.^{4,5}

Arthrodesis is effective for pain relief and has risks of nonunion or symptomatic hardware.⁶ We present a case of “hemi-hemi” PIP joint arthroplasty, with hemi-hamate autografting for P2 and hemi-implant for P1, in a young, active patient.

Case Report

A 26-year-old female recreational athlete initially presented with a nondominant middle finger P2 base fracture-dislocation from flag football. Treatment was via open reduction internal fixation and PIP joint dorsal block pinning. She did well after surgery and was discharged with a PIP joint range of motion (ROM) 5° short of full extension to 95° of flexion. More than 1 year later, she sustained another injury while playing softball. She had PIP joint tenderness, a 70° arc of motion, laxity of the radial collateral ligament, and ulnar deviation deformity. Her grip strength was 23 kg in the postoperative hand, compared to 36 kg in the contralateral hand. Radiographs revealed posttraumatic changes at the PIP joint. She was treated with orthoses and buddy straps. After 3 months,

Declaration of interests: No benefits in any form have been received or will be received related directly or indirectly to the subject of this article.

Corresponding author: Kenneth R. Means, Jr, MD, the Curtis National Hand Center, MedStar Union Memorial Hospital, 3333 North Calvert Street, JPB #200, Baltimore, MD 21218.

E-mail address: editor@curtishand.com (K.R. Means, Jr).

<https://doi.org/10.1016/j.jhsg.2022.02.002>

2589-5141/Copyright © 2022, THE AUTHORS. Published by Elsevier Inc. on behalf of The American Society for Surgery of the Hand. This is an open access article under the CC BY-NC-ND license (<http://creativecommons.org/licenses/by-nc-nd/4.0/>).

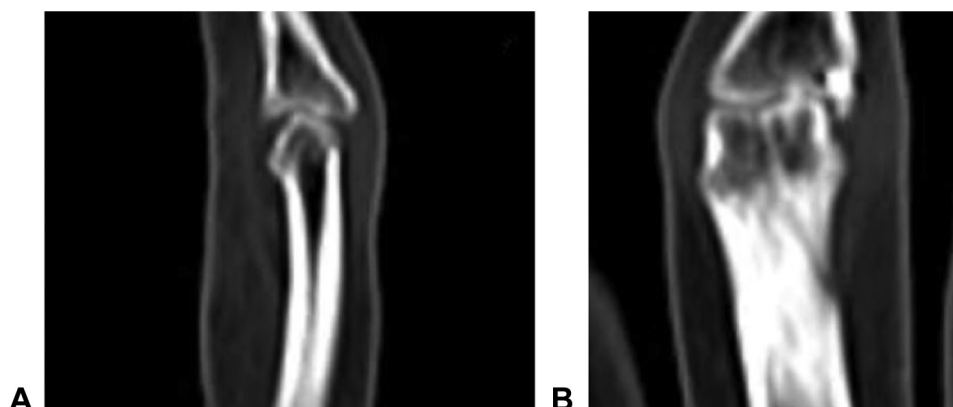


Figure 1. Selected computed tomography images of the PIP joint to evaluate posttraumatic changes prior to “hemi-hemi” reconstructive surgery. **A** Sagittal and **B** frontal views.

the ulnar deviation deformity was unchanged, and she had persistent pain and swelling. A corticosteroid injection provided transient relief. Computed tomography scans revealed extensive arthritic changes at the P1 and P2 surfaces (Fig. 1). Given her age and activity level, we discussed that standard surgical options may not be ideal. After receiving written informed consent from the patient, we reached a shared decision to consider reconstruction with P1 hemi-implant arthroplasty and P2 hemi-hamate autograft.

Surgical technique

We reopened the palmar chevron incision at the PIP joint. We opened the flexor sheath between the A2 and A4 pulleys and mobilized and retracted the flexor tendons. We detached the volar plate distally and elevated it proximally. We released the accessory collateral ligaments and hyperextended the PIP joint. We noted substantial degenerative changes at P1 and P2. We decided to proceed with “hemi-hemi” reconstruction (Fig. 2).

Per the Small Bone Innovations (SBI) manufacturer's guidelines, we cut the P1 head with a sagittal saw, used a series of broaches, and inserted the press-fit P1 implant. Using a sagittal saw, we removed the P2 degenerative surface, preserving the dorsal rim. The resulting defect was ~80% of the base (Fig. 3). We made a dorsal transverse incision over the ring and small finger carpometacarpal joints, protecting the extensor tendons and dorsal ulnar sensory nerve branches. We sharply elevated capsular flaps, exposing the joints. We harvested the hemi-hamate graft via sagittal saw and osteotome. Afterward, we confirmed stability of the carpometacarpal joints through axial loading.

We fashioned the graft and used Kirschner wires to provisionally secure it to P2, allowing assessment of alignment through ROM. We used 2 1.0-mm titanium screws (DePuy Synthes) to fix the graft to the dorsal P2 rim (Fig. 4). We confirmed graft placement and fixation via fluoroscopy (Figs. 5 and 6). After reduction of the PIP joint, there was no malrotation or malangulation throughout PIP joint ROM (Fig. 7). We sutured the distal volar plate to the surrounding soft tissues, preventing PIP joint hyperextension. Following skin closure, we buddy-wrapped the finger to the ring finger and applied a dorsal extension-blocking orthosis with the PIP joints in ~20° of flexion.

Postoperative rehabilitation

Therapy was initiated 5 days after surgery and included a PIP joint extension-blocking orthosis at ~20° of flexion. The patient

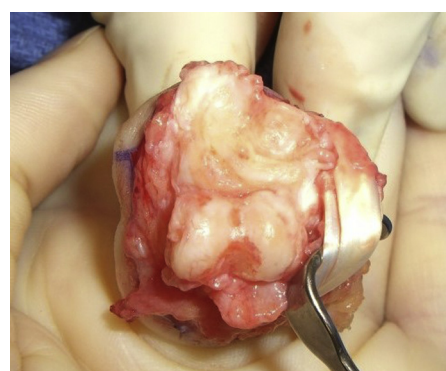

Figure 2. Shotgun view of the PIP joint, showing articular defects of both P1 and P2.

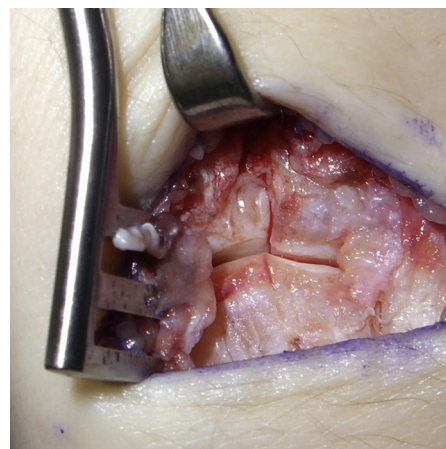


Figure 3. Dorsal view of hemi-hamate autograft harvest site.

began ROM within this orthosis, initially in a short arc and gradually increasing. At the first, second, and fourth postoperative months, her active PIP joint ROM arcs were 20° to 75°, 20° to 65°, and 15° to 65°, respectively. She was able to touch her fingertip to her palm at each of these points. By the fourth postoperative month, she was pain-free and had no joint, implant, or graft instability or other concerns. Her grip strength was 39 pounds in the postoperative hand versus 69 pounds for the dominant contralateral hand.

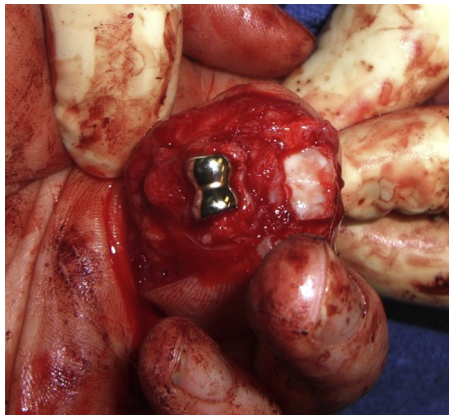


Figure 4. Shotgun view of the PIP joint after hemi-hamate arthroplasty for P2 and SBI cobalt chrome implant arthroplasty for P1.

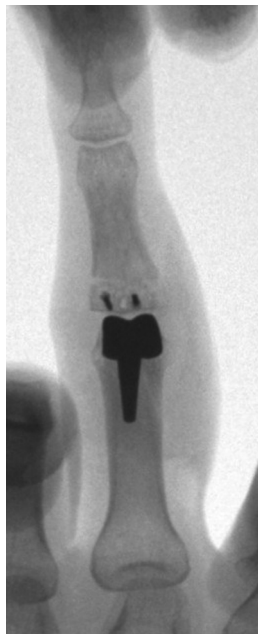


Figure 5. Posteroanterior intraoperative fluoroscopy showing hemi-hamate arthroplasty for P2 and metal-implant arthroplasty for P1.

Follow-up

At an unrelated visit 1 year after surgery, the patient noted occasional PIP joint pain that did not preclude daily activities or recreational sports. There was no PIP joint instability, deviation, or other concerns (Fig. 8).

Three years after reconstruction, she presented with a non-displaced P1 base avulsion fracture from another recreational sports activity. Radiographs showed that the P1 implant and P2 graft were well-incorporated, with some wear at P2. The implant was uninvolved with the avulsion fracture, which healed non-surgically in 6 weeks (Fig. 9).

The patient returned for a 12-year postoperative follow-up, per our request. She reported no pain at the reconstructed PIP joint, regardless of activity. She noted occasional at-worst 1-out-of-10 pain at the hemi-hamate harvest site during weather changes or strenuous activity. She reported some hypersensitivity along the incisional scar and radial digital nerve distribution, with no impact

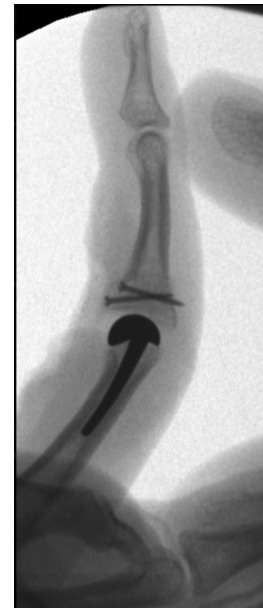

Figure 6. Lateral intraoperative fluoroscopy.

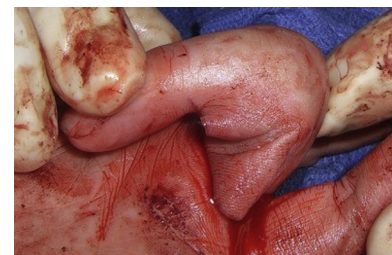

Figure 7. Intraoperative middle finger PIP joint passive flexion prior to skin closure.

on function, typing, or other work as a paralegal. Our examination revealed no carpometacarpal harvest site tenderness or instability (Fig. 10). Measuring with a dorsally placed goniometer, the distal interphalangeal joint had a 15° active extensor lag, with full active and passive ROM otherwise. The PIP joint had full active and passive extension to neutral, with active and passive flexion to 80°. The grip strengths via JAMAR dynamometer (Patterson Medical) on the second setting, averaged over 3 patient-blinded trials, were 28 kg in the postoperative hand and 31 kg in the contralateral hand. Fingertip-to-thumb pinch strengths, similarly averaged via JAMAR pinch-meter (Patterson Medical), were 4 and 5 kg in the postoperative and contralateral middle fingers, respectively. Radiographs showed no substantial changes compared to 3 years after surgery (Fig. 11).

Discussion

The “hemi-hemi” approach successfully restored stable, pain-free PIP joint ROM in our young, active patient. Hemi-hamate and metal-implant arthroplasties are individually characterized in the literature. To our knowledge, their concurrent use is not described. Alone, hemi-hamate reconstruction can restore function.^{1–3} For our case, a large majority (~80%) of P2 was resurfaced. The large graft size made canting it dorsally while matching the articular rim challenging. Fortunately, the patient did not experience instability during or after surgery.

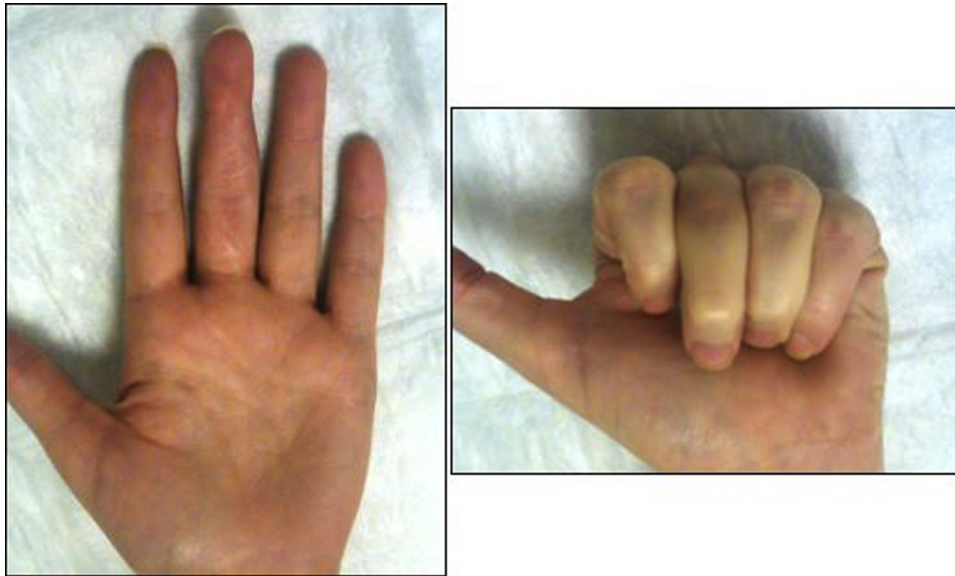

Figure 8. Clinical images of active ROM 1 year after left middle finger PIP joint hemi-hemi reconstruction.

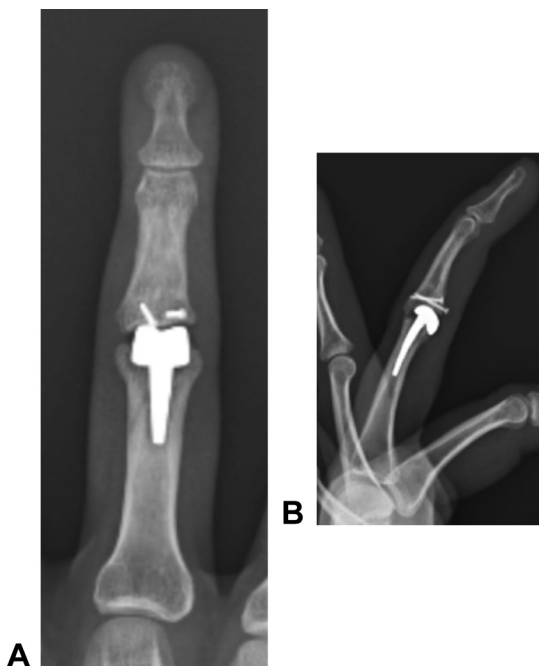

Figure 9. **A** Posteroanterior and **B** lateral radiographs 3 years after surgery, after healing of an unrelated P1 base fracture; there is wear at the P2 base hemi-hamate graft site.

The SBi PIP joint implant is not approved by the Food and Drug Administration, limiting its use to “compassionate care.” In our experience, 2-piece PIP joint arthroplasties have few complications at P1 and typically fail at P2. We thus opted for hemi-implant at P1 and hemi-hamate at P2 as a potentially more robust long-term option.

Although a reasonable alternative, we avoided silicone and pyrocarbon implants because of our patient’s age and activity level. Silicone implants can have subsidence, sclerosis, decreased ROM,

and bony resorption.^{7–9} Authors report silicone fracture rates up to 63% at 14 years, although these are often minimally impactful.^{7,10} Other possible complications include malrotation, instability, synovitis, and granuloma formation.^{7,10} Silicone microparticles can collect within inflammatory cells, leading to bony erosion. This can make future salvage procedures, such as arthrodesis, more difficult.

Pyrocarbon implants are prone to loosening, squeaking, infection, and joint contractures. Reports of PIP joint pyrocarbon implant loosening vary from 16% to 100% by 4 years after surgery.^{7,10} In our experience, these are especially problematic at P2, where they can loosen and subside, sometimes leading to PIP joint dislocation. Dickson et al¹⁰ found that 37% of pyrocarbon implants required additional surgery. Total PIP joint arthroplasty with either pyrocarbon or silicone also typically fails to substantially improve upon the preoperative grip strength and ROM, the restoration of which were important goals for our patient.

For our patient’s situation, arthrodesis is typically reserved for failed reconstruction or when joint instability and/or bone stock preclude reconstruction. A permanently flexed PIP joint would not have allowed her to wear gloves for recreational activities such as softball, something she continued to participate in for many years after the “hemi-hemi” surgery.

We are not aware of any reports with follow-ups of >10 years for hemi-hamate or SBi PIP joint implants. Our patient had well-maintained joint stability, ROM, and grip and pinch strengths at the 12-year follow-up, with no pain or activity limitations. Radiographs, however, showed relatively early wear of the hemi-hamate graft that has since remained stable. This discrepancy between the radiologic appearance and clinical outcomes is well-documented in short-term follow-ups of other PIP joint reconstructions.⁸

In conclusion, for our patient’s PIP joint fracture-dislocation with later posttraumatic degeneration at a young age, P1 hemi-implant and P2 hemi-hamate arthroplasty has been a viable long-term solution. It allowed us to avoid the P2 challenges associated with 2-piece arthroplasty, especially for a highly active patient. It has provided her pain-free ROM and strength, with the resumption of all activities, over more than 10 years of follow-up.

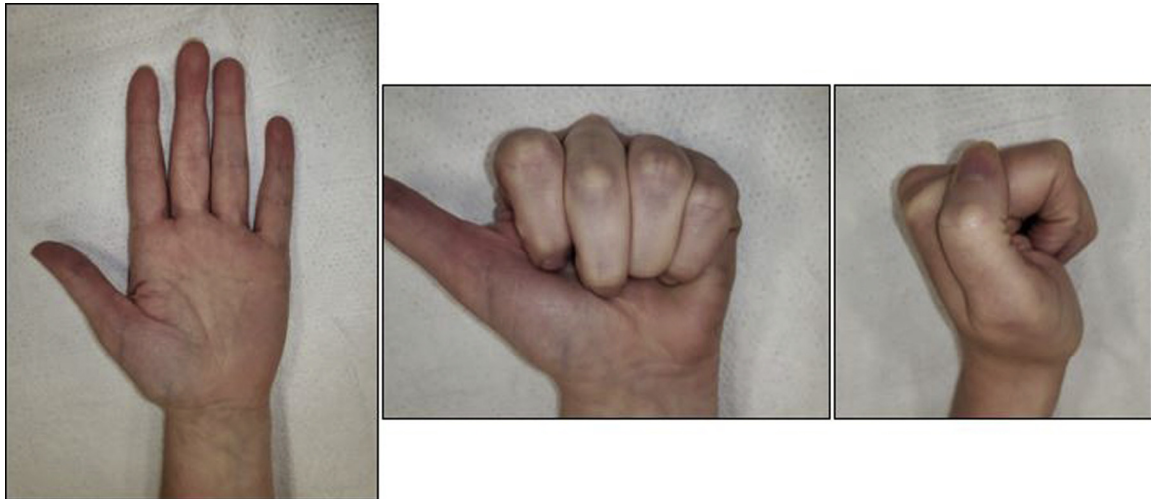

Figure 10. Clinical images 12 years after middle finger hemi-hemi PIP joint reconstruction. The PIP joint had full active and passive extension to neutral, with active and passive flexion measured at 80°.

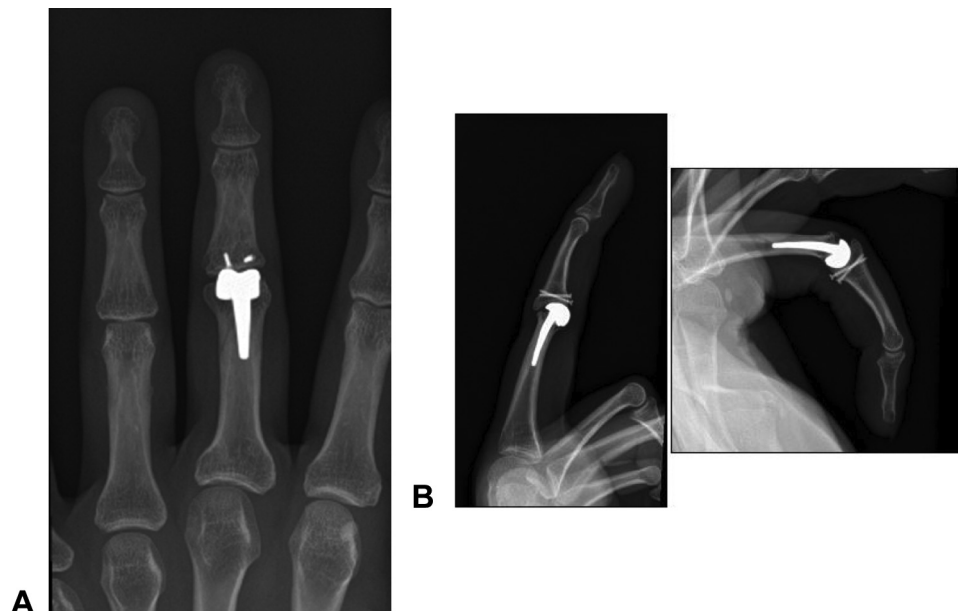


Figure 11. A Posteroanterior and B lateral radiographs 12 years after middle finger hemi-hemi PIP joint reconstruction.

References

1. Calfee RP, Kiefhaber TR, Sommerkamp TG, Stern PJ. Hemi-hamate arthroplasty provides functional reconstruction of acute and chronic proximal interphalangeal fracture-dislocations. *J Hand Surg Am.* 2009;34(7):1232–1241.
2. McAuliffe JA. Hemi-hamate autograft for the treatment of unstable dorsal fracture dislocation of the proximal interphalangeal joint. *J Hand Surg Am.* 2009;34(10):1890–1894.
3. Williams RM, Kiefhaber TR, Sommerkamp TG, Stern PJ. Treatment of unstable dorsal proximal interphalangeal fracture/dislocations using a hemi-hamate autograft. *J Hand Surg Am.* 2003;28(5):856–865.
4. Luther C, Germann G, Sauerbier M. Proximal interphalangeal joint replacement with surface replacement arthroplasty (SR-PIP): functional results and complications. *Hand (N Y).* 2010;5(3):233–240.
5. Muder D, Hailer NP, Vedung T. Two-component surface replacement implants compared with perichondrium transplantation for restoration of metacarpophalangeal and proximal interphalangeal joints: a retrospective cohort study with a mean follow-up time of 6 respectively 26 years. *BMC Musculoskelet Disord.* 2020;21(1):657.
6. Jones DB Jr, Ackerman DB, Sammer DM, Rizzo M. Arthrodesis as a salvage for failed proximal interphalangeal joint arthroplasty. *J Hand Surg Am.* 2011;36(2):259–264.
7. Adkinson JM, Chung KC. Advances in small joint arthroplasty of the hand. *Plast Reconstr Surg.* 2014;134(6):1260–1268.
8. Chan K, Ayeni O, McKnight L, Ignacy TA, Farrokhhyar F, Thoma A. Pyrocarbon versus silicone proximal interphalangeal joint arthroplasty: a systematic review. *Plast Reconstr Surg.* 2013;131(1):114–124.
9. Ashworth CR, Hansraj KK, Todd AO, et al. Swanson proximal interphalangeal joint arthroplasty in patients with rheumatoid arthritis. *Clin Orthop Relat Res.* 1997;342(Sep):34–37.
10. Dickson DR, Nuttall D, Watts AC, Talwalkar SC, Hayton M, Trail IA. Pyrocarbon proximal interphalangeal joint arthroplasty: minimum five-year follow-up. *J Hand Surg Am.* 2015;40(11):2142–2148.e4.