

## CASE REPORT

# Malignant metastatic deposits in an immunocompromised patient—could this be tuberculosis?

Y Ng<sup>1,\*</sup>, R Aros-Atolagbe<sup>2</sup>, R Ravanan<sup>3</sup>, C Kendall<sup>4</sup> and B Bovill<sup>1</sup>

<sup>1</sup>Department of Infectious Diseases, Southmead Hospital, Bristol, UK, <sup>2</sup>Faculty of Medicine, University of Bristol, UK, <sup>3</sup>Department of Renal and Transplant Medicine, Southmead Hospital, Bristol, UK, and <sup>4</sup>Department of Palliative Medicine, Southmead Hospital, Bristol, UK

\*Correspondence address. Department of Infectious Diseases, Southmead Hospital, Bristol BS10 5NB, UK. E-mail: YangNg@nhs.net

## Abstract

We report the case of a 50-year-old female renal transplant patient who developed disseminated deposits initially diagnosed as metastatic malignancy of unknown primary. She declined a tissue diagnosis but subsequently developed recurrent sepsis and symptomatic unilateral pleural effusion. *Mycobacterium tuberculosis* was cultured from pleural fluid. Following introduction of anti-tuberculous medications, her symptoms improved rapidly and the progression of her disseminated deposits stabilized. Tuberculosis is well-known to be associated with immunocompromised patients. It is a curable disease and should remain an important differential diagnosis for transplant patients who develop suspicious malignant metastatic lesions.

## INTRODUCTION

Patients who receive solid organ transplantation are at risk of both malignancies and atypical infections such as Tuberculosis (TB) [1]. Both are life threatening, but TB is a curable communicable disease. It is important to note that TB and malignancy can have overlapping symptoms and signs. We present a case study of a renal transplant patient who developed disseminated lesions initially thought to be metastatic malignancy of unknown primary, but later developed miliary TB which improved with treatment.

## CASE REPORT

A 50-year-old female of Filipino heritage received a living unrelated renal transplant in August 2013. Her past history included

end-stage renal failure of unknown aetiology, hypertension, transient ischaemic attack and cervical cancer treated with transabdominal hysterectomy and radiotherapy. Post-transplant immunosuppression consisted of Prednisolone and trough level controlled Tacrolimus. Post-operatively she developed multiple complications including recurrent ureteric obstruction and failed ureteric stents necessitating long-term nephrostomy. She suffered from recurrent urinary tract infections caused by multi-resistant *Escherichia coli* and *Pseudomonas sp.* Despite the above, her transplant functioned well with a baseline Creatinine of 140  $\mu\text{mol/L}$  and estimated glomerular filtration rate of 34 mL/min/1.73 m<sup>2</sup>. Following risk assessment, TB prophylaxis was considered but not prescribed due to her multiple complications and illnesses in the immediate post-transplant period.

In October 2014 she was admitted with abdominal and back pain. A computed-tomography (CT) revealed new lytic lesions

Received: November 5, 2016. Revised: January 9, 2017. Accepted: February 16, 2017

© The Author 2017. Published by Oxford University Press.

This is an Open Access article distributed under the terms of the Creative Commons Attribution Non-Commercial License (<http://creativecommons.org/licenses/by-nc/4.0/>), which permits non-commercial re-use, distribution, and reproduction in any medium, provided the original work is properly cited. For commercial re-use, please contact [journals.permissions@oup.com](mailto:journals.permissions@oup.com)

in multiple vertebral bodies and iliac bones, confirmed on magnetic resonance imaging (MRI) (Fig. 1). Following a negative myeloma screen, she was given a provisional diagnosis of metastatic malignancy of unknown primary. The patient declined a tissue diagnosis at that time and opted for palliative management of her symptoms. She received a course of palliative radiotherapy for impending cord compression and for pain control. She had several admissions in rapid succession with fever and rigors which were thought to be due to sepsis that resolved quickly with intravenous antibiotic administration. Pain control was always worse during these episodes, but sites of reported pain did not fit with her known spinal lesions.

In November 2015, the patient was admitted with chest pain and breathlessness. CT scan revealed progression of her bony lesions with bilateral pulmonary nodules, pleural thickening and new unilateral pleural effusion initially thought to be lung malignancy (Fig. 2). The effusion was drained twice for symptomatic relief. Pleural fluid analysis revealed an exudate with LDH of 525 U/L and protein 38 g/L. Cytology was negative but Acid-Fast Bacilli were grown from TB culture 3 weeks later, subsequently confirmed to be *Mycobacterium tuberculosis*.

She was treated with Rifampicin, Isoniazid, Pyrazinamide and Ethambutol, with the latter 2 discontinued 2 months later. Following 2 months introduction of anti-tuberculous therapy, her pulmonary nodules and pleural effusion resolved completely (Fig. 3). Bone biopsy to conclusively rule out malignancy was offered but declined by the patient. Subsequent follow-up MRIs showed significant improvement of her spinal lesions.

## DISCUSSION

TB is one of the most important causes of premature death worldwide, killing 1.5 million people every year [2]. The overall incidence of TB in the UK has remained stable in the past decade, but a significant proportion of cases are reported in large urban cities (e.g. London, Birmingham) [3]. Overall, 75% of TB cases in the UK occur in patients born overseas, particularly those born in countries with high TB risk [3]. Other risk factors include HIV infection, alcohol excess, chronic renal disease, haemodialysis and patients receiving immunosuppression therapy—particularly

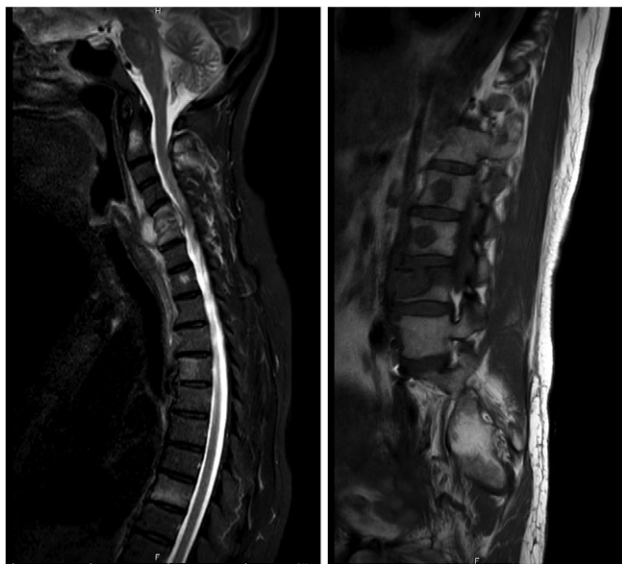


Figure 1: MRI whole spine performed in May 2015 revealed multi-level osteolytic infiltration including impending cord compression at C5/6.

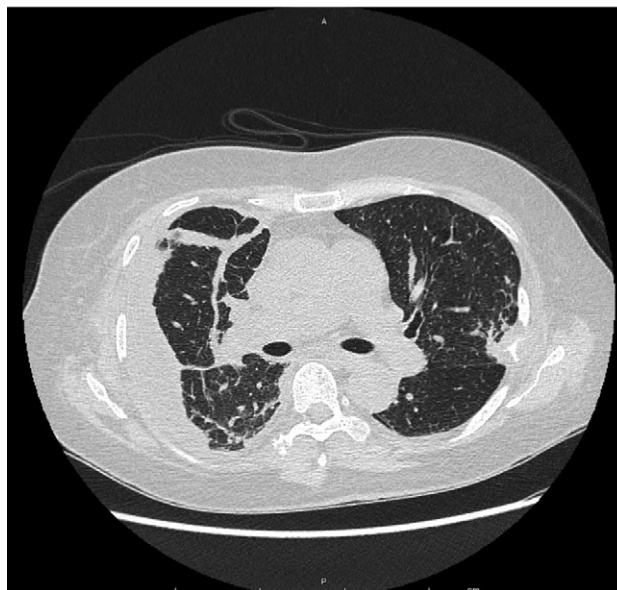


Figure 2: non-contrast CT performed in November 2015 showed new unilateral pleural effusion, bilateral progressing pulmonary nodules and pleural irregularity and thickening initially thought to be consistent with lung malignancy.

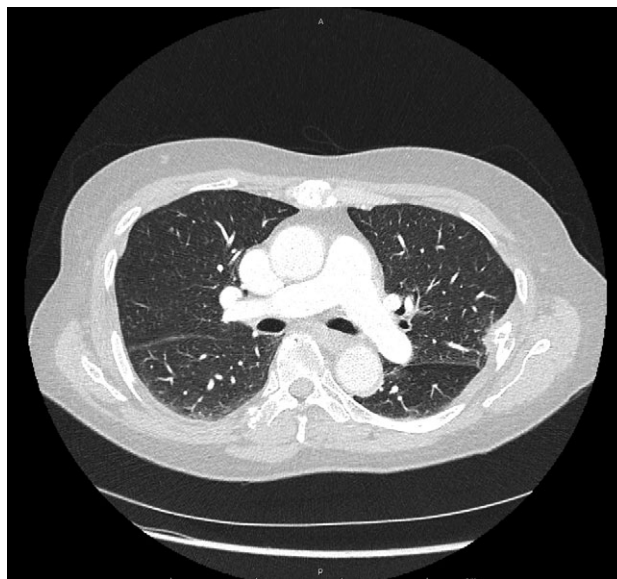

Figure 3: CT pulmonary angiogram performed in February 2016 revealed near-complete resolution of pulmonary nodules, pleural thickening and pleural effusion.

those who have received solid organ transplantation [4]. The risk of TB infection in transplant patients is at least 30 times higher than that of the general population [5]. Most UK centres routinely offer prophylactic anti-tuberculous therapy for transplant patients at higher risk of developing TB.

Transplant patients also have an overall 2-fold increase in incidence of malignancies—these can be malignancies driven by oncogenic viral infections (e.g. lymphoma, anorectal and cervical cancers), or non-infection related (e.g. skin, lung, liver and thyroid cancers) [6]. Patients receiving organ transplantation are therefore routinely counselled regarding the risk of cancer.

The classical symptoms of productive cough and haemoptysis in TB may not always be present in immunosuppressed patients. Patients may have non-specific symptoms such as recurrent fever, lethargy, chest pain and weight loss. Miliary TB, in particular, may have overlapping clinical and radiological features with metastatic malignancy. Due to the relative rarity of TB among patients in the UK, it is therefore unsurprising that we often do not routinely consider TB as part of our differential diagnosis.

Treatment of TB in transplant patients require close liaison between Transplant specialists and Respiratory or Infectious Diseases specialists. Routine treatment in the UK will include 2 months of quadruple therapy (Rifampicin, Isoniazid, Ethambutol and Pyrazinamide), followed by at least 4 further months of dual therapy (Rifampicin and Isoniazid). It is crucial to note that Rifampicin is a potent inducer of the hepatic CYP450 enzyme system, therefore the dosages of corticosteroids and calcineurin inhibitors, both commonly used in transplant recipients, need to be dose-adjusted accordingly.

## CONCLUSION

Patients who have received solid organ transplantation are at risk of both malignancies and atypical infections including TB, which can present in an unusual manner. TB is a curable disease, and should remain an important differential diagnosis in immunosuppressed patients who develop suspicious metastatic lesions.

## LEARNING POINTS

- (1) Transplant patients are at risk of both malignancies and atypical infections such as tuberculosis.
- (2) Miliary TB can present in an atypical and indolent manner, particularly in an immunocompromised patient.
- (3) TB should be considered in a transplant patient who develops metastatic lesions of unknown origin, even in those with an established diagnosis of malignancy.
- (4) Treatment of TB in transplant patients require close liaison between transplant and TB specialists due to interactions between anti-tuberculous and immunosuppression therapy.

## ACKNOWLEDGEMENTS

The authors would like to thank the patient for giving her kind permission for publication.

## CONFLICT OF INTEREST STATEMENT

None declared.

## FUNDING STATEMENT

No funding required.

## ETHICAL APPROVAL

No ethical approval required.

## CONSENT

Written consent provided by patient.

## GUARANTOR

Corresponding author (Dr Y. Ng).

## REFERENCES

1. Al-Efraij K, Mota L, Lunny C, Schachter M, Cook V, Johnston J. Risk of active tuberculosis in chronic kidney disease: a systematic review and meta-analysis. *Int J Tuberc Lung Dis* 2015; **19**:1493–9.
2. World Health Organisation *Global tuberculosis report*. World Health Organisation, 2015.
3. Public Health England. *Tuberculosis in the UK: 2014 report*. London: Public Health England, 2014.
4. National Institute for Health and Care Excellence. *Tuberculosis: NICE Guideline NG33*. London: NICE, 2016.
5. British Thoracic Society Standards of Care Committee and Joint Tuberculosis Committee. Guidelines for the prevention and management of *Mycobacterium tuberculosis* infection and disease in adult patients with chronic kidney disease. *Thorax* 2010; **65**:559–79.
6. Engels EA, Pfeiffer RM, Fraumeni JF Jr, Kasiske BL, Israni AK, Snyder JJ, et al. Spectrum of cancer risk among US solid organ transplant recipients. *J Am Med Assoc* 2011; **306**:1891.