

Review

Cite this article: Zhou J, Yang X, Hu Y and Li S (2025). Epidemiological and osteoarticular involvement sites' characteristics of multiple osteoarticular tuberculosis: a scoping review. *Epidemiology and Infection*, **153**, e26, 1–9 <https://doi.org/10.1017/S095026882400150X>

Received: 12 March 2024
Revised: 18 September 2024
Accepted: 26 September 2024

Keywords:

age; clinical type; gender; involvement sites; multifocal osteoarticular tuberculosis

Corresponding authors:

Shijun Li and Yong Hu;
Emails: zjumedjun@163.com;
huyong1979@gmc.edu.cn

Epidemiological and osteoarticular involvement sites' characteristics of multiple osteoarticular tuberculosis: a scoping review

Jian Zhou^{1,2} , Xuanjie Yang¹, Yong Hu¹ and Shijun Li^{1,2}

¹School of Public Health, the Key Laboratory of Environmental Pollution Monitoring and Disease Control, Ministry of Education, Guizhou Medical University, Guiyang, China and ²Guizhou Center for Disease Control and Prevention, Guiyang, China

Abstract

Multiple osteoarticular tuberculosis (MOT) represents an uncommon yet severe form of tuberculosis, characterized by a lack of systematic analysis and comprehension. Our objective was to delineate MOT's epidemiological characteristics and establish a scientific foundation for prevention and treatment. We conducted searches across eight databases to identify relevant articles. Pearson's chi-square test (Fisher's exact test) and Bonferroni method were employed to assess osteoarticular involvement among patients of varying age and gender ($\alpha = 0.05$). The study comprised 98 articles, encompassing 151 cases from 22 countries, with China and India collectively contributing 67.55% of cases. MOT predominantly affected individuals aged 0–30 years (58.94%). Pulmonary tuberculosis was evident in 16.55% of cases, with spinal involvement prevalent (57.62%). Significant differences were noted in trunk, spine, thoracic, and lumbar vertebrae involvement, as well as type I lesions across age groups, increasing with age. Moreover, significant differences were observed in upper limb bone involvement and type II lesions across age groups, decreasing with age. Gender differences were not significant. MOT primarily manifests in China and India, predominantly among younger individuals, indicating age-related variations in osteoarticular involvement. Enhanced clinical awareness is crucial for accurate MOT diagnosis, mitigating missed diagnoses and misdiagnoses.

Introduction

Multiple osteoarticular tuberculosis (MOT) is a chronic infectious disease caused by *Mycobacterium tuberculosis* infection, characterized by extensive lesions in bone and joint tissues [1–3]. MOT typically affects multiple skeletal sites and joints, either simultaneously or consecutively, with common locations including the spine, pelvis, femoral head, shoulder joints, and knee joints [4]. Symptoms of MOT include joint pain, stiffness, redness, swelling, localized temperature elevation, restricted movement, and consequent bone deformation [5]. The diagnostic process for MOT commonly involves various imaging modalities such as X-ray, CT scan, and magnetic resonance imaging (MRI). Confirmation of the diagnosis may require bacterial testing and tissue biopsy [5–7].

The pathogenesis of bone and joint tuberculosis is believed to involve *M. tuberculosis* infection. Typically entering through the respiratory tract and disseminating via the circulatory system, the bacteria eventually colonize bone and joint tissues. Due to the relatively weak resistance of these tissues to bacterial invasion, inflammation, and destruction occur [4]. However, the pathogenesis of bone and joint tuberculosis in patients without pulmonary tuberculosis remains less understood. Furthermore, the clinical symptoms associated with this condition are atypical, making diagnosis challenging and prone to misdiagnosis and oversight [8–11].

Given its rarity, MOT cases are primarily reported as individual case reports in current literature. Establishing a diagnosis for this uncommon condition requires a comprehensive approach that includes systematic epidemiological and clinical evidence. Therefore, to address this gap in knowledge, we made efforts to collect information on MOT cases from the literature database, and the language types of literature for this scoping review were English and Chinese.

Methods

The protocol for this systematic review was registered on the PROSPERO (International Prospective Register of Systematic Reviews) and assigned registration number CRD4202-3494495, which can be accessed at <https://www.crd.york.ac.uk/PROSPERO/>. As the study was based on previously published preliminary research, ethical approval and patient consent were not sought.

Search strategy

Two reviewers (JZ and XJY) conducted searches in Embase, PubMed, Scopus, Web of Science, Cochrane Library, Chinese National Knowledge Infrastructure (CNKI), Wanfang, and VIP databases. The search deadline was set as 12 December 2023. A Boolean search strategy with subject words and free words was employed using keywords and MeSH or Emtree terms related to 'multifocal' and 'bone and joint tuberculosis' for each database (Supplementary Table 1: Search strategies).

Eligibility criteria

Studies meeting the following criteria were included: (1) primarily consisting of case reports and original studies, (2) involving human subjects without discrimination based on age, gender, or geographical origin; and (3) requiring a diagnosis supported by comprehensive evidence from imaging, bacteriological, or biopsy sources. Exclusion criteria were (1) reviews, conference papers, abstracts, expert opinions, and repeated literature were excluded; (2) literature with unclear diagnosis, especially those without imaging and bacteriological evidence, was excluded; (3) infections due to nontuberculous *Mycobacteria* were excluded; and (4) literature without gender and age of patients was excluded.

Quality assessment and data extraction

This study adhered to the rigorous guidelines of the Preferred Reporting Items for Systematic Reviews and Meta-analyses (PRISMA) [12]. In strict accordance with the diagnostic criteria for bone and joint tuberculosis, we considered imaging and bacteriological evidence as crucial tools for MOT diagnosis and assessed patient eligibility based on MOT determination conditions [4]. Two individuals (JZ and XJY) extracted the literature data, respectively, and finally, combined the data and verified the accuracy of the data. In cases where discrepancies arose between the two extractions, a thorough re-examination of the literature was conducted to obtain accurate data (Supplementary Table 2: Data collection evaluation form).

Variable definitions

Using a standardized data abstraction form, we recorded the following information from articles that met our inclusion criteria: reporting time, country, gender, age, presence or absence of pulmonary tuberculosis, and sites of bone and joint involvement. MOT was defined as the simultaneous occurrence of two or more non-adjacent bone and/or joint lesions caused by *M. tuberculosis*. MOT was further categorized into three types: type I involved multiple spinal segments (or the same segment separated by at least one vertebral body), type II involved multiple joints only, and type III involved complex multiple bones including joints, spine, or other parts [4].

Age groups were divided into four categories: 0–20, 21–40, 41–60, and above 61 years old. The affected regions of the body were classified as skull bones, trunk bones (including ribs), upper limb bones (including shoulder girdle), lower limb bones (including pelvic girdle), and different segments of the spine such as thoracic vertebrae lumbar vertebrae cervical vertebrae sacral vertebrae. Proportions were used to describe and analyze specific indicators of bone involvement. Furthermore, the proportions of bone and joint

involvement in different genders and age groups were calculated to examine potential differences.

Statistical analysis

SPSS 26.0 software was used to analyze the extracted data. According to the conditions of the data, Pearson's chi-square test or Fisher's exact test was used to analyze the differences in the proportion of bone and joint involvement in different genders and ages. If the difference in the proportion between groups was statistically significant, Bonferroni method was used for pairwise comparison between groups. In addition, the chi-square test for trend was used to analyze the trend of proportion in different age groups. The test level $\alpha = 0.05$.

Patient and public involvement

The Ethics Committee of the Guizhou Center for Disease Control and Prevention considered that the ethical approval and consent to participant were not relevant to this study, ethical approval is not required for this review, as it will exclusively use data from published studies.

Results

Description of studies

After conducting an extensive literature search, a total of 612 articles were initially retrieved from various databases including PubMed (145), Web of Science (122), Scopus (64), Embase (165), Cochrane library (1), CNKI (75), Wanfang (17), and VIP database (23). Among them, 68 articles were excluded due to duplication, while 356 articles did not align with the study's objectives based on their title and abstract content. Additionally, 4 articles were inaccessible for various reasons (Figure 1). Subsequently, the remaining 184 articles underwent full-text evaluation resulting in the exclusion of another 86 articles. Ultimately, 98 articles were finally included in our study [1, 13–109], a total of 151 cases (Supplementary Table 2).

Basic characteristics of MOT cases

These 151 cases of MOT were reported between 1958 and 2023, with ages ranging from 7 months to 86 years (median: 25; mean: 30), the highest proportion of cases was observed in the 0–5 years, accounting for 19.87%, with a gradual decline in case numbers noted as age increased (Figure 2). Of the total, there were 89 males and 62 females (male/female = 1.44), distributed across 22 countries worldwide, with China accounting for the largest proportion at 35.10% followed by India at 32.45%. Patients aged between 0 and 10 years accounted for the highest proportion (28.48%), while those aged between 0 and 30 years accounted for nearly 60%. Pulmonary tuberculosis was present in 25 patients with MOT (male/female = 2.57), representing 16.55% of all cases. In terms of bone involvement sites, trunk bones were most commonly affected (63.58%), with spine involvement being predominant (90.63%) among them. Lower limb bone involvement was also common (60.93%). Spinal involvement occurred in over half of all cases (57.62%), with thoracic vertebrae being the most frequently involved site (42.38%) followed by lumbar vertebrae (36.42%). In terms of clinical classification, type I represented 13.91%, while types II and III accounted for 41.72% and 44.37%, respectively (Table 1).

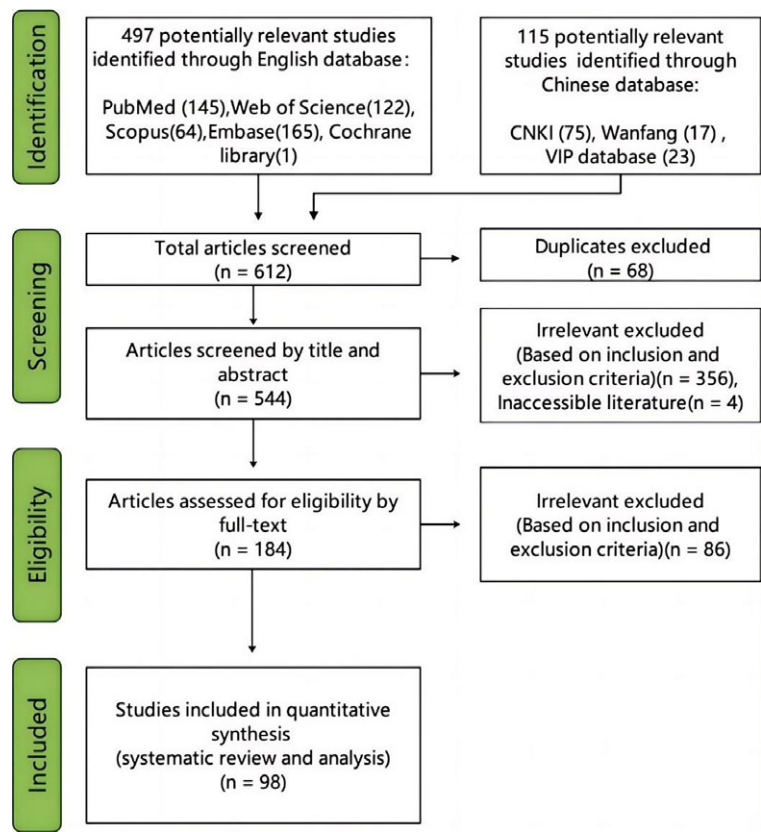


Figure 1. PRISMA flow diagram for study selection.

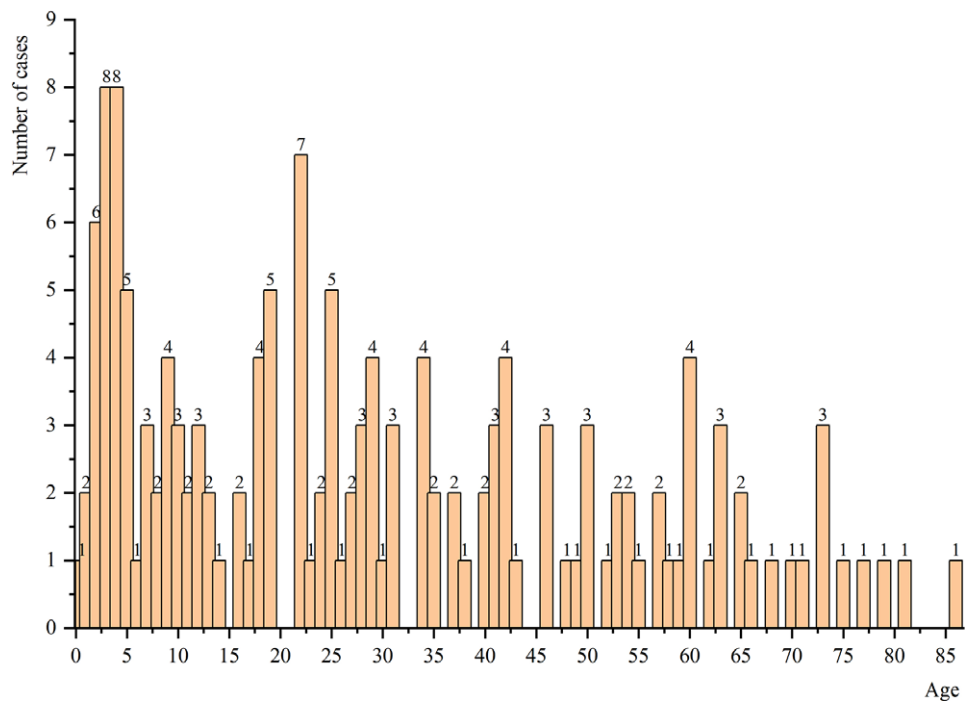


Figure 2. Age distribution of MOT cases.

Table 1. Basic characteristics of patients with MOT (N = 151)

Category	Number of case	Proportion (%)	Category	Number of case	Proportion (%)
Gender	151	100.00	Period of cases	151	100.00
Male	89	58.94	1958 ~ 1999	28	18.54
Female	62	41.06	2000 ~ 2009	33	21.85
Age	151	100.00	2010 ~ 2019	64	42.38
0 ~ 10	43	28.48	2020 ~ 2023	26	17.22
11 ~ 20	20	13.25	Country	151	100.00
21 ~ 30	26	17.22	China	53	35.10
31 ~ 40	14	9.27	India	49	32.45
41 ~ 50	16	10.60	Turkey	11	7.28
51 ~ 60	14	9.27	Iran	4	2.65
61 ~ 70	9	5.96	Pakistan	4	2.65
71 ~ 80	7	4.64	South Africa	4	2.65
80 ~ 90	2	1.32	USA	4	2.65
Pulmonary tuberculosis	151	100.00	Morocco	3	1.99
Yes	25	16.55	UK	3	1.99
No	83	54.97	Filipino	2	1.32
Unknown	43	28.48	Poland	2	1.32
Site of involvement	151	100.00	Tunisia	2	1.32
Skull	22	14.57	Afghanistan	1	0.66
Trunk	96	63.58	Colombia	1	0.66
Upper limb	69	45.70	Indonesia	1	0.66
Lower limb	92	60.93	Israel	1	0.66
Site of spinal involvement	87	57.62	Japan	1	0.66
Thoracic vertebrae	64	42.38	Korea	1	0.66
Lumbar vertebrae	55	36.42	Malaysia	1	0.66
Cervical vertebrae	23	15.23	Portugal	1	0.66
Sacral vertebrae	15	9.93	Senegalese	1	0.66
Type of MOT	151	100.00	Spain	1	0.66
Type I	21	13.91			
Type II	63	41.72			
Type III	67	44.37			

Distribution characteristics of osteoarticular involvement in different ages

There was no statistically significant difference in the proportion of skull involvement among different age groups ($P = 0.13$). However, both MOT cases over 61 years of age and those aged 0–20 years had a higher proportion of skull involvement. A significant difference was observed in the proportion of trunk osteoarticular involvement between different age groups ($P = 0.005$), with the most pronounced difference found between the 0- to 20-years-old group (49.21%) and the over 60-years-old group (88.89%) ($P < 0.05$). Furthermore, there was an increasing trend in the proportion of trunk osteoarticular involvement with advancing age ($P < 0.001$). Significant differences were identified in the proportion of upper limb osteoarticular involvement among different age groups ($P < 0.001$), particularly within the 0- to 20-years-old group

(63.49%) and the 41- to 60-years-old group (13.33%). No significant difference was observed in the proportion of lower limb osteoarticular involvement across different age groups ($P = 0.055$), but there was a decreasing trend noted as age increased ($P = 0.018$) (Figure 3a).

Distribution characteristics of spinal involvement in different ages

There was a significant difference in the proportion of spinal involvement among different age groups ($P = 0.039$), particularly between the 0–20 age group (46.03%) and those over 61 years old (77.78%) ($P < 0.05$). The proportion of spinal involvement increased with age ($P = 0.004$). Significant differences were observed in the proportion of thoracic vertebrae involvement

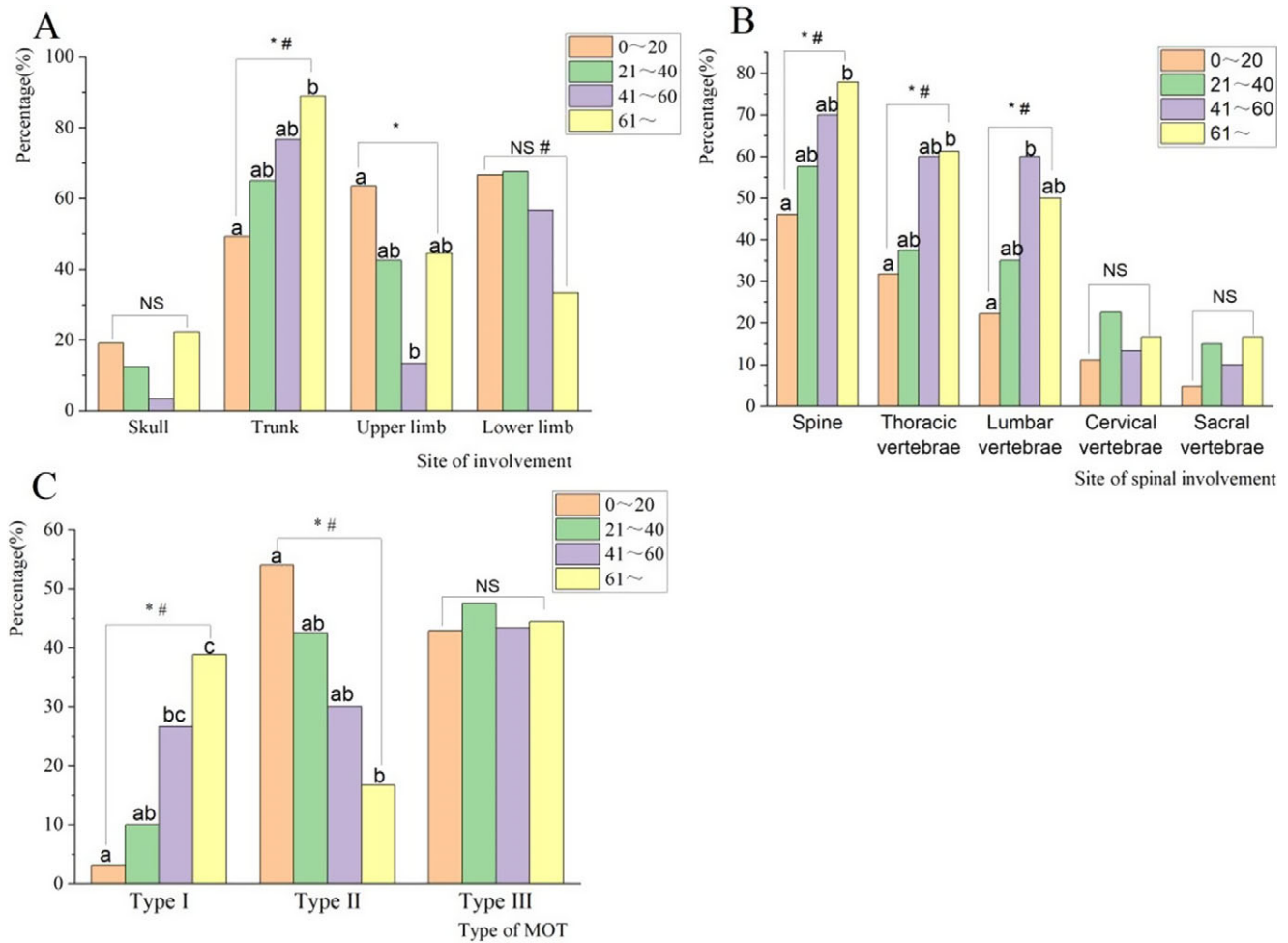


Figure 3. (a) Distribution characteristics of osteoarticular involvement sites in different ages. (b) Distribution characteristics of spinal involvement sites in different age groups. (c) Characteristics of clinical types of MOT in different age groups. The letters represent pairwise comparisons between groups, and the different letters between groups represent statistically significant differences ($P < 0.05$); 'NS' indicates no statistically significant difference between groups ($P > 0.05$); '*' indicates statistically significant differences between groups ($P < 0.05$); '#' represents trend chi-square test with statistical significance ($P < 0.05$).

among different age groups ($P = 0.021$), especially between the 0–20 age group (31.75%) and those over 61 years old (61.11%) ($P < 0.05$). The proportion of thoracic vertebrae involvement also increased with age ($P = 0.003$). Furthermore, there was a significant difference in the proportion of lumbar vertebrae involvement among different age groups ($P = 0.003$), particularly between the 0–20 years old and those aged from 41 to 60 years old (60% vs. 22%, respectively; $P < 0.05$), and the proportion of lumbar vertebrae involvement increased with age ($P = 0.001$), while no significant difference was found for cervical or sacral vertebrae involvement across all ages ($P > 0.05$) (Figure 3b).

Clinical classification characteristics in different ages

There was a significant difference in the distribution of type I cases across different age groups ($P < 0.001$), particularly within the 0–20 (3.17%), 21–40 (10.00%), and over 61 (38.89%) age groups ($P < 0.05$). Moreover, there was an upward trend in the proportion of type I cases with advancing age ($P < 0.001$). The proportion of type II cases exhibited a notable variation among various age groups as well ($P = 0.017$), especially between individuals aged 0- to 20-years old (53.97%) and those above 61 years old (16.67%) ($P < 0.05$). Furthermore, there was an inverse relationship between

the proportion of type II cases and increasing age ($P = 0.001$). Conversely, no statistically significant difference existed in the distribution of type III cases across different age groups ($P = 0.973$) (Figure 3c).

Distribution characteristics of osteoarticular involvement in different genders

Although there was no significant difference in the proportion of skull, trunk, upper limb, and lower limb osteoarticular involvement between male and female patients with MOT ($P > 0.05$), it was noted that the proportion of osteoarticular involvement was greater in males than in females, especially in the skull and lower limb bones and joints (Figure 4a).

Distribution characteristics of spinal involvement in different genders

Even though there was no statistically significant difference in the proportion of spinal, thoracic, lumbar, cervical, and sacral vertebrae involved in MOT cases by gender ($P > 0.05$), it is noteworthy that male (61.80%) exhibited an overall higher proportion of spinal involvement compared to female (51.61%). However, females

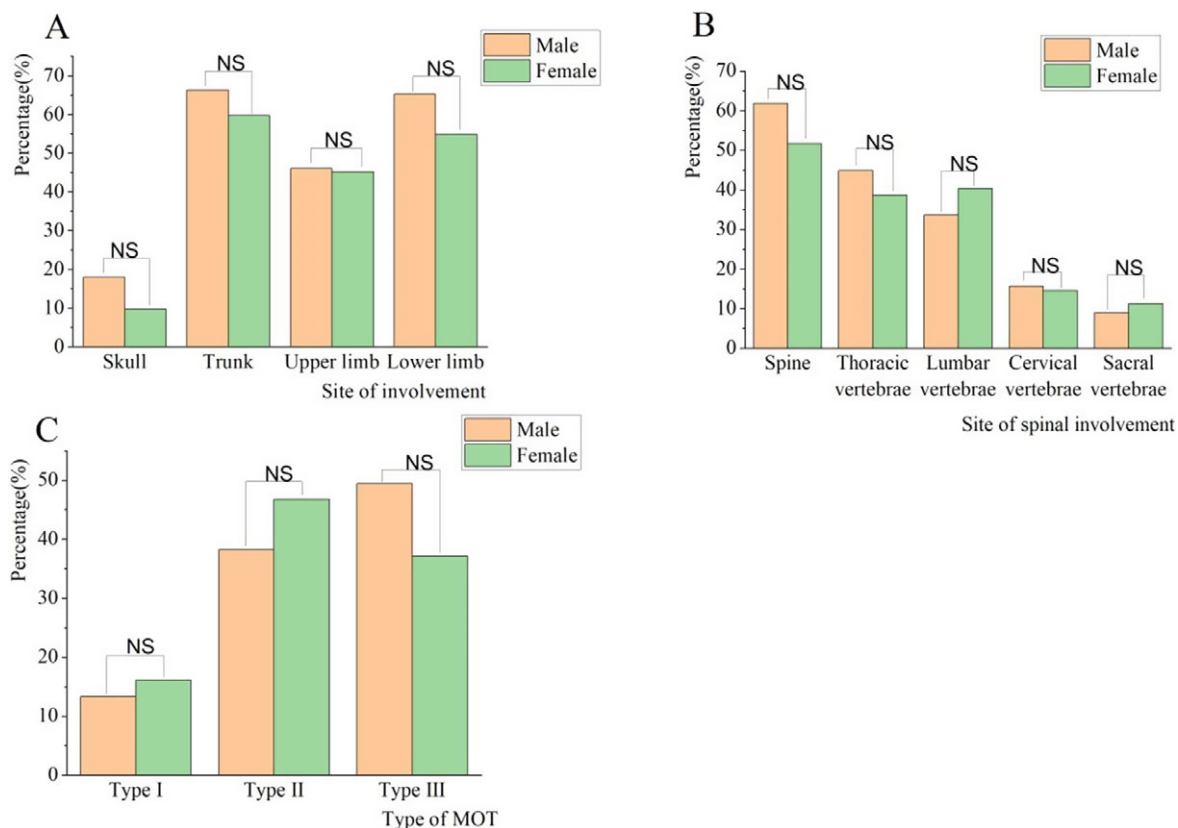


Figure 4. (a) Distribution characteristics of osteoarticular involvement sites in different genders. (b) Distribution characteristics of spinal involvement sites in different genders. (c) Clinical classification in different genders. 'NS' indicates no statistically significant difference between groups ($P > 0.05$).

demonstrated a greater involvement of lumbar and sacral vertebrae than males (Figure 4b).

Clinical classification characteristics in different genders

The proportions of type I, type II, and type III cases did not exhibit any significant differences across different genders ($P > 0.05$) (Figure 4c).

Discussion

Among tuberculosis cases reported by the World Health Organization (WHO) in 2020, 18% were extrapulmonary, with incidence rates ranging from 9% in the Western Pacific Region to 24% in the Eastern Mediterranean Region [110]. Numerous studies have demonstrated an increasing trend in the proportion of extrapulmonary tuberculosis [111, 112]. Bone tuberculosis represents a prevalent form of extrapulmonary tuberculosis, accounting for approximately 10–15% of all cases [113]. A study has reported that in Guangxi province in China, bone and joint tuberculosis accounted for as high as 27.20% of extrapulmonary cases [114].

Conversely, MOT is a rare yet clinically severe manifestation outside the lungs that manifests through pain, tenderness, and activity limitations along with specific and general symptoms depending on disease location, stage, and severity [115, 116]. The physical pain endured by patients with multiple bone tuberculosis coupled with mental and financial stress is unimaginable. This study aimed to elucidate the epidemiological characteristics of MOT and distribution patterns of bone involvement.

We found that the reported MOT cases have increased year by year, suggesting that there may be more MOT cases that have not been detected or reported, which further indicates the importance of the diagnosis and treatment of MOT. Our findings reveal that MOT cases are predominantly concentrated in developing countries such as China and India which also bear the highest burden of TB globally [117, 118]. Furthermore, there is a higher prevalence among males compared to females aligning with gender-specific characteristics observed for tuberculosis infections [119, 120]. Concurrently, the reporting rate for MOT cases has been consistently increasing over time indicating a need for greater attention and research focus.

Our study also presents some notable findings. First, the age distribution of MOT cases primarily concentrates between 0 and 30 years old, particularly within the 0–10 year age group, indicating a tendency for MOT occurrence in younger individuals. Second, children aged 0–5 years represented the highest number of cases; however, it remains unclear whether this is related to their immune systems or BCG vaccination, as evidence in this area is lacking. This underscores the need for increased attention and research on the risk of MOT in children. The proportion of spinal involvement in MOT cases reaches 57.62%, with thoracic vertebrae being predominantly affected, aligning with previous studies [121, 122].

Age stratification analysis reveals that both younger and older age groups exhibit a higher likelihood of skull involvement, while upper limb bone involvement is more prevalent among younger individuals. Notably, lower limb bone involvement decreases with age, while trunk bones become increasingly affected, especially the thoracic and lumbar vertebrae in the spine. Furthermore, gender

differences analysis indicates that males are more prone to skull and lower limb bone involvement, whereas females demonstrate a higher incidence of lumbar and sacral spine involvement; however, further clinical evidence is required to substantiate these observations.

Our study highlights that MOT predominates in developing countries such as China and India. The observed trend towards younger ages at MOT onset along with distinct patterns of bone involvement based on age and gender underscore the importance of considering these characteristics during future clinical diagnosis processes to minimize missed or incorrect diagnoses of MOT. These significant findings warrant additional investigation to elucidate underlying reasons behind these observations aiming at reducing the prevalence of MOT and enhancing cure rates for multiple bone tuberculosis.

Limitations

The primary limitation of our study lies in the insufficient availability of clinical information, such as comorbidities and immune function, for a significant number of MOT cases, thereby impeding further statistical analysis. Furthermore, certain literature sources were inaccessible due to various reasons. Finally, only Chinese and English literature could be accessed while literature in other languages remained unattainable.

Conclusion

MOT cases are predominantly reported in developing countries, with a higher prevalence among individuals aged 0–30 years. Spinal involvement is the most prevalent (57.62%), while there is a decrease in lower limb bone involvement and an increase in trunk bone involvement with age, particularly affecting the thoracic and lumbar vertebrae. Males exhibited a greater likelihood of skull and lower limb bone involvement, whereas females were more prone to lumbar and sacral vertebrae involvement.

Supplementary material. The supplementary material for this article can be found at <http://doi.org/10.1017/S095026882400150X>.

Data availability statement. The original contributions presented in the study are included in the article/Supplementary Information. Further inquiries can be directed to the corresponding author.

Acknowledgements. We thank all the members who participated in this work.

Author contribution. JZ designed the review and analysis, JZ and XJY searched the literature and collated the data, JZ performed the statistical analysis and drafted the initial manuscript, and SJL and YH provided revisions, guidance, and funding support for the article. All authors contributed to the article and approved the submitted version.

Financial support. This study was supported by 'Project for Public Health Talent Cultivation of China. Grant No. Guo Jikong Zong Ren Han [2024]122'.

Competing interest. All the authors declared that there was no conflict of interest in the study.

References

- [1] **Thatoi P**, et al. (2017) Multifocal tubercular Dactylitis: A rare presentation of skeletal tuberculosis in an adult. *Journal of Clinical and Diagnostic Research* **11**(6), OD23–OD24.
- [2] **Gunawan H**, et al. (2019) A rare case of multiple lupus vulgaris in a multifocal tuberculosis pediatric patient. *International Journal of Mycobacteriology* **8**(2), 205–207.
- [3] **Zhang H**, et al. (2016) Atypical imaging of spinal tuberculosis: A case report and review of literature. *Pan African Medical Journal* **24**, 101.
- [4] **Muradali D**, et al. (1993) Multifocal osteoarticular tuberculosis: Report of four cases and review of management. *Clinical Infectious Diseases* **17**, 204–209.
- [5] **Na S**, et al. (2023) Diagnosis and treatment of skipped multifocal spinal tuberculosis lesions. *Orthopaedic Surgery* **15**(6), 1454–1467.
- [6] **Sahoo MM**, et al. (2019) Role of percutaneous transpedicular biopsy in diagnosis of spinal tuberculosis and its correlation with the clinico-radiological features. *The Indian Journal of Tuberculosis* **66**(3), 388–393.
- [7] **Kaila R**, et al. (2007) The incidence of multiple level noncontiguous vertebral tuberculosis detected using whole spine MRI. *Journal of Spinal Disorders & Techniques* **20**(1), 78–81.
- [8] **Herzog A** (2009) Dangerous errors in the diagnosis and treatment of bony tuberculosis. *Deutsches Arzteblatt International* **106**(36), 573–577.
- [9] **Wang B**, et al. (2020) Current study of the detection and treatment targets of spinal tuberculosis. *Current Drug Targets* **21**(4), 320–327.
- [10] **He Y**, et al. (2020) Analysis of the early clinical outcomes of arthroscopic debridement in the treatment of shoulder tuberculosis. *Journal of Orthopaedic Surgery and Research* **15**(1), 550.
- [11] **Cheng J**, et al. (2019) Tuberculosis of acromioclavicular joint: A case report. *BMC Infectious Diseases* **19**(1), 111.
- [12] **Tricco AC**, et al. (2018) PRISMA extension for scoping reviews (PRISMA-ScR): Checklist and explanation. *Annals of Internal Medicine* **169**, 467–473.
- [13] **Afzali H**, et al. (2012) A case report of disseminated multifocal bone tuberculosis. *Journal of Clinical Immunology* **32**, S249.
- [14] **Agarwal A**, et al. (2014) Lytic lesions of distal radius in children: A rare tubercular presentation. *Hand Surgery* **19**, 369–374.
- [15] **Agarwal A**, et al. (2011) Multifocal osteoarticular tuberculosis in children. *Journal of Orthopaedic Surgery* **19**, 336–340.
- [16] **Aggarwal A**, et al. (1997) Multifocal cystic bone tuberculosis with lupus vulgaris and lymphadenitis. *Indian Pediatrics* **34**, 443–446.
- [17] **Ali M**, et al. (2004) Symmetrical lytic lesions in ulna: Unusual presentation of multifocal osteoarticular tuberculosis. *Journal of the Pakistan Medical Association* **54**, 339–340.
- [18] **Arslan A**, et al. (1999) Multifocal bone tuberculosis presenting as a breast mass: CT and MRI findings. *European Radiology* **9**, 1117–1119.
- [19] **Assadi M**, et al. (2009) Diagnostic role of whole body bone scintigraphy in atypical skeletal tuberculosis resembling multiple metastases: A case report. *Journal of Medical Case Reports* **3**, 141.
- [20] **Baghdadi T**, et al. (2016) Multifocal tuberculosis of long bones in an immunocompetent child. *Journal of Pediatric Orthopaedics. Part B* **25**, 248–252.
- [21] **Bodur H**, et al. (2003) Multifocal tuberculosis presenting with osteoarticular and breast involvement. *Annals of Clinical Microbiology and Antimicrobials* **2**, 6.
- [22] **Chabchoub I**, et al. (2021) Multifocal bone tuberculosis simulating metastasis. *Clinical Case Reports* **9**, e04536.
- [23] **Chandiralingam P**, et al. (2015) Multifocal tuberculous osteomyelitis: A rare presentation. *The Indian Journal of Tuberculosis* **62**, 43–45.
- [24] **Chang DS**, et al. (1998) Primary multifocal tuberculous osteomyelitis with involvement of the ribs. *Skeletal Radiology* **27**, 641–645.
- [25] **Chaudhry LA**, et al. (2013) A 35-year-old immuno-competent male with open pulmonary tuberculosis associated with extra-ordinary extensive extrapulmonary tuberculosis. *International Journal of Mycobacteriology* **2**(3), 183–186.
- [26] **Chen C**, et al. (2004) A case of misdiagnosis of bone tumor by multiple iliac bone tuberculosis. *Journal of Modern Medicine & Health* **20**, 769.
- [27] **Chen T**, et al. (2023) One case of multiple bone tuberculosis, left skull base, middle ear and bilateral cervical lymph node tuberculosis. *Journal of China Clinic Medical Imaging* **39**(10), 1593.
- [28] **Cheng MH**, et al. (2012) A case of rare multiple bone tuberculosis. *Chinese Journal of Clinicians (Electronic Edition)* **6**, 6600–6601.

- [29] **Cheng MY**, et al. (2004) A case of rare multiple iliac bone tuberculosis. *Journal of Medical Radiology Technology* 100.
- [30] **Cheng YL**, et al. (2016) Clinical analysis of six misdiagnosis cases with atypical multifocal osteoarticular tuberculosis. *Chinese Journal of Antituberculosis* 8, 645–648.
- [31] **Chiu YC**, et al. (2022) Single posterior approach for circumferential debridement and anterior reconstruction using fibular allograft in patients with skipped multifocal spinal tuberculosis. *Journal of Orthopaedic Surgery and Research* 17(1), 489.
- [32] **Dewan P**, et al. (2017) Multifocal tuberculous osteomyelitis in a 3-year-old child. *Paediatrics and International Child Health* 37, 152–154.
- [33] **Dickinson FL**, et al. (1996) Multifocal skeletal tuberculosis: Bone scan appearances. *Nuclear Medicine Communications* 17, 957–962.
- [34] **Dlimi F**, et al. (2011) Multifocal bone tuberculosis: A case report. *Foot and Ankle Surgery*. 17, e47–e50.
- [35] **Dong AS**, et al. (2010) A case of multiple bone tuberculosis. *Journal of Clinical Radiology* 29, 1236–1237.
- [36] **Dong JX**, et al. (1959) A case report of multiple cap sular bone tuberculosis. *Chinese Journal of Radiology*. 07, 225.
- [37] **Eid A**, et al. 1994) Multifocal musculoskeletal cystic tuberculosis without systemic manifestations. *Scandinavian Journal of Infectious Diseases* 26, 761–764.
- [38] **Elghoul N**, et al. (2020) A report of two challenging cases of bone infection: *Mycobacterium tuberculosis* How to manage?. *Oxford Medical Case Reports* 2020, omaa025.
- [39] **Gelal F**, et al. (2006) Multifocal skeletal tuberculosis involving the lumbar spine and a sacroiliac joint: MR imaging findings. *Diagnostic and Interventional Radiology (Ankara, Turkey)* 12, 139–141.
- [40] **Girisha BS**, et al. (2018) A case of multifocal tuberculosis involving skin and bone: An uncommon presentation. *Indian Dermatology Online Journal* 9, 458–460.
- [41] **Go SW**, et al. (2012) Atypical disseminated skeletal tuberculosis mimicking metastasis on PET-CT and MRI. *Internal Medicine* 51, 2961–2965.
- [42] **Gosal G**, et al. (2012) Multifocal skeletal tuberculosis involving the lumbar spine and iliac bone, mimicking a malignant bone tumour: A case report. *Malaysian Orthopaedic Journal* 6(3), 51.
- [43] **Günay B**, et al. (2022) A rare presentation of tuberculosis: Multifocal skeletal and multisystemic disease evaluated with imaging findings. *Journal of the Belgian Society of Radiology* 106, 14.
- [44] **Gur A**, et al. (2014) Multifocal skeletal tuberculosis presenting as paraplegia: A case report. *Journal of Back And Musculoskeletal Rehabilitation* 27, 239–245.
- [45] **Haghighatkah H**, et al. (2015) Multifocal skeletal tuberculosis mimicking Langerhans cell Histiocytosis in a child: A case report with a long-term follow-up. *Iranian Red Crescent Medical Journal* 17, e19942.
- [46] **Haider N**, et al. (2011) Tubercular dactylitis and multifocal osteoarticular tuberculosis – two rare cases of extrapulmonary tuberculosis. *BMJ Case Reports* 2011 bcr0920114800.
- [47] **Hardoff R**, et al. (1995) Multifocal osteoarticular tuberculosis resembling skeletal metastatic disease. Evaluation with Tc-99m MDP and Ga-67 citrate. *Clinical Nuclear Medicine* 20, 279–281.
- [48] **Hassen-Zrou S**, et al. (2008) Dactylite tuberculeuse multifocale: à propos d'un cas Multifocal tuberculous dactylitis: A case report. *Chirurgie de la Main*. 27, 122–125.
- [49] **Hong L**, et al. (2010) Multifocal skeletal tuberculosis: Experience in diagnosis and treatment. *Medecine et Maladies Infectieuses* 40, 6–11.
- [50] **Hopkins GO** (1983) Multiple joint tuberculosis presenting as HLA-B27 disease. *Postgraduate Medical Journal* 59, 113–115.
- [51] **Hu S**, et al. (2015) Multifocal osteoarticular tuberculosis of the extremities in an immunocompetent young man without pulmonary disease: A case report. *Experimental and Therapeutic Medicine* 9, 2299–2302.
- [52] **Jaiswal A**, et al. (2006) Multifocal skeletal TB or disseminated bone TB. *Tropical Doctor* 36, 178–180.
- [53] **Jia MS**, et al. (1990) A case report of multiple cap sular bone tuberculosis. *Chinese Journal of Orthopaedics* 10, 381–C3.
- [54] **Jiang SD** (1994) A case of multiple cystic bone tuberculosis. *Jiangxi Medical Journal* 193.
- [55] **Keles I**, et al. (2005) Multifocal osteoarticular tuberculosis: A case report. *Rheumatology International* 25(4), 307–310.
- [56] **Kimizuka Y**, et al. (2013) A case of skeletal tuberculosis and psoas abscess: Disease activity evaluated using 18 F-fluorodeoxyglucose positron emission tomography-computed tomography. *BMC Medicine Imaging* 13, 37.
- [57] **Aggarwal AN**, et al. (2009) Tubercular osteomyelitis of the clavicle- a report of four cases. *J Orthop Surg (Hong Kong)* 17(1), 123–6.
- [58] **Kumar K**, et al. (1988) Multifocal osteoarticular tuberculosis. *International Orthopaedics* 12, 135–138.
- [59] **Lemos AP**, et al. (2019) Multifocal chronic osteomyelitis to multiresistant *Serratia Marcescens* in a child with sick cell disease and bone tuberculosis. *Cogent Medicine* 6, 1.
- [60] **Li BY**, et al. (2019) A case of rare recurrent, multiple bone tuberculosis. *Chinese Journal of Antituberculosis* 41, 579–582.
- [61] **Li M**, et al. (2014) A case of aplastic anemia with generalized multiple osteoarticular tuberculosis. *Chinese Journal of Antituberculosis* 36, 402–403.
- [62] **Liang HJ** (1999) Multiple foci of bony tuberculosis: A case report. *Chinese Journal of Orthopaedics* 19(12), 715.
- [63] **Lim SL**, et al. (2020) Multifocal osteoarticular tuberculosis in a systemic lupus erythematosus (SLE) patient: A rarity or an underdiagnosed condition? *Modern Rheumatology Case Reports* 4, 237–242.
- [64] **Liu SZ**, et al. (1990) A case report of multiple cap sular bone tuberculosis. *Chinese Journal of Radiology* 24, 90.
- [65] **Lynn MM**, et al. (2012) Troublesome tuberculosis: A case report on multi-focal tuberculous osteomyelitis in an immunocompetent patient. *Journal of Clinical Medicine Research* 4(1), 73–76.
- [66] **Ma LS**, et al. (1958) A case report of multiple pseudocystic bone tuberculosis. *Chinese Journal of Pediatrics* 9, 379.
- [67] **Mandal A**, et al. (2017) The many faces of tuberculosis. *International Journal of Pediatrics & Adolescent Medicine* 4, 112–114.
- [68] **Marudanayagam A**, et al. (2006) Multifocal skeletal tuberculosis: A report of three cases. *The Iowa Orthopaedic Journal* 26, 151–153.
- [69] **Mellat-Ardakani M**, et al. (2021) Multifocal Osteolytic lesions in skull bone with *mycobacterium tuberculosis*: A case report. *Infectious Disorders Drug Targets* 21, e270421187878.
- [70] **Morris BS**, et al. (2002) Multifocal musculoskeletal tuberculosis in children: Appearances on computed tomography. *Skeletal Radiology* 31, 1–8.
- [71] **Nabih SO**, et al. (2020) Contribution of radiobiphosphonates bone scan in multifocal tuberculous osteomyelitis. *World Journal of Nuclear Medicine* 19, 184–186.
- [72] **Nataprawira HM**, et al. (2019) Multifocal Osteomyelitic tuberculosis at rare locations with metastatic tuberculosis abscess. *American Journal of Case Reports* 20, 503–507.
- [73] **Nataraj AR**, et al. (2011) Multifocal skeletal tuberculosis presenting as periarthritis of shoulder joint: A case report. *European Orthopaedics and Traumatology* 2, 93–95.
- [74] **Opala A**, et al. (2023) A successful bisphosphonates monotherapy in spinal form of Paediatric chronic recurrent multifocal osteomyelitis (CRMO)-case report. *Metabolites* 13, 344.
- [75] **Ozol D**, et al. (2006) Active pulmonary tuberculosis with vertebra and rib involvement: Case report. *Southern Medical Journal* 99, 171–173.
- [76] **Qu MY**, et al. (2015) Case analysis of tuberculosis of multiple bones and joints: Diagnosis and treatment with literature review. *Journal of Clinical Research* 32(9), 1710–1713.
- [77] **Ramírez-Sánchez IC**, et al. (2021) Multifocal skeletal tuberculosis with mycobacteremia after kidney transplantation: A case report. *Transplant Infectious Disease* 23, e13591.
- [78] **Rasool MN** (2001). Osseous manifestations of tuberculosis in children. *Journal of Pediatric Orthopaedics* 21, 749–755.
- [79] **Rathod NM**, et al. (2017) Multifocal tuberculosis presenting as metastatic tumour. *The Journal of the Association of Physicians of India* 65, 102–103.
- [80] **Reyes HA**, et al. (2017) Multifocal Osteoarticular tuberculosis in a lupus with Sjogren syndrome patient. *American Journal of Therapeutics* 24, e498–e499.

- [81] **Sabat D**, et al. (2008) Scapholunate dissociation: A rare presentation of TB wrist in a case of multi-focal skeletal tuberculosis. *Indian Journal of Tuberculosis* **55**(3), 149.
- [82] **Sardana R**, et al. (2020) Tuberculosis of the axial skeleton mimicking malignancy. *Journal of the Royal College of Physicians of Edinburgh* **50**(2), 168–170.
- [83] **Sezgin B**, et al. (2008) Concomitant cutaneous metastatic tuberculous abscesses and multifocal skeletal tuberculosis. *Indian Journal of Dermatology* **53**, 149–153.
- [84] **Shah BA**, et al. (2005) Multifocal osteoarticular tuberculosis. *Orthopedics* **28**, 329–332.
- [85] **Shanmugam VK**, et al. (2019) Retinal vasculitis with chronic recurrent multifocal osteomyelitis: A case report and review of the literature. *BMC Rheumatology* **3**, 1–12.
- [86] **Shannon FB**, et al. (1990) Multifocal cystic tuberculosis of bone. Report of a case. *Journal of Bone and Joint Surgery-American Volume* **72**, 1089–1092.
- [87] **Shi GC**, et al. (2014) A case of multiple bone tuberculosis. *Chinese Journal of Antituberculosis* **36**, 299–300.
- [88] **Shyam S**, et al. (2011) Multifocal osteoarticular tuberculosis presenting as oligoarticular chronic juvenile arthritis. *Journal of Musculoskeletal Research* **14**, 1272002.
- [89] **Singh R**, et al. (2021) Multifocal osseous tuberculosis mimicking Langerhans' cell Histiocytosis: A case series. *Indian Journal of Radiology and Imaging* **31**, 378–382.
- [90] **Song L**, et al. (2010) Multifocal skeletal tuberculosis detected by whole body bone scintigraphy: Report of one case. *Journal of China Clinic Medical Imaging* **21**, 910–901.
- [91] **Song LX**, et al. (1999) A case of multiple capsular bone tuberculosis. *Chinese Journal of Radiology* **28**.
- [92] **Soriano V**, et al. (1992) Multifocal bone tuberculosis in one AIDS patient. *Genitourinary Medicine* **68**, 273.
- [93] **Tang SY**, et al. (1994) Report of a case of multiple bone tuberculosis of the ipsilateral limb. *Journal of Clinical Surgery* **70**.
- [94] **Turgut M** (2001) Multifocal extensive spinal tuberculosis (Pott's disease) involving cervical, thoracic and lumbar vertebrae. *British Journal of Neurosurgery* **15**, 142–146.
- [95] **Wang C**, et al. (2020) Multifocal tuberculosis simulating a cancer—a case report. *BMC Infectious Diseases* **20**, 495.
- [96] **Wang JP**, et al. (2006) One case: Multiple Bone Tuberculosis. *Journal of Practical Radiology* **22**, 739,55.
- [97] **Wei GF**, et al. (1988) Report of a case of multiple tuberculosis of the skull combined with tuberculosis of the lateral condyle of the left humerus, tuberculosis of the middle phalanx of the right thumb, and tuberculosis of the skin of both eyelids. *Chinese Community Doctors* **28**.
- [98] **Xie LZ**, et al. (2019) Analysis on diagnosis and treatment process of one patient with multiple osteoarticular tuberculosis complicated with multiple cutaneous tuberculosis. *Chinese Journal of Antituberculosis* **41**, 112–117.
- [99] **Xu H**, et al. (2011) A case of multiple osteoarticular tuberculosis with cutaneous tuberculosis in a child and review of the literature. *Academic Journal of Chinese PLA Medical School* **32**, 767–768.
- [100] **Yang L**, et al. (2004) Report of misdiagnosis of multiple tuberculous arthritis. *Clinical Misdiagnosis & Mistherapy* **17**, 41.
- [101] **Yang ZY**, et al. (2007) A case of multiple osteoarticular tuberculosis of the pterygoid- saddle region of the skull base and of the whole body. *Chinese Journal of Radiology* **41**, 1413–1415.
- [102] **Ye M**, et al. (2016) Multifocal musculoskeletal tuberculosis mimicking multiple bone metastases: A case report. *BMC Infectious Diseases* **16**, 34.
- [103] **Yilmaz MH**, et al. (2004) Multifocal skeletal tuberculosis. *Southern Medical Journal* **97** 785.
- [104] **Yu YP**, et al. (2013) Multifocal bone infarcts combined with bone tuberculosis: 3 case report. *Chinese Journal of Bone and Joint* 531–534.
- [105] **Yue JB** (1992). Report of a case of generalized multiple cystic bone tuberculosis. *Journal of Clinical Radiology* 325–341.
- [106] **Zhang L**, et al. (2016) Multifocal skeletal tuberculosis: A case report. *Experimental and Therapeutic Medicine*. **11**, 1288–1292.
- [107] **Zhang LX**, et al. (2009) A case of multiple bone tuberculosis with erythema nodosum as its first manifestation. *The Medical Forum* **13**, 138.
- [108] **Zhou XZ**, et al. (1993) A case of multiple osteoarticular tuberculosis with bilateral pleural effusion. *Chinese Journal of Antituberculosis* 37–38.
- [109] **Znajdek M**, et al. (2019) Juvenile spondyloarthritis and chronic recurrent multifocal osteomyelitis overlap syndrome in a 16-year-old adolescent. A case report and literature review. *Journal of Ultrasonography*; **19**, 152–7.
- [110] **WHO** (2021) Tuberculosis data. Available from: <https://www.who.int/teams/Global-tuberculosis-programme/data>.
- [111] **Mok J**, et al. (2019) Drug resistance in extrapulmonary tuberculosis in South Korea: Comparison with pulmonary tuberculosis. *International Journal of Tuberculosis And Lung Disease* **23**(2), 151–156.
- [112] **Chen L**, et al. (2021) Upward trends in new, rifampicin-resistant and concurrent extrapulmonary tuberculosis cases in northern Guizhou Province of China. *Scientific Reports* **11**(1), 18023.
- [113] **Golden MP**, et al. (2005) Extrapulmonary tuberculosis: An overview. *American Family Physician* **72**(9), 1761–1768.
- [114] **Li L**, et al. (2023) Epidemiology of extrapulmonary tuberculosis in Central Guangxi from 2016 to 2021. *European Journal of Clinical Microbiology & Infectious Diseases* **42**(2), 129–140.
- [115] **Procopie I**, et al. (2017) Osteoarticular tuberculosis-brief review of clinical morphological and therapeutic profiles. *Current Health Sciences Journal* **43**, 171–190.
- [116] **Arathi N**, et al. (2013) Osteoarticular tuberculosis—a three years' retrospective study. *Journal of Clinical and Diagnostic Research* **7**, 2189–2192.
- [117] **Chakaya J**, et al. (2021) Global tuberculosis report 2020 – reflections on the global TB burden, treatment and prevention efforts. *International Journal of Infectious Diseases* **113**(Suppl 1), S7–S12.
- [118] **Couvin D**, et al. (2019) Two tales: Worldwide distribution of central Asian (CAS) versus ancestral east-African Indian (EAI) lineages of *Mycobacterium tuberculosis* underlines a remarkable cleavage for phylogeographical, epidemiological and demographical characteristics. *PLoS One* **14**(7), e0219706.
- [119] **Hertz D**, et al. (2019) Sex differences in tuberculosis. *Seminars in Immunopathology* **41**(2), 225–237.
- [120] **GBD 2019 tuberculosis collaborators** (2022) Global, regional, and national sex differences in the global burden of tuberculosis by HIV status, 1990–2019: Results from the global burden of disease study 2019. *Lancet Infectious Diseases* **22**(2), 222–241.
- [121] **Wu R**, et al. (2023) A high proportion of caseous necrosis, abscess, and granulation tissue formation in spinal tuberculosis. *Frontiers in Microbiology* **14**, 1230572.
- [122] **Wang DM**, et al. (2023) Osteoarticular tuberculosis cases in the southwest of China: A 9-year retrospective study. *Frontiers in Medicine* **10**, 1051620.