

Imaging and treatment of idiopathic abdominal cocoon in 9 patients

RUI YU*, YANG YA, XIAOQIONG NI and GUOHUA FAN*

Department of Radiology, The Second Affiliated Hospital of Soochow University, Suzhou, Jiangsu 215004, P.R. China

Received April 13, 2019; Accepted November 1, 2019

DOI: 10.3892/etm.2019.8258

Abstract. The aim of the current study was to investigate the imaging features of abdominal cocoon (AC), the methods of diagnosis and treatment of AC and improve understanding of AC. To do this, the current study retrospectively analyzed the clinical data and imaging findings of nine patients with AC. The clinical manifestations included intestinal obstruction in six out of the nine cases of AC, which included two cases of bowel strangulation and five cases of soft masses in the abdomen. Imaging features of AC included the following: i) Bowel loops were usually present in a fixed cluster; ii) bowel loops were encapsulated partially or totally by a thickening fibrous membrane-like ‘cocoon’; iii) bowel wall thickened in the ‘cocoon’, and the bowel loops and sac adhered; iv) loculated ascites in the ‘cocoon’; v) abnormal clustering of the mesenteric vasculature, hypoplasia of the omentum majus was present or absent; and vi) Ileus occurred in some cases. The features of a plain abdominal X-ray, a gastrointestinal barium meal series and ultrasonography lacked specificity. The results of CT in eight out of nine cases of AC were consistent with the surgical findings. Surgery was the first choice of therapy. All cases were treated surgically, showing that the bowel loops were encapsulated partially or totally by a thickened fibrous membrane. All cases received operations including partial or total excision of the membrane and enterolysis. In conclusion, CT may be highly valuable in the preoperative diagnosis of AC.

Introduction

Abdominal cocoon (AC) is a rare clinical entity that is infrequently reported, with the majority of cases occurring

post-operatively (1). Abdominal cocoon is an abdominal disease characterized by a fibrous membrane enveloping part or all of the organs of the abdominal pelvis; covering of the small intestine is the most common presentation. Named for its resemblance to a cocoon, the condition is also termed peritoneal fibrosis, peritoneal sclerosis, calcified peritonitis and encapsulated peritoneal sclerosis (1). Clinically, this disease has no specific symptoms or abnormal laboratory diagnostic indicators; often, acute abdominal pain, an abdominal mass or incomplete intestinal obstruction are the first symptoms identified in hospital. AC is a rare peritoneal disease, the pathogenesis of which remains to be determined. It is difficult to make a definite pre-operative diagnosis, thus AC is often misdiagnosed or omitted (2). Correct pre-operative diagnosis and early treatments may reduce complications, but also reduce mortality (2,3). Imaging examinations, especially CT, can facilitate pre-operative diagnosis, but few studies have discussed AC's imaging features and the diagnostic value of radiological imaging. The authors of the present study analyzed the clinical data and imaging results of nine patients who were diagnosed with AC from laparotomy and histopathological examinations between January 1991 and January 2018 in The Second Affiliated Hospital of Soochow University. The authors also reviewed the relevant literature to investigate the imaging characteristics, clinical symptoms and treatments of AC in order to improve understanding of the condition, which may help in the selection of suitable detection methods and treatment protocols.

Materials and methods

Data review. The case files of patients with AC were extracted from The Second Affiliated Hospital of Soochow University between January 1991 and January 2018. Data included clinical manifestations, imaging examinations, diagnoses and treatments of the nine patients with AC, and were reviewed in detail. Patients inclusion criteria were as follows: i) Surgical treatment and complete pathological data; ii) CT scan and enhanced scan completed prior to surgery; iii) Patients had no previous history of abdominal surgeries, peritonitis, tuberculosis or peritoneal dialysis, autoimmune diseases or prolonged drug intake. Patients exclusion criteria were: Patients who received CT scan without an enhanced CT. All patients were followed up (at 3, 6 and 12 months after surgery) by telephone or using the outpatient service.

Correspondence to: Professor Guohua Fan, Department of Radiology, The Second Affiliated Hospital of Soochow University, 1055 Sanxiang Road, Gusu, Suzhou, Jiangsu 215004, P.R. China
E-mail: fangh22@sina.com

*Contributed equally

Key words: abdominal cocoon, intestinal obstruction, imaging, diagnosis, treatment

Radiological imaging

X-ray and sonographic examination. Plain abdominal X-ray and ultrasonography were performed before surgery as routine examinations. A barium meal was performed in patients with or without partial intestinal obstruction, and a barium follow through was observed at different times (60 and 90 min) after drinking barium.

CT examination. CT scans and subsequent contrast-enhanced CT scans were performed with a 64 detector row helical CT scanner in all cases. For the patients with or without partial intestinal obstruction, 4% mannitol was orally administered 1 h before the examination to fill the gastrointestinal tract.

Surgery. A laparotomy was performed 24 h after helical CT in all nine cases. All samples were histopathologically examined. The pathological examination was performed under an optical microscope with a magnification of x100. Fixation was performed using 10% formalin at room temperature for 6-8 h. Staining was performed using hematoxylin-eosin at 40°C for ~30 min. The thickness of the tissue sections was 4 µm.

Results

Patient characteristics. The current study included a total of nine patients with a mean age of 43 years (range, 25-64 years), which included five men and four women. All patients had no previous history of abdominal surgeries, peritonitis, tuberculosis or peritoneal dialysis, autoimmune diseases or prolonged drug intake. All patients showed recurrent abdominal pain and distention, which was more apparent after meals, six cases had episodes of intestinal obstruction, abdominal distention, colicky abdominal pain, nausea and vomiting and five cases had a non-tender, soft, smooth mass upon abdominal palpation and the boundary of the mass was not sharp (Table I).

Imaging. The plain abdominal X-ray examination identified that six out of nine cases presented with dilated small-bowel loops with air-fluid levels in the small intestine. A total of three cases provided normal findings. Following the barium meal examination revealed that seven of the nine patients had a cauliflower sign, which consisted of disorderly arranged and bunched bowels that congregated in a single area. When pressing the clustered bowel loops, they remained in a constant position (Fig. 1; Table II). A total of six cases presented with dilated small-bowel loops with air-fluid levels and the small-bowel transit time was delayed. However, the mucous membrane of the small intestine was normal. Sonographic examination identified that each patient had a mass within the echogenic bowels and a number of cases had masses within the liquid anechoic area (Fig. 2).

CT interpretation. An appropriate amount (1,000-1,500 ml) of oral 4% mannitol liquid was used as the contrast medium that filled the gastrointestinal tract prior to the CT scan, and helped to identify clustered intestinal loops encased by a membrane-like sac. In six cases, the small-bowel loops congregated in the middle-lower abdomen, and were encased by a soft-tissue density mantle. Partial small-bowel loops were encased by the sac in two cases and the small bowel was

rarely out of the sac. A section of the colon was covered in one case. A small amount of fluid was identified between the sac and these encapsulated bowel loops (Fig. 3; Table II). A thick (2 mm) mild-moderate enhancing membrane surrounded the bowel, and the wall of the enhancing membrane was well-distributed in seven cases. The corresponding mesenteric structure had developmental abnormalities with centralized mesenteric vessels, and the omentum majus appeared hypoplastic or absent. A Bottle Gourd sign was noted in six cases. A Bottle Gourd sign is the dilatation of the second and third part of the duodenum with encasement of distal duodenum and jejunal loops (4). A total of two cases out of nine presented with strangulated intestinal obstruction. The CT findings included a thickened intestine wall, which either could not be enhanced or could be enhanced slightly, and mesenteric hydrops when the mesenteric fat gained density. Ascitic fluid was identified in six of nine patients.

Surgical interpretation. Upon opening the abdomen, all or part of the small bowel and the colon were revealed to be enclosed by a whitish cocoon-like sac (Fig. 4A). The small bowel was shortened and the intestine was either lacking or missing entirely, or in the abdominal cavity. During surgery it was observed that the sac's position, size and the scope of involved intestine were consistent with CT findings. Part of the tough well-distributed membrane-like tissues adhered to the wall of abdomen, which was 2-mm thick and involved encased intestine loops. The tissues congregated to the center of the abdomen with the intestine loops adhering to each other and to the sac. Dilated proximal bowel loops were observed in six cases, two of which had strangulated intestinal obstruction with the presence of dark purple thickening and swelling of the necrotic bowel wall. A small volume of flaxen or red liquid was observed in the sac, and edematous mesenteric and bloody dialysis was effluent in the abdominal cavity. Homologous mesenteric vessels with preternatural distribution thickened and centralized. The greater omentum appeared hypoplastic or absent.

Surgical treatment. Adherent areas in most cases were loose and easy to separate. After excision of the cocoon-like fibrous tissue, the adhesions among bowel loops, between loops and the sac wall or between the sac and abdominal wall were dissected allowing the encapsulated intestines to be freed (Fig. 4B), and the intestine was rearranged. Resection of the necrotic bowel was also required. Sufficient postoperative drainage was performed after rinsing the abdominal cavity repeatedly. All patients were followed up (3, 6 and 12 months after surgery) by telephone or using the outpatient service, and the prognosis was good, with patients being asymptomatic.

Pathological examination. The microbiological examination of the opalescent membrane showed proliferation of fibro-connective and adipose tissue with a chronic inflammatory reaction accompanied by degeneration or necrosis and formation of form granulation tissue (Fig. 5). The dark purple wall of the necrotic bowel thickened and swelled with the hemorrhagic contents leaking into the enteric cavity. Microscopically, the bowel wall was observed to bleed, necrose and exhibit the inflammatory reaction.

Table I. Clinical data of nine cases of abdominal cocoon.

Clinical data	Number of cases	Ratio (%)
Sex		
Male	5	55.56
Female	4	44.44
Clinical symptoms		
Abdominal pain and detention	9	100
Intestinal obstruction	6	66.67
Abdominal mass	5	55.56

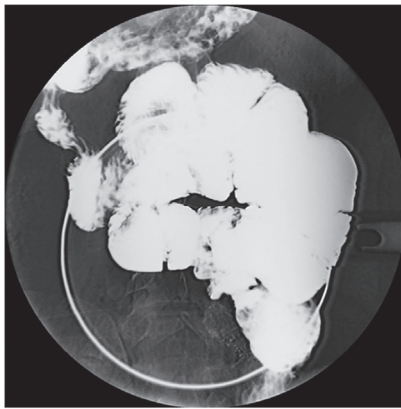


Figure 1. Barium meal follow through radiograph shows small bowel loops bunched and confined in the central abdomen and with a cauliflower sign. The clustered bowel loops maintain a constant position when pressed.

Discussion

The observation that abdominal organs were partially or totally encased in a fibrous membrane and consisted of multiple internal adhesions was first reported by Owtschinnikow (5) in 1907, in a study entitled 'Peritonitis chronic fibrosa incapsulata'. However, the condition has also been described as peritoneal fibrosis, peritoneal sclerosis, calcified peritonitis and encapsulated peritoneal sclerosis (1). The abdominal cocoon was first named in 1978 by Foo *et al* (6). The fibrous membrane surrounds the small bowel, but it occasionally extends to include the colon, stomach or other organs (7). However, it rarely encases all abdominal organs. The authors of the current study hypothesized that the abdominal cocoon may reflect the morphological symptoms of this condition more directly as the fibrous sac is not limited to the small intestine, and a number of cases in the literature (4,8,9) also lack the inflammatory reaction and calcification.

AC is a rare peritoneal disease, the pathogenesis of which remains to be determined. AC can be divided into an idiopathic and a secondary form (10). The idiopathic form has been reported to be associated with congenital dysplasia (11). Causes of the secondary form include chronic peritoneal dialysis, intra-abdomen foreign body stimulation, serious and chronic peritonitis, autoimmune disease, intake of the β -blocker practolol, bacteria proof filter use, liver transplantation, tuberculous inflammation, ventriculoperitoneal and

Table II. Imaging in patients with abdominal cocoon.

Imaging technique and finding	Number of cases	Ratio (%)
X-ray		
Dilatation of small intestine	6	66.67
Intestinal air-fluid levels	6	66.67
Cauliflower sign	7	77.78
CT		
Soft tissue wraps around the small intestine	6	66.67
Small-bowel loops encased by the sac	2	22.22
Part of colons encased by the sac	1	11.11
Peritoneal thickening	7	77.78
Bottle Gourd sign	6	66.67
Bowel wall thickening	2	22.22
Mesenteric hydrops	2	22.22

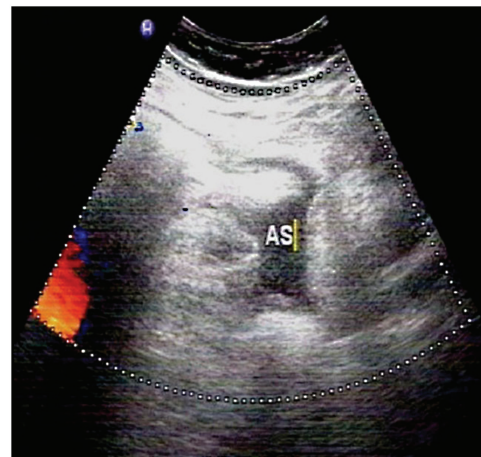


Figure 2. AS shows a large mass within the echogenic bowel and a small number of hypoechoic ascites. AS, abdominal sonogram.

peritoneovenous shunts and carcinoid syndrome (10,12-17). All these factors can lead to peritonitis, leading to a decrease in mesothelial cells, a sustained expression of mesothelial metastatic growth factor and the production of a large number of extracellular matrix products, which increase the exudation of protein fiber and peritoneal fibroblasts hyperplasia, and lead to the formation of the fibrous sac (18). Peritoneal dialysis-related AC may be due to the dialysis solution and its metabolites damaging the peritoneum, which can lead to the subcutaneous area of the peritoneal mesothelium thickening and expanding (19). Repeated infections can cause peritoneal damage, which can impair the normal physiological function of the peritoneum, and undergoes three stages of turbidity, deformation and fibrosis (3). In the current study, the nine included cases did not exhibit peritonitis, peritoneal dialysis or prolonged drug intake. The patients had a wide range of age distribution and majority were male. Therefore, it was considered that these patients had experienced abnormal congenital development, which supports the congenital etiology of AC.

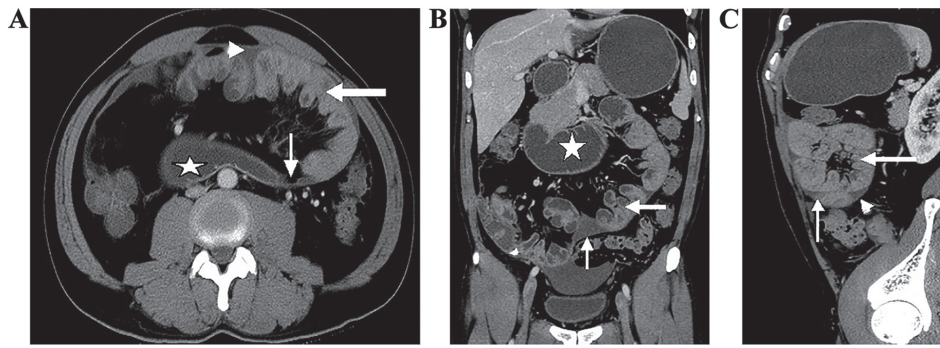


Figure 3. CT findings of abdominal cocoon disease. CT of the (A) abdomen axial, (B) coronal reformatted and (C) sagittal reformatted show the small bowel contained within a sac. The thickened enhancing membrane (short and thin arrows) covering congregated small bowel loops (thick white arrows) are visible and ascites (white triangle) around loops and the dilated loop of duodenum with fluid (stars) are also visible due to intestinal obstruction. The second and third part of the duodenum mimic the Bottle Gourd appearance (stars).

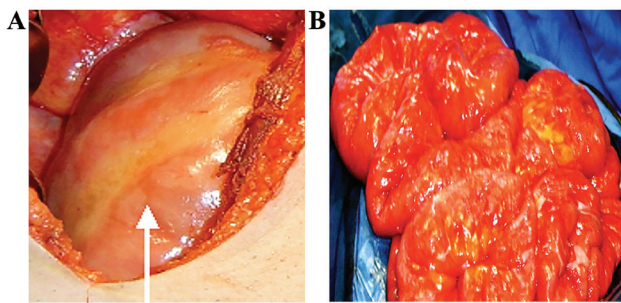


Figure 4. (A) Intraoperative photograph shows all the small bowels were enclosed by a whitish cocoon-like fibrotic sac (arrow). (B) After excision of the cocoon-like fibrotic sac, the adhesions were dissected, freeing the encapsulating small bowel.

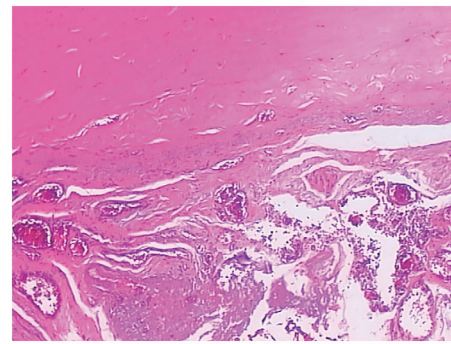


Figure 5. Histology of the membrane revealed proliferation of fibroconnective tissue with hyaline degeneration and infiltration of a small number of inflammatory cells. Representative image from one of the nine patients. Hematoxylin and eosin staining; original magnification, x100.

The clinical presentation of AC syndrome mostly occurs as acute abdominal pain. The incidence of acute abdominal pain in the current study was 100%. The main clinical manifestations included signs of bowel function and peritoneum physiological function disorder, and the fibrous sac also lead to bowel function disorder, decreased reabsorption and weakened enterokinesia, which caused nausea, vomiting, abdominal distension, the disappearance of bowel tone, abdominal pain, abdomen or pelvic masses, intestine obstruction, weight loss and blunt abdominal wall trauma-induced intra-cocoon bleeding (2,3,10,20). Peritoneal fibrosis lead to ascites by blocking the lymphatic vessels, which is a nonspecific symptom (21). The most common manifestation of the disease is small bowel obstruction, which is characterized by complete or partial obstruction (16,17,22) and this was observed in approximately two-thirds of the cases in the current study. Signs of bowel function disorder were not only related to the encapsulated intestine but also the damaged vessels, vas lymphatica and nerve plexus of the bowel wall muscular layer. AC may lead to infertility in female patients as the fibrous membrane encapsulates the fallopian tubes, which restricts its movement, blocks the fimbriated extremities and makes it difficult for the ovum to travel the fallopian tubes, however the uterus and ovaries appear normal (20).

Clinical diagnosis of AC is undertaken based on signs of bowel function and peritoneum physiological function disorder (10-12). The signs of AC are nonspecific, so it is

difficult to make a definite preoperative diagnosis (2,20,23). The majority of cases are diagnosed during a laparotomy (20) Patients presenting with recurrent episodes of abdominal pain, abdominal distension, unexplained chronic mechanical intestinal obstruction and soft abdominal mass may have AC. Weakened peritoneal transport function, anemia and c-reactive protein levels can act as a clinical reference, but have no specific value. An elevated WBC count and C-reactive protein level, hypoalbuminemia and anemia may be detected in patients with AC (16).

The majority of studies assessing the imaging of AC are case reports (2,7,14,16,21,24-27). Plain abdominal X-ray has been demonstrated to exhibit no diagnostic specificity, and only indicated dilated small-bowel loops with air-fluid levels and peritoneal calcification in previous studies (10,28). In the current study, a total of six cases (66.67%) exhibited small intestinal air-fluid levels and there were no cases of peritoneal calcification. Barium meal examination revealed the cauliflower sign, and seven cases (77.78%) exhibited this characteristic in the current study. Sonographic examination revealed cystic echoes in the bowel sac with occasional identification of the sac wall and sac effusion. Reports about MRI findings of AC are rare, therefore it is unknown if MRIs have any value in the diagnosis of AC until more cases are accumulated in the future. CT scans can indicate a distinctive manifestation of AC, which is of important value for

diagnosis (3). With CT findings, a definite preoperative diagnosis is more likely. These manifestations include: i) The small-bowel loops amassing in a certain area of the abdomen and the intestine is rarely seen in other areas of the peritoneal cavity; ii) the clustered bowel loops are surrounded by a sac-like structure in a typical cocoon pattern; iii) the wall of the sac is complete or incomplete, and well- or poorly distributed. iv) Intestine loops in the sac may adhere to each other and the wall causing it to thicken; v) small amounts of encapsulated effusion in the sac are visible; vi) corresponding mesenteric vessels are centralized with abnormal running and distribution, mesenteric fat gains density and the greater omentum is hypoplastic or absent; vii) cocoon-like membrane and the wall of the intestine occasionally show calcification; viii) lymph nodes swell reactively; ix) CT findings of AC with the complication of intestinal obstruction; x) intestine loops encased by the sac and secondary adhesion being the main cause of the obstruction. In the current study, a total of six patients (66.67%) showed proximal intestinal dilatation, normal or poor intestinal dilatation and the distal intestine was normal or empty. Bowel ischemia is a manifestation of a strangulated intestinal obstruction. And the Bottle Gourd sign, cauliflower sign are important radiological findings and they were identified in approximately two-thirds of cases.

Enhanced CT is an effective way to observe bowel mesenteric ischemia and necrosis, and has high sensitivity and accuracy (3). CT findings of bowel ischemia include: i) Bowel wall annular thickening; ii) abnormal enhancement of the bowel wall; iii) bowel wall bleeding; and iv) mesenteric effusion, mesenteric vessels thickening and fuzziness. In the current study, characteristic CT appearances of AC include clustered bowel loops encased by a thickened sac that are accompanied by the accumulation of mesenteric vessels, abnormal distribution and the hypoplasia or absent omentum majus. Stafford-Johnson *et al* (9) indicated that calcification of the intestinal fenum and peritoneum were more characteristic of AC, but none of the cases in the current study showed peritoneum calcification. In the past, AC could only be definitively diagnosed after surgery. However, combined with clinical and imaging reports, the current study performed preoperative diagnosis using CT scans, which allow for a reliable diagnostic method. Using this method increases the understanding of the disease and serves an important role in assisting surgical treatments (4,10,25).

The common characteristics of peritoneal morphological changes are mesothelium loss and interstitium thickening within the peritoneum (20). A thickened interstitium may be cellulous (possibly fibroblasts) or acellular (collagen deposition). Collagen fibers, inflammatory cells and abnormal morphological vessels have also been previously observed, with focal mesothelial cells, lymphocytes and reactive hyperplasia lymph nodes with or without plasmacytes (29,30).

AC should be identified due to peritoneal encapsulation (3), which is a rare type of abnormal congenital development. Cleland (31) first reported, in 1868, that the peritoneal membrane is divided from the yolk sac as it is drawn into the embryonic abdominal cavity during the twelfth week of pregnancy, and malrotation of the midgut and a vascular anomaly may result in AC. The majority of patients with AC are asymptomatic, and a few cases exhibit show intermittent

abdominal pain, with acute intestinal obstruction occurring in a number of infant patients. Peritoneal encapsulation characteristically presents with part or all of the small bowel being enveloped in an accessory peritoneal sac, the wall of which is formed by the omentum and mesocolon. CT imaging of the small intestine enveloped in the peritoneum and existing omentum are diagnostic. Histologically, the sac of PE is the crystalloid peritoneum, which is normal, has no fibrosis and no adhesion with the intestine. However, AC often presents with omental dysplasia or absence, and the sac is formed of thickened collagen and fibrous tissue, which may be accompanied by nonspecific chronic inflammation (26,32,33). In addition, AC also needs to be identified with tuberculosis, peritoneal mesothelioma and peritoneal pseudomyxoma (27,32,33).

The present study demonstrated that clinical symptoms might manifest iteratively for patients who accept conservative treatments. Therefore, the contention is that surgical intervention is an effective treatment (2,20,28,34), especially for those with intestinal obstruction or an abdominal mass. Laparoscopy is a useful tool for a definitive diagnosis and treatment protocol for AC (20). The therapeutic principle of AC is lysis of adhesions and removal of the membrane (2,25). In the current study, the treatment was effective by excising the thickened cocoon-like membrane, thereby freeing intestinal adhesions and enveloping bowl loops, as well as relieving intestinal obstruction and removing the necrotic intestine. During surgery, the adhesion between the sac and the surrounding structure, between the sac and the intestine and between the intestinal tube and the intracapsular intestine was easier to remove, but extensive separation should be avoided so as not to completely excise the fibrous membrane (20). This may result in intestinal serosal injury due to intestinal rupture or postoperative adhesion obstruction (7). For the cases secondary to chronic bacterial or chemical peritonitis, the condensing fibrous adhesion throughout the intestine makes separation difficult (35), which requires avoidance of intestinal vessel damage to lessen ischemia or necrosis of the intestine. For those patients, whose condition involves wide-ranging bowel or serious adhesions that cannot be separated, rearrangement of the intestinal position is necessary to prevent postoperative adhesion and obstruction (36). However, a number of authors hypothesize that intestinal arrangement will greatly increase the difficulty of the operation for patients with postoperative adhesion (10). The method used to manage the appendix has been debated and where additional appendectomy is necessary is determined depending on the appendiceal position, in relation to the sac and whether inflammation may emerge (20,28).

As the current study was retrospective study, there may have been unavoidable selection bias. Additionally, the sample size was small. Further expansion of the sample size is required in future studies.

In summary, preoperative CT examination serves an important role in making a definitive diagnosis, understanding the sac and complications that can occur, and selecting the most suitable treatments for AC. CT scans can help to avoid excising the peritoneum, which can lead to the intestine being accidentally cut, or resecting a mass of encapsulated small bowel believing it is a tumor, which will lead to short-intestine syndrome (24). To prevent the postoperative adhesion and the sac reformation, the peritoneal cavity can be intraoperatively

filled with anti-adhesion agents (2,37), including sodium hyaluronate or medium molecular dextran. Postoperatively, drugs, including neostigmine, which promotes enterokinesia and recovery of bowel function, or hydrocortisone, which inhibits the generation of cellulose, may be useful. For recurrent bowel obstruction, surgical complications are the major cause of mortality, followed by intestinal leakage or short-intestine syndrome (38). For recurrent bowel obstruction, the majority of cases can be cured by conservative treatment as reoperation is difficult and complications are more likely to occur.

Acknowledgements

Not applicable.

Funding

No funding was received.

Availability of data and materials

The datasets used or analyzed during the current study are available from the corresponding author on reasonable request.

Authors' contributions

RY designed the study, performed the research, analyzed the data and wrote the article. YY performed the research and analyzed the data. XN designed the study. GF made significant contributions to data acquisition, data analysis and interpretation, and made critical and important revisions to the manuscript. GF reviewed and approved the manuscript for publication. All authors read and approved the final manuscript.

Ethics approval and consent to participate

Written informed consent was obtained from all study participants and ethical approval for this study was obtained from the local research ethics committee of The Second Affiliated Hospital of Soochow University.

Patient consent for publication

Not applicable.

Competing interests

The authors declare that they have no competing interests.

References

- Solmaz A, Tokoçin M, Arıcı S, Yiğitbaş H, Yavuz E, Gülçiçek OB, Erçetin C and Çelebi F: Abdominal cocoon syndrome is a rare cause of mechanical intestinal obstructions: A report of two cases. *Am J Case Rep* 16: 77-80, 2015.
- Xia J, Xie W, Chen L and Liu D: Abdominal cocoon with early postoperative small bowel obstruction: A case report and review of literature in China. *Medicine (Baltimore)* 97: e11102, 2018.
- Singhal M, Krishna S, Lal A, Narayanasamy S, Bal A, Yadav TD, Kochhar R, Sinha SK, Khandelwal N and Sheikh AM: Encapsulating peritoneal sclerosis: The abdominal cocoon. *Radiographics* 39: 62-77, 2019.
- Gorsi U, Gupta P, Mandavdhare HS, Singh H, Dutta U and Sharma V: The use of computed tomography in the diagnosis of abdominal cocoon. *Clin Imaging* 50: 171-174, 2018.
- Owtschinnikow P.J. Peritonitis chronica fibrosa incapsulata. *Arch für Klinische Chirurgie*, 83, pp623-634, 1907.
- Foo KT, Ng KC, Rauff A, Foong WC and Sinniah R: Unusual small intestinal obstruction in adolescent girls: The abdominal cocoon. *Br J Surg* 65: 427-430, 1978.
- Yeniay L, Karaca CA, Calışkan C, Fırat O, Ersin SM and Akgün E: Abdominal cocoon syndrome as a rare cause of mechanical bowel obstruction: Report of two cases. *Ulus Travma Acil Cerrahi Derg* 17: 557-560, 2011.
- Tarzi RM, Lim A, Moser S, Ahmad S, George A, Balasubramaniam G, Clutterbuck EJ, Gedroyc W and Brown EA: Assessing the validity of an abdominal CT scoring system in the diagnosis of encapsulating peritoneal sclerosis. *Clin J Am Soc Nephrol* 3: 1702-1710, 2008.
- Stafford-Johnson DB, Wilson TE, Francis IR and Swartz R: CT appearance of sclerosing peritonitis in patients on chronic ambulatory peritoneal dialysis. *J Comput Assist Tomogr* 22: 295-299, 1998.
- Danford CJ, Lin SC, Smith MP and Wolf JL: Encapsulating peritoneal sclerosis. *World J Gastroenterol* 24: 3101-3111, 2018.
- Fei X, Yang HR, Yu PF, Sheng HB and Gu GL: Idiopathic abdominal cocoon syndrome with unilateral abdominal cryptorchidism and greater omentum hypoplasia in a young case of small bowel obstruction. *World J Gastroenterol* 22: 4958-4962, 2016.
- Sharma V, Mandavdhare HS, Rana SS, Singh H, Kumar A and Gupta R: Role of conservative management in tubercular abdominal cocoon: A case series. *Infection* 45: 601-606, 2017.
- Brown EA, Bargman J, van Biesen W, Chang MY, Finkelstein FO, Hurst H, Johnson DW, Kawanishi H, Lambie M, de Moraes TP, *et al*: Length of time on peritoneal dialysis and encapsulating peritoneal sclerosis-position paper for ISPD: 2017 update. *Perit Dial Int* 37: 362-374, 2017.
- Takebayashi K, Sonoda H, Shimizu T, Ohta H, Ishida M, Mekata E, Endo Y, Tani T and Tani M: Successful surgical approach for a patient with encapsulating peritoneal sclerosis after hyperthermic intraperitoneal chemotherapy: A case report and literature review. *BMC Surg* 14: 57, 2014.
- Kaur S, Doley RP, Chabbhra M, Kapoor R and Wig J: Post trauma abdominal cocoon. *Int J Surg Case Rep* 7C: 64-65, 2015.
- Lee KW, Cho CW, Lee N, Lee S, Kim JM, Choi GS, Kwon CH, Joh JW and Lee SK: Encapsulating peritoneal sclerosis in liver transplant recipients: A report of 2 cases. *Ann Surg Treat Res* 92: 164-167, 2017.
- Salamone G, Atzeni J, Agrusa A and Gulotta G: A rare case of abdominal cocoon. *Ann Ital Chir* 84, 2013.
- Koak Y, Gertner D, Forbes A and Ribeiro BF: Idiopathic sclerosing peritonitis. *Eur J Gastroenterol Hepatol* 20: 148-150, 2008.
- Izumotani T, Ishimura E, Yamamoto T, Otoshi T, Okuno S, Inaba M, Kim M and Nishizawa Y: Correlation between peritoneal mesothelial cell cytology and peritoneal histopathology with respect to prognosis in patients on continuous ambulatory peritoneal dialysis. *Nephron* 89: 43-49, 2001.
- Li S, Wang JJ, Hu WX, Zhang MC, Liu XY, Li Y, Cai GF, Liu SL and Yao XQ: Diagnosis and treatment of 26 cases of abdominal cocoon. *World J Surg* 41: 1287-1294, 2017.
- Gurleyik G, Emir S and Saglam A: The abdominal cocoon: A rare cause of intestinal obstruction. *Acta Chir Belg* 110: 396-398, 2010.
- Ceulemans LJ, Deferm NP, Deferm S, Willaert RAV, Deferm JT and Vanhoenacker FM: Unusual cause of mechanical ileus: Abdominal cocoon syndrome. *J Belg Soc Radiol* 100: 36, 2016.
- Cheng Y, Qu L, Li J, Wang B, Geng J and Xing D: Abdominal cocoon accompanied by multiple peritoneal loose body. *Medicine (Baltimore)* 96: e6185, 2017.
- Lim MC, Chotai NC and Giron DM: Idiopathic sclerosing encapsulating peritonitis: A rare cause of subacute intestinal obstruction. *Case Rep Med* 2016: 8206894, 2016.
- Aliyev V, Yagi S, Hammad A, Badawy A, Sasaki Y, Masano Y, Yamamoto G, Kamo N, Taura K, Okajima H, *et al*: Sclerosing encapsulating peritonitis after living-donor liver transplantation: A case series, Kyoto experience. *Ann Hepatobiliary Pancreat Surg* 22: 144-149, 2018.
- Mbanje C, Mazingi D, Forrester J and Mungazi SG: Peritoneal encapsulation syndrome: A case report and literature review. *Int J Surg Case Rep* 41: 520-523, 2017.

27. Tombak MC, Apaydin FD, Colak T, Duce MN, Balci Y, Yazici M and Kara E: An unusual cause of intestinal obstruction: Abdominal cocoon. *AJR Am J Roentgenol* 194: W176-W178, 2010.
28. Allam H, Al Yahri O, Mathew S, Darweesh A, Suliman AN, Abdelazim S, Khairat M, Toro A and Di Carlo I: The enigma of primary and secondary encapsulating peritoneal sclerosis. *BMC Surg* 16: 81, 2016.
29. Braun N, Alscher DM, Fritz P, Edenhofer I, Kimmel M, Gaspert A, Reimold F, Bode-Lesniewska B, Ziegler U, Biegger D, *et al*: Podoplanin-positive cells are a hallmark of encapsulating peritoneal sclerosis. *Nephrol Dial Transplant* 26: 1033-1041, 2011.
30. Lopez-Anton M, Lambie M, Lopez-Cabrera M, Schmitt CP, Ruiz-Carpio V, Bartosova M, Schaefer B, Davies S, Stone T, Jenkins R, *et al*: miR-21 promotes fibrogenesis in peritoneal dialysis. *Am J Pathol* 187: 1537-1550, 2017.
31. Cleland: On an abnormal arrangement of the peritoneum, with remarks on the development of the mesocolon. *J Anat Physiol* 2: 201-206, 1868.
32. Jagdale A, Prasla S and Mittal S: Abdominal cocoon-A rare etiology of intestinal obstruction. *J Family Med Prim Care* 6: 674-676, 2017.
33. Acar T, Kokulu İ, Acar N, Tavusbay C and Hacıyanlı M: Idiopathic encapsulating sclerosing peritonitis. *Ulus Cerrahi Derg* 31: 241-243, 2015.
34. Li Y, Li N, Zhu WM, Gong JF, Zhang W, Gu LL, Zuo LG and Li JS: Surgical treatment for idiopathic abdominal cocoon. *Zhonghua wai ke za zhi* 51: 139-141, 2013 (In Chinese).
35. Basu A, Sukumar R, Sistla SC and Jagdish S: 'Idiopathic' abdominal cocoon. *Surgery* 141: 277-278, 2007.
36. Rajagopal AS and Rajagopal R: Conundrum of the cocoon: Report of a case and review of the literature. *Dis Colon Rectum* 46: 1141-1143, 2003.
37. Jaber S, Dulaijan K, Sadoun M, Moghazy K and El-Said M: Post-traumatic intra-cocoon mesenteric tear: A case report. *Case Rep Gastroenterol* 5: 206-211, 2011.
38. Kawaguchi Y, Kawanishi H, Mujais S, Topley N and Oreopoulos DG: Encapsulating peritoneal sclerosis: Definition, etiology, diagnosis, and treatment. International Society for Peritoneal Dialysis Ad Hoc Committee on Ultrafiltration Management in Peritoneal Dialysis. *Perit Dial Int* 20 (Suppl 4): S43-S55, 2000.



This work is licensed under a Creative Commons Attribution-NonCommercial-NoDerivatives 4.0 International (CC BY-NC-ND 4.0) License.