

# Drug-Induced Sleep Endoscopy and Its Recent Clinical Applications in Combination with Other Procedures in Children: A Narrative Review

Zhixian Xiao<sup>1,\*</sup>, Xing Li<sup>2,\*</sup>, Li Zhou<sup>3,\*</sup>, Xiaocui Long<sup>4</sup>, Li Tian<sup>3</sup>, Weiqi Li<sup>2</sup>

<sup>1</sup>Department of Otorhinolaryngology-Head and Neck Surgery, Affiliated Meishan Hospital of Chengdu University of TCM, Meishan, People's Republic of China; <sup>2</sup>Department of Otorhinolaryngology-Head and Neck Surgery, Traditional Chinese Medicine Hospital of Meishan, Meishan, People's Republic of China; <sup>3</sup>Department of Otorhinolaryngology, Hospital of Chengdu University of Traditional Chinese Medicine, Chengdu, People's Republic of China; <sup>4</sup>Department of Ophthalmology, Traditional Chinese Medicine Hospital of Meishan, Meishan, People's Republic of China

\*These authors contributed equally to this work

Correspondence: Weiqi Li, Department of Otorhinolaryngology-Head and Neck Surgery, Traditional Chinese Medicine Hospital of Meishan, No. 9, North Section of Mindong Avenue, Dongpo District, Meishan, 620010, Sichuan, People's Republic of China, Tel +8615983311840, Email 35285171@qq.com; Li Tian, Department of Otorhinolaryngology, Hospital of Chengdu University of Traditional Chinese Medicine, No. 39~41, 12 Qiao Road, Jinniu District, Chengdu, 610075, People's Republic of China, Tel +8618980880129, Email 18980880129@qq.com

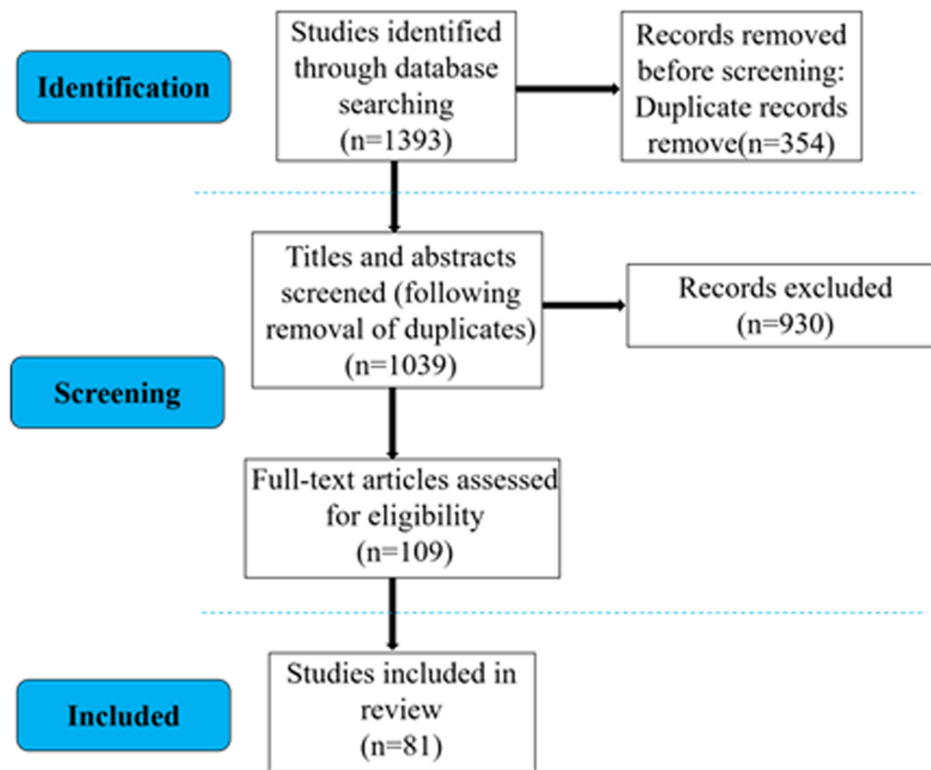
**Abstract:** Drug-induced sleep endoscopy (DISE) is a dynamic diagnostic tool that is increasingly used to evaluate upper airway obstruction, especially in pediatric obstructive sleep apnea. Although initially established in adult populations, its pediatric application is expanding. Since 1990, more than 80 studies have explored various aspects of DISE, with a growing subset focusing specifically on its use in children, supported by advancements in sedation protocols. This narrative review summarizes the clinical indications for pediatric DISE, preparation protocols, and validated scoring systems, including the VOTE and Chan classifications. We also highlight the integration of DISE with adjunctive tools such as positive airway pressure titration, long-range optical coherence tomography, and dynamic magnetic resonance imaging for improved diagnostic accuracy and individualized treatment planning. These developments suggest that DISE, when standardized, holds strong potential to refine the management of complex pediatric airway disorders.

**Keywords:** children, drug-induced sleep endoscopy, obstructive sleep apnea, combination strategy

## Introduction

Drug-induced sleep endoscopy (DISE) is an examination procedure involving insertion of an endoscope to evaluate the anatomical structure of the airway while patients are in a sleep state induced by appropriate medications.<sup>1</sup> Croft et al proposed for the first time in 1989 that DISE could be used for dynamic assessment of upper airway obstruction in patients with obstructive sleep apnea-hypopnea syndrome and then in 1990 suggested the application of DISE in pediatric patients.<sup>2</sup> Since then, DISE has been gradually accepted for adults in clinical practice worldwide. However, its application in the pediatric population has remained limited. Children exhibit different characteristics from adults in terms of pathology, physiology, growth, and development. Thus, in pediatric cases, DISE examinations should be tailored toward the special requirements of children. Similar to adult patients, pediatric patients undergo DISE examinations for evaluation of potential upper airway obstruction while asleep. DISE is primarily indicated for children with upper respiratory symptoms, such as snoring and breath holding during sleep.<sup>3</sup>

For comprehensive evaluation of the different sites and severities of upper airway obstruction, a scoring system is required to accurately record the examination results. Many scoring systems have been developed, and each has unique advantages. Some have been designed to evaluate the physiological characteristics of the airway of children specifically, with the goal of providing detailed and accurate assessments of potential obstructions.<sup>4</sup> As DISE examination becomes increasingly standardized and well-accepted in clinical practice, efforts also have been made toward the systematic development of a consensus on the anesthetic regimen, procedural steps, and scoring criteria for DISE. Additionally, the combination of DISE with other procedures has been explored in the clinic.<sup>5</sup> Here, we review the current literature and



**Figure 1** Flowchart of the search and selection strategy for studies included in this narrative review.

summarize the clinical application of DISE in the diagnosis and treatment of children, in order to improve the management of upper airway illness in this special population.

## Methodology

This narrative review followed a structured search strategy to ensure transparency and minimize selection bias. We conducted a literature search across three electronic databases: PubMed, Web of Science, and China National Knowledge Infrastructure (CNKI). The search period ranged from January 1990 to June 2024, aligning with the timeline since the first introduction of DISE in clinical practice. The search strategy used combinations of Medical Subject Headings (MeSH) and free-text terms, including: (“children” OR “pediatric”) AND (“obstructive sleep apnea” OR “obstructive sleep apnea hypopnea syndrome” OR “sleep disordered breathing” OR “snoring”) AND (“drug-induced sleep endoscopy” OR “DISE” OR “sleep endoscopy” OR “dynamic upper airway evaluation”). Boolean operators (AND, OR) were used to structure the query. The inclusion criteria for studies were: (1) human studies involving pediatric patients; (2) original research or reviews directly addressing DISE-related techniques, indications, outcomes, or scoring systems; and (3) articles published in peer-reviewed journals. The following study types were excluded: (1) conference abstracts, editorials, and commentaries; (2) studies focusing solely on adult populations; and (3) animal studies. After screening titles and abstracts, eligible full-text articles were reviewed by two independent researchers (ZXX and XCL). Discrepancies were resolved through discussion with a third reviewer. Ultimately, 81 studies were included. [Figure 1](#) illustrates the study selection process.

## Clinical Indications

### Uncertain Site of Upper Airway Obstruction

Tonsillectomy and adenoidectomy are the first-line treatments and standard procedures for obstructive sleep apnea (OSA) in children. Symptom improvement after these procedures occurs in approximately 70% of children but varies

significantly among different reports.<sup>6</sup> Many children experience no symptom relief, or even more severe airway obstruction, after tonsillectomy and adenoidectomy.<sup>7</sup> OSA is a major indication for DISE examination, and OSA patients represent the largest candidate population for DISE. DISE is applied to determine the site of persistent obstruction after tonsillectomy and adenoidectomy, which facilitates further management approaches. Polysomnography is the gold standard for the diagnosis of pediatric OSA.<sup>8</sup> However, awake endoscopy often fails to reveal obvious obstruction in children with a high obstructive apnea–hypopnea index and low oxygen saturation as measured by polysomnography to indicate severe airway obstruction.<sup>9</sup> In addition, some children cannot tolerate the polysomnography examination, and in such cases, the results may not match the actual situation. DISE examination is recommended to further clarify the site of the obstruction.<sup>10</sup> These conditions are more common in cases with multiple sites of obstruction other than the tonsils, such as soft palate relaxation, epiglottal collapse, tongue hypertrophy from lymphatic tissue swelling at the tongue base, and laryngomalacia.<sup>3,11,12</sup> Other less common conditions include non-organic obstruction of the glottis, such as paradoxical vocal cord movement,<sup>13</sup> or even unexplained vocal cord dysfunction during sleep.<sup>14,15</sup>

## Preoperative Evaluation of Fibrous Chronic Tonsillitis

In clinical practice, children for whom tonsillectomy and adenoidectomy are planned often have fibrous chronic tonsillitis, also known as small tonsils.<sup>16,17</sup> Due to the concern that compensatory tonsil hyperplasia can block the airway after simple adenoidectomy, clinical decision-making and communications with the child's guardian can be complicated. In this situation, a pre-operative DISE examination can be performed on the day of the operation to assess the oropharyngeal structure and more accurately determine the requirement for tonsillectomy. The findings of the DISE examination can be shared with the child's guardian in planning the next treatment step, and during this process, the child does not need to be awakened. After discussion with the guardian, the anesthesia regimen would then be adjusted and ventilator support provided for the next procedural step.

## Preoperative Evaluation in High-Risk Pediatric Cases

Children at high risk for OSA include those with obesity, older age (>7 years), black race, severe preoperative OSA, Down syndrome, neuromuscular disease, and craniofacial abnormalities.<sup>18–21</sup> Children with the above characteristics can have a high risk for persistent postoperative residue sleep apnea. Therefore, DISE examination can be recommended to determine the optimal treatment method when the obstruction site is unclear.

## DISE Examination Preparation

### Endoscopy

DISE examination requires the preparation of necessary examination equipment, anesthetics, and monitoring devices. The examination steps are similar to those of painless gastroendoscopy, which requires a flexible laryngoscope, including a fiberoptic laryngoscope or an electronic endoscope. A small-sized scope (preferably between 2.5–3.5 mm) is selected due to the small body size of children.<sup>22</sup> This can avoid damaging the upper airway mucosa and reduce the possibility of sleep interruption caused by examination stimulation. Use of a small-sized scope can also minimize distortion of the airway structure to avoid measurement errors in the examination results.

DISE examination requires a high-definition recording system to determine the obstruction site during the real-time examination. If questions or diagnostic disagreements arise, further in-depth analysis can be performed by reviewing the recorded videos.

## Selection of Anesthetic and Sedative Medications

During the DISE examination, optimal anesthesia will maintain spontaneous breathing, simulate normal airway tone during sleep, be reproducible, and allow a short examination duration, without causing excessive airway secretions.<sup>23</sup> Currently, the anesthetics are mainly given through an inhalation or intravenous route, with a distinction between single-agent and combination therapy (Tables 1 and 2). Although sevoflurane is first choice of inhalation anesthetic in general, it

**Table 1** Overview of Anesthetic Strategies for DISE

Route	Drug	Dosage	Mechanism of Action	Advantages	Disadvantages	Specific Indications
Inhalational	Sevoflurane	1–2% for induction	Inhibits NMDA receptors and enhances GABA <sub>A</sub> receptor activity, inducing anesthesia	Rapid induction, easy control	Relaxes airway smooth muscle, affects accuracy	PInduction only
Intravenous	Dexmedetomidine	1 µg/kg bolus, then 1 µg/kg/h infusion	Selective α <sub>2</sub> -adrenergic receptor agonist that mimics non-rapid eye movement (NREM) sleep	Preserves airway tone, no respiratory depression	Slow onset, infusion rate sensitive	Preferred for preserving spontaneous breathing
Intravenous	Propofol	1 mg/kg bolus, then 20–30 mg q3–5min	Enhances GABA <sub>A</sub> receptor activity, leading to sedation	Rapid onset, stable sedation effect	May cause respiratory depression and hypotension; high risk when used alone	Used with Dex for maintenance
Intravenous	Ketamine	1 mg/kg IV bolus	Non-competitive NMDA receptor antagonist providing sedation and analgesia without significant respiratory depression	Maintains blood pressure and oxygen saturation	May increase upper airway muscle tone, altering obstructive sleep apnea (OSA) patterns	For unstable hemodynamics
Intravenous	Midazolam	0.05–0.1 mg/kg	Binds to GABA <sub>A</sub> receptors, enhancing inhibitory neurotransmission	Effective sedation	Significantly reduces muscle tone, affecting upper airway dynamics; contraindicated in pediatric patients	Rarely used in children
Intravenous	Esketamine	0.5–1 mg/kg	A derivative of ketamine with a shorter onset time and fewer side effects	Rapid induction, fewer adverse effects	Lacks large-scale clinical data support	Emerging use in pediatric DISE

**Table 2** Overview of Combined Anesthetic Strategies for DISE

Combination Strategy	Drug Composition	Mechanism of Action	Advantages	Disadvantages	Recommended Use
Dexmedetomidine + Propofol	Dexmedetomidine (α <sub>2</sub> -adrenergic agonist) + Propofol (GABA <sub>A</sub> receptor agonist)	Mimics sleep + rapid sedation	Good sedation control, preserves breathing	May cause hypotension, needs titration	Standard combination for DISE
Dexmedetomidine + Ketamine	Dexmedetomidine (α <sub>2</sub> -adrenergic agonist) + Ketamine (NMDA receptor antagonist)	Sleep mimic + stable hemodynamics	Maintains BP/O <sub>2</sub> , reduces respiratory depression	May affect airway tone, individual adjustment needed	For hemodynamically unstable children
Esketamine + Dexmedetomidine	Esketamine (short-acting NMDA receptor antagonist) + Dexmedetomidine (α <sub>2</sub> -adrenergic agonist)	Rapid sedation + low respiratory depression	Fast onset, fewer side effects	Lacks large-scale validation	Emerging, more data needed

can relax airway smooth muscles, which may cause errors in DISE measurements. Thus, it is rarely used for DISE examinations.

Multiple clinical trials and expert consensus have determined that dexmedetomidine and propofol are the most appropriate sedatives for DISE.<sup>24–27</sup> Dexmedetomidine is a selective α<sub>2</sub>-adrenergic agonist that can simulate non-rapid

eye movement sleep without causing respiratory depression and minimal interference in the upper airway tension or cross-sectional area. Dexmedetomidine should be prepared into a 4 µg/mL solution and first given in a bolus dose via intravenous injection at a volume of 1 µg/kg, followed by continuous intravenous infusion through a pump at 1 µg/kg/hr, which is started 10 min after the bolus injection and continued until the end of the DISE examination.<sup>25</sup> Propofol achieves sedation by interacting with γ-aminobutyric acid receptors. It can be initiated at 1 mg/kg and maintained by administering 20–30 mg intravenous injections every 3–5 min.<sup>25</sup> However, propofol can suppress the respiratory system and cause temporary respiration arrest. In addition, propofol has a negative inotropic effect, resulting in hypotension. Therefore, propofol is commonly used together with dexmedetomidine, rather than alone, during DISE examination.

Ketamine is another common medication that provides sedation without suppressing the respiratory system. However, ketamine may increase the upper airway muscle tone and distort the obstructive breathing pattern during sleep. Still, several studies have reported that blood pressure and oxygen saturation can be maintained, with minimal impact on the upper airway muscle tone and structures during sleep, with the combination of ketamine and dexmedetomidine, leading to a high success rate of DISE examination. When used in combination with dexmedetomidine, ketamine is administered intravenously at a dose of 1 mg/kg for general anesthesia induction.<sup>28</sup>

The benzodiazepine sedative midazolam was most commonly used in the early application of DISE.<sup>29</sup> However, due to its significant effect on muscle tone reduction and the clearly stated contraindication in children, midazolam is now rarely used in pediatric DISE examinations.

A recent study compared the efficacy of ketamine and dexmedetomidine in DISE examination in children and showed shorter onset time, deeper sedation, and fewer adverse reactions, suggesting this combination provides an effective and safe approach to providing anesthesia.<sup>30</sup> More large-sample clinical trials are required to further compare different analgesic and sedative regimens.

## Monitoring During Anesthesia and Sedation

To date, some researchers have used the bispectral index (BIS) and polysomnography to guide the sedation level during DISE examination.<sup>25,31</sup> BIS values in the ranges of 85–100, 65–84, and 40–64 are generally believed to be appropriate for normal, sedated, and anesthetized statuses, respectively. During DISE examination, a sedation or deeper status is typically required. However, due to great variation in the BIS in children, there is currently no established clinical or experimental evidence regarding the ideal values for BIS monitoring in children.<sup>32</sup> Electroencephalogram monitoring of polysomnography can identify sleep stages and respiratory events. Respiratory obstruction most commonly occurs during rapid eye movement sleep. In addition, the Michigan Sedation Scale,<sup>33</sup> as an alternative to the BIS and polysomnography, can be applied to assess the sedation depth. Its clinical suitability and consistency have been validated in both adult and pediatric patients.

## Patient Preparation

DISE examinations in children are usually performed in an operating room with a comfortable room temperature, dim lighting, and minimal noise disturbances.<sup>34</sup> If an outpatient clinic has an isolated space that meets the examination requirements, it can also be equipped with necessary monitoring equipment for DISE performance. However, the operating room is still the preferred examination location, because serious complications can occur, such as hypoxia, laryngospasm, drug allergy, and apnea. Pediatric patients are typically placed in the supine position without a pillow during DISE examinations. However, they can be moved to the lateral position if a suspected positional airway obstruction must be clarified by DISE.<sup>35</sup> In addition, the use of topical anesthetics or nasal mucosal decongestants should be avoided to preserve the structure of the upper airway as closely as possible to that in the natural sleeping state during the DISE examination.

## DISE Scoring Systems

The Velum, Oropharynx and lateral pharyngeal walls, Tongue base, and Epiglottis (VOTE) scoring system is widely used due to its simplicity and ease of use. However, it has certain limitations, such as the lack of assessments of the nasopharynx and supraglottic areas, which are two common obstruction locations in children.<sup>35</sup> To address this

**Table 3** Unified Comparative Summary of DISE Scoring Systems for Pediatric Patients

Scoring System	Pediatric-specific	No. of Sites	Obstruction Grading	Key Sites	Strengths	Limitations
VOTE	No	4	0–2 (none, partial, complete)	Velopharynx, Oropharynx, Tongue base, Epiglottis	Simple and widely used	Misses nasopharynx, supraglottis
Chan	Yes	5	0–3 (0–50%, 50–99%, complete)	Nasopharynx, Velopharynx, Oropharynx, Tongue base, Epiglottis	Tailored for pediatric anatomy	Moderate inter-rater reliability
Boudewyns	No	6	0–3 (fixed % collapse)	Nasopharynx, Velopharynx, Oropharynx, Tongue base, Supraglottis, Epiglottis	Moderate anatomical detail	Not pediatric-specific
Fishman	No	5	0–3 (mild to severe)	Turbinate, Nasopharynx, Oropharynx, Tongue base, Epiglottis	Easy to apply in clinical settings	Subjective scale, lacks detail
Bachar	No	6	+1 to +2 (severity)	Turbinate, Nasopharynx, Velopharynx, Oropharynx, Tongue base, Epiglottis	Includes severity scoring	No unified cutoff, less validated
SERS	No	6	0–2 + confidence rating	Turbinate, Nasopharynx, Velopharynx, Oropharynx, Supraglottis, Epiglottis	Confidence scoring included	Not developed for children
NAVOTEL	Yes	7	0–2	Nasopharynx, Velopharynx, Oropharynx, Tongue base, Supraglottis, Epiglottis, Larynx	Highly detailed, includes larynx	Complex, time-consuming
IPOG Consensus	Yes	7	0–2	Nasopharynx, Velopharynx, Oropharynx, Tongue base, Epiglottis, Arytenoid, Turbinate	Standardized expert consensus	Does not account for ethnic variability

**Abbreviations:** NAVOTEL, nose, adenoids, velum, oropharynx, tongue, epiglottis, larynx; SERS, sleep endoscopy rating scale; VOTE, velum, oropharynx and lateral pharyngeal walls, tongue base and epiglottis; x, selected; -, not selected.

limitation, the Chan scoring system was developed specifically for evaluating children during DISE.<sup>18</sup> It has been optimized and improved specifically for the pediatric population by incorporating the assessment of key locations, such as the adenoids and supraglottic structures. In addition, other scoring systems have been reported, such as the Boudewyns, Fishman, Sleep Endoscopy Rating Scale (SERS), and Bachar scoring systems (Table 3).<sup>4,36–38</sup> These systems offer diverse and detailed assessment approaches, considering many factors related to obstruction severity, assessment quality, and OSA, in addition to the specific site of upper airway obstruction.

To address the complexity and lack of consensus on DISE examination and scoring systems in children, the International Pediatric Otolaryngology Group recently reached an expert consensus and developed a DISE scoring system suitable for children to provide better international communication, establish evidence-based practice, and reduce research heterogeneity.<sup>39</sup> Although more obstruction sites are assessed, the scoring criteria are simple and easy to implement, allowing for widespread application. However, a limitation of this consensus is that it does not consider the upper airway anatomical differences among children of different ethnicities. More comprehensive evaluations and international cooperation are required to address this issue.

## Combined Clinical Application of DISE with Other Procedures (Table 4)

### DISE Combined with Positive Pressure Ventilation Treatment

Positive pressure ventilation is a common treatment choice for children with complex OSA or those who refuse surgical treatment for airway obstruction. Polysomnography can determine the severity of OSA. Typically, once the



**Table 4** Comparison of Features, Advantages, and Disadvantages of DISE Combined with Other Diagnostic and Therapeutic Methods

Combined Examination Methods	Purpose	Advantages	Disadvantages
DISE combined with Positive Pressure Ventilation	<ul style="list-style-type: none"> <li>• Real-time visualization during therapy</li> <li>• Clarifies obstruction site and determines pressure titration</li> </ul>	<ul style="list-style-type: none"> <li>• Optimizes positive ventilation treatment</li> <li>• Effective for oropharyngeal obstruction</li> <li>• Reduces the need for multiple tests</li> </ul>	<ul style="list-style-type: none"> <li>• Pressure determination can be challenging</li> <li>• Less effective for laryngomalacia with epiglottic collapse</li> <li>• Multiple tests may complicate management</li> </ul>
DISE combined with LR-OCT	<ul style="list-style-type: none"> <li>• High-resolution, cross-sectional airway images</li> <li>• 3D airway model creation</li> </ul>	<ul style="list-style-type: none"> <li>• Provides accurate assessment</li> <li>• Enhances DISE validity</li> <li>• Supports clinical research</li> </ul>	<ul style="list-style-type: none"> <li>• DISE scoring is subjective</li> <li>• Requires additional equipment</li> </ul>
DISE combined with dynamic MRI	<ul style="list-style-type: none"> <li>• Multi-plane observation of obstructions</li> <li>• Simultaneous DISE and MRI</li> </ul>	<ul style="list-style-type: none"> <li>• Increases accuracy of obstruction assessment</li> <li>• Reduces repeated anesthesia</li> </ul>	<ul style="list-style-type: none"> <li>• Requires sedation for both DISE and MRI</li> <li>• Limited to large hospitals due to cost and equipment</li> </ul>

polysomnography examination is completed and the results analyzed, a pressure titration test is further performed to determine the appropriate pressure for positive pressure ventilation therapy during natural sleep. However, the precise pressure required for positive pressure ventilation can be difficult to determine, leading to the requirement of multiple tests and potentially complicating the management of children who cannot tolerate positive pressure ventilation therapy. During positive pressure ventilation therapy, a mask is connected to a dual-rotating adapter to enable simultaneous visualization. In addition to clarifying the site of obstruction, this allows for precise determination of the critical pressure titration level, guiding and supporting the subsequent positive ventilation treatment.<sup>5,40</sup> Positive pressure ventilation also is the most effective treatment for oropharyngeal obstruction in children, but is less effective or even ineffective for treating laryngomalacia with epiglottic collapse in children. This may suggest that pediatric cases in which positive pressure ventilation treatment fails might have significant epiglottic collapse.<sup>5</sup>

## DISE Combined with Long-Range Optical Coherence Tomography Examination (LR-OCT)

DISE examination can clearly determine the site of airway obstruction, but the applied scoring system remains subjective and dependent on the examiner's experience and skills. LR-OCT can capture cross-sectional images using a probe under DISE guidance. These images can be processed to create a three-dimensional model of the airway in the sleep state, allowing for accurate assessment and development of treatment plans.<sup>41</sup> In addition, objective data acquired via LR-OCT can better support clinical research and the validity of DISE examination.

## DISE Combined with Dynamic Magnetic Resonance Imaging Examination

The accuracy of DISE primarily relies on the subjective judgment of the examiner, while dynamic magnetic resonance imaging (MRI) analysis can offer objective measurement and simultaneous observation of obstructions across multiple planes.<sup>42</sup> Both procedures require sedation and anesthesia and can be applied in both adults and children. DISE examination can be performed in the MRI examination room to avoid repeated anesthesia, when the necessary equipment can be assembled there.<sup>43</sup> The combination of these two procedures can greatly enhance the accuracy of upper airway obstruction assessment in children. However, this combined approach is most commonly performed in large research and teaching hospitals and has not been widely accepted, likely due to factors such as medical insurance coverage, cost, and the availability of ancillary support services.

## Discussion

### Critical Appraisal of Existing Literature

Despite the growing body of research on pediatric DISE, methodological limitations remain. Many studies have been retrospective in design with small sample sizes and lack appropriate control groups, which compromises the strength of evidence. Only a limited number of randomized controlled trials (RCTs) have been conducted, making it difficult to establish evidence-based standards for sedation regimens or scoring systems.

Moreover, heterogeneity in sedation protocols (eg, dexmedetomidine vs ketamine vs propofol), patient positioning (supine vs lateral), and DISE scoring systems (eg, VOTE, Chan, NAVOTEL) also hampers data comparability. While some studies demonstrate high inter-rater reliability using structured scoring (eg, SERS and IPOG consensus tools), others show wide variability in interpretation, likely due to lack of training or standardization. Additionally, selection bias is prevalent, as most studies have focused on children with persistent OSA after adenotonsillectomy, excluding those with milder symptoms or varied clinical presentations.<sup>44,45</sup> Publication bias also exists, with underreporting of negative or inconclusive results.

Conflicting findings across studies are not uncommon—for example, while several studies suggest that DISE improves surgical planning and outcomes,<sup>46–48</sup> others find no added benefit compared to traditional evaluation.<sup>49–51</sup> These discrepancies may stem from institutional experience, patient heterogeneity, or variations in anesthetic depth and scoring interpretation.

To advance the field, future research should include multicenter prospective studies with standardized methodology, validated scoring frameworks, and assessments of inter-rater reliability. Incorporating computational tools or artificial intelligence (AI)-assisted image analysis may help reduce subjectivity in obstruction grading.

### Limitations and Future Directions

#### Knowledge Gaps in Pediatric DISE

Although the application of DISE in pediatric populations has expanded in recent years, there remains limited high-quality evidence on long-term outcomes, optimal timing (pre- vs postoperative), and patient selection criteria. For instance, whether routine postoperative DISE improves management is still unclear, especially in cases without residual symptoms.

#### Methodological Challenges

Most studies on pediatric DISE have been retrospective, single-center studies with small sample sizes. Variability in sedation depth, operator experience, and interpretation of scoring systems contributes to inconsistent findings. Moreover, the lack of standardized outcome metrics limits meta-analysis and evidence synthesis.

#### Barriers to Clinical Implementation

The high cost of equipment, need for specialized personnel, and limited insurance coverage hinder widespread adoption, especially in low-resource settings. Additionally, concerns about sedation safety in children often lead to reluctance among parents and healthcare providers.

#### Standardization Issues

There is currently no universally accepted protocol for anesthesia, scoring systems, or procedural steps in pediatric DISE. While the IPOG consensus provides a promising framework, inter-center variability in practice remains a significant limitation.

#### Areas Requiring Further Research

Future efforts should focus on large-scale, multicenter, prospective studies to validate scoring systems, explore AI-assisted video analysis to reduce observer bias, and evaluate the cost-effectiveness of DISE in routine care. Studies should also address the impact of racial and anatomical variabilities in pediatric airway anatomy on DISE interpretation and treatment planning.

### Clinical Implications

DISE plays an increasingly critical role in guiding personalized treatment strategies for pediatric OSA. Its ability to visualize dynamic airway collapse allows clinicians to tailor interventions beyond traditional adenotonsillectomy, such as





incorporating lingual tonsillectomy or supraglottoplasty. In high-risk children or those with residual symptoms post-surgery, DISE findings directly influence decisions regarding surgical revision or the initiation of positive airway pressure therapy.

Several studies have demonstrated improved outcomes when DISE-guided strategies are employed. For example, Adler et al reported that DISE-directed continuous positive airway pressure (CPAP) titration significantly improved compliance and reduced the apnea–hypoxia index by more than 50% in 60% of children.<sup>40</sup> Akkina et al showed that DISE-assisted surgery in children with Down syndrome led to meaningful improvement in polysomnography parameters.<sup>20</sup>

Although DISE requires sedation and specialized equipment, it can be cost-effective in the long term by reducing diagnostic ambiguity, preventing failed surgeries, and optimizing resource allocation. Appropriate patient selection is essential to maximize benefit. Ideal candidates include those with persistent OSA post-adenotonsillectomy, craniofacial anomalies, neuromuscular disease, or intolerance to CPAP. In these populations, DISE provides essential diagnostic insight to support informed decision-making.

## Conclusion

The ideal approach to performing endoscopic evaluation of obstructive upper airway disease is during the natural sleep state. However, this is often impractical, because most children are easily aroused even by minimal stimulation during the procedure.<sup>34</sup> Thus, a drug-induced sleep state offers the most reliable alternative to the natural sleep state. At present, DISE examination can be performed in children with upper airway obstructive disease, if they have no contraindication to anesthesia. Dexmedetomidine and propofol have been identified as the best sedatives for pediatric DISE examination, although further research is needed to determine the optimal concentrations of these sedative drugs and optimal sedation depth for fully simulating the natural sleep state, as well as to characterize the long-term and short-term side effects and optimize electroencephalogram monitoring. Pediatric DISE scoring systems can provide a standard for large-scale, multi-center clinical studies. However, the efficacy of current scoring systems still must be clinically validated to improve their performance and promote clinical acceptability. In addition, upper airway anatomical structures can differ among children from different ethnic backgrounds. Thus, research is still required to determine whether such differences lead to significant differences in DISE results, requiring different evaluation approaches and types and doses of medications. The combined application of DISE examination with other therapeutic and diagnostic procedures can enable objective and precise determination of airway obstruction morphology, three-dimensional structural diagrams, and positive pressure ventilation titration. Its use for all of these purposes can lead to expanded clinical application of DISE examination in both pediatric and adult populations.

## Abbreviations

DISE, Drug-induced sleep endoscopy; OSA, Obstructive sleep apnea; VOTE, Velum, oropharynx and lateral pharyngeal walls, tongue base, and epiglottis; LR-OCT, Long-range optical coherence tomography; SERS, Sleep Endoscopy Rating Scale; MRI, Magnetic resonance imaging.

## Data Sharing Statement

The datasets generated and analyzed during the present study are available from the corresponding author on reasonable request.

## Author Contributions

Critical revision: All authors reviewed and revised the manuscript, agreed on all versions before submission and during revisions, and are accountable for the content.

Agreement: All authors agreed on the journal for submission and the final version of the article.

Conceptualization: Zhixian Xiao, Xing Li, Li Tian, Weiqi Li

Funding acquisition: Zhixian Xiao, Weiqi Li

Methodology: Zhixian Xiao, Xiaocui Long

Resources: Zhixian Xiao, Xing Li, Weiqi Li

Supervision: Li Tian, Weiqi Li

Visualization: Li Zhou

Writing-original draft: Zhixian Xiao, Xing Li, Li Zhou, Xiaocui Long, Li Tian, Weiqi Li.

## Disclosure

We declare that we have no conflict of interest.

## References

- Arganbright JM, Lee JC, Weatherly RA. Pediatric drug-induced sleep endoscopy: an updated review of the literature. *World J Otorhinolaryngol Head Neck Surg.* 2021;7(3):221–227. doi:10.1016/j.wjorl.2021.05.002
- Croft CB, Thomson HG, Samuels MP, Southall DP. Endoscopic evaluation and treatment of sleep-associated upper airway obstruction in infants and young children. *Clin Otolaryngol Allied Sci.* 1990;15(3):209–216. doi:10.1111/j.1365-2273.1990.tb00777.x
- Iannella G, Magliulo G, Greco A, et al. Clinical application of pediatric sleep endoscopy: an international survey. *Children.* 2024;11(1):94. doi:10.3390/children11010094
- Williamson A, Ibrahim SR, Coutas SW, Carr MM. Pediatric drug-induced sleep endoscopy: technique and scoring system. *Cureus.* 2020;12(10):e10765. doi:10.7759/cureus.10765
- Masarova M, Matousek P, Jor O, et al. Sleep endoscopy with positive airway pressure: a method for better compliance and individualized treatment of patients with obstructive sleep apnea. *Life.* 2022;12(12):2108. doi:10.3390/life12122108
- Baldassari CM, Lam DJ, Ishman SL, et al. Expert consensus statement: pediatric drug-induced sleep endoscopy. *Otolaryngol Head Neck Surg.* 2021;165(4):578–591. doi:10.1177/0194599820985000
- Zalzal HG, Coutas S. Palatine tonsil stenting of the airway as determined by drug-induced sleep endoscopy. *Case Rep Otolaryngol.* 2018;2018:2614143. doi:10.1155/2018/2614143
- Quinlan CM, Otero H, Tapia IE. Upper airway visualization in pediatric obstructive sleep apnea. *Paediatr Respir Rev.* 2019;32:48–54. doi:10.1016/j.prrv.2019.03.007
- Frederick RM, Brandt J, Sheyn A. Drug-induced sleep endoscopy effect on intraoperative decision making in pediatric sleep surgery: a 2-year follow up. *Laryngoscope Investig Otolaryngol.* 2022;7(6):2112–2118. doi:10.1002/liv.2.918
- Cousineau J, Prevost AS, Battista MC, Gervais M. Management of obstructive sleep apnea in children: a Canada-wide survey. *J Otolaryngol Head Neck Surg.* 2021;50(1):53. doi:10.1186/s40463-021-00539-5
- Albdah AA, Alkusayer MM, Al-Kadi M, Almofada H, Alnofal EA, Almutairi S. The impact of drug-induced sleep endoscopy on therapeutic decisions in obstructive sleep apnea: a systematic review and meta-analysis. *Cureus.* 2019;11(10):e6041. doi:10.7759/cureus.6041
- Maksimowski M, Maurrasse SE, Hoff SR, et al. Pediatric sleep outcomes after endoscopy-directed simultaneous lingual tonsillectomy and epiglottopexy. *J Otolaryngol Head Neck Surg.* 2022;51(1):11. doi:10.1186/s40463-022-00562-0
- Newby M, Callahan S, Carr M. Obstructive sleep apnea with paradoxical vocal cord movement in children during sleep endoscopy: case series. *Case Rep Pediatr.* 2020;2020:7380802. doi:10.1155/2020/7380802
- Katwa U, Sisniega C, McKeon M, Lee GS. Sleep endoscopy-directed management of Arnold-Chiari malformation: a child with persistent obstructive sleep apnea. *J Clin Sleep Med.* 2020;16(2):325–329. doi:10.5664/jcsm.8194
- Viola FC, Favre NM, Kabalan M, Carr MM. Unilateral vocal cord paresis during sleep endoscopy. *Cureus.* 2021;13(5):e15157. doi:10.7759/cureus.15157
- Chen J, He S. Drug-induced sleep endoscopy-directed adenotonsillectomy in pediatric obstructive sleep apnea with small tonsils. *PLoS One.* 2019;14(2):e0212317. doi:10.1371/journal.pone.0212317
- Miller C, Kirkham E, Ma CC, et al. Polysomnography outcomes in children with small tonsils undergoing drug-induced sleep endoscopy-directed surgery. *Laryngoscope.* 2019;129(12):2771–2774. doi:10.1002/lary.27759
- Lenze NR, Bharadwaj SR, Baldassari CM, Kirkham EM. Surgical management of pediatric obstructive sleep apnea beyond adenotonsillectomy: the nose, nasopharynx, and palate. *Otolaryngol Clin North Am.* 2024;57(3):421–430. doi:10.1016/j.otc.2024.02.008
- Lookabaugh S, McKenna M, Karelsky S, et al. Drug-induced sleep endoscopy findings in surgically-naïve obese vs non-obese children. *Int J Pediatr Otorhinolaryngol.* 2020;138:110289. doi:10.1016/j.ijporl.2020.110289
- Akkina SR, Ma CC, Kirkham EM, Horn DL, Chen ML, Parikh SR. Does drug induced sleep endoscopy-directed surgery improve polysomnography measures in children with Down Syndrome and obstructive sleep apnea? *Acta Otolaryngol.* 2018;138(11):1009–1013. doi:10.1080/00016489.2018.1504169
- Sharma AV, Padhya T, Nallu S. Management of pediatric obstructive sleep apnea after failed tonsillectomy and adenoidectomy. *Adv Pediatr.* 2022;69(1):95–105. doi:10.1016/j.yapd.2022.03.006
- Adler AC, Musso MF, Mehta DK, Chandrakantan A. Pediatric drug induced sleep endoscopy: a simple sedation recipe. *Ann Otol Rhinol Laryngol.* 2020;129(5):428–433. doi:10.1177/0003489419892292
- Chieffe D, Baldassari CM, Friedman N, Smith D, Heubi C, Hartnick C. Pediatric down syndrome upper airway stimulation: patient selection and post-implantation optimization. *Otolaryngol Head Neck Surg.* 2024;170(4):1158–1166. doi:10.1002/ohn.633
- Mooney KL, Brooks Peterson M, Skirko JR, Friedman NR. The quest for a DISE protocol. *Otolaryngol Head Neck Surg.* 2022;167(3):590–599. doi:10.1177/01945998211036645
- Polytarchou A, Moudaki A, Van de Perck E, et al. An update on diagnosis and management of obstructive sleep apnoea in the first 2 years of life. *Eur Respir Rev.* 2024;33(171):230121. doi:10.1183/16000617.0121-2023
- Liu KA, Liu CC, Alex G, Szmuk P, Mitchell RB. Anesthetic management of children undergoing drug-induced sleep endoscopy: a retrospective review. *Int J Pediatr Otorhinolaryngol.* 2020;139:110440. doi:10.1016/j.ijporl.2020.110440
- Zhang JW, Zhang RD. [Feasibility study of dexmedetomidine combined with ketamine for drug-induced sleep airway endoscopy in children with obstructive sleep apnea syndrome]. *Int J Anesthesiol Resuscitat.* 2021;42(2):4. Danish.



28. Croft CB, Pringle M. Sleep nasendoscopy: a technique of assessment in snoring and obstructive sleep apnoea. *Clin Otolaryngol Allied Sci.* 1991;16(5):504–509. doi:10.1111/j.1365-2273.1991.tb01050.x
29. Yongping Z, Xinyi L, Aming S, et al. The safety and efficacy of esketamine in comparison to dexmedetomidine during drug-induced sleep endoscopy in children with obstructive sleep apnea hypopnea syndrome: a randomized, controlled and prospective clinical trial. *Front Pharmacol.* 2022;13:1036509. doi:10.3389/fphar.2022.1036509
30. Carrasco Llatas M, Agostini Porras G, Cuesta Gonzalez MT, et al. Drug-induced sleep endoscopy: a two drug comparison and simultaneous polysomnography. *Eur Arch Otorhinolaryngol.* 2014;271(1):181–187. doi:10.1007/s00405-013-2548-3
31. Kong LY. Review and prospect of drug-induced sleep endoscopy in children. *Chin J Integr Trad Western Pediatrics.* 2019;11(1):5.
32. Zheng Y, Xiong B, Sang A, Liu X, Li X, Song X. Bispectral index versus the University of Michigan sedation scale in assessing sedation depth during pediatric drug-induced sleep endoscopy. *Sleep Breath.* 2024;28(3):1365–1372. doi:10.1007/s11325-024-03022-3
33. Ulualp SO, Kezirian EJ. Advanced diagnostic techniques in obstructive sleep apnea. *Otolaryngol Clin North Am.* 2024;57(3):371–383. doi:10.1016/j.otc.2024.02.002
34. Carr M, Phillips D. Sleep endoscopy findings in children in supine versus left lateral position. *Int J Pediatr Otorhinolaryngol.* 2020;134:110056. doi:10.1016/j.ijporl.2020.110056
35. DeJarnette K, Frederick RM, Harris AJ, Bashir A, Wood J, Sheyn A. Use of VOTE score in predicting outcomes in pediatric obstructive sleep apnea. *Int J Pediatr Otorhinolaryngol.* 2022;162:111256. doi:10.1016/j.ijporl.2022.111256
36. C YC. [Clinical research and meta-analysis of role of drug-induced sleep endoscopy during management of obstructive sleep apnea-hypopnea syndrome in children]. *China Med Univ.* 2023.
37. Qarbal J, Le Treut-Gay C, Allali L, Rossi ME, Nicollas R, Moreddu E. Drug-induced sleep endoscopy in children: NAVOTEL scoring system development. *Pediatr Pulmonol.* 2023;58(7):1889–1895. doi:10.1002/ppul.26408
38. Williamson A, Fang W, Kabalan MJ, Zalzal HG, Coutras SW, Carr MM. Reliability of a pediatric sleep endoscopy scoring system. *Int J Pediatr Otorhinolaryngol.* 2022;162:111284. doi:10.1016/j.ijporl.2022.111284
39. Parikh SR, Boudewyns A, Friedman NR, et al. International Pediatric Otolaryngology Group (IPOG) consensus on scoring of pediatric Drug Induced Sleep Endoscopy (DISE). *Int J Pediatr Otorhinolaryngol.* 2023;171:111627. doi:10.1016/j.ijporl.2023.111627
40. Adler AC, Chandrakantan A, Musso MF. Continuous positive airway pressure titration during pediatric drug induced sleep endoscopy. *Ann Otol Rhinol Laryngol.* 2022;131(10):1085–1091. doi:10.1177/00034894211055527
41. Goshtasbi K, Su E, Jing JC, et al. Long-range optical coherence tomography of pediatric airway during drug induced sleep endoscopy: a preliminary report. *Int J Pediatr Otorhinolaryngol.* 2024;178:111900. doi:10.1016/j.ijporl.2024.111900
42. Li C, Kou YF, DeMarcantonio MA, et al. Sleep endoscopy and cine magnetic resonance imaging evaluation of children with persistent obstructive sleep apnea. *Otolaryngol Head Neck Surg.* 2023;168(4):848–855. doi:10.1177/01945998221097659
43. Bergeron M, Lee DR, DeMarcantonio MA, et al. Safety and cost of drug-induced sleep endoscopy outside the operating room. *Laryngoscope.* 2020;130(8):2076–2080. doi:10.1002/lary.28397
44. Galluzzi F, Garavello W. Impact of adenotonsillectomy in children with severe obstructive sleep apnea: a systematic review. *Auris Nasus Larynx.* 2021;48(4):549–554. doi:10.1016/j.anl.2020.10.008
45. Alomari O, Ertan SN, Mokresh ME, et al. Revisiting the efficiency and necessity of adenotonsillectomy in children with mild obstructive sleep apnea: a systematic review and meta-analysis. *Eur Arch Otorhinolaryngol.* 2025. doi:10.1007/s00405-025-09380-2
46. Vito A, Cammaroto G, Chong KB, Carrasco-Llatas M, Vicini C. Drug-induced sleep endoscopy: clinical application and surgical outcomes. *Healthcare.* 2019;7(3).
47. Huntley C, Chou D, Doghramji K, Boon M. Preoperative drug induced sleep endoscopy improves the surgical approach to treatment of obstructive sleep apnea. *Ann Otol Rhinol Laryngol.* 2017;126(6):478–482. doi:10.1177/0003489417703408
48. Hessel NS, de Vries N. Results of uvulopalatopharyngoplasty after diagnostic workup with polysomnography and sleep endoscopy: a report of 136 snoring patients. *Eur Arch Otorhinolaryngol.* 2003;260(2):91–95. doi:10.1007/s00405-002-0511-9
49. Veugen C, Sanders RMC, Stokroos RJ, Copper MP. Drug-induced sleep endoscopy: are there predictors for failure of oral appliance treatment? *Int Arch Otorhinolaryngol.* 2022;26(3):e339–e347. doi:10.1055/s-0041-1731368
50. Chen RF, Nakayama M, Sung WC, Hung JF, Chu YM. Comparison of surgical outcomes of sleep surgeries preoperatively evaluated with drug-induced sleep endoscopy and Müller's maneuver. *Auris Nasus Larynx.* 2022;49(2):235–239. doi:10.1016/j.anl.2021.08.001
51. Ha JG, Lee Y, Nam JS, et al. Can drug-induced sleep endoscopy improve the success rates of tongue base surgery? *J Otolaryngol Head Neck Surg.* 2020;49(1):8. doi:10.1186/s40463-020-00405-w

## Nature and Science of Sleep

## Publish your work in this journal

Nature and Science of Sleep is an international, peer-reviewed, open access journal covering all aspects of sleep science and sleep medicine, including the neurophysiology and functions of sleep, the genetics of sleep, sleep and society, biological rhythms, dreaming, sleep disorders and therapy, and strategies to optimize healthy sleep. The manuscript management system is completely online and includes a very quick and fair peer-review system, which is all easy to use. Visit <http://www.dovepress.com/testimonials.php> to read real quotes from published authors.

Submit your manuscript here: <https://www.dovepress.com/nature-and-science-of-sleep-journal>

**Dovepress**  
Taylor & Francis Group