

Comparison of Honey versus Polylactide Anti-Adhesion Barrier on Peritoneal Adhesion and Healing of Colon Anastomosis in Rabbits

Ali Reza Negahi¹, Parisa Hosseinpour², Mohammad Vaziri^{1,3}, Hamed Vaseghi⁴, Pedram Darvish⁵, Behnaz Bouzari⁶, Seyed Hamzeh Mousavie^{1*}

¹Hazrat Rasoul Medical Complex, Iran University of Medical Sciences, Tehran, Iran; ²School of Medical, Iran University of Medical Sciences, Tehran, Iran; ³Thoracic Surgery Iran University of medical sciences, Tehran, Iran; ⁴Rasoul Akram Hospital, Iran University of Medical Sciences, Tehran, Iran; ⁵Iran University of Medical Sciences, Tehran, Iran; ⁶Department of Pathology and Laboratory Medicine, Iran University of Medical Sciences, Firoozgar Hospital, Valadi St, Valiasr Square, Tehran, Iran

Abstract

Citation: Negahi AR, Hosseinpour P, Vaziri M, Vaseghi H, Darvish P, Bouzari B, Mousavie SH. Comparison of Honey versus Polylactide Anti-Adhesion Barrier on Peritoneal Adhesion and Healing of Colon Anastomosis in Rabbits. Open Access Maced J Med Sci. 2019 May 31; 7(10):1597-1601.
<https://doi.org/10.3889/oamjms.2019.284>

Keywords: Peritoneal Adhesion; Honey; Polylactide; Colon

***Correspondence:** Seyed Hamzeh Mousavie. Hazrat Rasoul Medical Complex, Iran University of Medical Sciences, Tehran, Iran. E-mail: afraziabi2017@gmail.com

Received: 19-Jan-2019; **Revised:** 05-May-2019; **Accepted:** 06-May-2019; **Online first:** 25-May-2019

Copyright: © 2019 Ali Reza Negahi, Parisa Hosseinpour, Mohammad Vaziri, Hamed Vaseghi, Pedram Darvish, Behnaz Bouzari, Seyed Hamzeh Mousavie. This is an open-access article distributed under the terms of the Creative Commons Attribution-NonCommercial 4.0 International License (CC BY-NC 4.0)

Funding: This research did not receive any financial support

Competing Interests: The authors have declared that no competing interests exist

BACKGROUND: Postoperative adhesion is still a consequence of intra-abdominal surgeries, which results in bowel obstruction and abdominopelvic pain. Bowel anastomosis as a common abdominal surgery has the incidence of leakage in up to 30% of patients that increase morbidity and mortality. Due to similar pathways of adhesion formation and wound healing, it is important to find a way to reduce adhesions and anastomosis leakage.

AIM: This study was designed to compare antiadhesive as well as anastomosis healing improvement effect of honey and polylactide anti-adhesive barrier film.

METHODS: Forty-five rabbits divided into three groups of honey, adhesion barrier film, and control group in an animal study. Under a similar condition, rabbits underwent resection and anastomosis of cecum under general anaesthesia. In the first group, honey was used at the anastomosis site, in the second one polylactide adhesion barrier film utilised, and the third one was the control group. Adhesion, as well as anastomosis leakage, was assessed after 21 days. Data were analysed using the Statistical Package for Social Scientists (SPSS) for Windows version 25.

RESULTS: Three groups of 15 rabbits were studied. The results showed that mean peritoneal adhesion score (PAS) was lower in the honey group (1.67) in comparison to the adhesion barrier film group (3.40) and the control group (6.33).

CONCLUSION: Bio-absorbable polylactide barrier has an anti-adhesion effect but is not suitable for intestinal anastomosis in rabbits. Further studies needed to evaluate these effects on human beings.

Introduction

Postoperative peritoneal adhesion is still an obvious consequence of intra-abdominal surgeries in spite of modern surgical techniques and precautions [1], [2]. Peritoneal surfaces trauma and tissue ischemia cause adhesion resulting in bowel obstruction, abdominopelvic pain, and female infertility [3], [4], [5]. Adhesion will lead to prolonged hospitalisation and increased health care cost [6], [7].

Bowel anastomosis is a common abdominal

operation, and the incidence of anastomosis leakage has been reported in different studies between 2.6% to 30% depending on the type of procedure, surgical technique and patient demographics [8], [9], [10], [11]. Anastomosis leakage leads to increase hospitalisation, morbidity and mortality ranging from 6.2% to 37% [12], [13]. Due to similar pathways of adhesion formation and wound healing, finding a way to reduce adhesions will probably lead to discovering measures to reduce anastomosis leakage.

Although various methods have been used to reduce tissue adhesion and improve anastomosis

healing, there is no significant effect yet [14], [15], [16]. Honey has a long history in medicine as an anti-inflammatory, anti-bacterial, and wound healing agent [17], [18]. Recent animal studies have reported anti-adhesion effect and anastomosis healing properties of honey [19], [20]. Moreover, some commercially available barriers have reported having both anti-adhesion and healing improvement effects [21], [22], [23]. Research has shown that honey can reduce the inflammation, growth and angiogenesis, improve intra-abdominal adhesion and increase antioxidant factors [24], as well as in a review study, bactericidal effects, reduction the pH of the wound, chronic inflammation and increment of fibroblasts infiltration has been reported for honey [25].

Considering the beneficial effects of honey are approved, and there is no problem in its accessibility, as well as given that it is affordable, this study was designed to evaluate the effect of honey and polylactide barrier on adhesion formation as well as leakage of anastomosis site in rabbits.

Methods

Animal study

In this study, 45 healthy male rabbits with the mean weight of 3000-3500 grams were divided into three groups (15 rabbits in each group, including honey, adhesion barrier film, and control group). Rabbits were obtained from the Pasteur Institute of Iran (IPI).

They were kept and fed based on standard laboratory diet and water for one week before surgery in a similar condition. Animals were fasted, except for water, 12 hours before surgical intervention. Neither mechanical bowel preparation nor intraoperative bowel irrigation was performed. All experimental procedures were approved by the ethics committee of Iran University of Medical Sciences for the use of laboratory animals.

Rabbits were shaved and anaesthetised in the supine position with intramuscular ketamine (30-35 mg/kg) and intramuscular xylazine (10-15 mg/kg) by a specialised team from the department of veterinary medicine of Tehran University of Medical Sciences.

The shaved area was cleaned and isolated with a sterile dressing. Approximately 6 cm midline incision starting from 10 cm below the xiphoid along the linea alba was made. After entering the peritoneal cavity, the cecum was identified and transected 5 cm distal to ileocecal junction and anastomosis of the transected area was performed using a single running layer Vicryl 3-0 sutures. In the first group, 3 ml of sterile honey was applied at the anastomosis site. In

the second group, one adhesion barrier film was used over the anastomosis site. The third was a control group in which no material was used. Finally, abdominal fascia and skin were closed using continuous Nylon 3-0 and interrupted Nylon 4-0 sutures, respectively. The postoperative dressing was applied to prevent self-harm.

In the first group, sterile antibacterial medical honey produced by DERMESIENCES Company was used in our study. A bio-absorbable polylactide adhesion barrier film with a copolymer of 70:30 polys (L-lactide-co-D, L-lactide) produced by MAST company was used in the second group.

Adhesion Barrier Film (SurgiWrap®) is a temporary physical barrier to:

1. Separate opposing tissues and prevent the ingrowth of scar tissues and the formation or reformation of adhesions immediately adjacent to the barrier film.

2. Aid in the reoperation procedures by promoting the formation of a surgical dissection plane immediately adjacent to the barrier film.

3. Promote the formation of a surgical dissection plane to include the following anatomic regions:

- 1) Peritoneum, peritoneal cavity, bowels, cecum, organs

- 2) Ob/Gyn (e.g. Female pelvic, reproductive organs, ovaries, uterus, uterine tube, etc.)

Adhesion Barrier Film is a transparent polymer film that is designed to separate opposing tissue during the critical period of peritoneal healing. Made of polylactide (PLA), it comes in 8 different sizes. A copolymer of 70:30 Polys (L-lactide-co-D, L-lactide), it is composed of lactic acid similar to that which occurs naturally in the human body, the material maintains its strength during the healing process, and is slowly hydrolysed into lactic acid. The molecules are then metabolised into carbon dioxide and water and are released from the body through the lungs. SurgiWrap® received FDA clearance to be used in urological, gynaecological, and gastroenterological procedures, either by laparotomy or laparoscopy. Seprafilm Adhesion Barrier is contraindicated for use wrapped directly around a fresh anastomotic suture or staple line; as such use increases the risk of anastomotic leak and related events (fistula, abscess, leak, sepsis, peritonitis) (<https://www.seprafilm.us>).

The postoperative diet was initiated after complete regain of consciousness with standard laboratory diet and water. Rabbits were returned to the operating room 21 days after the first operation and anaesthetised using the previous method. The previous surgical site was shaved, cleaned, and isolated with sterile dressing in the supine position.

Then laparotomy was done at a previous site by another surgeon and anastomosis leakage, mesenteric ischemia, and peritoneal adhesion index (PAI) were evaluated. The abdomen was divided into nine areas, and an adhesion severity score was related to each area. The sum of the scores was calculated as the PAI. Adhesion severity score was presented as the following order: zero for no adhesions, 1 for filmy adhesions which could remove by blunt dissection, 2 for strong adhesions which were removed by sharp dissection, and 3 for very strong vascularized adhesions which were removed by sharp dissection and tissue damage was hardly preventable. Anastomosis leakage was also evaluated by the second surgeon.

Statistical analysis

The values were expressed as mean, standard errors of deviation. The mean values of the groups were compared by one-way analysis of variance (ANOVA) as well as the least significant difference (LSD) as a post hoc test. $P < 0.05$ was considered significant. The statistical tests were run on a compatible personal computer using the Statistical Package for Social Scientists (SPSS) for Windows version 25.

Results

Four of 15 rabbits in the polylactide anti-adhesive-barrier – film (SurgiWrap®) group died in the second week which immediately underwent laparotomy, and the adhesion severity and leakage status were investigated.

Table 1: The mean and standard deviation of Peritoneal Adhesion Index for the three groups

Variable	N	Mean (SD)	95% Confidence Interval
Peritoneal Adhesion Index			
Honey	15	1.67 (0.724)	1.27, 2.07
SurgiWrap®	15	3.40 (1.805)	2.40, 4.40
Control	15	6.33 (1.447)	5.53, 7.13
Total	45	3.80 (2.380)	3.09, 4.51

Descriptive data for 45 Rabbits are presented in Table 1. The results showed that the least adhesion occurred in the honey group, and the most adhesion occurred in the control group.

Table 2: Adhesion Score for the three study groups

Adhesion score	Honey group (n = 15)	SurgiWrap® group (n = 15)	Control group (n = 15)
0	0	2	0
1	7	0	0
2	6	2	0
3	2	3	0
4	0	3	2
5	0	4	2
6	0	1	4
7	0	0	4
8	0	0	2
9	0	0	1
10	0	0	0

Adhesion numbers with different scores for each group are presented in Table 2. Also, the box plot for the comparison of the three groups is presented in Figure 1.

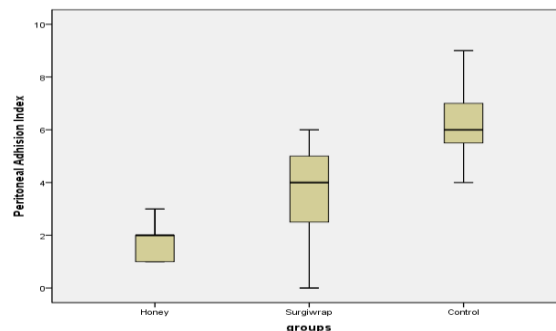


Figure 1: Box Plot of adhesion score for the three study groups

One-way ANOVA for the mean adhesion score of the three groups showed that there was a significant difference between the control group and the two other interventional groups (honey and SurgiWrap®) ($P < 0.001$, $F = 45.2$), so that the honey group had significantly less adhesion score compared with the control and polylactide groups. Post-hoc test (LSD) was used to assess the difference between adhesion scores of all three groups, which are presented in Table 3.

Table 3: Comparison of Peritoneal Adhesion Index in the three groups

Groups	Mean Diff.	Std. Error	P value	95% CI
Honey SurgiWrap®	-1.733	0.511	0.002	-2.76 to -0.70
Honey Control	-4.667	0.511	0.000	-5.70 to -3.64
SurgiWrap® Control	-2.933	0.511	0.000	-3.96 to -1.90

*The mean difference is significant at the 0.05 level.

Discussion

Anastomosis healing without adhesion formation after bowel injury repair or elective bowel resection and anastomosis is still an unmet necessity. In addition to increasing postoperative morbidity and mortality, anastomosis leakage and adhesion formation lead to escalating health costs [3], [4], [12], [13]. Although, several studies have been done on barrier films or chemical agents; there is no effective method yet [15], [16].

Use of barriers has been reported in previous studies as an effective anti-adhesion agent, but adverse effects on bowel anastomosis have limited their widespread application. Bio-absorbable polylactide adhesion barrier films were used in our study, which had significantly less adhesion compared with the control group. The main effect of barriers is to separate injured serosal surfaces so that the mesothelial regeneration can be completed smoothly

[19]. Beneficial anti-adhesion effects of barriers after abdominal surgeries [23], [26], [27] and gynecologic operations [28], [29] have been reported with acceptable results.

In a study conducted by Aly Saber in 2009, which compared the anti-adhesion effect of honey versus integral as an anti-adhesive agent, none of the rats was immune from adhesion formation [19]. Barriers had local anti-adhesion effects and did not decrease adhesion at other abdominal sites. Probably this was due to the good local anti-adhesion effect of polylactide barrier and lower surgical manipulation of other sites in these two rabbits.

In the study of sabre, although all rabbits in the honey group had postoperative adhesion, adhesion score in the honey group was significantly lower than polylactide barrier. Adhesion score in the honey group was between 1 and 3, and there were not strong or very strong adhesions (grade II and III) in none of the honey group rabbits. It may be due to the wider diffusion of honey compared to barrier resulting in less adhesion effect on other abdominal areas leading to lower adhesion score. Saber also reported that 80% of rats receiving intraperitoneal honey had adhesions [19] firmly. Honey' barrier action may be effective in separating traumatised surfaces and reducing extent as well as adhesion severity [19], [30]. Aysan et al. concluded that the high density of honey would result in its late peritoneal absorption, and this may inhibit adhesion formation up to mesothelial regeneration in their study on rats [31].

Gollu et al. revealed that honey had a protective role against intraperitoneal adhesion [30]. Honey has a long history as an effective subject for wound healing [32]. Moreover, its anti-bacterial and anti-fungal effects may reduce adhesion, since infection is a known trigger of adhesion formation [33], [34]. Furthermore, honey can prevent adhesion formation as a result of anti-inflammatory and anti-oxidant effects [35].

Current anti-adhesion agents improve anastomosis healing and inhibit adhesion formation [30], [36]. But their use is controversial as an increase in anastomosis leakage has been reported in some studies [37]. In our study, both rabbits, there was no anastomosis leakage in the honey and the control groups, but five rabbits in polylactide anti-adhesion group died because of anastomosis leakage. Van Oosterom, in his study on the effect of hyaluronic acid-carboxymethylcellulose membrane on small bowel anastomosis, reported no anastomosis healing impairment [38]. Erturk on his study on the hyaluronic acid-carboxymethylcellulose membrane's effect on colonic anastomosis also reported no adverse effects [39]. Probably this is due to the local anti-adhesion effect of polylactide barrier, which has adverse effects on anastomosis healing as both of the processes have a similar molecular mechanism. Furthermore, honey might be effective on the molecular mechanism

of wound healing, but the definite mechanism is unknown [40].

In conclusion, honey has anti-adhesion and wound healing effects on bowel anastomosis in rabbits. Bio-absorbable polylactide barrier has an anti-adhesion effect but is not suitable for intestinal anastomosis in rabbits. Further studies needed to evaluate these effects on human beings.

References

- Roman H, Canis M, Kamble M, et al. Efficacy of three adhesion-preventing agents in reducing severe peritoneal trauma induced by bipolar coagulation in a laparoscopic rat model. *Fertil Steril.* 2005; 83(1):1113-8. <https://doi.org/10.1016/j.fertnstert.2004.08.039> PMID:15831283
- Ellis H. Medicolegal consequences of postoperative intra-abdominal adhesions. *J R Soc Med.* 2001; 94(7):331-2. <https://doi.org/10.1177/014107680109400703> PMID:11418701 PMCid:PMC1281595
- van der Wal JB, Jeekel J. Biology of the peritoneum in normal homeostasis and after surgical trauma. *Colorectal Dis.* 2007; 9(Suppl 2):9-13. <https://doi.org/10.1111/j.1463-1318.2007.01345.x> PMID:17824965
- Menzies D, Ellis H. Intestinal obstruction from adhesions--how big is the problem? *Ann R Coll Surg Engl.* 1990; 72(1):60-3.
- Boland GM, Weigel RJ. Formation and prevention of postoperative abdominal adhesions. *J Surg Res.* 2006; 132(1):3-12. <https://doi.org/10.1016/j.jss.2005.12.002> PMID:16457846
- Ergul E, Korukluoglu B. Peritoneal adhesions: facing the enemy. *Int J Surg.* 2008; 6(3):253-60. <https://doi.org/10.1016/j.ijsu.2007.05.010> PMID:17617231
- Kössi J, Salminen P, Rantala A, et al. Population-based study of the surgical workload and economic impact of bowel obstruction caused by postoperative adhesions. *Br J Surg.* 2003; 90(11):1441-4. <https://doi.org/10.1002/bjs.4272> PMID:14598429
- Bruce J, Krukowski ZH, Al-Khairy G, et al. Systematic review of the definition and measurement of anastomotic leak after gastrointestinal surgery. *Br J Surg.* 2001; 88(9):1157-68. <https://doi.org/10.1046/j.0007-1323.2001.01829.x> PMID:11531861
- Hyman N, Manchester TL, Osler T, et al. Anastomotic leaks after intestinal anastomosis: it's later than you think. *Ann Surg.* 2007; 245(2):254-8. <https://doi.org/10.1097/01.sla.0000225083.27182.85> PMID:17245179 PMCid:PMC1876987
- Aznan MI, Khan OH, Unar AO, Sharif SE, Khan AH, Aziz SH, Zakaria AD. Effect of Tualang honey on the anastomotic wound healing in large bowel anastomosis in a rats-A randomized controlled trial. *BMC complementary and alternative medicine.* 2015; 16(1):28. <https://doi.org/10.1186/s12906-016-1003-6> PMID:26803744 PMCid:PMC4724403
- Fielding LP, Stewart-Brown S, Blesovsky L, et al. Anastomotic integrity after operations for large-bowel cancer: a multicentre study. *Br Med J.* 1980; 281(6237):411-4. <https://doi.org/10.1136/bmj.281.6237.411> PMID:7427298 PMCid:PMC1713296
- Vignali A, Fazio VW, Lavery IC, et al. Factors associated with the occurrence of leaks in stapled rectal anastomoses: a review of 1,014 patients. *J Am Coll Surg.* 1997; 185(2):105-13. [https://doi.org/10.1016/S1072-7515\(97\)00018-5](https://doi.org/10.1016/S1072-7515(97)00018-5)
- McArdle CS, McMillan DC, Hole DJ. Impact of anastomotic leakage on long-term survival of patients undergoing curative resection for colorectal cancer. *Br J Surg.* 2005; 92(9):1150-4. <https://doi.org/10.1002/bjs.5054> PMID:16035134

14. Boland GM, Weigel RJ. Formation and prevention of postoperative abdominal adhesions. *J Surg Res.* 2006; 132(1):3-12. <https://doi.org/10.1016/j.jss.2005.12.002> PMID:16457846
15. Gulcelik MA, Dinc S, Bir F, et al. Locally applied mlogramostim improves wound healing at colonic anastomoses in rats after ligation of the common bile duct. *Can J Surg.* 2005; 48(3):213-8.
16. Ustek S, Kismet K, Akkus MA, et al. Effect of povidone-iodine liposome hydrogel on colonic anastomosis. *Eur Surg Res.* 2005; 37(4):242-5. <https://doi.org/10.1159/000087870> PMID:16260875
17. Aziz Z, Abdul Rasool Hassan B. The effects of honey compared to silver sulfadiazine for the treatment of burns: A systematic review of randomized controlled trials. *Burns.* 2017; 43(1):50-57. <https://doi.org/10.1016/j.burns.2016.07.004> PMID:27576926
18. Farzadnia P, Jofreh N, Khatamsaz S, et al. Anti-inflammatory and Wound Healing Activities of Aloe vera, Honey and Milk Ointment on Second-Degree Burns in Rats. *Int J Low Extrem Wounds.* 2016; 15(3):241-7. <https://doi.org/10.1177/1534734616645031> PMID:27217089
19. Saber A. Effect of honey versus intergel in intraperitoneal adhesion prevention and colonic anastomotic healing: a randomized controlled study in rats. *Int J Surg.* 2010; 8(2):121-7. <https://doi.org/10.1016/j.ijsu.2009.11.010> PMID:19961959
20. Yuzbasioglu MF, Kurutas EB, Bulbuloglu E, et al. Administration of honey to prevent peritoneal adhesions in a rat peritonitis model. *Int J Surg.* 2009; 7(1):54-7. <https://doi.org/10.1016/j.ijsu.2008.10.011> PMID:19042166
21. Trew GH, Pistofidis GA, Brucker SY, et al. A first-in-human, randomized, controlled, subject- and reviewer-blinded multicenter study of Actamax™ Adhesion Barrier. *Arch Gynecol Obstet.* 2017; 295(2):383-395. <https://doi.org/10.1007/s00404-016-4211-x> PMID:27844212 PMID:PMC5281664
22. Berdah SV, Mariette C, Denet C, et al. A multicenter, randomized, controlled trial to assess the safety, ease of use, and reliability of hyaluronic acid/carboxymethylcellulose powder adhesion barrier versus no barrier in colorectal laparoscopic surgery. *Trials.* 2014; 15:413. <https://doi.org/10.1186/1745-6215-15-413> PMID:25348087 PMID:PMC4233044
23. Kim EH, Kim JW, Han GD, et al. Biocompatible, drug-loaded anti-adhesion barrier using visible-light curable furfuryl gelatin derivative. *Int J Biol Macromol.* 2018; 120(Pt A):915-920. <https://doi.org/10.1016/j.ijbiomac.2018.07.180> PMID:30071230
24. Rahimi VB, Shirazinia R, Fereydouni N, Zamani P, Darroudi S, Sahebkar AH, Askari VR. Comparison of honey and dextrose solution on post-operative peritoneal adhesion in rat model. *Biomedicine & Pharmacotherapy.* 2017; 92:849-55. <https://doi.org/10.1016/j.biopha.2017.05.114> PMID:28618654
25. Minden-Birkenmaier B, Bowlin G. Honey-based templates in wound healing and tissue engineering. *Bioengineering.* 2018; 5(2):46. <https://doi.org/10.3390/bioengineering5020046> PMID:29903998 PMID:PMC6027142
26. Li X, Zou B, Zhao N, et al. Potent anti-adhesion barrier combined biodegradable hydrogel with multifunctional Turkish galls extract. *ACS Appl Mater Interfaces.* 2018; 10(29):24469-24479. <https://doi.org/10.1021/acsami.8b10668> PMID:29974740
27. Yang Y, Liu X, Li Y, et al. A postoperative anti-adhesion barrier based on photoinduced imine-crosslinking hydrogel with tissue-adhesive ability. *Acta Biomater.* 2017; 62:199-209. <https://doi.org/10.1016/j.actbio.2017.08.047> PMID:28867650
28. diZerega GS, Coad J, Donnez J. Clinical evaluation of endometriosis and differential response to surgical therapy with and without application of Oxiplex/AP adhesion barrier gel. *Fertil Steril.* 2007; 87(3):485-9. <https://doi.org/10.1016/j.fertnstert.2006.07.1505> PMID:17126335
29. Mettler L, Hucke J, Bojahr B, Tinneberg HR, Leyland N, Avelar R. A safety and efficacy study of a resorbable hydrogel for reduction of post-operative adhesions following myomectomy. *Human reproduction.* 2008; 23(5):1093-100. <https://doi.org/10.1093/humrep/den080> PMID:18346996
30. Gollu A, Kismet K, Kilicoglu B, et al. Effect of honey on intestinal morphology, intraabdominal adhesions and anastomotic healing. *Phytother Res.* 2008; 22(9):1243-7. <https://doi.org/10.1002/ptr.2457> PMID:18697181
31. Aysan E, Ayar E, Aren A, Cifter C. The role of intra-peritoneal honey administration in preventing post-operative peritoneal adhesions. *European Journal of Obstetrics & Gynecology and Reproductive Biology.* 2002; 104(2):152-5. [https://doi.org/10.1016/S0301-2115\(02\)00070-2](https://doi.org/10.1016/S0301-2115(02)00070-2)
32. Witte MB, Barbul A. Repair of full-thickness bowel injury. *Crit Care Med.* 2003; 31(8 Suppl):S538-46. <https://doi.org/10.1097/01.CCM.0000081436.09826.A4> PMID:12907884
33. Cooper RA, Molan PC, Harding KG. The sensitivity to honey of Gram-positive cocci of clinical significance isolated from wounds. *J Appl Microbiol.* 2002; 93(5):857-63. <https://doi.org/10.1046/j.1365-2672.2002.01761.x> PMID:12392533
34. Taormina PJ, Niemira BA, Beuchat LR. Inhibitory activity of honey against foodborne pathogens as influenced by the presence of hydrogen peroxide and level of antioxidant power. *Int J Food Microbiol.* 2001; 69(3):217-25. [https://doi.org/10.1016/S0168-1605\(01\)00505-0](https://doi.org/10.1016/S0168-1605(01)00505-0)
35. Gheldof N, Wang XH, Engeseth NJ. Identification and quantification of antioxidant components of honeys from various floral sources. *J Agric Food Chem.* 2002; 50(21):5870-7. <https://doi.org/10.1021/jf0256135> PMID:12358452
36. Rodgers KE, Verco SJ, diZerega GS. Effects of intraperitoneal 4% icodextrin solution on the healing of bowel anastomoses and laparotomy incisions in rabbits. *Colorectal Dis.* 2003; 5(4):324-30. <https://doi.org/10.1046/j.1463-1318.2003.00447.x> PMID:12814410
37. Beck DE, Cohen Z, Fleshman JW, et al. A prospective, randomized, multicenter, controlled study of the safety of Seprafilm adhesion barrier in abdominopelvic surgery of the intestine. *Dis Colon Rectum.* 2003; 46(10):1310-9. <https://doi.org/10.1007/s10350-004-6739-2> PMID:14530667
38. Van Oosterom FJ, van Lanschot JJ, Oosting J, Obertop H. Hyaluronic acid/carboxymethylcellulose membrane surrounding an intraperitoneal or subcutaneous jejunojunostomy in rats. *The European journal of surgery.* 2000; 166(8):654-8. <https://doi.org/10.1080/110241500750008349> PMID:11003437
39. Erturk S, Yuceyar S, Temiz M, et al. Effects of hyaluronic acid-carboxymethylcellulose antiadhesion barrier on ischemic colonic anastomosis: an experimental study. *Dis Colon Rectum.* 2003; 46(4):529-34. <https://doi.org/10.1007/s10350-004-6594-1> PMID:12682549
40. Lusby PE, Coombes A, Wilkinson JM. Honey: a potent agent for wound healing? *J Wound Ostomy Continence Nurs.* 2002; 29(6):295-300. <https://doi.org/10.1097/00152192-200211000-00008> PMID:12439453