

REVIEW ARTICLE

Speculative Considerations about Some Cardiology Enigmas

Paulo Roberto Barbosa Evora^{*}, André' Schmidt, Livia Arcêncio and José Antonio Marin-Neto

Department of Surgery and Anatomy (Division of Cardiothoracic Surgery); Department of Medicine (Division of Cardiology); Ribeirão Preto School of Medicine, University of São Paulo, SP, Brazil

Abstract: Background: Enigmas often lead to hypotheses and speculations. For this reason, especially for the sake of the reader's motivation, we opted for the plain discussion of some cardiology enigmas.

Objective: The present text was aimed to discuss speculatively some cardiology enigmas.

Method: Text was freely designed in the context of coronary artery and heart valve diseases.

Results: The results were presented as the combination enigma/hypothesis. 1) The absence of arteriosclerosis in intramyocardial coronary arteries/ endothelium-myocardial interaction (crosstalk); 2) The unique and always confirmed superior evolution of the internal thoracic artery as coronary graft/ higher NO basal release 3) The prophylactic left internal thoracic artery graft in mildly-stenosed coronary lesions/need of more accurate functional imaging techniques; 4) The high incidence of perioperative atrial fibrillation in patients with coronary artery disease/atrial ischemia associated to left circumflex coronary lesions; 5) The handling of disease-free saphenous vein grafts at the time of reoperation/biological serendipity with graft vein segments; 6) The possible aortic stenosis protection against coronary artery disease/ endothelium-myocardium interaction (crosstalk) improving NO release.

Conclusion: The discussed topics associated with their respective speculative hypothesis remain as enigmas, but would become motivations for investigations

Keywords: Coronary artery disease, heart valve disease, controversies, cardiology enigmas, arteriosclerosis, atrial fibrillation.

ARTICLE HISTORY

Received: January 24, 2017
Revised: March 03, 2017
Accepted: March 08, 2017

DOI:
10.2174/1573403X13666170317121721

1. INTRODUCTION

The English language dictionaries refer "ENIGMA" as "a perplexing data that is often ambiguous and inexplicable, something like a puzzle or riddle". Also, the dictionary completes this definition discussing that an enigma remains a mystery as the paradox contained in it is often difficult to understand. An enigma may refer to a puzzling situation or occurrence that is mostly inexplicable. Otherwise, enigmas often lead to hypotheses and speculations. For this reason, especially for the sake of the reader's motivation, we opted for the clear discussion of some cardiology enigmas in the context of CAD and heart valve disease (Table 1), with the particular hypotheses raised for better understanding.

2. CORONARY ARTERY DISEASE (CAD)

Concerning the CAD, five well-recognized enigmas will be discussed: 1) The absence of arteriosclerosis in intramyocardial coronary arteries; 2) The unique and always confirmed superior evolution of the left internal thoracic artery as coronary graft; 3) The prophylactic left internal thoracic artery graft in mildly-stenosed coronary lesions, and; 4) The high incidence of perioperative AF in patients with CAD, and; 5) The handling of disease-free saphenous vein grafts (SVG) at the time of reoperation.

*Address correspondence to this author at the Department of Surgery and Anatomy, Ribeirão Preto School of Medicine, University of São Paulo, Av. Bandeirantes, 3900 - Monte Alegre - CEP: 14049-900 Ribeirão Preto/SP, Brazil; Fax: +55 16 3602-2497; E-mail: prbevora@gmail.com

Table 1. Cardiology hypotheses.

| <u>CORONARY ARTERY DISEASE</u> |
|---|
| <ul style="list-style-type: none"> The absence of arteriosclerosis in intramyocardial coronary arteries - endothelium-myocardial interaction (crosstalk) ? |
| <ul style="list-style-type: none"> The unique and always confirmed superior evolution of the internal thoracic artery as coronary graft – Higher NO basal release? |
| <ul style="list-style-type: none"> The prophylactic left internal thoracic artery graft in mildly-stenosed coronary lesions - Need of more accurate functional imaging techniques ? |
| <ul style="list-style-type: none"> The high incidence of perioperative atrial fibrillation in patients with coronary artery disease – atrial ischemia associated to left circumflex coronary lesions? |
| <ul style="list-style-type: none"> The handling of disease-free saphenous vein grafts at the time of reoperation – “Biological serendipity with graft vein segments?” |
| <u>HEART VALVE DISEASE</u> |
| <ul style="list-style-type: none"> Symptoms and acute pulmonary edema independent of the mitral stenosed area and hemodynamic changes – alveoli/capillary membrane not affected during the rheumatic crisis. |
| <ul style="list-style-type: none"> The possible aortic stenosis protection against coronary artery disease - endothelium-myocardial interaction (crosstalk) improving NO release. |

3. THE ABSENCE OF ARTERIOSCLEROSIS IN INTRAMYOCARDIAL CORONARY ARTERIES

Geiringer [1] described approximately 60 years ago, the "myocardial bridge" and the wall thickness differences of intramyocardial arteries and other coronary arteries. However, the most intramyocardial coronaries are free from arteriosclerosis, while the epicardial portions are severely involved, have been poorly discussed and investigated [2- 4].

Several studies show that portions of intramyocardial coronary arteries are spared of arteriosclerosis, involving embryological, morphological, biochemical and pathophysiological aspects (Figs. 1 and 2).

Endothelial function is significantly modified in the segment of transition, as detected by the abnormal vasoactive response to acetylcholine (Ach). These findings suggest that myocardial bridging can provide protection mechanisms against arteriosclerosis by counteracting the adverse endothelial dysfunction effects. This protective phenomenon deserves further scientific research. Improved morphological, biomechanical and especially a deeper embryological knowledge may be the key to a future window

of opportunity for chronic arterial disease therapy and prevention [5].

4. THE SUPERIOR EVOLUTION OF THE LEFT INTERNAL THORACIC ARTERY AS A CORONARY GRAFT

The main advantages of coronary artery surgical revascularization or coronary artery bypass graft (CABG) using the left internal thoracic artery (LITA) have been well established since the 80s and can be enumerated as follows: 1) Increased long-term patency, undoubtedly demonstrated; 2) Improved resistance to atherosclerosis probably based on the endothelial production of nitric oxide and prostacyclin; 3) In contrast to the venous bypass, it has been used not only for *in situ* pedicle grafts but also as free graft; 4) Improved clinical outcomes (various studies have shown the positive influence of LITA graft avoiding the recurrence of angina, nonfatal myocardial infarction, and favoring prolonged survival, and; 5) Less need for reoperations (a 50% lower incidence of reoperations), and 6) LITA has the capacity of flow adaptation according to the myocardial metabolic necessities, and it has a "hibernating" capacity, protecting against CAD [6].

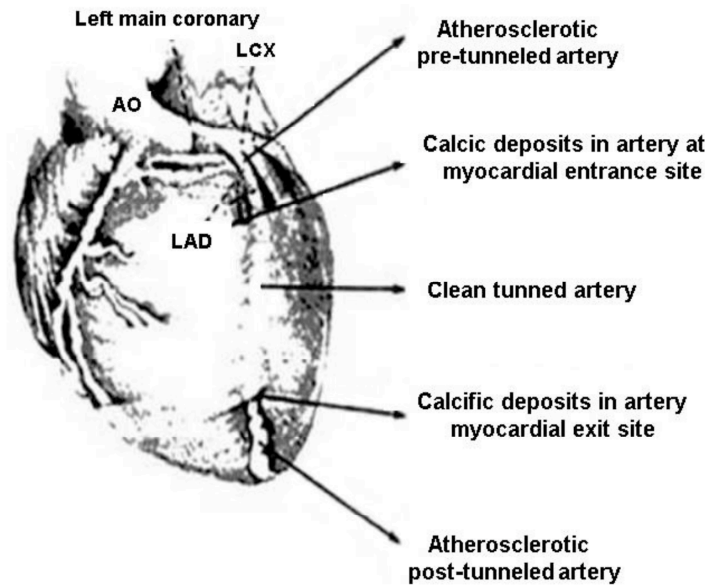


Fig. (1). Major anatomopathological aspects (Ref 5: Rev Bras Cir Cardiovasc 2011; 26: 440-6).

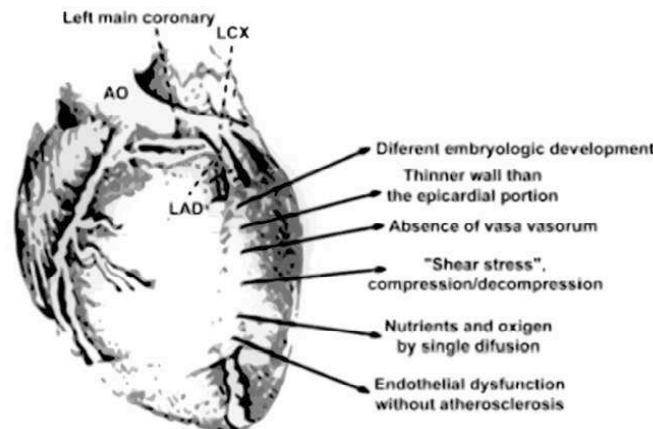


Fig. (2). Major anatomic functional and embryological aspects (Ref 5: Rev Bras Cir Cardiovasc 2011; 26: 440-6).

5. THE “PROPHYLACTIC” LEFT INTERNAL THORACIC ARTERY GRAFT IN MILDLY-STENOSED CORONARY LESIONS

It has been well established that coronary venous grafts in arteries with moderate atherosclerotic lesions (<70%) had early occlusion mainly due to flow competition with the antegrade flow in the native coronary circulation. Thus, to graft a moderately stenosed coronary vessel with LITA remains debatable, keeping the question proposed by Hayward and colleagues open: "Should all moderate coronary lesions be grafted during primary coronary bypass surgery?" [7]. Moreover, controversy exists whether LITAs should be used to bypass coronary arteries with noncritical stenosis. In a recent editorial, we discussed this controversy concluding that all moderate coronary lesions would be LITA grafted during primary coronary bypass surgery, but always considering that the LITA graft occlusion due to flow competition would prevent the possibility of future use in an eventual CABG reoperation. Nowadays, the notion of a prophylactic LITA on a mildly-stenosed LAD is not confirmed yet by clinical evidence [8].

Hypothesizing that LITA is biologically "special" due to a unique endothelium function, we bioassayed, blindly, left and right canine arteries with and without endothelium (n=20). Vasoactive properties of the effluent were bioassayed on canine coronary artery smooth muscle. In 83% of the superfusion experiments, effluent from the LITA induced greater relaxation of the bioassay ring than did effluent from the right internal thoracic artery (RITA) (Fig. 3). However, in "organ chamber" in vitro experiments, right and left ITAs exhibited comparable endothelium-dependent vasorelaxation to Ach. Nitric oxide induces vasodilatation and also inhibits platelet adhesion, platelet aggregation, and atherogenesis. Hence the ITA luminal release of NO can contribute to superior results when the artery is used in bypass grafts. The LITA has different embryologic origin than RITA, but it is unknown if this fact is causally related to the LITA coronary "gold standard" for surgical myocardial revascularization [9].

6. THE HIGH INCIDENCE OF PERIOPERATIVE ATRIAL FIBRILLATION IN PATIENTS WITH CORONARY ARTERY DISEASE

Knowledge about the risk factors for postoperative AF seems to have a fundamental importance in the elaboration of prophylactic and therapeutic measures for this arrhythmia.

Age is the most cited risk factor in the literature, probably due to the higher content of atrial collagen in elderly patients (> 70 years). Other factors reported in the literature include chronic obstructive pulmonary disease, mitral valvular disease, use of inotropic agents, previous history of AF, and pericarditis [10]. Atrial fibrillation in patients with CAD has led Hod and colleagues to hypothesize that the early transient AF, during evolving myocardial, is a consequence of impaired left atrial perfusion. This reduced perfusion would be caused by proximal left circumflex artery occlusion [11].

The high incidence of perioperative AF in patients under cardiac surgery led us to verify, retrospectively, the possible left circumflex artery disease association with the atrial arrhythmias. We studied 186 consecutive patients undergoing coronary artery bypass grafting and reported an AF incidence of 6.04% (11 cases). In these eleven patients, the left circumflex artery was involved in 81.20%, a percentage greater than ventricular arrhythmias incidence. These numbers are compatible with Hod's hypothesis [12, 13].

7. THE HANDLING OF DISEASE-FREE SVG AT THE TIME OF REOPERATION

The replacement of old vein grafts at the date of redo operations is another controversial dilemma. Routine replacement of all SVGs, which are beyond 5 years of age at the time of reoperation, despite their angiographic appearance, has been an accepted practice in many institutions [14]. Grondin wrote a critical editorial with a more conservative view, discouraging the replacement of angiographically normal grafts after 5 years by another vein segment [15] noted that although in general, graft disease afflicts 75% of grafts during the first decade, there is a subgroup of patients who have pristine-looking grafts at a new catheterization after 5 years, and often even after 10 years [14]. An observational study also questioned the policy of universal replacement of vein grafts during reoperation from a clinical standpoint: there was no disadvantage in terms of operative survival, angina relief, incidence of late myocardial infarction, cardiac readmission, or long-term survival for patients who did not have original vein grafts replaced at the reoperation [16]. Furthermore, additional evidence has shown no clinical disadvantages, and even advantages, of not replacing angiographically pristine grafts at long-term follow-up. Measurement of nitric oxide release in old SVG, when angiographically pristine, shows similar values to that of the na-

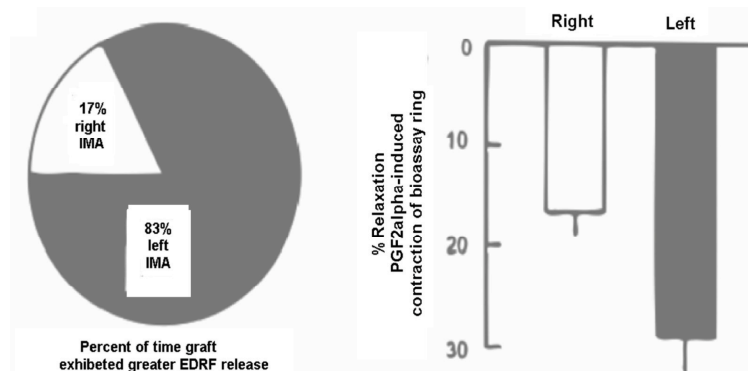


Fig. (3). Comparison of endothelium-derived relaxing factor (EDRF) release from left versus right internal thoracic arteries (Ref 9: Ann Thorac Surg 1992; 54: 1078-84).

tive saphenous vein. These findings support the more recent clinical observations that long-term angiographically disease-free vein grafts are 'biologically privileged,' and should indeed not be routinely replaced [14]. Bilfinger and colleagues presented an interesting discussion based on valuable data on this subject. Moreover, they highlighted the paucity of information concerning the handling of disease-free SVG at the time of redo CABG [17]. Of note, current guidelines do not discuss the handling of disease-free SVG at the date of reoperation. However, solving this dilemma would be critical to non-interventional cardiologists, interventional cardiologists, cardiac surgeons, and patients as well.

8. CARDIAC VALVE DISEASE

8.1. Acute Pulmonary Edema Independent of the Area of the Mitral Stenosis

Mitral stenosis is an extensively studied heart defect over the years, but still, presents many facts whose understanding is controversial. We conducted research in the eighties, including 20 patients with isolated rheumatic mitral stenosis, to contribute to better understanding of its pathophysiology [18, 19]. Perhaps one of the greatest and oldest enigmas of Cardiology is the reason why some young patients present acute pulmonary edema as the first sign of mitral stenosis (i.e. without previous symptoms of effort dyspnea, orthopnea), while many other patients with significant similar hemodynamic changes and severity of mitral stenosis are chronically symptomatic. In the evolution of acute rheumatic fever, the pulmonary infiltrates occurrence is often considered a manifestation of pulmonary congestion, unrelated

bacterial or viral pneumonitis, infarction or atelectasis. These interpretations are undoubtedly correct in some cases, but cannot apply to all cases. Since the pathological process in acute rheumatic fever is known to be diffuse, being capable of the vascular system and connective tissue involvement in an extensive organ system, the case of rheumatic pneumonitis may be logically advanced in such situations [20]. It is known that structural alveolar-capillary membrane changes tend to prevent pulmonary edema, but a full explanation for this fact has not yet been presented [21]. These background data, taken together, provided the basis for our medical hypothesis: The occurrence of acute pulmonary edema in mitral stenosis is related to the lowest degree of pneumonitis during acute rheumatic fever manifestations. With less inflammatory reaction affecting the alveolar-capillary membrane, the occurrence of acute pulmonary edema would be facilitated by an even smaller increase in pulmonary capillary pressure caused by physical effort. Otherwise, as in most cases of acute rheumatic fever, pneumonia occurs with inflammation, causing the alveolar-capillary membrane thickening that protects against the acute lung edema (Fig. 4) [22].

8.2. The Possible Aortic Stenosis Protection Against Coronary Artery Disease

Angiographic studies have shown that the prevalence of significant CAD in patients with aortic stenosis (AS) varies from 20 to 60%. From 2005 to 2015, 261 patients received aortic valve prosthesis associated or not with myocardial revascularization at Ribeirão Preto School of Medicine, University of São Paulo SP, Brazil (patients with isolated aortic valve stenosis, after excluding congenital aortic stenosis and

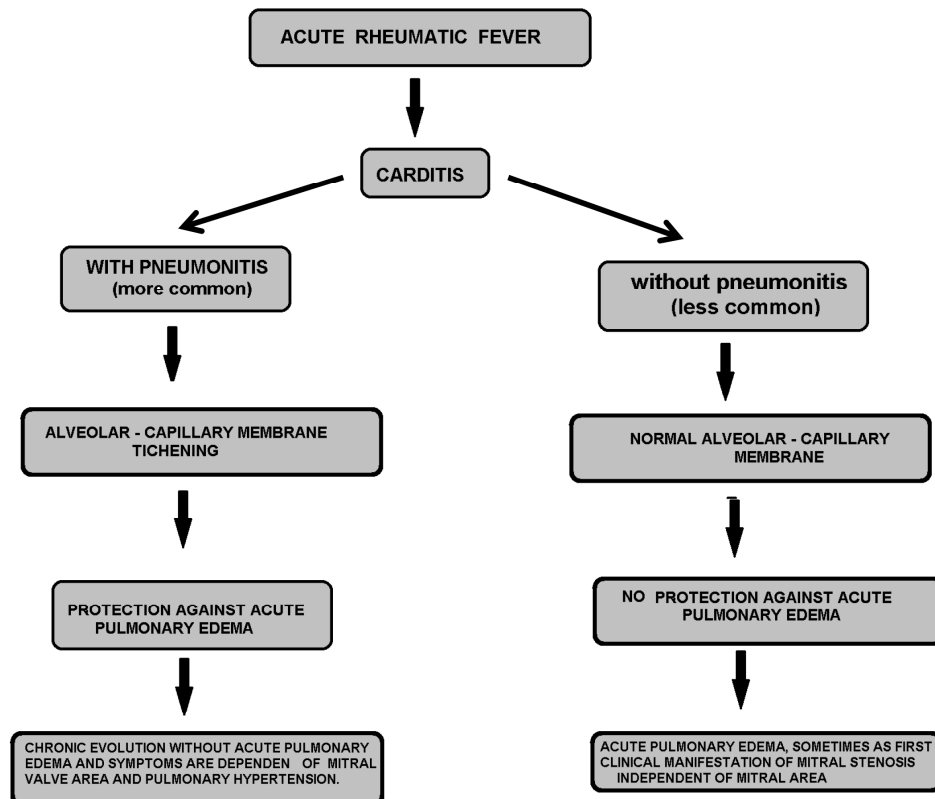


Fig. (4). Mitral stenosis acute pulmonary edema and rheumatic fever pneumonitis hypothesis. [22].

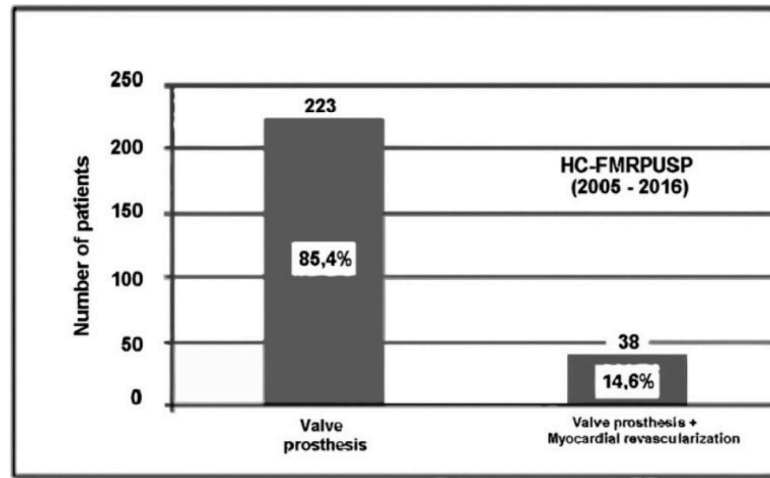


Fig. (5). Aortic valve prosthesis associated or not with myocardial revascularization at Ribeirão Preto School of São Paulo, University of São Paulo SP, Brazil (2005 - 2015) (isolated aortic valve stenosis, after excluding congenital aortic stenosis and bicuspid aortic valve). (Ref 23: Arq Bras Cardiol 2016; 106: 338-41).

bicuspid aortic valve). Only 38 (14,6%) patients had an association of myocardial revascularization (Fig. 5). This low incidence is suggestive about the AS protection against CAD, and this hypothesis can be based on some key points clearly established: 1) Necropsy studies are compatible with lower CAD incidence in patients with AS; 2) CAD is present in 85% of patients with angina and mitral valve disease, but in only 33% of patients with angina and aortic valve disease; 3) The American College of Cardiology and the American Heart Association guidelines minimize the importance of myocardial revascularization at the time of surgical AVR, keeping the indication for revascularization lesions greater than 70% but not for 50% of 70% stenotic lesions; 5) Transcatheter aortic valve implantation (TAVI) changed the guidelines for AS in patients with high comorbidity, without any rule about CABG in the presence of moderate CAD. While CABG may favorably influence the long-term outcome in patients undergoing aortic prosthesis surgery, however, this information is not yet applicable to TAVI, because the profile of its long-term outcome is still unknown. This information is crucial, considering the advent of transcatheter valves [23].

CONCLUSION

The enigma of AS protection against CAD would be better explained by an endothelium/myocardial interaction (crosstalk) triggered by the left ventricular overload, inducing the cGMP/NO pathway. This hypothesis would explain the low incidence of CAD, which is compatible with the incredibly natural long-term AS evolution [23]. This theory is illustrated in Fig. (6), and its keys point would be summarized: 1) Increased coronary diameters are systematically observed in association with ventricular hypertrophy secondary to aortic valve disease and chronic systemic hypertension; 2) In patients with AS, right coronary artery dimensions remain unchanged, while left ventricle hypertrophy is associated with an increase in left coronary dimensions; 3) When left ventricle hypertrophy severity increases, coronary artery size increase would be insufficient, and; 4) After valve replacement, the enlarged left coronary artery size decreases at an equal rate with the muscle mass regression [23].

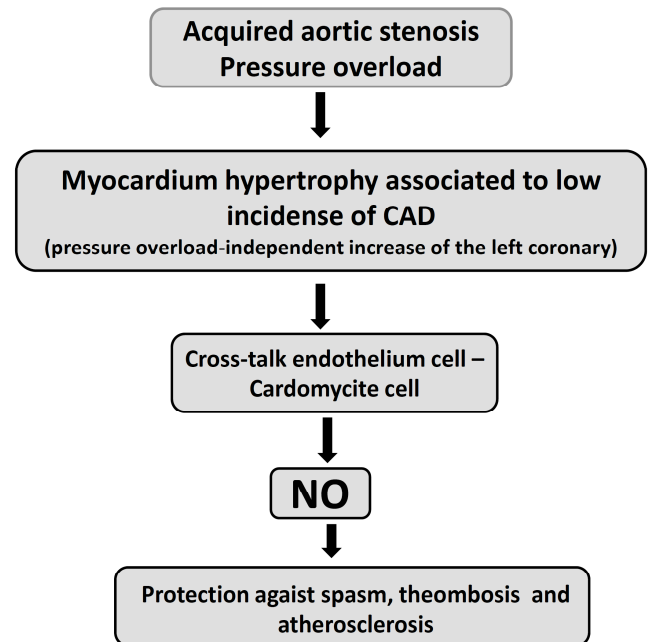


Fig. (6). Physiopathological suggestion explanation for the small incidence of coronary artery disease and long natural history (> 50 years without symptoms) in patients with acquired aortic valve stenosis. (Ref 23: Arq Bras Cardiol. 2016; 106:338-41).

GRANTS

Conselho Nacional Pesquisa Desenvolvimento-Brasil CNPq (474439/2013-5).

CONFLICT OF INTEREST

The authors confirm that this article content has no conflicts of interest.

ACKNOWLEDGEMENTS

Declared none.

REFERENCES

- [1] Geringer E. The mural coronary. *Am Heart J* 1951; 41: 359-68.
- [2] Botta DMJ, Elefteriades JA. Why are the intramyocardial portions of the coronary arteries spared from arteriosclerosis: Clinical implications. *Int J Angiol* 2009; 18: 59-61.
- [3] Scher AM. Absence of atherosclerosis in human intramyocardial coronary arteries: a neglected phenomenon. *Atherosclerosis* 2000; 149: 1-3.
- [4] Robicsek F, Thubrikar MJ. The freedom from atherosclerosis of intramyocardial coronary arteries: reduction of mural stress - a key factor. *Eur J Cardiothorac Surg* 1994; 8: 228-35.
- [5] Ramalli EL Jr, Braga LH, Evora PM, *et al.* The absence of arteriosclerosis in intramyocardial coronary arteries: a mystery to be solved? *Rev Bras Cir Cardiovasc* 2011; 26: 440-6.
- [6] Evora PR, Ribeiro PJ, Brasil JC. Myocardial revascularization and internal thoracic artery. *Arq Bras Cardiol* 1987; 49: 129-31..
- [7] Evora PR, Arcêncio L, Schmidt A, Rodrigues AJ. Prophylactic left internal thoracic artery graft in mildly-stenosed coronary lesions. still an open discussion. *Arq Bras Cardiol* 2016; 106: 168-70.
- [8] Pearson PJ, Evora PR, Schaff HV. Bioassay of EDRF from left internal thoracic arteries: implications for early and late bypass graft patency. *Ann Thorac Surg* 1992; 54: 1078-84.
- [9] Amar D, Zhang H, Leung DH, Roistacher N, Kadish AH. Older age is the strongest predictor of postoperative atrial fibrillation. *Anesthesiology* 2002; 96: 352-6.
- [10] Hod H, Lew AS, Keltai M, *et al.* Early atrial fibrillation during evolving myocardial infarction: a consequence of impaired left atrial perfusion. *Circulation* 1987; 75: 146-50.
- [11] Sgarbieri RN, de Freitas JN, Evora PR, *et al.* Postoperative atrial fibrillation in myocardial revascularization. *Arq Bras Cardiol* 1989; 52: 19-22.
- [12] Tinel M. Atrial fibrillation and cardiac surgery: a never ending and always controversial history. *Braz J Cardiovasc Surg* 2005; 20: 323-31.
- [13] Marshall WG Jr, Saffitz J, Kouchoukos NT. Management during reoperation of aortocoronary saphenous vein grafts with minimal atherosclerosis by angiography. *Ann Thorac Surg* 1986; 42: 163-7.
- [14] Grondin CM. The removal of still functioning albeit old grafts: not in our genes? *Ann Thorac Surg* 1986; 42: 122-3.
- [15] Mehta ID, Weinberg J, Jones MF, *et al.* Should angiographically disease-free saphenous vein grafts be replaced at the time of redo coronary artery bypass grafting? *Ann Thorac Surg* 1998; 65: 17-22; discussion 22-3.
- [16] Bilfinger TV, Vosswinkel JA, Rialas CM, Krukenkamp IB, Stefano GB. Functional assessment of disease-free saphenous vein grafts at redo coronary artery bypass grafting. *Ann Thorac Surg* 2000; 69: 1183-7.
- [17] Evora PR, Vichi FL, Mori LE, Romero LC, Otaviano AG, Sader AA. The mitral valve area and physical capacity determined by the cycloergometric test in patients with mitral stenosis. *Arq Bras Cardiol* 1982; 38: 193-7.
- [18] Evora PR, Manço JC, Marin-Neto JA, *et al.* Correlation of intraoperative measurement of the functional valve area with clinical and hemodynamic parameters in patients with mitral stenosis. *Arq Bras Cardiol* 1982; 38: 91-8.
- [19] Lukas DS, Dotter CT. Modifications of the pulmonary circulation in mitral stenosis. *Am J Med* 1952; 12: 639-49.
- [20] Araujo J, Lukas DS. Interrelationships among pulmonary capillary pressure, blood flow and valve size in mitral stenosis; the limited regulatory effects of the pulmonary vascular resistance. *J Clin Invest* 1952; 31: 1082-8.
- [21] Evora PR, Evora PM, Capellini VK, Celotto AC. Mitral stenosis acute pulmonary edema and rheumatic fever pneumonitis: a hypothesis to an old enigma. *Int J Cardiol* 2011; 151: 365-6.
- [22] Evora PR, Arcêncio L, Rodrigues AJ, Schmidt A. Protective effect of aortic stenosis on the coronary arteries. Hypothetic considerations to an old enigma. *Arq Bras Cardiol* 2016; 106: 338-41.
- [23] Evora PR, Arcêncio L, Rodrigues AJ, Schmidt A. Protective effect of aortic stenosis on the coronary arteries. Hypothetic considerations to an old enigma. *Arq Bras Cardiol* 2016; 106(4): 338-41.