

## Poly (ADP-ribose) polymerase 1 protein expression in normal and neoplastic prostatic tissue

M. Salemi,<sup>1</sup> A. Galia,<sup>2</sup> F. Fraggetta,<sup>2</sup>  
C. La Corte,<sup>2</sup> P. Pepe,<sup>3</sup> S. La Vignera,<sup>1</sup>  
G. Improta,<sup>4</sup> P. Bosco,<sup>5</sup> A.E. Calogero<sup>1</sup>

<sup>1</sup>Section of Endocrinology, Andrology and Internal Medicine, Department of Medical and Pediatric Sciences, University of Catania, Italy; <sup>2</sup>Pathology Unit, Cannizzaro Hospital, Catania, Italy; <sup>3</sup>Urology Unit, Cannizzaro Hospital, Catania, Italy; <sup>4</sup>Laboratory of Clinical Research and Molecular Diagnostics, IRCCS-CROB Hospital, Rionero in Vulture, PT, Italy; <sup>5</sup>Laboratory of Cytogenetics, Oasi Institute for Research on Mental Retardation and Brain Aging, Troina, EN, Italy

### Abstract

A genetic background has been implicated in the development of prostate cancer. Protein microarrays have enabled the identification of proteins, some of which associated with apoptosis, that may play a role in the development of such a tumor. Inhibition of apoptosis is a co-factor that contributes to the onset and progression of prostate cancer, though the molecular mechanisms are not entirely understood. Poly (ADP-ribose) polymerase 1 (*PARP-1*) gene is required for translocation of the apoptosis-inducing factor (AIF) from the mitochondria to the nucleus. Hence, it is involved in programmed cell death. Different *PARP-1* gene expression has been observed in various tumors such as glioblastoma, lung, ovarian, endometrial, and skin cancers. We evaluated the expression of PARP-1 protein in prostatic cancer and normal prostate tissues by immunohistochemistry in 40 men with prostate cancer and in 37 normal men. Positive nuclear PARP-1 staining was found in all samples (normal prostate and prostate cancer tissues). No cytoplasmic staining was observed in any sample. PARP-1-positive cells resulted significantly higher in patients with prostate carcinoma compared with controls ( $P < 0.001$ ). *PARP-1* over-expression in prostate cancer tissue compared with normal prostate suggests a greater activity of *PARP-1* in these tumors. These findings suggest that PARP-1 expression in prostate cancer is an attempt to trigger apoptosis in this type of tumor similarly to what reported in other cancers.

### Introduction

Prostate cancer (PCa) is one of the most commonly diagnosed male malignancies; some of them are slow growing, whereas others are more aggressive.<sup>1</sup> Many factors, including genetics, have been implicated in the development of PCa.<sup>2</sup> Men who have a brother or father with PCa have twice the risk of developing PCa.<sup>3,4</sup> Cancer cells may metastasize from the prostate to other parts of the body, particularly the bones and lymph nodes. Moreover, there is a significant number of men who require systemic therapy and ongoing surveillance for advanced PCa.<sup>5</sup> Therefore, genetic studies of this disease and new therapeutic strategies are urgently needed for the prevention and the treatment of PCa.

Apoptosis is a programmed cell death process that takes place under normal physiological and pathological conditions. Inhibition of apoptosis is a critical pathophysiological factor that contributes to the onset and progression of PCa, but the molecular mechanisms are not entirely understood. Therefore, insight into the mechanism(s) of an abnormal apoptosis regulation may be the basis for developing more effective therapeutic approaches to destroy apoptosis-resistant tumor cells, as those found in PCa.<sup>6,7</sup>

Poly (ADP-ribose) polymerase 1 (*PARP-1*) gene is located to 1q42; it is 43 kb long and is split into 23 exons (OMIM 173870). PARP-1 is a chromatin associated enzyme that participates to cell cycle regulation, transcription, tumorigenesis, and cellular response to DNA damage.<sup>8-10</sup> PARP-1 has an important roles in DNA base excision repair (BER), acting as a nick sensor, and modulator of key DNA repair molecules.<sup>11</sup> Upon activation, PARP-1 synthesizes poly (ADP-ribose) (PAR) using nicotinamide adenine dinucleotide (NAD<sup>+</sup>) as a substrate and covalently transfers PAR to nuclear proteins, including nucleosomal core histones, topoisomerases I and II, high mobility group (HMG) proteins, and p53.<sup>12</sup> Genetic and pharmacological studies have shown that *PARP-1* overexpression is a key mediator of programmed-necrotic cell death *in vivo*. Furthermore, *PARP1* is required for translocation of the apoptosis-inducing factor (AIF) from the mitochondria to the nucleus<sup>13</sup> and it is proteolytically cleaved at the onset of apoptosis by CASP3.<sup>13</sup> *PARP-1* appears to be also involved in programmed cell death processes, such as apoptosis or macroautophagocytotic cell death.<sup>13</sup> Analysis of *PARP-1* gene expression showed that *PARP-1* is highly expressed in several types of tumors including prostate cancer, colorectal cancer, pancreatic cancer, hepatocellular carcinoma, cutaneous malignant melanomas, and glioblastoma multi-

Correspondence: Dr. Michele Salemi, Section of Endocrinology, Andrology and Internal Medicine, Department of Medical and Pediatric Sciences, University of Catania, via S. Sofia 78, 95123 Catania, Italy.  
E-mail: micezia@tiscali.it

Key words: prostate cancer, *PARP-1* gene, protein expression, immunohistochemistry.

Received for publication: 13 December 2012.  
Accepted for publication: 4 February 2013.

This work is licensed under a Creative Commons Attribution NonCommercial 3.0 License (CC BY-NC 3.0).

©Copyright M. Salemi et al., 2013  
Licensee PAGEPress, Italy  
European Journal of Histochemistry 2013; 57:e13  
doi:10.4081/ejh.2013.e13

forme.<sup>13-19</sup> The present study was undertaken to evaluate the expression of PARP-1 protein by immunohistochemistry in normal prostate tissues and in prostate cancer according to their Gleason score. The Gleason score system, in addition to other parameters, is used to evaluate the prognosis of men with prostate cancer and to guide the treatment. A Gleason score is given to prostate cancer based upon its microscopic appearance.<sup>20</sup> Cancers with higher Gleason score are more aggressive and have a worse prognosis.

### Materials and Methods

#### Patient and control prostate samples

The study included 40 cases of PCa with different Gleason score, and 37 cases of normal prostatic tissues (6 prostates removed by *post mortem* autopsy in normal donors and 31 prostatic biopsies). The diagnosis and grading of PCa was made according to the 2005 International Society of Urological Pathology (ISUP) Consensus Conference,<sup>21</sup> by two different pathologists (AG and FF). The protocol was approved by the internal Institutional Review Board and an informed written consent was obtained from each patient with PCa or, if deceased, by his/her relatives.

#### Immunohistochemical staining

Prostate section (4  $\mu$ m thick) were obtained from all normal donors and PCa patients. All sections were formalin-fixed and paraffin-embedded following standard methods.

PARP-(F-2), a mouse monoclonal antibody raised against human PARP-1 protein, was used for immunohistochemistry (Santa Cruz

Biotechnology, Inc., Heidelberg, Germany). As indicated by the manufacturer instructions, this antibody, at the dilution of 1:300, has been shown to reliably recognize PARP-1 proteins in PCa and normal prostate by immunohistochemistry. Slides were deparaffinized, rehydrated, subjected to three 5 min cycles in a microwave at 360 W in citrate buffer, preincubated in 3% H<sub>2</sub>O<sub>2</sub> in citrate buffer, and thoroughly washed in 50 mM Tris-Cl (pH 7.4), 150 mM NaCl Tris buffered saline (TBS) containing 0.05% Tween 20 (washing buffer). Slides were then pre-incubated with 3% bovine serum albumin (BSA) in TBS for 30 min, incubated with 1:300 dilution of anti-PARP-1 antibody in TBS containing 1% BSA, thoroughly washed in washing buffer before detection with the LSAB 2 kit (anti mouse, biotinylated and peroxidase-labeled streptavidin) and 3,3'-diaminobenzidine-4HCl (DAB; Dako, Carpinteria, CA, USA) following the instructions contained in the kit. After detection, the sections were counterstained with haematoxylin, dehydrated and mounted in xylene-based DPX mountant (BDH, Pool, UK).<sup>22</sup>

### Microscopic evaluation

Slides were observed and cells visually scored at 10x, 20x, and 40x. To evaluate the percentage of positive tumor cells, at least 500 cells were analyzed for each prostate cancer and normal prostate tissue. PARP-1 positive cells were evaluated independently in a blinded fashion by two observers (GA and SM). No significant difference was observed between the two observers.

### Statistical analysis

Results are reported as mean±SEM. Data were analyzed by Student's *t*-test or 1-way analysis of variance (ANOVA) followed by the Duncan's Multiple Range test. The statistical significance was accepted when the P value was lower than 0.05.

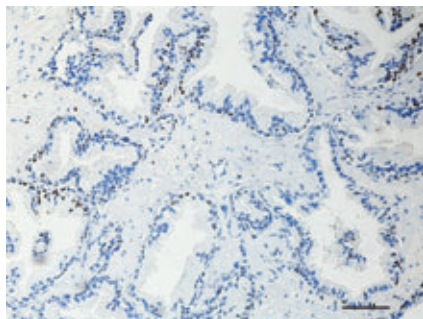


Figure 1. Immunohistochemistry of normal prostate. Hematoxylin counterstain; scale bar: 80 μm.

## Results

Patients with prostate carcinoma had a mean of 69.3±8.0 years, which did not differ significantly from controls (73.0±9.0 years). Immunohistochemical analysis of paraffin-embedded sections revealed a strong nuclear signals for PARP-1 staining in both normal and prostate carcinoma cells. No cytoplasmic staining was observed in any sample of both groups (Figure 1; Figure 2A,B). The percentage of PARP-1-positive cells resulted significantly higher in patients with prostate carcinoma compared with controls ( $P<0.001$ , Student's *t*-test) (Figure 3). According to the Gleason score, the percentage of cells with positive nuclear PARP-1 staining resulted significantly higher than controls compared to that observed in patients with Gleason scores of 6 (9 cases), 7 (10 cases), 8 (16 cases) or 9 (5 cases) ( $P<0.05$ , ANOVA followed by Duncan test) (Figure 4). In addition, the percentage of PARP-1-positive nuclei in patients with a Gleason score of 8 were significantly higher than that observed in patients with a Gleason score of 6 ( $P<0.05$ , ANOVA followed by Duncan test) (Figure 4).

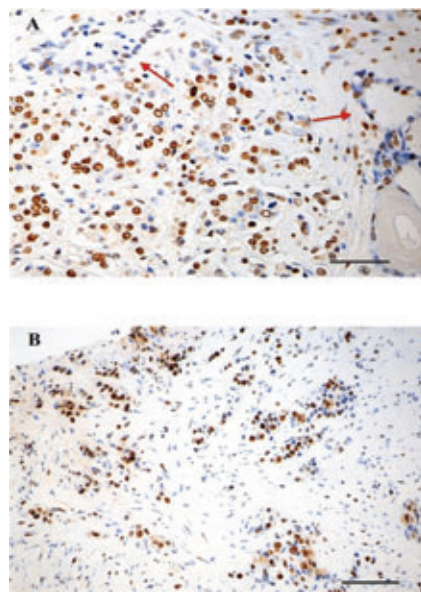


Figure 2. Immunohistochemistry of prostate cancer and normal prostate. A) Prostate cancer Gleason score 8, the red arrows indicate tubules of normal prostate; hematoxylin counterstain; Scale bar: 200 μm. B) Prostate cancer Gleason score 9; hematoxylin counterstain; scale bar: 80 μm.

## Discussion

A significantly higher number in cells expressing PARP-1 proteins in PCa tissues compared with the normal prostate cells confirmed previous studies showing the association of this gene over-expression with tumors.<sup>4</sup> Also, Ossovskaya *et al.* (2010) had already shown a higher PARP-1 mRNA expression in prostate cancer.<sup>13</sup> The greater expression of PARP-1 protein in PCa compared to normal prostate may relate to the its close functional/structural relationship with the factors which favors the activation of the pro-apoptotic mechanisms, suggesting that pro-apoptotic mechanisms may be activated in these tumors.

*PARP-1* gene plays a important role in apoptosis. This may, in part, justify the presence of PARP-1 protein in some tumors, such as non-Hodgkin's lymphomas, breast, ovarian, lung, endometrial and skin cancers.<sup>14</sup> PARP-1 is an abundant, chromatin-associated enzyme present in all eukaryotic cell nuclei, where it plays an important function in the maintenance of genomic integrity and transcriptional control.<sup>14,23</sup> Poly(ADP-ribose) polymerase-1

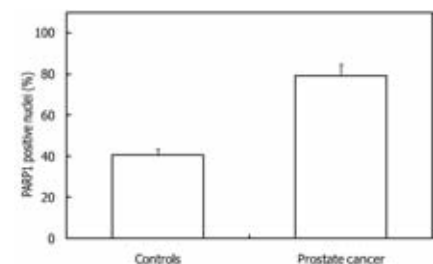


Figure 3. Percentage of PARP-1-positive nuclear signals in cells of prostate cancer and normal prostate (controls).

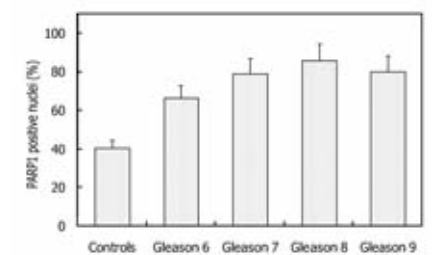


Figure 4. Percentage of PARP-1-positive nuclear signals in cells of prostate cancer (according to Gleason score) and normal prostate (controls).

inhibitor, increases the antitumor activity against glioma, intracranial melanoma, lymphoma, and hematological neoplasias.<sup>24-27</sup> These observations suggest a potential role of *PARP-1* inhibitors in the treatment of PCa. Activation of *PARP-1* gene in response to DNA damage is an important mechanism to maintain the homeostasis or to trigger apoptosis. The function of *PARP-1* has been studied in primary human lung cell cultures from normal human bronchial epithelial cells (NHBE) and peripheral lung cells (PLC) from lung cancer patients grown as explant cultures, over a period of 12 weeks. *PARP-1* protein was expressed in all the cell culture derived from bronchial epithelium explants.<sup>22</sup> Recent data on *PARP-1* agree on the meaning of this gene expression in tumors. Accordingly, the results of this study indicate that *PARP-1* gene may play a role in PCa.<sup>27</sup> In conclusion, *PARP-1* over-expression in prostate cancer tissues compared with normal prostate cells suggests a greater activity of *PARP-1* in these tumors. In addition, *PARP-1* proteins was expressed in a significantly greater number of cells in sample with a greater Gleason score. These findings lead to hypothesize that *PARP-1* protein over-expression in PCa is an attempt to trigger apoptosis in this type of tumor. This conclusion is similar to what already reported in many other cancers.<sup>14</sup>

## References

- Steinberg GD, Carter BS, Beaty TH, Childs B, Walsh PC. Family history and the risk of prostate cancer. *Prostate* 1990;17: 37-47.
- Kucuk O. Chemoprevention of prostate cancer. *Cancer Metastasis Rev* 2002;21: 111-24.
- Jemal A, Siegel R, Ward E, Murray T, Xu J, Thun MJ. Cancer statistics CA. *Cancer J Clin* 2007;57:43-66.
- Trojan L, Kiknaveidze K, Knoll T, Alken P, Michel MS. Prostate cancer therapy: standard management, new options and experimental approaches. *Anticancer Res* 2005;25:551-61.
- Walczak JR, and Carducci MA, Prostate cancer: a practical approach to current management of recurrent disease. *Mayo Clin Proc* 2007;82:243-49.
- Guseva NV, Taghiyev AF, Rokhlin OW, Cohen MB. Death receptor-induced cell death in prostate cancer. *J Cell Biochem* 2004;91:70-9.
- Zornig M, Hueber AO, Baum W, Evan G. Apoptosis regulators and their role in tumorigenesis. *Biochim Biophys Acta* 2001;1551:F1-F37.
- Hassa PO, Hottiger MO. The diverse biological roles of mammalian PARPs, a small but powerful family of poly-ADP-ribose polymerases. *Front Biosci* 2008;13:3046-82.
- Hassa PO, Haenni SS, Elser M, Hottiger MO. Nuclear ADP-ribosylation reaction in mammalian cells: where are we today and where are we going? *Microbiol Mol Biol Rev* 2006;70:789-829.
- Kim MY, Zhang T, Kraus WL. Poly(ADP-ribose)ylation by PARP-1: 'PAR-laying' NAD<sup>+</sup> into a nuclear signal. *Genes Dev* 2005;19:951-67.
- Burke A. Poly(ADP-ribose)ylation, a DNA damage-driven protein modification and regulator of genomic instability. *Cancer Lett* 2001;163:1-5.
- Schreiber V, Dantzer F, Ame JC, de Murcia G. Poly(ADP-ribose): novel functions for an old molecule. *Nat Rev Mol Cell Biol* 2006;7:517-28.
- Ossovskaya V, Koo IC, Kaldjian EP, Alvares C, Sherman BM. Up-regulation of poly(ADP-ribose) polymerase-1 (PARP1) in triple-negative breast cancer and other primary human tumor types. *Genes Cancer* 2010;8:812-21.
- Eustermann S, Videler H, Yang JC, Cole PT, Gruszka D. The DNA-binding domain of human PARP-1 interacts with DNA single-strand breaks as a monomer through its second zinc finger. *J Mol Biol* 2011; 407:149-170.
- Sulzyc-Bielicka V, Domagala P, Hybiak J, Majewicz-Broda A, Safranow K, Domagala W. Colorectal cancers differ in respect of PARP-1 protein expression. *Pol J Pathol* 2012;63:87-92.
- Klauschen F, von Winterfeld M, Stenzinger A, Sinn BV, Budczies J, Kamphues C, et al. High nuclear poly-(ADP-ribose)-polymerase expression is prognostic of imprecise survival in pancreatic cancer. *Histopathology* 2012;61:409-16.
- Shimizu S, Nomura F, Tomonaga T, Sunaga M, Noda M, Ebara M, et al. Expression of poly(ADP-ribose) polymerase in human hepatocellular carcinoma and analysis of biopsy specimens obtained under sonographic guidance. *Oncol Rep* 2004;12:821-25.
- Csete B, Lengyel Z, Kádár Z, Battyáni Z. Poly(adenosine diphosphate-ribose) polymerase-1 expression in cutaneous malignant melanomas as a new molecular marker of aggressive tumor. *Pathol Oncol Res* 2009;15:47-53.
- Galia A, Calogero AE, Condorelli R, Frassetto F, La Corte A, Ridolfo F, et al. PARP-1 protein expression in glioblastoma multiforme. *Eur J Histochem* 2012;56:e9.
- Ro YK, Lee S, Jeong CW, Hong SK, Byun SS, Lee SE. Biochemical recurrence in Gleason score 7 prostate cancer in Korean men: significance of the primary Gleason grade. *Korean J Urol* 2012;12:826-9.
- Epstein JI, Allsbrook WC Jr, Amin MB, Egevad LL, ISUP Grading Committee. The 2005 International Society of Urological Pathology (ISUP) Consensus Conference on Gleason Grading of Prostatic Carcinoma. *Am J Surg Pathol* 2005;1:228-42.
- Salemi M, Calogero AE, Zaccarello G, Castiglione R, Cosentino A, Campagna C, et al. Expression of SPANX proteins in normal prostatic tissue and in prostate cancer. *Eur J Histochem* 2010;54:e41.
- Kannan S, Fang W, Song G, Mullighan CG, Hammitt R, McMurray J. Notch/HES1-mediated PARP1 activation: a cell-type specific mechanism for tumor suppression. *Blood* 2011;117:2891-900.
- Tentori L, Leonetti C, Scarsella M, D'Amati G, Vergati M. Systemic administration of GPI 15427, a novel poly(ADP-ribose) polymerase-1 inhibitor, increases the antitumor activity of temozolomide against intracranial melanoma, glioma, lymphoma. *Clin Cancer Res* 2003;9:5370-9.
- Russo AL, Kwon HC, Burgan WE, Carter D, Beam K, Weizheng X. In vitro and in vivo radiosensitization of glioblastoma cells by the poly (ADP-ribose) polymerase inhibitor E7016. *Clin Cancer Res* 2009; 5:607-12.
- McEllin B, Camacho CV, Mukherjee B, Hahn B, Tomimatsu N. PTEN loss compromises homologous recombination repair in astrocytes: implications for glioblastoma therapy with temozolomide or poly(ADP-ribose) polymerase inhibitors. *Cancer Res* 2010;70:5457-64.
- Ahmad M, Torky A, Glahn F, Scheubel RJ, Foth H. PARP-1 expression and activity in primary human lung cells. *Arch Toxicol* 2011;85:669-79.