

# Clinical Outcomes of Micropulse Transscleral Cyclophotocoagulation: 2 Years of Experience in Portuguese Eyes

Rita C Basto<sup>1</sup>, Júlio Almeida<sup>2</sup>, Joana N Roque<sup>3</sup>, Susana P Henriques<sup>4</sup>, Ana S Gonçalves<sup>5</sup>, Fernando T Vaz<sup>6</sup>, Helena Carvalho<sup>7</sup>, Isabel Prieto<sup>8</sup>

Received on: 16 February 2022; Accepted on: 13 January 2023; Published on: 13 May 2023

## ABSTRACT

**Aim:** This study evaluates the safety and efficacy of micropulse transscleral cyclophotocoagulation (MPTSCPC) in glaucoma patients, with standard parameters, over a 24-month period.

**Methods:** Retrospective analysis of 61 eyes undergoing MPTSCPC from January 2018 to December 2020 was carried out. Patients received 160 seconds of laser, with settings of 2000 mW/cm<sup>2</sup> and a duty cycle of 31.3%.

**Results:** A total of 61 eyes were included, arranged in an age distribution of 73.9 ± 10.8 years. The most frequent diagnosis was primary open-angle glaucoma (POAG), with a mean best-corrected visual acuity (BCVA) of 5/10 in the Snellen Visual chart. Around 37.7% of the eyes had undergone at least one glaucoma filtration surgery prior to MPTSCPC. The mean pretreatment intraocular pressure (IOP) was 24.9 ± 8.6 mm Hg. Except for the contrast at 24 months, at every other follow-up visit, there was a significant reduction ( $p \leq 0.001$ ) in IOP and in the number of topical drugs required to control IOP, from four (baseline) to three, with oral acetazolamide suspension in most cases. The total success rate (absolute and clinical successes combined) was 81.9% after 1 year of the treatment. There was no drop in visual acuity or cases of serious complications. There is a positive and significant correlation between prior glaucoma surgery and the need for reinterventions ( $p = 0.028$ ).

**Conclusions:** Micropulse transscleral cyclophotocoagulation (MPTSCPC) is an effective and safe procedure for reducing IOP within a broad spectrum of glaucoma patients. Additional studies are needed to confirm the current indications, widen their scope, and determine the optimal treatment settings on an individual basis.

**Keywords:** Diode laser, Glaucoma, Goldmann applanation tonometry, Intraocular pressure, Laser therapy, Micropulse transscleral cyclophotocoagulation, Refractory glaucoma, Treat and follow-up of glaucoma.

*Journal of Current Glaucoma Practice* (2023); 10.5005/jp-journals-10078-1395

## INTRODUCTION

The aim of glaucoma treatment is to reduce IOP in order to preserve visual function. The reduction in IOP can be achieved either by increasing the outflow or by decreasing the production of aqueous humor (AH), using glaucoma drugs, laser treatment, or surgery (microinvasive or incisional).<sup>1</sup>

Cyclodestructive procedures (cyclocryocoagulation, cyclotherapy, or continuous cyclophotocoagulation) lower IOP by destructing the ciliary body epithelium and stroma, consequently decreasing AH production.<sup>2,3</sup> These procedures have traditionally been used in eyes with poor visual prognosis or to alleviate refractory glaucoma due to the risk of phthisis, hypotony, visual deterioration, and unpredictability.<sup>2,4,5</sup> These complications are due to the collateral damage of surrounding tissues, mainly the ciliary muscles, nonpigmented epithelium, and ciliary body stroma.<sup>6</sup>

With the advent of MPTSCPC, it is possible to minimize adjacent tissue damage, as previously seen in continuous wave transscleral cyclophotocoagulation (CWTSCPC).<sup>7-9</sup> MPTSCPC utilizes a fractionated continuous wave 810 nm infrared diode laser, which targets the melanin in ciliary body tissues without causing tissue destruction.<sup>4</sup> The laser emission in a 31.3% duty cycle implies that the laser is off 68. Around 7% of the time, thereby allowing thermal dissipation and avoiding focal heating

<sup>1</sup>Department of Surgery, Ophthalmology Service, Unidade Local De Saúde Matosinhos, Hospital Pedro Hispano, Matosinhos, Portugal

<sup>2-6,8</sup>Department of Ophthalmology, Professor Doutor Fernando Fonseca Hospital, Lisboa, Portugal

<sup>7</sup>Department of Social Research Methods, Instituto Universitario de Lisboa (ISCTE-IUL), CIES-IUL, Lisbon, Portugal

**Corresponding Author:** Rita C Basto, Department of Surgery, Ophthalmology Service, Unidade Local De Saúde Matosinhos, Hospital Pedro Hispano, Matosinhos, Portugal, Phone: +351924478033, e-mail: rita.c.basto@gmail.com

**How to cite this article:** Basto RC, Almeida J, Roque JN, *et al.* Clinical Outcomes of Micropulse Transscleral Cyclophotocoagulation: 2 Years of Experience in Portuguese Eyes. *J Curr Glaucoma Pract* 2023;17(1):30-36.

**Source of support:** Nil

**Conflict of interest:** None

and burning of the ciliary body and adjacent tissues.<sup>9,10</sup> Unlike CWTSCPC, ultrasound biomicroscopy, or anterior segment coherence tomography do not demonstrate anatomical changes produced by MPTSCPC.<sup>3,11</sup>

Micropulse transscleral cyclophotocoagulation (MPTSCPC) appears to decrease IOP not only by diminishing the ciliary body's production of AH but also by increasing uveoscleral outflow<sup>12</sup> and

acting as pilocarpine-like (contraction of the longitudinal fibers of the ciliary muscle hence increasing conventional outflow of the AH).<sup>13,14</sup> The MPTSCPC exerts its effect through a combination of the aforementioned modes of action, where one prevails over another depending on the level of energy used.

Micropulse transscleral cyclophotocoagulation (MPTSCPC) shows promising results and lower complication rates, making it attractive to be used as one of the first options in the course of glaucoma treatment. Though, existing evidence is still limited: most studies have a modest sample size, with a short follow-up period; moreover, only a few authors use standard laser settings, which does not allow to establish an agreement on the ideal treatment parameters.<sup>14</sup>

In the present study, the authors evaluate the long-term safety and efficacy profiles of the MPTSCPC treatment with standard laser parameters used in patients diagnosed with several types of glaucoma at different stages of the disease.

## MATERIALS AND METHODS

### Study Design

An observational retrospective non-comparative study of 61 eyes (46 patients) with mild to advanced glaucoma from the Glaucoma Department of the Hospital Professor Doutor Fernando Fonseca EPE [Hospital Fernando Fonseca (HFF), Lisbon, Portugal] was submitted to MPTSCPC between January 2018 and December 2020. Patients were admitted to the procedure if they had worsening IOP control and/or deteriorating visual fields despite maximum tolerated therapy; were unable to comply with the prescribed topical medications; did not wish or were not good candidates, either for additional medications, or invasive surgeries. The study included all adult patients submitted to the procedure, with at least 3 months of follow-up.

The research was conducted according to the principles of the Helsinki Declaration (2013). All patients signed a formal consent at the time of the procedure, allowing the utilization of clinical data. All patient identifiers were removed while analyzing the data in compliance with Health Insurance Portability and Accountability Act regulations.

### Surgical Technique

All procedures were performed at Hospital Doutor Professor Fernando Fonseca EPE (HFF, Lisbon, Portugal). Intraoperatively, the patients received a peribulbar blockage with 2% lidocaine associated with minor systemic sedation or general anesthesia (especially if the bilateral procedure was performed). The Iridex Cyco G6 Glaucoma Laser Machine (Mountain View, California, United States of America) was used with a MicroPulse P3™ handpiece. A micropulsed infrared diode laser having a wavelength of 810 nm was utilized. Regarding the balance between efficacy and safety, the standard and fixed parameters recommended by the supplier were followed—2000 mW/cm<sup>2</sup> of power, 31.3% duty factor (micropulse with 0.5 ms laser on and 1.1 ms laser off time), and total treatment duration of 160 seconds. A speculum was used to ensure adequate exposure.

The probe used (MicroPulse P3®) included a notch to indicate the right position. The notch was positioned to the central cornea, and the base was positioned to the opposite side, adjacent to the limbus, to allow precise placement of the fiberoptic tip at 3 mm posterior to the limbus at pars plana. The handpiece was moved in a continuous sliding arc motion of 10 seconds each, with firm and uniform pressure, perpendicular to the globe, between the

180 degrees of the superior hemisphere, for 80 seconds in total. The same technique was repeated for the inferior hemisphere. A lubricant gel or artificial tears were applied to facilitate probe movement. It is desirable to spare the neurovascular bundle at 3 and 9 o'clock meridians, along with any area of thinning, pigmented, or hemorrhagic conjunctiva. If there is a previous glaucoma surgery with the presence of a filtering bleb or a drainage device, the area should also be avoided.

Postoperatively, all patients were advised to stop acetazolamide immediately and received ofloxacin drops of 0.3% five times a day for 1 week and prednisolone drops of 1% five times a day, with a 1-month weaning period. Topical glaucoma medications were continued and adjusted based on individual needs. Decisions on further surgery or laser treatment were made on a case-by-case basis, depending on the clinical condition.

Baseline parameters, including age, gender, ethnicity, diagnosis, previous procedures, glaucoma therapy, visual acuity, and IOP (measured by Goldmann applanation tonometry), were recorded prior to the procedure. All patients also had a slit lamp examination and disc and macular optical coherence tomography.

The electronic patient clinic record system was consulted to review data at 1 day and 1 week and 1, 3, 6, 9, 12, 18, and 24 months. For each of these visits, BCVA, IOP, number of topical agents, and the need for acetazolamide were recorded. Clinical examination was performed to assess for any abnormal findings, specifically inflammation, hypotony (IOP < 6 mm Hg), keratopathy, choroidal detachment, and phthisis bulbi. The need for re-interventions (new MPTSCPC, trabeculectomy, or implantation of drainage device) and the time between reinterventions were also registered.

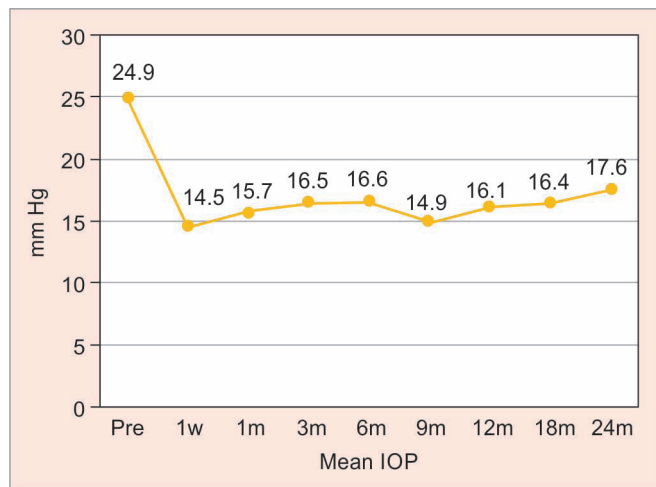
**Table 1:** Demographic and clinical characteristics

No of eyes	61 (46 patients)	
	N	%
Age (years)	M = 73.9 (minimum = 38 and maximum = 89)	
Sex		
Male	22	47.8
Female	24	52.2
Glaucoma		
Open-angle	39	63.9
Pseudoexfoliative	12	19.7
Congenital	2	3.3
Neovascular	6	9.8
Angle closed	2	3.3
Visual acuity (Snellen chart)		
<1/10	14	23.0
1/10–3/10	14	23.0
4/10–6/10	10	16.4
7/10–10/10	23	37.7
Prior glaucoma surgery N (%)		
None	38	62.3
One (trabeculectomy or drainage device)	14	23.0
Two (trabeculectomy and drainage device)	9	14.8

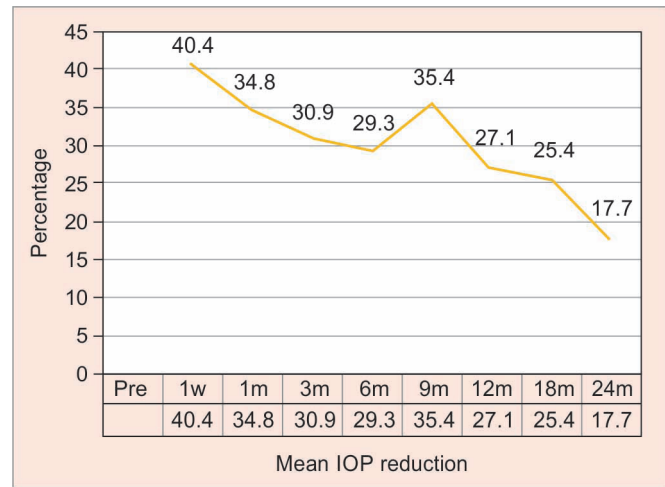
**Table 2:** Comparison between postoperative mean IOP and preoperative baseline IOP at each time point

	N	Mean difference	p	95% boot confidence interval
IOP_1 week-IOP_pre	61	-10.38	<0.001	-11.92; -8.89
IOP_1 month-IOP_pre	61	-9.16	<0.001	-10.86; -7.56
IOP_3 month-IOP_pre	61	-8.39	<0.001	-10.26; -6.69
IOP_6 month-IOP_pre	47	-7.92	<0.001	-10.04; -5.87
IOP_9 month-IOP_pre	47	-9.57	<0.001	-11.70; -7.57
IOP_12 month-IOP_pre	33	-7.46	<0.001	-10.33; -4.88
IOP_18 month-IOP_pre	22	-7.23	0.007	-11.91; -4.23
IOP_24 month-IOP_pre	11	-9.09	0.076	-18.74; 0.55

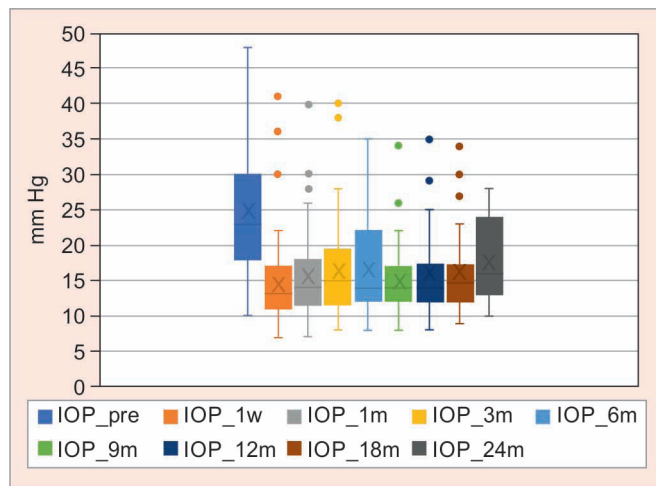
Note: IOP preoperative baseline IOP



**Fig. 1:** Mean IOP during the follow-up period



**Fig. 3:** Mean IOP reduction from baseline during the follow-up period



**Fig. 2:** Intraocular pressure (IOP) distribution at each time point

**Definition of Success**

Absolute success was defined according to guidelines of the World Glaucoma Association.<sup>15</sup> (1) IOP between 6 and 21 mm Hg, (2) IOP reduction of 20% or more from baseline, and (3) no posttreatment addition of antiglaucomatous medication or incisional surgery.

Clinical success was defined as—(1) IOP between 6 and 21 mm Hg with <20% IOP reduction from baseline, or (2) IOP >21 mm Hg with IOP reduction of 20% or more from baseline, or (3)

posttreatment withdraw of oral carbonic anhydrase inhibitors or topical antiglaucomatous medication.

Total success was defined as the combination of absolute and clinical successes.

Failure was defined as—(1) IOP < 6 mm Hg with hypotony maculopathy or >21 mm Hg and <20% IOP reduction from baseline; or (2) posttreatment addition of topical antiglaucomatous drug, oral carbonic anhydrase inhibitor, or incisional surgery. Retreatment with MPTSCPC was not considered a failure.

**Data Analysis**

A descriptive statistical analysis [mean, standard deviation (SD), range, and median] was conducted through the study variables. Categorical variables were presented as frequencies and percentages. Pre and postoperative IOP was compared at every follow-up visit, using paired *t*-test. As in some comparisons, the sample size was <30, bootstrap estimation was performed, and bootstrap results were based on 5,000 bootstrap samples. A categorical multiple regression was done to accommodate categorical, ordinal, and quantitative independent variables with a categorical dependent variable in small samples.<sup>16,17</sup> Spearman–Brown coefficient was used to calculate bivariate correlations. Data analysis was conducted with IBM-Statistical Package for the Social Sciences statistics version 27.0, and *p* < 0.05 was considered significant.

**RESULTS**

A total of 61 eyes of 46 patients were treated with MPTSCPC. The mean age of treated patients was 73.9 years (SD = 10.8,



**Table 3:** Effectiveness of MPTSCPC during the follow-up period

	Absolute success		Clinical success		Total success <sup>1</sup>		Failure	
	N	%	N	%	N	%	N	%
1 week	51	83.6	8	13.1	59	96.7	2	3.3
1 month	44	72.1	14	23.0	58	95.1	3	4.9
3 months	40	65.6	16	16.2	56	91.8	5	8.2
6 months	26	55.3	17	36.2	43	91.5	4	8.5
9 months	33	70.2	12	25.5	45	95.7	2	4.3
12 months	18	54.5	9	27.3	27	81.8	6	18.2
18 months	15	68.2	4	18.2	19	86.4	3	13.6
24 months	5	45.5	4	36.4	9	81.8	2	18.2

<sup>1</sup>Total success = absolute + clinical successes

**Table 4:** Results of regression analysis

Variables	Success					
	1 month	3 months	6 months	9 months	12 months	18 months
	$\beta$	$\beta$	$\beta$	$\beta$	$\beta$	$\beta$
Sex	0.019	0.082	0.162	0.146	0.094	0.271
Age	-0.170	-0.228	-0.215	-0.116	-0.023	-0.045
Diagnosis	0.213 <sup>†</sup>	0.265 <sup>†</sup>	0.328*	0.495**	0.187	0.520*
Prior glaucoma surgery	-0.112	-0.235	-0.212	-0.012	0.443	-0.149

Note: Two periods were not considered in inferential analysis: 1 week—83.6% absolute success and 24 months—only 11 eyes were measured; <sup>†</sup> $p < 0.10$ ; \* $p < 0.05$ ; \*\* $p < 0.001$

**Table 5:** Resume of success and complication rates from some valuable studies

Study	Sample size (N)	Follow-up (months)	Settings	Definition of success	Rate of	
					Success	Complications
Tan et al. 2010 <sup>18</sup>	40	12–18	2000 mW and 360 seconds	IOP 6–21 mm Hg or 30% reduction	80.0%	Hyphaema 17.5%
Aquino et al. 2014 <sup>8</sup>	24	12	2000 mW and 100 seconds	IOP 16–21 mm Hg	52.0%	Uveitis 4%, drop in VA 4%, and scleral thinning 4%
Kuchar et al. 2016 <sup>1</sup>	19	2	2000 mW and 100–240 seconds	IOP 6–21 mm Hg or 20% reduction	73.7%	Hypotony 5.3%
Toyos et al. 2016 <sup>4</sup>	26	12	2000 mW and 160 seconds	IOP 8–21 mm Hg or 20% reduction		Drop in VA 12%
Emanuel et al. 2017 <sup>23</sup>	84	4	1900–2000 mW 320–360 seconds	IOP reduction	100.0%	Uveitis 46%, drop in VA 26.2%, Hypotony 18%, hyphaema 11%, choroidal detachment 4%
Zaarour et al. 2018 <sup>21</sup>	75	15	2000 mW and 180 seconds	IOP 6–21 mm Hg or 20% reduction	66.0%	Uveitis 23%, drop in VA 14%
Crom et al. 2020 <sup>20</sup>	141	24	2000–2200 mW 160–180 seconds	20% IOP reduction or decrease in number of medications	80.0%	Drop in VA 25%, Macular oedema 1.4%, hypotony 0.7%
Vig et al. 2020 <sup>3</sup>	29	6	2000 mW and 80–90 seconds	IOP 6–21 mm Hg or 20% reduction	58.6%	Macular oedema 3.4%
Ariga et al. 2021 <sup>24</sup>	55	3	2000 mW and 160 seconds	IOP 8–21 mm Hg or 20% reduction	89.1%	Drop in VA 27.3%, hypotony 7.3%
Dansdill et al. 2021 <sup>12</sup>	39	6	variable, 2392 mW, and 174 seconds	IOP 6–21 mm Hg, with 20% reduction, no subsequent glaucoma filtering surgery	74.4%	
Seo et al. 2021 <sup>22</sup>	45	12	2000 mW and 60–90 seconds	IOP 6–21 mm Hg or 20% reduction	68.2%	Drop in VA 44.4%, mydriasis 20%, iritis 17.8%, uveitis 24.2%

ranging from 38 to 89 years; median = 76 years), and 24 (52.2%) patients were female. While POAG accounted for the majority of cases (39 eyes, 63.9%), the study also included 12 eyes (19.7%) with pseudoexfoliative glaucoma, six eyes (10.0%) with neovascular glaucoma (NVG), two (3.3%) with angle closed glaucoma, and two (3.3%) with congenital glaucoma. Most of the eyes (54.1%) had a

BCVA of 4/10 or superior on the Snellen Visual chart, with a mean BCVA of 5/10. Table 1 summarizes the demographic and clinical characteristics of the sample.

At baseline, patients were, on average, on four topical glaucoma drugs, and 31.1% were on maximal topical medication and oral carbonic anhydrase inhibitors. A total of 37.7% of the eyes were

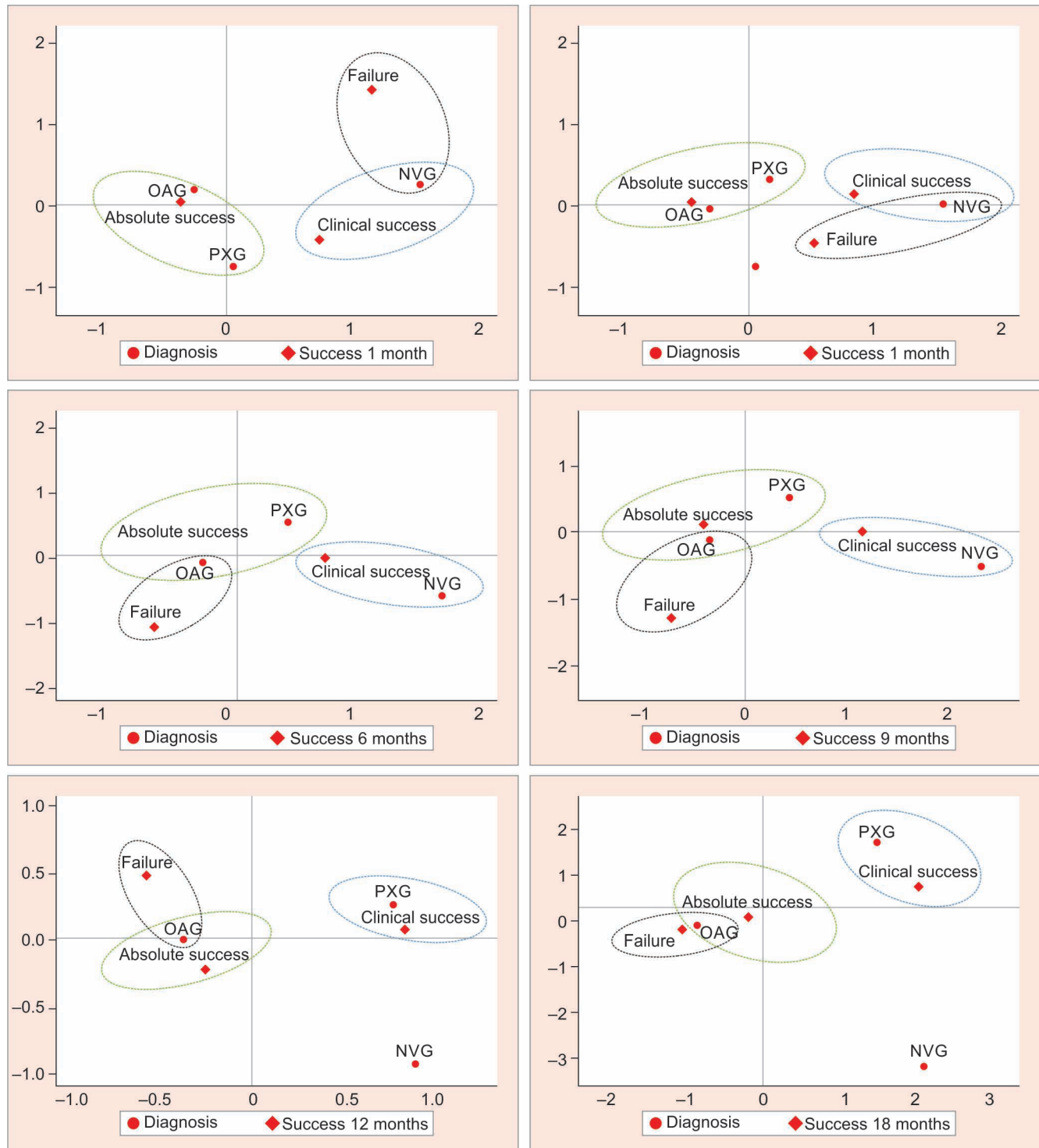


Fig. 4: Relationship between diagnosis and success

previously submitted to at least one glaucoma surgery (ab externo trabeculectomy or drainage device implantation). The average baseline IOP was 24.9 mm Hg (SD ± 8.6, ranging from 10 to 48 mm Hg). The mean follow-up period was 6 months, and 54.1% of cases had a follow-up period of >12 months.

Mean IOP was—14.5 mm Hg (40.4% reduction) at 1 week; 15.7 mm Hg (34.8% reduction) at 1 month; 16.5 mm Hg (30.9% reduction) at 3 months; 16.6 mm Hg (29.3% reduction) at 6 months; 14.9 mm Hg (35.4% reduction) at 9 months; 16.1 mm Hg (27.1%

reduction) at 12 months; 16.4 mm Hg (25.4% reduction) at 18 months; 17.5 mm Hg (17.7% reduction) at 24 months (schematic representation shown in Figs 1 to 3). Except for the comparison at 24 months ( $p = 0.076$ ), postoperative mean IOP at each time point was significantly lower ( $p < 0.01$ ) than preoperative baseline IOP (Table 2).

The mean number of glaucoma drugs post-MPTSCPC decreased to  $3.4 \pm 1.0$ , and it was possible to discontinue oral acetazolamide in 17 of 19 cases (89.5%). The success rate evolution is discriminated in Table 3.



Eight (17.4%) patients reported mild pain during the immediate postoperative period, with a good response to oral paracetamol. A subconjunctival hemorrhage in the first week posttreatment was found in 13 (21.3%) eyes. Postoperative inflammation, observed in four (6.6%) eyes, was successfully treated with topical corticosteroids. Corneal decompensation occurred in three (4.9%) cases, all of them with previous corneal pathology (herpetic keratitis, Fuchs endothelial dystrophy, and bullous keratopathy). Macular edema was observed in two (3.3%) cases, with a previous diagnosis of diabetic maculopathy. There was no record of other serious complications, including hyphema, prolonged hypotony, phthisis bulbi, retinal or choroidal detachment or hemorrhage, or decreased visual acuity.

The procedure was repeated once in nine (14.8%) cases, twice in two (3.3%) cases, and thrice in one (1.6%) case. The median time to retreatment was 4.4 months (ranging between 2 and 11 months). Absolute (75.0%) or clinical (25.0%) success was achieved in all cases post reintervention.

Categorical regression showed that gender, age, and prior glaucoma surgery were not significantly associated with success (Table 4). Figure 4 shows the relationship between the different diagnoses and the categories of success. The results highlight a greater association between OAG and absolute success and between NVG and clinical success. As the time to success increased (from 6 months), the OAG diagnosis also became associated with failure, although they are very few.

The relationship between diagnosis and prior glaucoma surgery with the need for reinterventions were also analyzed. The results showed a positive and significant correlation between prior glaucoma surgery and the need for reinterventions ( $\rho = 0.281$ ,  $p = 0.028$ ).

## DISCUSSION

Micropulse transscleral cyclophotocoagulation (MPTSCPC) is a procedure that emits a fractionated wave diode laser beam with an active cycle during 31.3% of the complete treatment duration. The laser is not released 68.7% of the time, allowing tissues to dissipate thermal energy, hence getting below the coagulation threshold. In that way, it is possible to target melanin of pigmented ciliary body epithelium, avoiding focal heating, and tissue burning of surrounding tissues. This mechanism of action minimizes complications rate when compared to continuous wave conventional cyclophotocoagulation.

It is important to emphasize that the conventional cyclophotocoagulation was traditionally reserved for refractory glaucoma, with poor prognosis, where other medical and surgical measures have failed, due to the risk of phthisis, hypotony, visual deterioration, and unpredictability. MPTSCPC has emerged as a possible therapeutic option in eyes with good vision/visual potential, on every level of the glaucoma spectrum, due to a lower rate of complications.<sup>8,18</sup> In our practice, MPTSCPC has been applied in cases of elevated IOP and/or advancing glaucoma, as adjunctive therapy, or as an alternative to reduce their medication load and avoid invasive surgery.

Many studies reported the short-term efficacy and safety of MPTSCPC. There are relatively few studies that report on the long-term results.

Lim et al.<sup>19</sup> reported success rates of up to 70% 6 weeks post procedure, with subsequent decline throughout the follow-up, to only 18.5% of success at 3 years. Aquino et al.<sup>8</sup> observed success rates of 75% after 12 months and 52% after 18 months of the treatment.

Our study, although with a smaller sample size, revealed a total success of 95.5 (70.2% absolute success), 86.4 (68.2% absolute success), and 81.9% (45.5% absolute success) after 9, 12, and

24 months of treatment, respectively. Mean IOP was significantly reduced from 24.9 to 16.1 mm Hg after 12 months and 17.5 mm Hg at the final follow-up.

In the study of Crom et al.,<sup>20</sup> the treatment protocol used was similar to ours, which makes both studies comparable. They treated 141 eyes and achieved an IOP between 6 and 21 mm Hg in 78.2 (111/141), 74.4 (67/90), and 80% (40/50) of patients after, respectively, 12, 18, and 24 months of follow-up. They also did not find a significant correlation between preoperative IOP and postoperative IOP, change or age, and postoperative IOP.

The definition of success used in this study includes clinical success, that is, the treatment is beneficial clinically to the patient (decrease in IOP, despite not reaching target IOP, or allowing to dismiss medications keeping IOP controlled). This may be one of the reasons that the current study shows superior total success rates when compared to other studies.

Our results showed a very rapid IOP lowering as early as 1 week postoperatively (40.4% of IOP reduction, to a mean value of 14.5 mm Hg). This has been attributed both to the increase in uveoscleral outflow, as well as a decrease in AH production.

Retreatment was needed in 12 eyes (19.7%). Preoperative IOP in this subgroup was found to be significantly higher (27.3 mm Hg) than the eyes not needing MPTSCPC retreatment. Crom et al.<sup>20</sup> reported a rate of retreatment of 27.6%. Opposite to the current study, the authors need to revert to other glaucoma surgery in seven cases.

Although success tends to decrease and, consequently, failure tends to increase during follow-up period, the procedure has a success rate superior to 80% after 2 years, maintaining efficacy in most of the cases. This fact is in agreement with studies with longer follow up that show that MPTSCPC has a waning effect over time.<sup>12,21</sup>

The number of required glaucoma drops was not significantly reduced, but there was a trend toward requiring fewer drops.

Our experience demonstrates that MPTSCPC is a safe procedure based on the low rates of mild complications and the absence of severe ones. Consistent with previous studies, there were no cases of hypotony or phthisis bulbi. There were two cases of macular edema (3.3%) in diabetic patients who had previous similar episodes prior to interventions. Of particular note, the current study had no cases of a decrease in visual acuity. In contrast, Seo et al.<sup>22</sup> had a significant number of patients (44.4%) who experienced vision changes after MPTSCPC. The difference may be explained by the higher severity of glaucoma, and the lower baseline mean VA of patients included in this study. To better understand the impact of MPTSCPC on vision, further research should be conducted with subgroups of different stages of the disease, baseline VA and visual field.

Table 5 resumes success and complication rates from some valuable studies.

37.7% of our population had previous filtration surgery, suggesting MPTSCPC is an effective treatment in diseases difficult to manage and/or refractory to other modalities.

The excellent safety and efficacy profile leads the authors to believe that MPTSCPC can be used in almost any part of glaucoma's treatment algorithm and can be extended to all types of glaucoma in all spectrums of the disease.

The current study has several limitations—retrospective nature; a small number of eyes treated; most patients had POAG, and the number of patients with secondary glaucoma (NVG and uveitis) constituted <20% of the total eyes; variable severity of glaucoma. Furthermore, the study did not include pediatric patients.

The strengths of the present study are a broad spectrum of indications for treatment and the inclusion of eyes with good visual

potential during a long follow-up. Therefore, the results support the idea that MPTSCPC is efficient and safe in every degree of glaucoma disease.<sup>23–27</sup>

## CONCLUSION

As of this day, this is the first study to introduce the definition of clinical success, along with absolute success. This fact allows us to assess disease control not exclusively based on absolute IOP measurement but also on patients' comfort and needs.

This study demonstrates the ability of MPTSCPC to significantly reduce IOP, along with the number of oral or topical drugs required for IOP control. MPTSCPC is rapid, technically simple to execute, relatively inexpensive, and minimally invasive. These reasons make MPTSCPC a useful option for invasive glaucoma surgery in patients who are at a high risk of surgical complications or failure.

The authors consider that multicenter studies, with a larger sample and longer follow-up periods, are necessary to better understand the real impact of MPTSCPC in glaucoma treatment.

The critical point of this technique is defining the optimal parameters of the laser and the treatment duration to strike the best balance between effectiveness and safety. Prospective multicenter studies focusing on the influence of managing laser parameters should be performed in the near future to create guidelines to determine ideal laser parameters on an individual basis, according to ethnicity and type and stage of the disease.

## COMPLIANCE WITH ETHICAL STANDARDS

### Ethical Approval

The study was carried out in accordance with the 2013 Helsinki declaration and its later amendments. Informed consent was obtained from all patients.

### ORCID

Rita C Basto <https://orcid.org/0000-0001-8503-8574>

Júlio Almeida <https://orcid.org/0000-0002-4651-8812>

Joana N Roque <https://orcid.org/0000-0002-0713-7064>

Helena Carvalho <https://orcid.org/0000-0001-5885-3039>

## REFERENCES

- Kuchar S, Moster MR, Reamer CB, et al. Treatment outcomes of micropulse transscleral cyclophotocoagulation in advanced glaucoma. *Lasers Med Sci* 2016;31(2):393–396. DOI: 10.1007/s10103-015-1856-9
- Dastiridou AI, Katsanos A, Denis P, et al. Cyclodestructive procedures in glaucoma: a review of current and emerging options. *Adv Ther* 2018;35(12):2103–2127. DOI: 10.1007/s12325-018-0837-3
- Vig N, Ameen S, Bloom P, et al. Micropulse transscleral cyclophotocoagulation: initial results using a reduced energy protocol in refractory glaucoma. *Graefes Arch Clin Exp Ophthalmol* 2020;258(5):1073–1079. DOI: 10.1007/s00417-020-04611-0
- Toyos MM, Toyos R. Clinical outcomes of micropulsed transscleral cyclophotocoagulation in moderate to severe glaucoma. *J Clin Exp Ophthalmol* 2016;7(6):620. DOI: 10.4172/2155-9570.1000620
- Yelenskiy A, Gillette TB, Arosemena A, et al. Patient outcomes following micropulse transscleral cyclophotocoagulation: intermediate-term results. *J Glaucoma* 2018;27(10):920–925. DOI: 10.1097/IJG.0000000000001023
- Lee JH, Shi Y, Amoozgar B, et al. Outcome of micropulse laser transscleral cyclophotocoagulation on pediatric versus adult glaucoma patients. *J Glaucoma* 2017; 26(10): 936–939. DOI: 10.1097/IJG.0000000000000757
- Abdelrahman AM, El Sayed YM. Micropulse versus continuous wave transscleral cyclophotocoagulation in refractory pediatric glaucoma. *J Glaucoma* 2018;27(10):900–905. DOI: 10.1097/IJG.0000000000001053
- Aquino MC, Barton K, Tan AM, et al. Micropulse versus continuous wave transscleral diode cyclophotocoagulation in refractory glaucoma: a randomized exploratory study. *Clin Exp Ophthalmol* 2014;43(1): 40–46. DOI: 10.1111/ceo.12360
- Ndulue JK, Rahmatnejad K, Sanvicente C, et al. Evolution of cyclophotocoagulation. *J Ophthalmic Vis Res* 2018;13(1): 55–61. DOI: 10.4103/jovr.jovr\_190\_17
- Sanchez FG, Lerner F, Sampaolesi J, et al. Efficacy and safety of Micropulse® transscleral cyclophotocoagulation in glaucoma. *Arch Soc Esp Oftalmol (Engl Ed)* 2018;93(12): 573–579. DOI: 10.1016/j.oftal.2018.08.003
- Michelessi M, Bicket AK, Lindsley K. Cyclodestructive procedures for non-refractory glaucoma. *Cochrane Database Syst Rev* 2018;4(4):CD009313. DOI: 10.1002/14651858.CD009313
- Dansdill D, Pikey K, Krishna R. Micropulse cyclophotocoagulation outcomes in primary open angle glaucoma. *Asian J Res Rep Ophthalmol* 2021; 4(1): 1–9. <https://journalajrrop.com/index.php/AJRROP/article/view/22>
- Johnstone M. Transscleral laser induces aqueous outflow pathway motion & reorganization. In *AGS2017*; 2017; Coronado.
- Sanchez FG, Peirano-Bononi J, Grippo TM. Micropulse transscleral cyclophotocoagulation: a hypothesis for the ideal parameters. *Med Hypothesis Discov Innov Ophthalmol* 2018;7(3): 94–100. PMID: 30386797; PMCID: PMC6205680
- Shaarawy TM. Guidelines on design and reporting of glaucoma surgical trials. *World Glaucoma Association: Kugler publications*; 2008.
- Gifi A. *Nonlinear multivariate analysis* Chichester: John Wiley and Sons; 1990.
- van der Kooij AJ, Meulman JJ, Heiser WJ. Local minima in categorical multiple regression. *Comput Stat Data Anal* 2006;50(2):446–462. DOI: 10.1016/j.csda.2004.08.009
- Tan AM, Chockalingam M, Aquino MC, et al. Micropulse transscleral diode laser cyclophotocoagulation in the treatment of refractory glaucoma. *Clin Exp Ophthalmol* 2010;38(3):266–272. DOI: 10.1111/j.1442-9071.2010.02238.x
- Lim EJY, Cecilia AM, Lim DKA, et al. Clinical efficacy and safety outcomes of micropulse transscleral diode cyclophotocoagulation in patients with advanced glaucoma. *J Glaucoma* 2021;30(3):257–265.
- de Crom RMPC, Slangen CGMM, Kujovic-Aleksov S, et al. Micropulse trans-scleral cyclophotocoagulation in patients with glaucoma: 1- and 2-year treatment outcomes. *J Glaucoma* 2020;29(9):794–798. DOI: 10.1097/IJG.0000000000001552
- Zaarour K, Abdelmassih Y, Arej N, et al. Outcomes of micropulse transscleral cyclophotocoagulation in uncontrolled glaucoma patients. *J Glaucoma* 2019;28(3):270–275. DOI: 10.1097/IJG.0000000000001174
- Seo D, Lee TJ, Kim JY, et al. Clinical outcomes of micropulse transscleral cyclophotocoagulation in refractory glaucoma. *Res Sq* 2021. DOI: 10.21203/rs.3.rs-147374/v1
- Emanuel ME, Grover DS, Fellman RL, et al. Micropulse cyclophotocoagulation: initial results in refractory glaucoma. *J Glaucoma* 2017;26(8): 726–729. DOI: 10.1097/IJG.0000000000000715
- Ariga M, Nivean PD, Madanagopalan VG, et al. Micropulse trans-scleral diode laser cyclophotocoagulation in refractory glaucoma: an initial experience in Indian eyes. *Int Ophthalmol* 2021;41(8):2639–2645. DOI: 10.1007/s10792-021-01697-1
- Gavris MM, Olteanu I, Kantor E, et al. IRIDEX MicroPulse P3: innovative cyclophotocoagulation. *Rom J Ophthalmol* 2017;61(2): 107–111. DOI: 10.22336/rjo.2017.20
- Pelc C. Control IOP without incisions: Iridex Cyclo G6 glaucoma laser system uses micropulse technology for safe treatment and quick recovery. *Ophthalmol Manag* 2015;19(2015):76–82. <https://www.ophtalmologymanagement.com/issues/2015/april-2015/spotlight-on-technology-amp-technique>
- Pastor SA, Singh K, Lee DA, et al. Cyclophotocoagulation: a report by the American Academy of Ophthalmology. *Ophthalmology* 2001;108(11):2130–2138. DOI: 10.1016/s0161-6420(01)00889-2

