

Available online at www.sciencedirect.com

ScienceDirect

journal homepage: <http://Elsevier.com/locate/radcr>

Case Report

I-131 uptake in fat necrosis of the breast

Malak Itani MD^{*}, David H. Lewis MD

Department of Radiology, University of Washington Medical Center, Box 357115, 1959 NE Pacific St, Seattle, WA 98195, USA

ARTICLE INFO

Article history:

Received 18 March 2016

Received in revised form

15 October 2016

Accepted 23 October 2016

Available online 23 November 2016

Keywords:

I-131

Breast

Fat necrosis

Poorly differentiated

Papillary thyroid cancer

Radioactive iodine therapy

ABSTRACT

I-131 uptake in the breast has been described with a variety of normal and pathologic conditions. We present the case of a 38-year-old female who received 317 millicuries of radioactive I-131 treatment for papillary thyroid carcinoma. Post-treatment scan demonstrated I-131 uptake in an area of fat necrosis in the breast.

© 2016 the Authors. Published by Elsevier Inc. under copyright license from the University of Washington. This is an open access article under the CC BY-NC-ND license (<http://creativecommons.org/licenses/by-nc-nd/4.0/>).

Introduction

Planar radioactive iodine scans are routinely performed to evaluate for metastatic disease from differentiated thyroid cancer. Iodine uptake can be seen in multiple sites, in physiologic and pathologic processes apart from metastatic thyroid cancer. We describe a case of I-131 uptake in an area of fat necrosis in the breast, pointing out the challenges in diagnosis and management of poorly differentiated papillary thyroid cancer.

Case report

The patient is a 38-year-old female who presented to our institution 2 years after her initial presentation and diagnosis,

and after being managed by other providers. She has had a history of hypothyroidism since age 25, and at age 36, she detected a painful and palpable right sided neck mass. Ultrasound demonstrated a solid isoechoic 1.7 cm nodule with multiple internal punctate echogenic foci, and ill-defined margins. Fine needle aspiration was nondiagnostic. A second fine needle aspiration showed thyroid carcinoma, which could not be classified. The patient underwent right hemithyroidectomy with neck dissection. Surgical pathology revealed a 3.5 cm poorly differentiated papillary thyroid cancer, with extension into the perithyroid tissue and muscles, as well as lymphatic and venous invasion, and 5 of 6 positive lymph nodes, which is consistent with an initial staging of T4aN1b. There was no evidence of distant metastases on staging positron emission tomography/computed

Competing Interests: The authors have declared that no competing interests exist.

^{*} Corresponding author.

E-mail address: mitani9@uw.edu (M. Itani).
<http://dx.doi.org/10.1016/j.radcr.2016.10.018>

1930-0433/© 2016 the Authors. Published by Elsevier Inc. under copyright license from the University of Washington. This is an open access article under the CC BY-NC-ND license (<http://creativecommons.org/licenses/by-nc-nd/4.0/>).

tomography (PET/CT). Because of the extensiveness of her local disease, the patient underwent external beam radiation therapy, followed by an extensive neck dissection, revealing an additional 7 positive lymph nodes out of 27 resected. A diagnostic whole body I-131 scan after administration of an oral 4.13 mCi demonstrated a small focus of moderate activity in the anterior neck along the midline, near the region of the thyroid bed. The patient was then treated with 135.2 mCi of radioactive iodine I-131 after Thyrogen stimulation, for remnant ablation and presumably for local aggressive disease with lymph node involvement. Post-treatment scan showed a new focus of mildly increased activity over the right upper chest, reported to be “concerning for a right upper lobe pulmonary metastasis or conceivably a supraclavicular lymph node metastasis” (Fig. 1). The inferred clinical opinion was that this uptake could be due to lung metastases or due to radiation-pneumonitis in the right upper lobe. CT chest was then performed, demonstrating new pulmonary metastases (Fig. 2), confirmed later with CT-guided biopsy as poorly differentiated thyroid carcinoma. After 4 months, restaging scans demonstrated mild interval increase in the size of the pulmonary nodules, with concurrent gradual elevation of her thyroglobulin levels (from 8.3 ng/mL before I-131 therapy, to 38 ng/mL). The patient presented to our institution at this stage for a second opinion. There was a question regarding the

potential benefit from a second radioactive iodine treatment, so a whole body I-131 scan was performed in an outside institution, and reported to have “evidence of iodine avidity in her pulmonary metastases”. The consensus decision among the patient, the endocrinologist, and the nuclear medicine physicians was to administer a second treatment dose of I-131 for treatment of pulmonary metastatic disease, based on whole body dosimetry (Memorial Sloan Kettering method). A dose of 3.1 mCi of oral I-131 was administered for whole body dosimetry. Images demonstrate only faint lung uptake, greater on the right side than the left (Figs. 3 and 4). Single-photon emission computed tomography (SPECT) was not performed, as this was a dosimetry study and the pretherapy scan was performed and demonstrated iodine uptake in the lung metastases. The dosimetry estimated 5402.6 mCi of oral I-131 to deliver 80 mCi retained dose in the lungs at 48 hours, and 344.2 mCi to deliver 200 rads to the bone marrow. With all the considerations, given there were known pulmonary nodules on the CT chest, and after discussion with the referring endocrinologist, 300 mCi I-131 were prescribed for Thyrogen-driven therapy. The patient presented for her second radioactive I-131 treatment, and received a dose of 317.3 mCi. A post-treatment I-131 scan was performed 9 days following administration of the therapeutic dose, demonstrating focal uptake in the right anterior chest, but no definite uptake in the

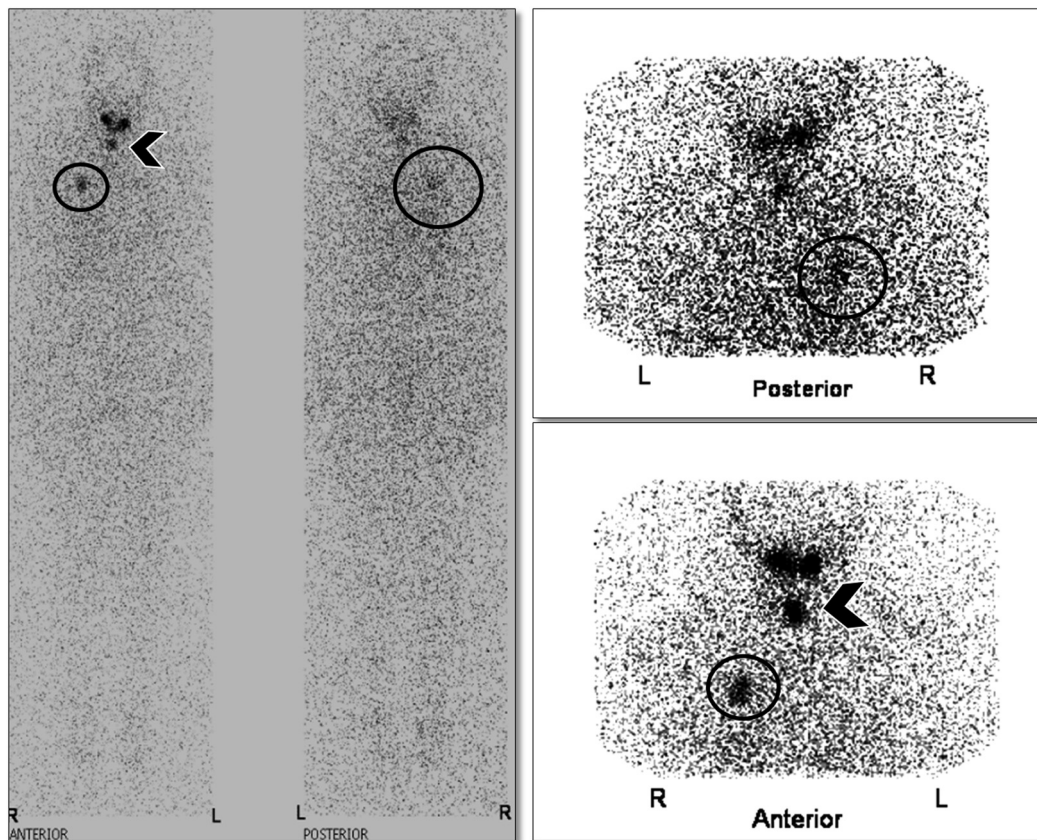


Fig. 1 – Initial post-treatment I-131 scan. Whole body planar views (left) and spot views of the head, neck, and chest obtained 16 days following initial treatment with 135.2 mCi of I-131. There is intense focal uptake in the neck consistent with minimal thyroid remnant (arrowheads), and focal uptake in the right anterior chest (circles), seen faintly on the posterior views (larger circles).

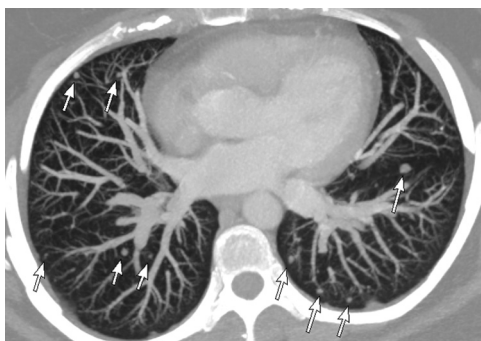


Fig. 2 – Pulmonary metastases on chest computed tomography (CT). Reconstructed 2 cm thick maximum intensity projection (MIP) image of chest CT demonstrating small bilateral pulmonary nodules (arrows) in random distribution, typical for miliary metastases. Biopsy was consistent with metastasis from patient's primary thyroid cancer. These were new when compared with a prior staging positron emission tomography (PET) scan.

lungs (Fig. 5), so a SPECT/CT was performed. The SPECT/CT images localized the uptake in the right anterior chest to an area of fat necrosis in the right breast (Fig. 6), but failed to confirm any I-131 uptake in the metastatic pulmonary nodules. Review of patient's prior imaging studies demonstrate that the area of fat necrosis was also present on staging fluorodeoxyglucose (FDG)-PET scan performed 2 years earlier (Fig. 7), and was reported on prior mammogram, along with postreduction changes. Thyroglobulin levels started to rise 6 months following the external beam radiation, and continued to increase gradually. CT chest was repeated 4 months following the second radioactive iodine therapy, and it demonstrated worsening metastatic disease with multiple new and enlarging pulmonary nodules, as well as several pleural metastatic deposits.

Discussion

In this presented case, we will allude briefly into several issues following the main discussion about radioiodine uptake in fat necrosis of the breast.

Radioactive iodine in the chest could be in multiple sites other than the lungs, and even in the lungs it could be seen with different pathology aside from metastatic lung disease. On planar imaging, iodine uptake in the chest may be internal or external because of contamination. Internal uptake can be classified by etiology as physiologic, pathologic, or internal retention [1]. Radioactive iodine uptake has been described in many normal organs as well as a variety of pathologic processes. In the chest, internal activity can be classified anatomically, within the soft tissues, breast, ribs, heart, pericardium, mediastinum, pleura, or lung parenchyma [2]. Iodine uptake in soft tissues and has been reported with lymphoepithelial cyst, skin burn [3], skin wound [4], and even in a psoriatic plaque [5]. Iodine uptake may be in the rib from a benign [6] or metastatic bone lesion, whether from papillary thyroid cancer or a different primary [7]. Iodine uptake in the

pleura and mediastinum has also been described in pleuropericardial cyst, pericardial effusion [8], esophageal retained saliva, Barrett's esophagus, or Zenker diverticulum, and is potentially possible in ectopic mediastinal thyroid tissue that has excessively migrated [7]. Myocardial iodine uptake has been described after myocardial infarction [9]. In the lung parenchyma, iodine uptake can be due to a primary lung malignancy, metastatic disease, or inflammatory lung disease [8,10]. Note that this is not a comprehensive list of sites of accumulation of radioactive iodine, and several extensive review articles are available covering this topic.

Focal uptake in the chest is not typical with metastatic pulmonary disease, given that papillary thyroid cancer tends to spread in a miliary pattern or diffuse micronodules when it metastasizes to the lungs. When focal uptake is noted in the chest, it might be wise to order oblique and/or lateral views to see whether this uptake localizes within or outside the thoracic cage. Alternatively, SPECT CT can be of value.

Iodine uptake has been described in the breast tissue in lactating and nonlactating females [11,12]. In the lactating breast, as well as in the thyroid gland, sodium-iodide symporter (NIS) mediates iodine uptake [13]. NIS expression in most thyroid cancers is less than that of normal thyroid gland; this is why thyroid cancers usually appear as cold nodules. Still, around 80% of well-differentiated thyroid cancers have enough NIS expression to facilitate iodine uptake in radioactive iodine treatment [13]. NIS is also overexpressed in the lactating breast [14]. Prolactin plays a role in induction of NIS [13], and bilateral breast uptake has been described in a woman with hyperprolactinemia from a pituitary microadenoma [15].

Iodine uptake in the nonlactating breast has been described in 6% of women who had radioiodine scans, and the etiology remains poorly understood [12]. Radioiodine uptake in the breast can be seen with gynecomastia, supernumerary breasts, and lactational duct cyst or galactocele [7].

Fat necrosis is a non-suppurative inflammatory process that is being increasingly encountered incidentally on mammography or other imaging modalities [16]. Fat necrosis can occur after trauma, diagnostic breast interventions, or breast surgery [17]. The inflammation is followed by a reparative phase, and is surrounded by a rim of fibroblasts, that may subsequently produce rim calcifications [16,18]. FDG uptake is expected in areas of active inflammation, and has been specifically described in fat necrosis of the breast [17]. Iodine uptake, on the other hand, has not been specifically associated with fat necrosis of the breast, although it has been described in inflammation and scars, as detailed earlier. An interesting observation when comparing the PET scan in the reported case to the SPECT, shows that FDG accumulation is mostly along the periphery of the area of fat necrosis, which is expected as it is probably related to the surrounding inflammation or fibroblastic activity [19]. Iodine accumulation, however, seems to be in the center of the fat necrosis. This observation might pave the road to further understanding of the etiology of iodine uptake in fat necrosis of the breast as a possible future work in cellular biology.

There have been some controversial aspects in the management of the reported patient. The patient is a 38-year-old female with poorly differentiated papillary thyroid carcinoma, and multiple bilateral metastatic pulmonary nodules.

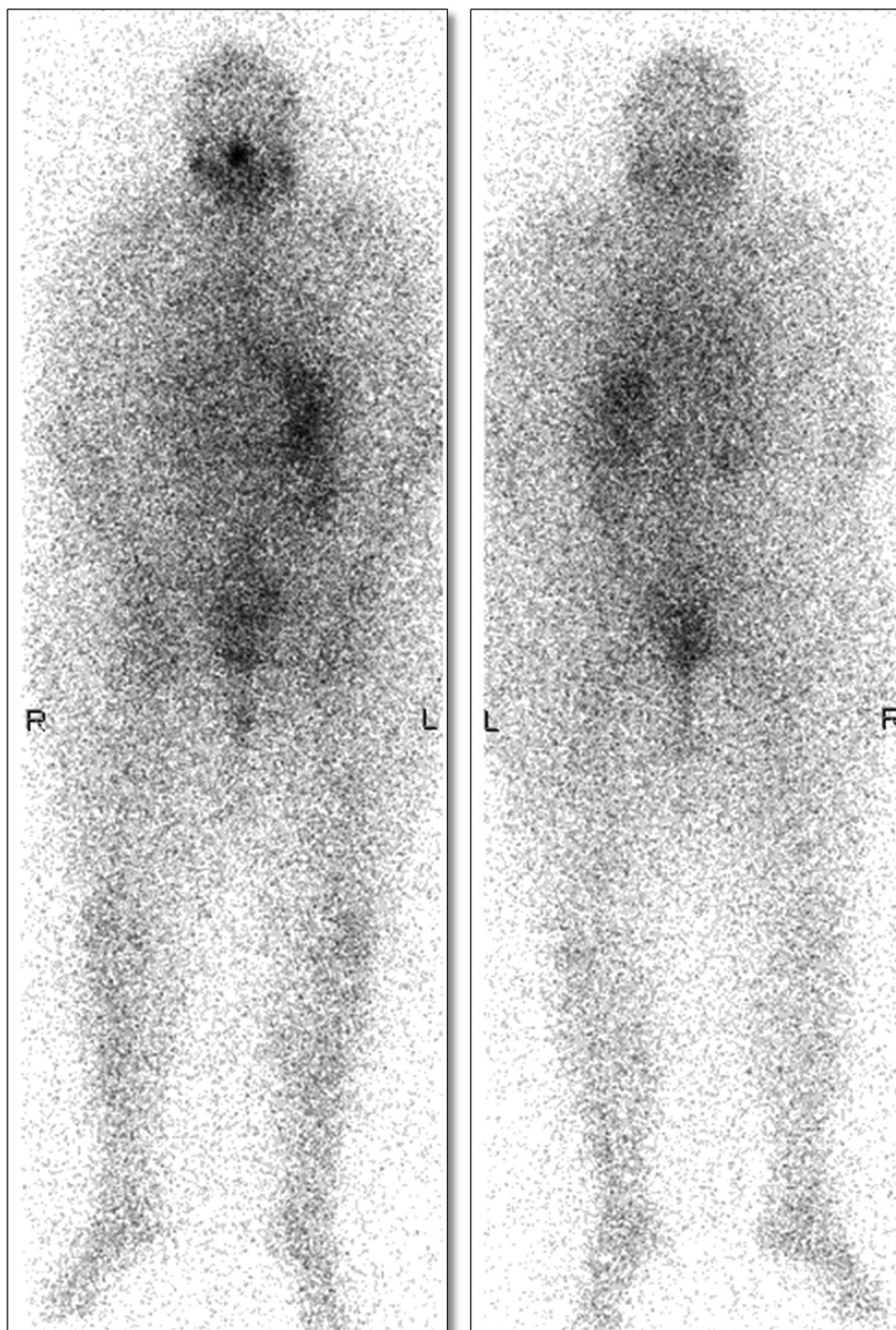


Fig. 3 – Diagnostic I-131 scan, 48 hours. Whole body planar scans were performed 48 hours following oral administration of 3.1 mCi of I-131 for a diagnostic study. There is apparent faint uptake overlying the chest on posterior and anterior views, compared with the adjacent soft tissues.

Radioactive I-131 therapy for malignant thyroid disease is a well-established treatment option in subgroups of patients with well-differentiated papillary, follicular, and Hurthle cell carcinoma of the thyroid. In cases of anaplastic carcinoma, radioactive I-131 treatment is not recommended. Poorly differentiated thyroid carcinoma falls histologically on the

spectrum between well-differentiated and anaplastic carcinoma [20]. In contrast to anaplastic carcinoma, poorly differentiated thyroid carcinomas tend to produce thyroglobulin, and up to two-thirds do concentrate iodine [21]. This indicates a potential role for radioactive I-131 therapy on a case-by-case basis. In a review from Memorial Sloan-

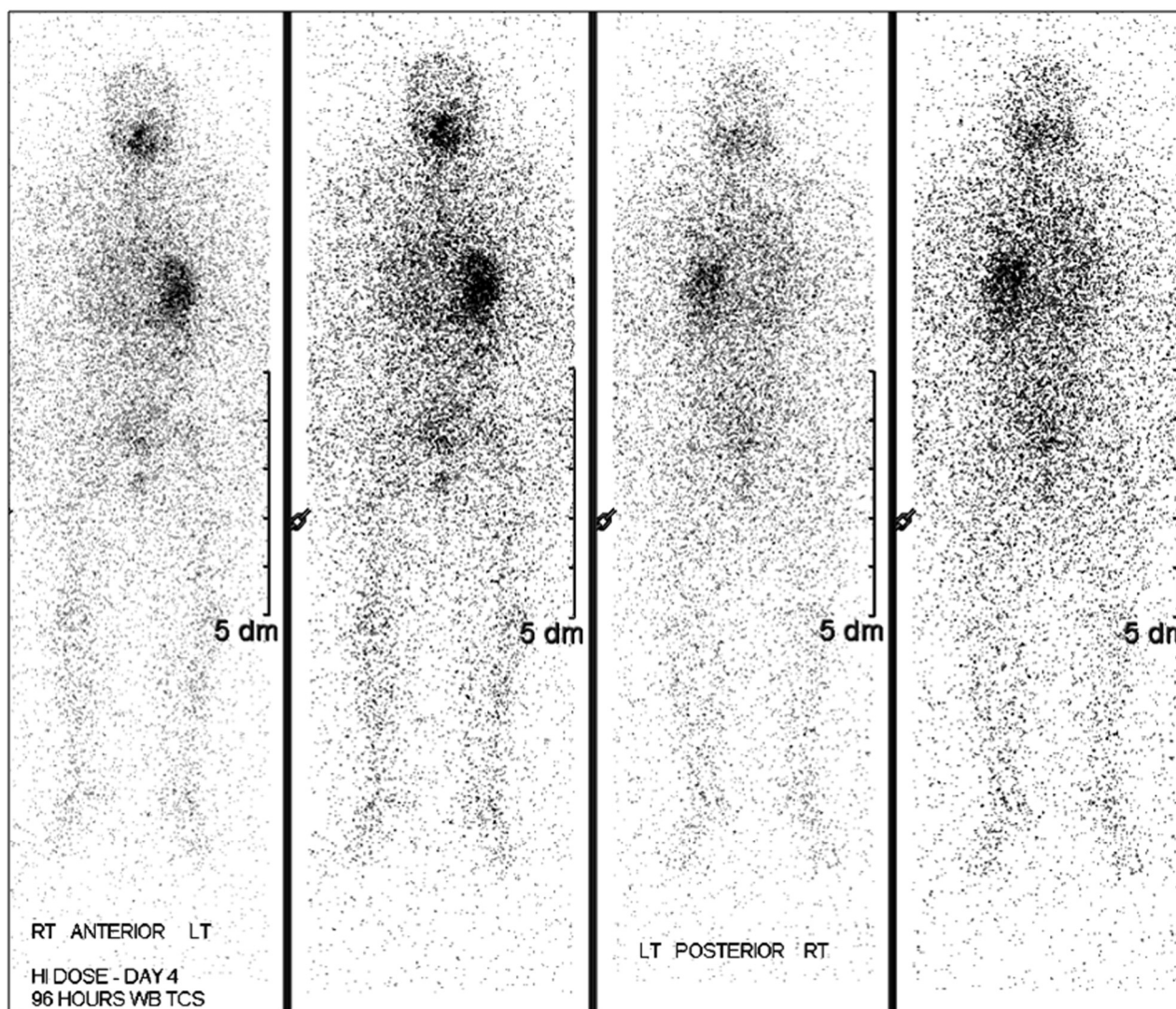


Fig. 4 – Diagnostic I-131 scan, 96 hours. Whole body planar scans were performed 96 hours following oral administration of 3.1 mCi of I-131. Two anterior views (left) and 2 posterior views (right) are presented with 2 different display settings. The chest uptake is even less conspicuous compared with images taken at 48 hours (shown in Fig. 3).

Kettering Cancer Center [22], authors state that up to 85% of poorly differentiated thyroid carcinomas display radioactive iodine avidity, and that most authors advocate for the use of radioactive iodine therapy in this setting. From the same institution, an argument was made that radioactive iodine ablation should be offered routinely to patients with poorly differentiated thyroid cancers, because of the aggressiveness of this disease, “giving it a shot”, despite the fact that many patients will have persistent or recurrent disease [23]. More recently, tyrosine kinase inhibitors have proven benefits in lung metastases from radioiodine-resistant thyroid cancer [24]. Currently, Sorafenib is the FDA-approved for radioiodine-resistant metastatic differentiated thyroid cancer, but it has a high rate of adverse events [25]. Because these scenarios are not very common, there are no specific guidelines and management options in cases of poorly differentiated thyroid cancer remain a topic of controversy and a clinical challenge.

In our reported case, the patient had her pretreatment uptake scan performed in another institution, and the findings were consistent with radioiodine uptake in the chest. As the patient had also had known metastatic pulmonary nodules, the study was officially interpreted as positive for iodine uptake within the lung metastases, and the decision to treat was based on this interpretation. The second treatment was carried out at our institution primarily after communication from the clinician that the lung metastases were positive for iodine uptake. Retrospectively, while we reviewed the records from the other hospital, and compared with the SPECT CT that we have performed, the chest uptake was actually in the area of fat necrosis in the right breast and not within the chest cavity or the lung metastases. Post-treatment SPECT confirmed that the disease in the lungs was not iodine avid, and the progression of the lung nodules after a few months also support this conclusion.

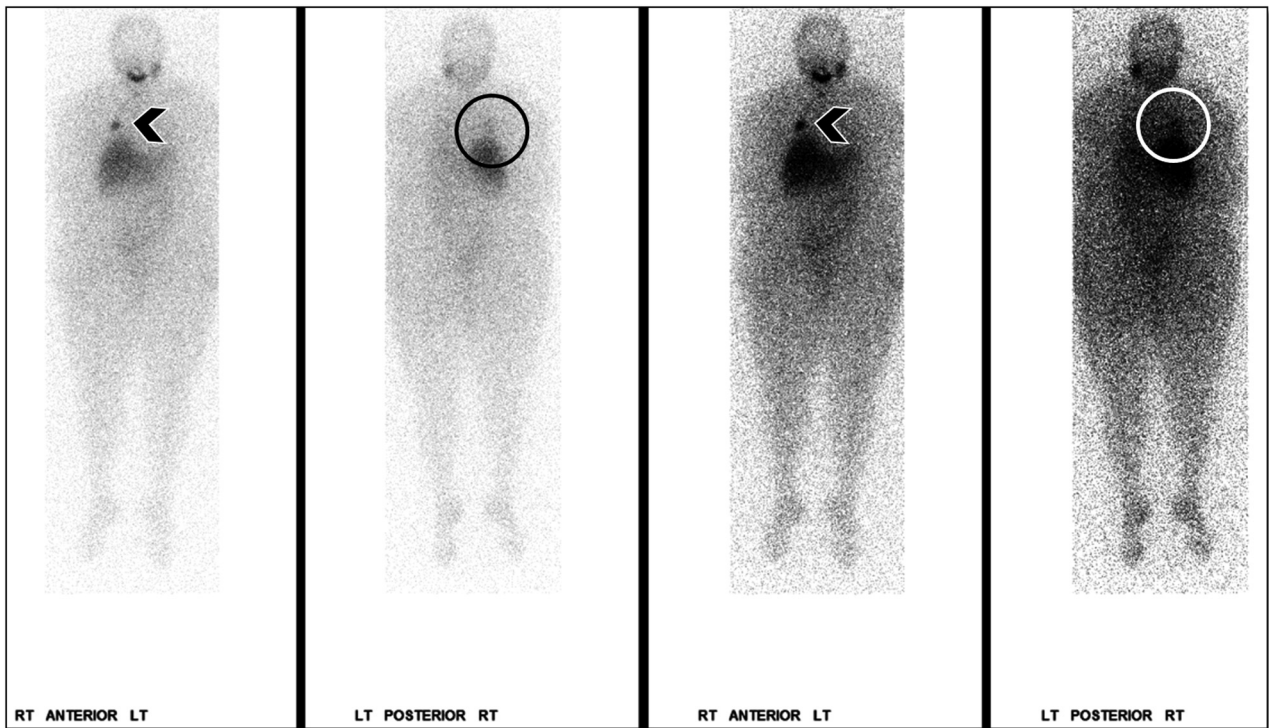


Fig. 5 – Second post-treatment I-131 scan. Whole body planar scans were performed 9 days following oral administration of 317 mCi of I-131. Two anterior and 2 posterior whole body views in 2 different display settings demonstrate focal uptake in the right hemithorax anteriorly (arrowheads), with faint shine-through on the posterior projection (circles).

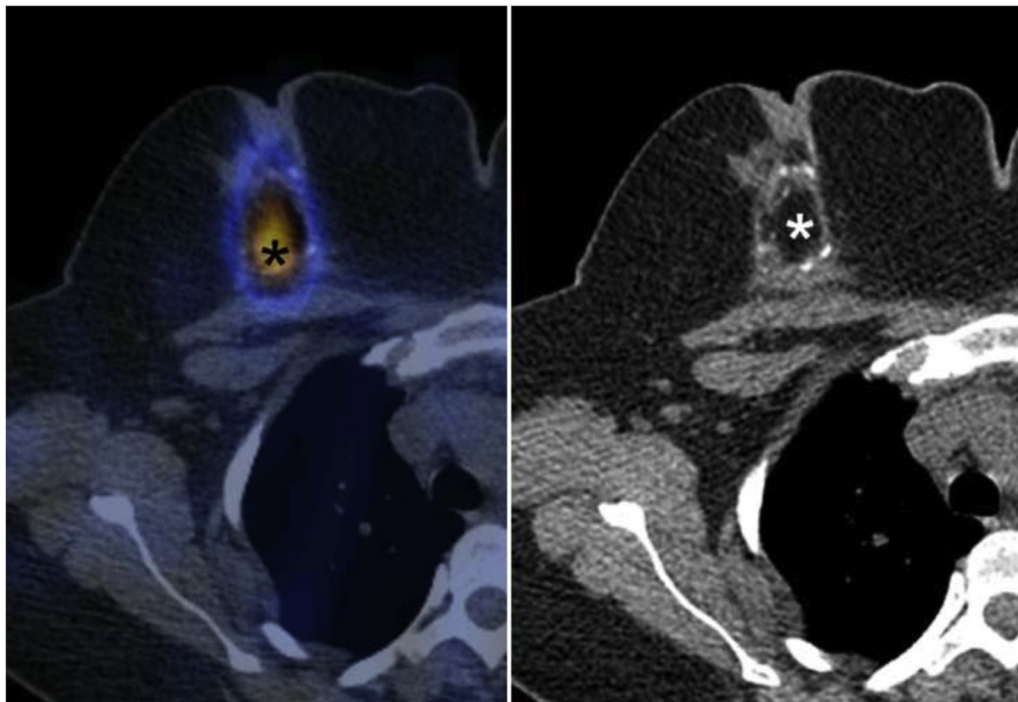


Fig. 6 – Single-photon emission computed tomography/CT demonstrating focal I-131 uptake in the right breast. The radiotracer uptake is localized to a fat containing well-defined lesion in the right breast, with surrounding rim of linear soft tissue and discontinuous linear calcifications, consistent with fat necrosis (asterisks).

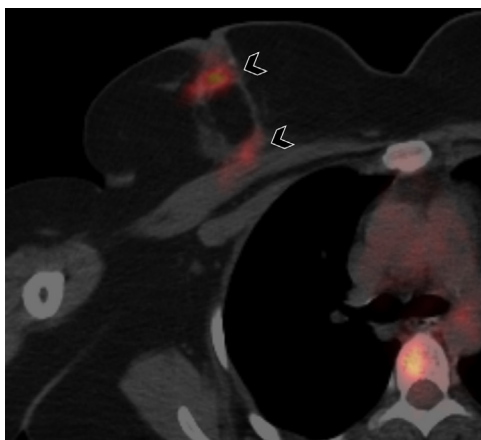


Fig. 7 – PET/CT demonstrating focal fluorodeoxyglucose (FDG) uptake in the right breast. Fused axial images from a PET/CT performed 2 years before the SPECT/CT (shown in Fig. 6). There is avid FDG uptake within the periphery of the fat necrosis in the right breast (arrowheads).

Conclusion

Poorly differentiated thyroid carcinoma represents a clinical challenge. Planar images for evaluation of metastatic disease should always be interpreted carefully, and any cases of ambiguous uptake should be investigated by SPECT-CT whenever possible. Nuclear medicine physicians and radiologists should be aware of physiologic and pathologic sites of iodine uptake. It is highly recommended to obtain all outside records of the patient before administering radioactive iodine therapy, especially for high doses.

REFERENCES

- [1] Bakheet SM, Powe J, Hammami MM. Radioiodine uptake in the chest. *J Nucl Med* 1997;38(6):984–6.
- [2] Oh JR, Ahn BC. False-positive uptake on radioiodine whole-body scintigraphy: physiologic and pathologic variants unrelated to thyroid cancer. *Am J Nucl Med Mol Imaging* 2012;2(3):362–85.
- [3] Greenler DP, Klein HA. The scope of false-positive iodine-131 images for thyroid carcinoma. *Clin Nucl Med* 1989;14(2):111–7.
- [4] Ahn BC. 12 Chapters on nuclear medicine. Rijeka, Croatia: InTech; 2011.
- [5] Bakheet SM, Hammami MM, Powe J. False-positive radioiodine uptake in the abdomen and the pelvis: radioiodine retention in the kidneys and review of the literature. *Clin Nucl Med* 1996;21(12):932–7.
- [6] Laguna R, Silva F, Vazquez-Sellés J, Orduña E, Flores C. Vertebral hemangioma mimicking a metastatic bone lesion in well-differentiated thyroid carcinoma. *Clin Nucl Med* 2000;25(8):611–3.
- [7] Shapiro B, Rufini V, Jarwan A, Geatti O, Kearfott KJ, Fig L, et al. Artifacts, anatomical and physiological variants, and unrelated diseases that might cause false-positive whole-body ¹³¹I scans in patients with thyroid cancer. *Semin Nucl Med* 2000;30(2):115–32.
- [8] McDougall IR. Whole-body scintigraphy with radioiodine-131. A comprehensive list of false-positives with some examples. *Clin Nucl Med* 1995;20(10):869–75.
- [9] Fronkova K, Vavrejn B, Fronek A. I-131 uptake by the myocardium in patients after myocardial infarct. *Cas Lek Cesk* 1964;103:64–6.
- [10] Höschl R, Choy DH, Gandeveia B. Iodine-131 uptake in inflammatory lung disease: a potential pitfall in treatment of thyroid carcinoma. *J Nucl Med* 1988;29(5):701–6.
- [11] Bakheet SM, Hammami MM. Patterns of radioiodine uptake by the lactating breast. *Eur J Nucl Med* 1994;21(7):604–8.
- [12] Hammami MM, Bakheet S. Radioiodine breast uptake in nonbreastfeeding women: clinical and scintigraphic characteristics. *J Nucl Med* 1996;37(1):26–31.
- [13] Kogai T, Taki K, Brent GA. Enhancement of sodium/iodide symporter expression in thyroid and breast cancer. *Endocr Relat Cancer* 2006;13(3):797–826.
- [14] Tazebay UH, Wapnir IL, Levy O, Dohan O, Zuckier LS, Zhao QH, et al. The mammary gland iodide transporter is expressed during lactation and in breast cancer. *Nat Med* 2000;6(8):871–8.
- [15] Hu LH, Wang SJ, Liu RS. Hyperprolactinemia-related ¹³¹I uptake in nonlactating breasts. *Clin Nucl Med* 2012;37(3):e57–8.
- [16] Chala LF, de Barros N, de Camargo Moraes P, Endo E, Kim SJ, Pincerato KM, et al. Fat necrosis of the breast: mammographic, sonographic, computed tomography, and magnetic resonance imaging findings. *Curr Probl Diagn Radiol* 2004;33(3):106–26.
- [17] Adejolu M, Huo L, Rohren E, Santiago L, Yang WT. False-positive lesions mimicking breast cancer on FDG PET and PET/CT. *AJR Am J Roentgenol* 2012;198(3):W304–14.
- [18] Hogge JP, Robinson RE, Magnant CM, Zuurbier RA. The mammographic spectrum of fat necrosis of the breast. *Radiographics* 1995;15(6):1347–56.
- [19] Ganau S, Tortajada L, Escribano F, Andreu X, Sentís M. The great mimicker: fat necrosis of the breast-magnetic resonance mammography approach. *Curr Probl Diagn Radiol* 2009;38(4):189–97.
- [20] Carballo M, Quiros RM. To treat or not to treat: the role of adjuvant radioiodine therapy in thyroid cancer patients. *J Oncol* 2012;2012:11.
- [21] Hiltzik D, Carlson DL, Tuttle RM, Chuai S, Ishill N, Shaha A, et al. Poorly differentiated thyroid carcinomas defined on the basis of mitosis and necrosis: a clinicopathologic study of 58 patients. *Cancer* 2006;106(6):1286–95.
- [22] Patel KN, Shaha AR. Poorly differentiated and anaplastic thyroid cancer. *Cancer Control* 2006;13(2):119–28.
- [23] Tuttle RM, Grewal RK, Larson SM. Radioactive iodine therapy in poorly differentiated thyroid cancer. *Nat Clin Pract Oncol* 2007;4(11):665–8.
- [24] Cabanillas ME, Waguespack SG, Bronstein Y, Williams MD, Feng L, Hernandez M, et al. Treatment with tyrosine kinase inhibitors for patients with differentiated thyroid cancer: the M. D. Anderson experience. *J Clin Endocrinol Metab* 2010;95(6):2588–95.
- [25] Thomas L, Lai SY, Dong W, Feng L, Dadu R, Regone RM, et al. Sorafenib in metastatic thyroid cancer: a systematic review. *Oncologist* 2014;19(3):251–8.