

Once in a Blue Moon ... Rare Adnexal Tumor: From the Clinical and Videodermoscopic Aspects to the Mohs Surgery and the Histological Diagnosis

Miriam Rovesti¹, Francesca Satolli^{1*}, Roberto Ricci², Roberta Manuguerra², Alfredo Zucchi¹, Marco Gandolfi¹, Serena Gianfaldoni³, Feliciani Claudio¹, Uwe Wollina⁴, Georgi Tchernev^{5,6}, Torello Lotti³

¹Department of Dermatology, University of Parma, Parma, Italy; ²Department of Pathology, University of Parma, Parma, Italy; ³University G. Marconi of Rome, Dermatology and Venereology, Rome, Italy; ⁴Städtisches Klinikum Dresden, Department of Dermatology and Allergology, 01067 Dresden, Germany; ⁵Department of Dermatology, Venereology and Dermatologic Surgery, Medical Institute of Ministry of Interior (MVR-Sofia), General Skobelev 79, 1606 Sofia, Bulgaria; ⁶Onkoderma - Polyclinic for Dermatology, Venereology and Dermatologic Surgery, General Skobelev 26, 1606, Sofia, Bulgaria

Citation: Rovesti M, Satolli S, Ricci R, Manuguerra R, Zucchi A, Gandolfi M, Gianfaldoni S, Claudio F, Wollina U, Tchernev G, Lotti T. Once in a Blue Moon ... Rare Adnexal Tumor: From the Clinical and Videodermoscopic Aspects to the Mohs Surgery and the Histological Diagnosis. Open Access Maced J Med Sci. 2018 Jan 25; 6(1):146-148. <https://doi.org/10.3889/oamjms.2018.053>

Keywords: Adnexal tumour; Eccrine adenocarcinoma; Squamoid eccrine ductal carcinoma; Videodermoscopy; Mohs surgery

***Correspondence:** Francesca Satolli. Università degli Studi di Parma Dipartimento di Medicina Clinica e Sperimentale Ringgold standard institution - Department of Dermatology, University of Parma, Parma, Italy. E-mail: fra.satolli@libero.it

Received: 20-Sep-2017; **Revised:** 02-Nov-2017; **Accepted:** 04-Nov-2017; **Online first:** 21-Jan-2018

Copyright: © 2018 Miriam Rovesti, Francesca Satolli, Roberto Ricci, Roberta Manuguerra, Alfredo Zucchi, Marco Gandolfi, Serena Gianfaldoni, Feliciani Claudio, Uwe Wollina, Georgi Tchernev, Torello Lotti. This is an open-access article distributed under the terms of the Creative Commons Attribution-NonCommercial 4.0 International License (CC BY-NC 4.0)

Funding: This research did not receive any financial support

Competing Interests: The authors have declared that no competing interests exist

Abstract

The adnexal tumours are a very heterogeneous group of lesions, more and more studied in the literature. The squamoid eccrine ductal carcinoma (SEDC) is a rare malignant variant that combines ductal structures with squamous differentiation.

We report a case of dermoscopic and histological diagnosis of SEDC, treated with Mohs Surgery and with no recurrence of a tumour after 12 months of follow up.

Introduction

Cutaneous adnexal tumours can be a diagnostic challenge for the pathologist and the dermatologist, because of the rarity and the complexity of these lesions. According to the traditional view, sweat gland tumours are divided into eccrine and apocrine. Nowadays, this classification has been modified because many of these tumours may have both eccrine and apocrine variants [1]. Squamoid eccrine ductal carcinoma (SEDC) is an extremely rare neoplasm with a tendency for local recurrence but low metastatic potential [1]. Less than

20 cases have been reported in the literature so far.

We report herein the case of an SEDC with its clinical and dermoscopic evaluation, treated with deferred Mohs surgery.

Case report

A 75 – year - old man, with a history of colon cancer and benign prostatic hypertrophy, addressed the Department of Plastic Surgery in October 2015 to

remove a nodular ulcerated lesion on the right temporal region of the face. No clinical pictures were taken. The histological diagnosis was that of a poorly differentiated squamous cell carcinoma, with acantholytic features, with perineural invasion and extended to the deep surgical margin. The patient underwent two subsequent radicalizations to reach free surgical margins.

In June 2016, the patient addressed to our Dermatologic Clinic for a recurrence of the lesion, in the same area (Figure 1).

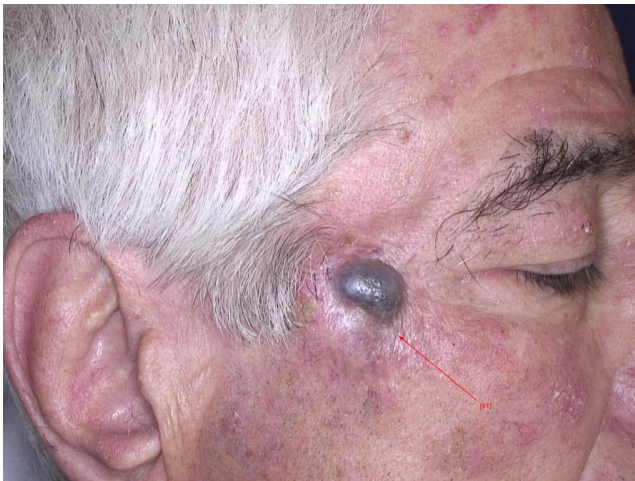

Figure 1: Bluish nodular lesion, after two months by its occurrence, at the temporal region in patient's face, in location of previous surgery

The lesion was a bluish, exophytic nodule, approximately 2 cm in diameter, soft to palpation. Contextually, a videodermoscopy was performed (Figure 2). Videodermoscopy showed a homogeneous, structureless, blue-white colour lesion with reddish - purple lacunar areas and irregular vessel at the periphery; the lesion was furthermore free of any specific criteria of melanocytic or non - melanocytic tumour.

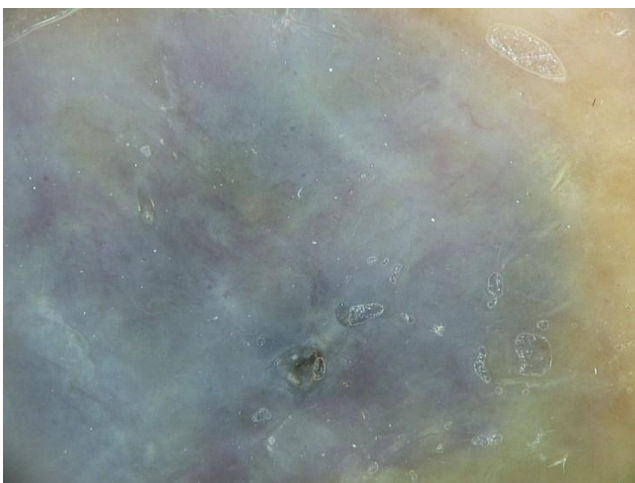


Figure 2: Videodermoscopy aspect of the lesion

In consideration of the patient's personal history and the high risk of the dermoscopic image,

deferred Mohs surgery was performed. Once established the absence of tumour cells at the margins, a dermo-epidermal skin graft was used to cover the surgical wound.

The histopathology examination showed a dermal proliferation with squamous and ductal differentiation. The lesion had an infiltrative growth pattern and perineural invasion. The final diagnosis was squamoid eccrine ductal carcinoma.

The 12 - months follow up was negative for recurrence.

Discussion

An adnexal tumour is nowadays a very huge and heterogeneous group of lesions. The rarity of this kind of lesions precludes drawing any solid conclusions concerning their line of differentiation, to the diagnosis and their biological behaviour [2].

The variety of names reflects the different approaches of authors who have emphasised a particular aspect of the neoplasm, describing it in the word itself (e.g. squamoid aspect, syringoid aspect, etc.) [2].

The terms "eccrine carcinoma" or "eccrine ductal" are used by different authors to indicate a malignant tumour with the proliferation of ductal structures. Nevertheless, because normal eccrine and apocrine ducts are indistinguishable, it is easy to confuse the two groups of lesions. [2] Moreover, the squamoid eccrine ductal carcinoma (SEDC) variant presented by our patient shows a variable degree of atypia. It combines ductal structures, usually towards the deep margin of the neoplasm, with squamous differentiation, usually towards the tumour surface (Figure 3 A, B).

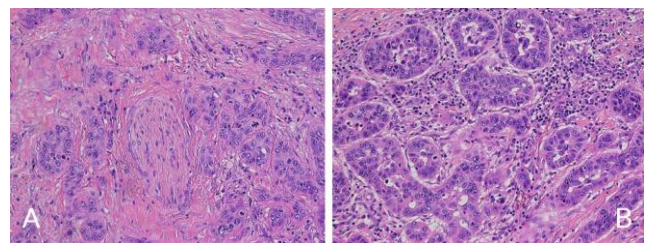


Figure 3: Histopathology revealed a dermal proliferation with squamous and ductal differentiation

The histological diagnosis is, therefore, difficult and could be confused with a squamoid tumour (like the squamous carcinoma). In particular, this misdiagnosis could be expected in superficial biopsies, which are not able to show the ductal proliferation predominant in the deeper part of a tumour [1]. Perineural and lymphovascular spread are

present in the 10% of cases [1]. Avraham et al. [3] highlight how in this rare adnexal tumour with eccrine differentiation, it's just the tumour depth and the lymphovascular invasion which are important survival factors, compared, for example, to the size of the neoplasm.

The SEDC usually presents clinically as a non - distinctive nodule or plaque on the head/neck or, less frequently, on the extremities, with a higher incidence in elderly and male patients [4]. Due to its rarity and non - specific clinical appearance, it is difficult to differentiate it from other malignant cutaneous lesions. Dermoscopy helps the diagnosis. In our case, dermoscopy revealed a blue-whitish colour structureless lesion with uneven reddish purple lacunar areas and linear irregular vessel at the periphery. Also, the lesion was free of any specific criteria of melanocytic or non - melanocytic tumour. In literature, the dermoscopic aspect of eccrine poroma and eccrine porocarcinoma is described. To our knowledge, this is the first case describing the dermoscopic aspect of an SEDC, and the blue aspect of this lesion has awakened our interest. The blue colour in dermoscopy is studied by different authors because, although it could be present in benign and malignant lesions, it is closely linked to melanoma (in particular if associated with other specific dermoscopic aspects). Our case would suggest that, albeit once in a blue moon, blue colour can be tricky and hide a rare malignant tumour, like SEDC. For this reason, if in doubt, do not hesitate in front of a dermoscopic blue lesion: cut it out.

About tumour behaviour, SEDC is a tumour with low risk of metastasis, in approximately 10% of cases has a local recurrence, as also proved by our patient (who had two recurrences of a tumour). Considering the malignancy of the lesion, the high risk of recurrence and perineural/lymph nodes invasion, an intracervical check of the margins would be desirable to reach a complete neoplasm extirpation.

Unfortunately, due to the relative rarity of SEDC, there have been no randomised studies comparing the traditional surgery with the Mohs Surgery (or other surgical treatments). However, a recent review [5] considers the three cases in the literature of SEDC treated with Mohs Surgery and highlighted the efficacy of this surgical modality for this type of a tumour (Figure 4 A, B).

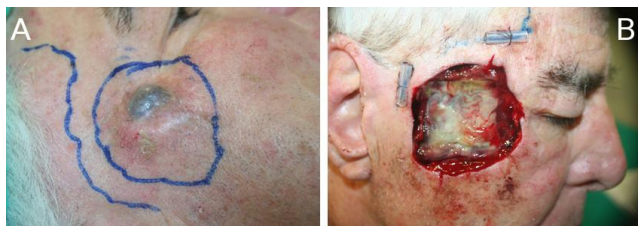

Figure 4: Before (A) and during (B) the Mohs surgery

The follow up of our patient at 12 months (Figure 5), which shows no recurrence of the lesion,

confirms it.

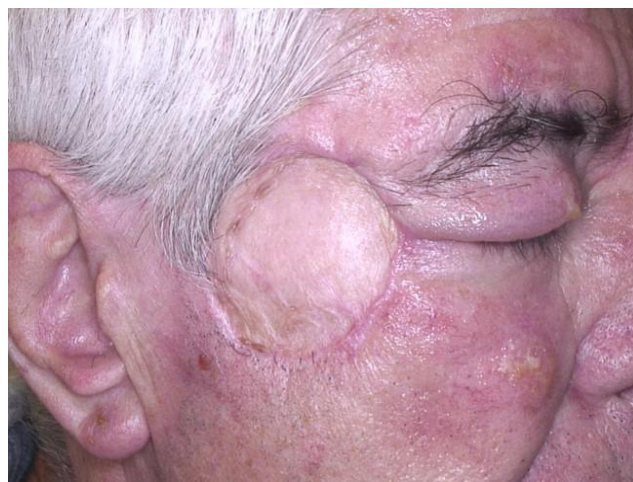

Figure 5: Follow up at 12 months

In conclusion, the squamoid eccrine ductal carcinoma (SEDC) is a rare adnexal tumour with a high risk of recurrence and perineural and lymphovascular invasion. Clinically It appears as a nodule or a plaque in elderly and male patients. An early clinical diagnosis is difficult. The dermoscopy, characterised by a blue-whitish colour and irregular reddish purple lacunar areas, could help the diagnosis. The morphology is similar to a squamous carcinoma; nevertheless, also a ductal proliferation is present in SEDC.

The Mohs Surgery is the most efficient surgical treatment for this type of neoplasm.

A close follow - up it's important to evaluate possible recurrences.

References

- Cardoso JC, Calonje E. Malignant sweat gland tumours: an update. *Histopathology*. 2015; 67: 589-606. <https://doi.org/10.1111/his.12767> PMID:26114606
- Kazakov DV, Michal M, Kacerovska D, et al. Cutaneous Adnexal Tumor. *Wolter Kluwer Health*, 2012; 1(1): 137-139.
- Avraham JB, Villines D, Maker VK, August C, Maker AV. Survival after resection of cutaneous adnexal carcinomas with eccrine differentiation: risk factors and trends in outcomes. *Journal of surgical oncology*. 2013;108(1):57-62. <https://doi.org/10.1002/jso.23346> PMID:23677677
- Van der Horst MP, Garcia-Herrera A, Markiewicz D et al. Squamoid Eccrine Ductal Carcinoma: A clinicopathologic study of 30 cases. *Am j Surg Pathol*. 2016; 40 (6):755-60. <https://doi.org/10.1097/PAS.0000000000000599> PMID:26796504
- Clark S, Young A, Piatigorsky E et al. Mohs Micrographic Surgery in the setting of squamoid eccrine ductal carcinoma. *J Clin Aesthet Dermatol*. 2013; 6(4):33-6. PMID:23630640 PMID:PMC3638851