



Low dose time-resolved CT-angiography in pediatric patients with venous malformations using 3rd generation dual-source CT: Initial experience

Thomas Henzler (MD)^a, Nils Vogler (MD)^a, Bettina Lange (MD)^b, Franz Dally^a,
Mathias Meyer (MD)^a, Stefan O. Schoenberg (MD)^a, Maliha Sadick (MD)^{a,*}

^a Institute of Clinical Radiology and Nuclear Medicine, University Medical Center Mannheim, Medical Faculty Mannheim, Heidelberg University, Theodor-Kutzer-Ufer 1-3, 68167 Mannheim, Germany

^b Department of Pediatric Surgery, University Medical Center Mannheim, Medical Faculty Mannheim, Heidelberg University, Theodor-Kutzer-Ufer 1-3, 68167 Mannheim, Germany

ARTICLE INFO

Article history:

Received 29 July 2016

Accepted 9 August 2016

Available online 12 August 2016

Keywords:

4D-CTAngiography

Venous malformation

Low dose dual-score CT

Pediatric

ABSTRACT

Objectives: To prospectively evaluate the diagnostic value and radiation dose of time-resolved CT-Angiography (4D-CTA) in pediatric patients with venous malformations using 3rd generation dual-source CT (DSCT) at 70 kVp tube voltage.

Methods: Between November 2014 and August 2015, seven children (2 male, 5 female; median age, 9 years; range 3–12 years) with suspected peripheral, non-cerebral, venous malformations were included in this feasibility study and underwent US, MRI and 4D-CTA. All three imaging modalities were analyzed and compared individually by an experienced interventional radiologist and a pediatric surgeon using a 5-point Likert scale, with regard to diagnosis of the vascular anomaly, additional information like presence of thrombophlebitis and lesion extension, flow dynamics, localization, volume and significance for treatment planning. For quantitative statistical analysis, an unifactorial analysis of variance was performed for every parameter and all three imaging modalities. Radiation dose values as expressed by the volume CT dose index (CTDI_{vol}) and dose-length product (DLP) were recorded for all patients.

Results: Three out of six patients had isolated type I venous malformations without peripheral venous drainage which could be demonstrated on MRI and CT. In two out of six patients a type II venous malformation with drainage into normal veins was diagnosed. In one case, 4D-CT was the only imaging modality that revealed a slow-flow venous malformation with shunting supply by a hypodynamic arterial feeder.

Treatment planning: 4D-CTA was rated as the best imaging modality for treatment planning with agreement between radiologist and surgeon, especially with respect to the hemodynamics of the venous malformation.

Conclusions: 4D-CTA at 70 kVp is a fast imaging modality that provides comprehensive diagnostic information of venous malformations in pediatric patients and is very valuable for therapy planning. Radiation dose of 4D-CTA must be weighted against the diagnostic information as well as the potential risk for sedation and contrast administration during MRI.

© 2016 The Author(s). Published by Elsevier Ltd. This is an open access article under the CC BY-NC-ND license (<http://creativecommons.org/licenses/by-nc-nd/4.0/>).

1. Introduction

Vascular anomalies still represent a diagnostic and therapeutic challenge for clinicians and molecular biologists all over the

world. Continuous effort is being made to understand their morphology and pathophysiology [1]. The aim is to provide appropriate therapeutic options for patients which meet the current standards of diagnostic imaging and minimally-invasive or surgical therapy [2–4].

In accordance with the International Society for the Study of Vascular Anomalies (ISSVA), these two vascular entities are classified in vascular tumors and vascular malformations [5,6]. Congenital hemangiomas are the most frequent representatives of vascular tumors and mainly affect pediatric patients [7]. They have a

* Corresponding author.

E-mail addresses: thomas.henzler@umm.de (T. Henzler), nils.vogler@umm.de (N. Vogler), bettina.lange@umm.de (B. Lange), franz.dally@gmx.de (F. Dally), mathias.meyer@umm.de (M. Meyer), stefan.schoenberg@umm.de (S.O. Schoenberg), maliha.sadick@umm.de (M. Sadick).

Table 1
Multiplanar MRI protocol on a 1.5 Tscanner.

Sequence	Repetition Time (TR)	Echo Time (TE)	Slice Thickness	Flip Angle α	Matrix
TIRM (Turbo Inversion Recovery Magnitude Sequence)	3830 ms	79 ms	4 mm	150°	256 × 256
T1 TSE (Turbo Spin Echo Sequence) pre and post contrast	500 ms	21 ms	4 mm	180°	318 × 320
T2 TSE (Turbo Spin Echo Sequence)	4160 ms	70 ms	6 mm	120°	384 × 258
TWIST Angiography (Time Resolved Angiography with Stochastic Trajectories)	2.87 ms	1 ms	3 mm	24°	384 × 384
T1 FS TSE (Fat Suppressed Turbo Spin Echo) post contrast	680 ms	17 ms	4 mm	150°	1145 × 1372

high degree of spontaneous regression and very rarely require minimally-invasive or surgical therapy [8].

Venous malformations (VMs) are most common with an incidence of 70–80% [9–11], whereas lymphatic and arteriovenous malformations are rare with an incidence of 2–10% and 5–15%, respectively [12]. The clinical aspect of VMs can vary between a localized solid or spongy compressible mass and a malformation with extensive manifestation in many parts of the body, involving soft tissue, inner organs and extremities. Especially in venous malformations a bluish dermal shimmer may facilitate diagnosis. Patient's history, physical examination and symptoms like recurrent thrombophlebitis with localized swelling and pain are important for diagnosis.

Ultrasound with duplex mode (US) and magnetic resonance imaging (MRI) are established imaging modalities for characterization and diagnosis of vascular anomalies [4,10]. Especially in pediatric imaging, US and MRI can provide dynamic and cross-sectional multi-planar diagnostic information in absence of radiation exposure. However, both techniques have also shortcomings which have to be considered. US is often limited regarding image post-processing as well as depiction of VMs complete extension and also depends on the experience of the clinician, performing it. MRI has the disadvantage of long examination times that often require sedation or anesthesia and iv contrast which is an ongoing matter of debate regarding harmful effects for brain development in pediatrics [13]. Moreover, reports about gadolinium deposition in the brain have led to growing concerns regarding the administration of gadolinium-based contrast agents in pediatric patients [14].

Recently, time-resolved CT-Angiography (4D CTA) over a wide z-axis coverage in combination with low tube voltage settings down to 70 kVp has become clinically available. Low tube voltage settings have the inherent advantage for significant radiation dose reduction since the radiation dose roughly changes with the square of the tube voltage [15]. Moreover, 70 kVp studies lead to a greater attenuation of iodinated contrast material due to the lower mean photon energy of the x-ray spectrum that leads to a greater photoelectric effect and increased Compton scattering [16].

Thus, the aim of this feasibility study was to evaluate radiation dose and the diagnostic value of 4D-CTA in pediatric patients with suspected VMs.

2. Materials and methods

2.1. Study population

This prospective single-centre study was approved by our institutional review board and complies both with the Declaration of Helsinki and the Health Insurance Portability and Accountability Act (HIPAA). Written informed parental consent was obtained for all participating patients prior to the 4D-CTA examination. Between November 2014 and August 2015, seven children (2 male, 5 female, median age, 9 years; range 3–12 years) with suspected venous malformations were included in this feasibility study. Vascular malformations of the head and neck region and intracranial

lesions were excluded from the study. Admission diagnosis in all children was functional impairment with uncontrollable pain and local or generalized swelling due to failure of conservative treatment attempts like compression bandage therapy, analgetic and anticoagulation therapy. The patients were referred to our interdisciplinary vascular anomaly center for assessment of possible minimal-invasive treatment. The localization of the vascular malformations in the patients was foot (n=3), thigh (n=1), buttock (n=1), upper arm (n=1) and hand (n=1).

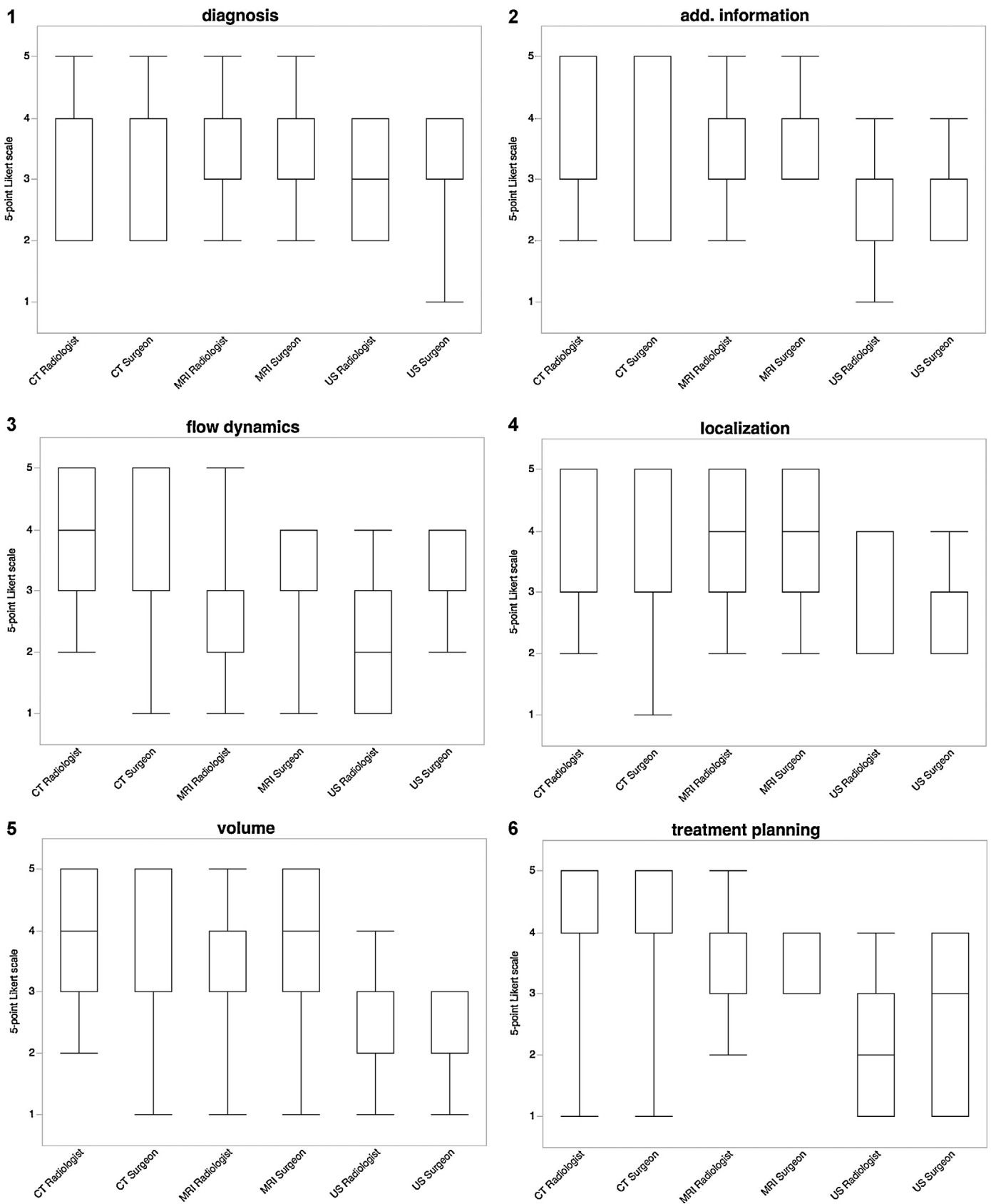
2.2. Imaging and image processing

After taking patient's medical history, clinical examination and thorough inspection of the lesion, all children underwent a detailed US examination followed by MRI and 4D-CTA.

US was performed by an experienced radiologist on an IU22 x matrix US System (Philips Healthcare GmbH, Hamburg, Germany) with a 12 MHz probe, and if required for small anatomical structures like hand and fingers, with a 17 MHz linear array transducer. For vascular tissue imaging, application of a color power Doppler US was mandatory.

After US all patients underwent MRI which is part of our institutional routine work-up of pediatric patients with VMs. All MRI examinations were performed on a 1.5 Tesla System (Magnetom Avanto Siemens Healthineers, Erlangen, Germany). Table 1 summarizes the MRI protocol. For contrast enhanced MRI 0.2 ml/kg bodyweight of a macrocycle-structured gadolinium-based contrast agent (Dotarem®, Guerbet GmbH Germany) was injected via an antecubital vein using a syringe pump.

All study related 4D-CTA examinations were performed on a 3rd generation dual-source CT (DSCT) System (Somatom FORCE, Siemens Healthineers, Forchheim, Germany). The following scan parameters were applied: 70 kVp tube voltage, 90 mAs tube current time-product, 48 × 1.2 collimation, 4-dimensional spiral mode with variable pitch with a z-axis coverage of 14.8 cm. In all patients 6 spiral acquisitions were performed with a variable interscan delay. The first acquisition was started 12 s after the start of the contrast injection followed by the 2nd phase after 18 s; 3rd phase after 24 s; 4th phase after 48 s; 5th phase after 84 s; 6th phase after 120 s. The variable inter-scan delay was chosen in order to have one non-contrast phase for the assessment of potential calcifications in the vascular anomaly as a potential sign of thrombophlebitis, 2 arterial phases for the assessment of presence of arterial feeder as well as four venous phases for the evaluation of the venous filling of the lesions over time. Contrast injection was performed via an antecubital vein with a flow rate of 3–4 ml/s using 1 ml iomeprol 400/kg body weight (Imeron® 400 MCT, Bracco, Italy). Images were reconstructed with a slice thickness of 0.75 mm and a reconstruction increment of 0.45 mm using filtered back projection with a dedicated vascular reconstruction kernel (Bv36, Siemens Healthcare Sector, Forchheim, Germany). The CT dose index (CTDIvol) and the dose-length product (DLP) of the scan acquisition was 5.18 mGy and 72 mGycm.



Figs. 1–6. Quantile box-plot analysis of the diagnostic parameters.

The six diagnostic parameters “correct diagnosis of the vascular anomaly (Fig. 1), additional information gained by imaging (Fig. 2), flow dynamics (Fig. 3), localization (Fig. 4), volume (Fig. 5) and significance of imaging for treatment planning (Fig. 6)” were compared and assessed using a 5-point Likert scale (1: strongly disagree, 2: disagree, 3: undecided/indifferent, 4: agree, 5: strongly agree) by a pediatric surgeon and the treating interventional radiologist separately for US, MRI and 4D-CT.

2.3. Comparison of diagnostic imaging modalities

All three imaging modalities were independently analyzed by an experienced interventional radiologist (R) and a pediatric surgeon (S) regarding the following diagnostic aspects using a 5-point Likert scale (1: strongly disagree, 2: disagree, 3: undecided/indifferent, 4: agree, 5: strongly agree):

- diagnosis of the vascular anomaly (venous, arteriovenous or lymphatic malformation)
- additional information gained by imaging (presence of thrombophlebitis, lesion extension)
- flow dynamics of the vascular anomaly (slow-flow, fast-flow)
- localization of the vascular anomaly
- volume of the vascular anomaly
- significance of diagnostic information regarding treatment planning

2.4. Statistical analysis

Statistical analysis was conducted using JMP 11 (SAS Institute, Cary, NC, USA). For quantitative statistical analysis median, minimum, maximum as well as the 10%, 25%, 75% and 90% quantiles were calculated separately for every parameter, all three imaging modalities and individually by each reader. Results were displayed as quantile box-plots for every parameter separately (Figs. 1–6). We refrained from calculating a kappa inter-rater agreement due to the small sample size.

3. Results

3.1. Study population

In 6 out of 7 patients, a slow-flow venous malformation without fast-flow arterio-venous shunting was suspected in US. All lesions were also correctly diagnosed using MRI and 4D CTA. In one 4-year old male patient with suspected venous malformation, increasing pain and a palpable mass on the dorsum of the foot, an US guided biopsy had to be performed in order to rule out malignancy. Histology demonstrated granuloma annulare, a benign inflammatory dermatosis.

Three out of the six patients with venous malformations suffered from isolated type I venous malformations (12, 13) without peripheral venous drainage which could be demonstrated on MRI and 4D CTA. In two out of six patients, a type II venous malformation with drainage into normal veins was diagnosed on US, MRI and 4D CTA. In one case, 4D CTA was the only imaging modality that depicted a slow-flow venous malformation with shunting supply by hypodynamic arterial feeder.

Out of the seven patients that underwent all three imaging modalities, the three youngest patients aged three, four and seven years required analgesation with anaesthesia *stand-by* for MRI, with total MRI examination times ranging between 40–50 min. The total examination time was less than 15 min for 4D CTA, wherefore only two patients (three and four years old) required analgesation with anaesthesia *stand-by*.

3.2. Comparison of diagnostic imaging modalities

The evaluation of the six parameters “correct diagnosis of the vascular anomaly, additional information gained by imaging, flow dynamics, localization, volume and significance of imaging for treatment planning” varied for US, MRI and 4D CTA. (Figs. 1–6).

US was suited for initial screening but not sufficient for precise diagnosis and treatment planning. For additional information on

the vascular anomaly, like arterio-venous vascular supply, with or without shunts, of the lesion and possible thrombophlebitis, both readers agreed on 4D CTA (median 5 [S] and 5 [R]). For assessment of flow dynamics and differentiation between fast-flow and slow-flow lesions, the radiologist agreed on CT (median 5 [S] and 4 [R]), as there were 6 spiral acquisitions with variable interscan delay covering arterial inflow phase to venous outflow and parenchymal phase. For evaluation of localization of the vascular anomaly, radiologist and surgeon showed more or less similar results on the Likert Scale for MRI (median 4 [S] and 4 [R]) and CT (median 5 [S] and 5 [R]) with consensus agreement on both modalities. Compared to ultrasound, both cross-sectional imaging modalities allowed precisely for delineation between intraosseous, intramuscular, sub- and epifascial localization. Figs. 1–6 demonstrate the results of the quantitative unifactorial analysis for US, MRI and CT.

As far as the clinical diagnostic information prior to intervention is concerned, all three modalities demonstrated different results. Fig. 7a–d, shows US images with a 17 MHz linear array transducer of a seven years old girl with a slow-flow venous malformation in her third and fourth finger (Fig. 7c). US displays several malformed dilated hypoechoic venous clusters (Fig. 7a–b) with partial central thrombosis (Fig. 7d), located subcutaneously and epifascial. Full extension of the lesion and flow dynamics could not be assessed fully with this modality.

MRI was performed for further characterization of flow dynamics and potential arterial feeder. MRI indeed displayed extension of the malformation focally in the hand (Fig. 8a). Due to long scanning time and patient movement, diagnostic information of TWIST angiography was limited and not sufficient for therapy planning (Fig. 8b).

Low dose 4D-CTA on a 3rd generation dual-source CT system was completed in this seven years old patient within 120s without necessity of analgesation. Diagnostic information on flow dynamics of the vascular malformation were very valuable for the interventional procedure. Unlike initially expected, the venous malformation showed hypodynamic arterial feeder draining into the lesion, which were displayed in early phase of the 4D CTA, 18 and 24 s post contrast injection (Fig. 9). However, the main part of the venous malformation was supplied by venous inflow and outflow vessels, interventional treatment could be limited to direct percutaneous venous sclerotherapy of the vascular anomaly without additional transcatheter arterial embolization.

4. Discussion

There is a growing interdisciplinary diagnostic, clinical and scientific approach to vascular anomalies in pediatric patients, as early diagnosis and treatment help to establish and improve life quality for the affected patients [2,17]. The earlier correct diagnosis is established, the sooner the patient can be directed towards therapy which includes a vast spectrum of conservative and minimal-invasive procedures. Surgical intervention can be avoided when diagnostic approach and treatment are not delayed [18]. In the interdisciplinary treatment of patients with vascular anomalies, imaging plays an essential role, as it gives information on localization, depth, extension and vascular composition of the malformation and thus significantly impacts treatment strategies [19]. In diagnostic radiology, not only the choice of the imaging modality has to be considered in pediatric patients but undoubtedly also radiation dose issues, especially when using time-resolved CT-angiography (4D-CTA) in pediatric patients, considering, that minimal-invasive interventional therapy might also involve radiation exposure in case of angiography with transcatheter embolization or phlebography with sclerotherapy.

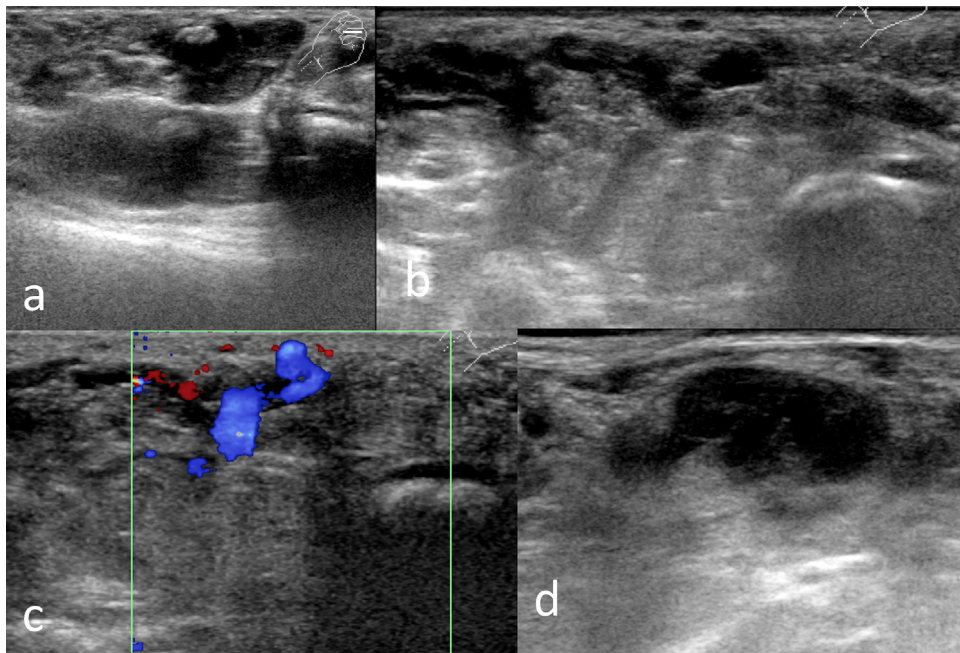


Fig. 7. a–d: Ultrasound with a 17 MHz linear array transducer of the left hand of a seven years old patient with a slow-flow venous malformation. Ultrasound displays several malformed dilated hypoechoic venous clusters (Fig. 2a–b) with partial central thrombosis (Fig. 2d), located subcutaneously and epifascial. Slow-flow characteristics on ultrasound (Fig. 2c).

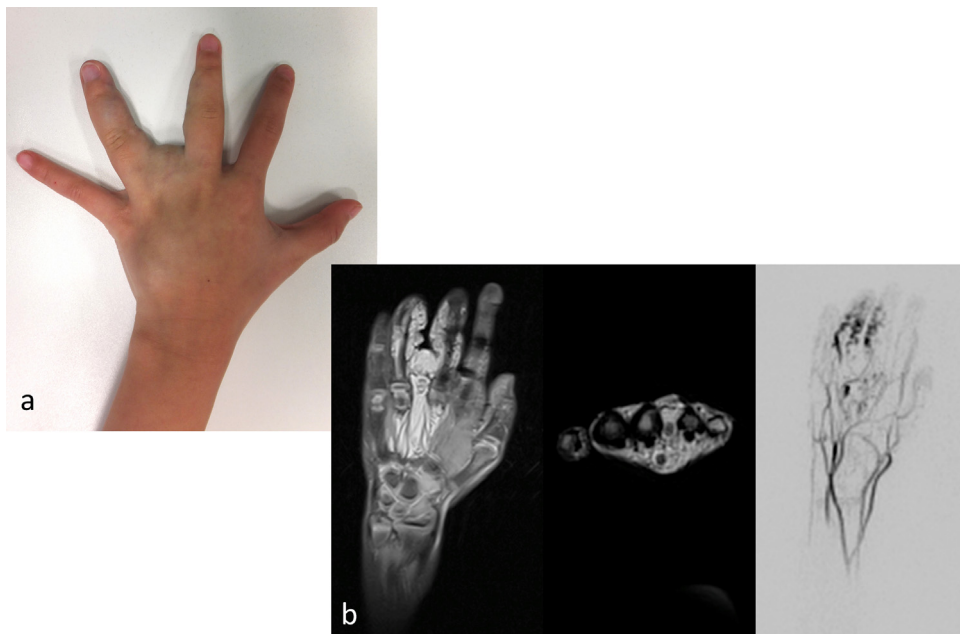


Fig. 8. a–b: Clinical impression of the VM and MRI with TWIST angiography. MRI was performed for further characterization of flow dynamics and potential arterial feeder. Good MRI delineation of the extension of the malformation in the hand (Fig. 3a). Limited diagnostic information on TWIST angiography (Fig. 3b).

US and MRI are commonly used diagnostic modalities for assessment of vascular anomalies. However, US and MRI have some limitations in pediatric patients with vascular malformations which have to be considered. US as a widely available and easy-to-use imaging modality is highly operator dependent and often cannot display the complete extension of vascular anomalies which is required for sufficient pre-procedural treatment planning in order to minimize diagnostic fluoroscopy during an intervention. Cross sectional imaging with MRI ideally combines soft tissue demarcation with 4D vascular information at the price of

examination times that usually extend 40 min. Therefore, especially in younger patients, sedation and anesthesia are frequently required in order to avoid non-diagnostic examinations. However, the use of anesthesia for diagnostic purpose in pediatric patients is a matter of ongoing debate due to potential harmful side effects on pediatric brain development [20]. Thus, the “uncomfortable reality” is that anesthesia should be avoided whenever possible in pediatric patients. Moreover, recent reports on gadolinium deposition within the brain of pediatric patients that underwent contrast enhanced MRI have raised concerns about potential harmful effects in

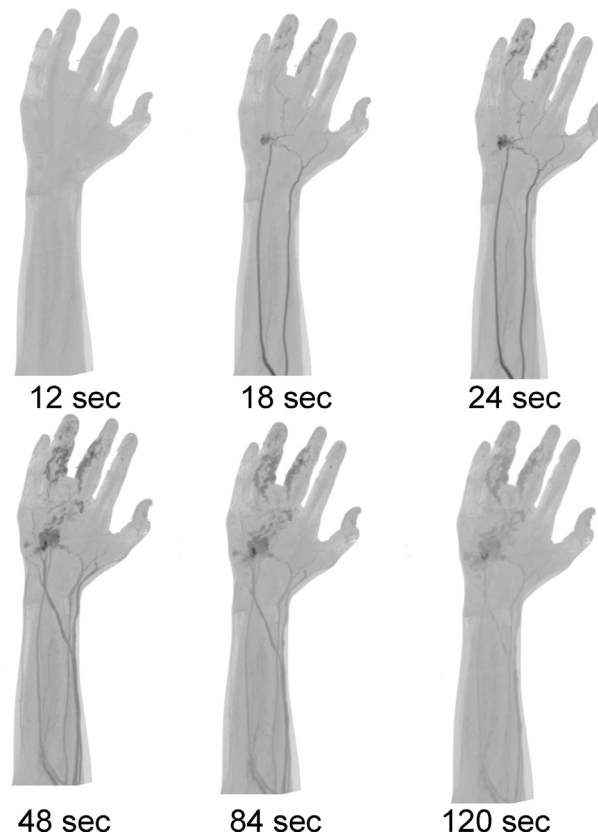


Fig. 9. Low dose 4D-CT on a 3rd generation dual-source CT system.

The venous malformation showed hypodynamic arterial feeder draining into the lesion, which were displayed in early phase CT-A, 18 and 24 s post contrast injection. But as the main part of the venous malformation was supplied by venous inflow and outflow vessels, interventional treatment could be limited to direct percutaneous venous sclerotherapy of the vascular anomaly without additional transcatheter arterial embolization.

pediatric patients. Although, one has to acknowledge that the clinical significance of gadolinium deposition in the brain of adult patients is not fully analyzed, the impact on the developing brain remains unclear. Given this uncertainties, clinicians should use prudence in selecting pediatric patients to undergo contrasted MRI [21].

Until now, CT and especially 4D-CTA have not been widely used in pediatric patients due to concerns on radiation exposure. However, due to the above mentioned limitations of contrast MRI and significant improvements in CT technology we aimed to investigate the usefulness of 4D CTA as an imaging alternative in pediatric patients with vascular malformations. The low tube voltage protocol used in our study led to a very low, and in our opinion, tolerable radiation dose with a DLP of 72 mGycm. Currently no data exists on the performance of 4D-CTA for the diagnosis of venous malformations in pediatric patients. However, over the last years, CT with *state-of-the-art* CT systems has been more widely used especially within the context of cardiothoracic imaging in which diagnostic sedation is also not necessary with CT [22,23]. Our goal was to investigate the impact of pre-therapeutic low dose 4D CTA with regard to scan time, radiation exposure, need for anesthesia and diagnostic outcome. Sedation was less frequently required for 4D CTA compared to MRI and at the same time resulted in superior image quality with improved diagnostic information. Thus, low tube voltage 4D CTA with a maximum reduction of the z-axis coverage can be used as an alternative to contrast MRI for diagnosis and therapy planning in patients with vascular malformations. The risk of the low radiation dose that can be achieved with 70 kVp 4D CTA has to be weighted against the risk of sedation as well as potential harmful effects of gadolinium based contrast material.

Our study has some limitations that have to be considered. First, our study population is small due to the low disease prevalence. Moreover, we only included pediatric patients in which US was not sufficient for accurate therapy planning and who presented with clinical impairment that required interventional treatment. Secondly, all of our 4D CTA examinations were performed on a *high-end* 3rd generation DSCT which is not widely available. Thus our findings are not transferable to older CT system generations that may not allow dynamic 4D CTA or only with significantly higher radiation dose levels.

In conclusion, 4D CTA at 70 kVp is a fast imaging modality that provides all diagnostic information for therapy planning in patients with venous malformations without sedation.

Acknowledgments

This research project is part of the Research Campus M²OLIE and funded by the Bundesministerium für Bildung und Forschung (BMBF) within the Framework “Forschungscampus: public-private partnership for Innovations” under the funding code 13GW00926.

Dr. Henzler receives additional research funding from Siemens Healthineers and Bracco which is not related to the present article.

Dres. Vogler, Lange, Meyer and Sadick have no conflicts of interest or financial ties to disclose.

References

- [1] P. Wojcicki, K. Wojcicka, Epidemiology, diagnostics and treatment of vascular tumors and malformations, *Adv. Clin. Exp. Med.* 23 (2014) 475–484.

- [2] K.A. Mattila, K. Kervinen, T. Kalajoki-Helmio, et al., An interdisciplinary specialist team leads to improved diagnostics and treatment for paediatric patients with vascular anomalies, *Acta Paediatr.* 104 (2015) 1109–1116.
- [3] B.B. Lee, I. Baumgartner, P. Berlien, et al., Diagnosis and treatment of venous malformations consensus document of the International Union of Phlebology (IUP): updated 2013, *Int. Angiol.* 34 (2015) 97–149.
- [4] S. Pimpalwar, Vascular malformations: approach by an interventional radiologist, *Semin. Plast. Surg.* 28 (2014) 91–103.
- [5] J.B. Mulliken, P.E. Burrows, S.J. Fishman, Mulliken & Young's Vascular Anomalies, Hemangiomas and Malformations, second ed., Oxford University Press, 2013, pp. 327–392.
- [6] M. Wassef, F. Blei, D. Adams, et al., Vascular anomalies classification: recommendation from the international society for the study of vascular anomalies, *Pediatrics* 136 (2015) 203–2014.
- [7] J.B. Mulliken, J. Glowacki, Hemangiomas and vascular malformations in infants and children: a classification based on endothelial characteristics, *Plast. Reconstr. Surg.* 69 (3) (1982) 412–422.
- [8] J.B. Mulliken, S.J. Fishman, P.E. Burrows, Vascular anomalies, *Curr. Probl. Surg.* 37 (8) (2000) 517–584.
- [9] J.B. Mulliken, P.E. Burrows, S.J. Fishman, Mulliken & Young's Vascular Anomalies, Hemangiomas and Malformations, second ed., Oxford University Press, 2013, pp. 645–710.
- [10] S.K. Thawait, K. Puttgen, J.A. Carrino, et al., MR imaging characteristics of soft tissue vascular anomalies in children, *Eur. J. Pediatr.* 172 (5) (2013) 591–600.
- [11] R.K. Clemens, T. Pfammatter, T.O. Meier, A.I. Alomari, B.R. Amann-Vesti, Vascular malformations revisited, *Vasa* 44 (2015) 5–22.
- [12] S. Puig, H. Aref, V. Chigot, et al., Classification of venous malformations in children and implications for sclerotherapy, *Pediatr. Radiol.* 33 (2003) 99–103.
- [13] G. Stratmann, Neurotoxicity of anesthetic drugs in the developing brain, *Anesth. Analg.* 113 (5) (2011) 1170–1179.
- [14] D.R. Roberts, K.R. Holden, Progressive increase of T1 signal intensity in the dentate nucleus and globus pallidus on unenhanced T1-weighted MR images in the pediatric brain exposed to multiple doses of gadolinium contrast, *Brain Dev.* 38 (3) (2016) 331–336.
- [15] T. Niemann, S. Henry, A. Duhamel, J.B. Faivre, A. Deschildre, L. Colas, T. Santangelo, J. Remy, et al., Pediatric chest CT at 70 kVp: a feasibility study in 129 children, *Pediatr. Radiol.* 44 (11) (2014) 1347–1357.
- [16] M. Meyer, H. Haubenreisser, U.J. Schoepf, et al., Closing in on the K edge: coronary CT angiography at 100, 80, and 70 kV-initial comparison of a second- versus a third-generation dual-source CT system, *Radiology* 273 (2) (2014) 373–382.
- [17] J.N. Noshier, P.G. Murillo, M. Liszewski, et al., Vascular anomalies: a pictorial review of nomenclature, diagnosis and treatment, *World J. Radiol.* 28 (6) (2014) 677–692.
- [18] W.A. Wohlgemuth, K. Wölfle, T. Schuster, et al., Hereditary vascular malformations: classification, symptoms, diagnostics and prognosis, *Zentralbl. Chir.* 137 (2012) 440–445.
- [19] M.E. Lidsky, J.N. Markovic, M.J. Miller, et al., Analysis of the treatment of congenital vascular malformations using a multidisciplinary approach, *J. Vasc. Surg.* 56 (2012) 1355–1362.
- [20] G.E. Mann, M. Kahana, The uncomfortable reality . . . we simply do not know if general anesthesia negatively impacts the neurocognitive development of our small children, *Int. J. Pediatr. Otorhinolaryngol.* 79 (9) (2015) 1379–1381.
- [21] D.R. Roberts, K.R. Holden, Progressive increase of T1 signal intensity in the dentate nucleus and globus pallidus on unenhanced T1-weighted MR images in the pediatric brain exposed to multiple doses of gadolinium contrast, *Brain Dev.* 38 (3) (2016) 331–336.
- [22] F.G. Meinel, T. Henzler, U.J. Schoepf, P.W. Park, W. Huda, J.V. Spearman, K.T. Dyer, A.G. Rao, A.M. Hlavacek, ECG-synchronized CT angiography in 324 consecutive pediatric patients: spectrum of indications and trends in radiation dose, *Pediatr. Cardiol.* 36 (3) (2015) 569–578.
- [23] C. Hagemstein, T. Henzler, H. Haubenreisser, M. Meyer, S. Sudarski, S.O. Schoenberg, K.W. Neff, M. Weis, Ultra-high pitch chest computed tomography at 70 kVp tube voltage in an anthropomorphic pediatric phantom and non-sedated pediatric patients: initial experience with 3(rd) generation dual-source CT, *Z. Med. Phys. (Dec (15))* (2015), <http://dx.doi.org/10.1016/j.zemedi.2015.11.002>, pii: S0939-3889(15)00148-8.