

Can early endoscopic ultrasound predict pancreatic necrosis in acute pancreatitis?

Surinder S. Rana, Deepak K. Bhasin, Vishal Sharma, Ravi Sharma, Vinita Chaudhary, Puneet Chhabra

Post Graduate Institute of Medical Education and Research (PGIMER), Chandigarh, India

Abstract

Background Presence of pancreatic/extrapancreatic necroses (PN/EPN) is an important prognostic indicator in acute pancreatitis (AP) and their early detection is a challenge. Endoscopic ultrasound (EUS) provides high resolution images of pancreas but there is paucity of data on its role in AP.

Methods Consecutive patients with AP seen at our center from December 2012-November 2013 and presenting within 5 days of onset of symptoms were prospectively enrolled. EUS was done on the day of admission with a radial echoendoscope and pancreatic/peripancreatic findings were compared with the abdominal computed tomography (CT) findings performed on day 7.

Results Of the 46 patients evaluated, 14 were excluded, and 32 patients (22 male; age 40.68 ± 12.46 years) underwent EUS at admission. The etiology of AP was alcohol in 16, gallstones in 13, and idiopathic in 3 patients. Necrotizing pancreatitis was present in 20 (62%) patients, and mean CT severity index was 6.45 ± 2.96 . In patients without PN (n=12), EUS revealed normal echo pattern in 6 patients and diffusely hyperechoic and enlarged pancreas in 6 patients. In patients with PN/EPN, EUS revealed multiple hypoechoic areas (>5 mm) in 5 patients, multiple hyperechoic areas (>5 mm) in 7 patients and mixed hypo and hyperechoic areas in 8 patients. Also, 13 of these patients had peripancreatic hypoechoic areas that correlated with EPN. Moreover, EUS detected common bile duct (CBD) stones in two patients, pleural effusion in 17 patients, and ascites in 15 patients.

Conclusion EUS done at admission can reliably detect PN and co-existent disorders like CBD stones.

Keywords Endosonography, acute pancreatitis, pancreatic necrosis

Ann Gastroenterol 2014; 27 (4): 404-408

Introduction

Acute pancreatitis (AP) is a complex acute inflammatory disorder of the pancreas and surrounding tissues that is usually mild in majority of the patients [1]. However, the clinical course of this disease is highly variable and in up to 20% of the patients the attack may be severe leading on to a variety of local and systemic complications, a prolonged hospital stay, and significant morbidity and mortality [1-4]. The factors that determine the severity of AP have not been completely understood, and hence it is difficult to predict the clinical course of patients with AP [1-4].

Pancreatic necrosis (PN) develops in up to 15% of patients with AP, and the patients with PN have markedly increased morbidity and mortality as compared to patients with non-necrotizing interstitial pancreatitis [5,6]. The majority of the patients who develop organ failure as well as life threatening complications of AP have necrotizing pancreatitis [7]. The increased morbidity and mortality in this subgroup of patients can be reduced by detecting the PN accurately and early in the course of the disease so that appropriate preventative measures, such as fluid resuscitation and intensive care monitoring, can be timely instituted. PN is currently detected by the loss of vascular enhancement on computed tomography (CT) or magnetic resonance imaging [7]. However, on cross sectional imaging the signs of PN evolve over several days, and therefore its full extent may not be completely apparent on a contrast-enhanced CT for up to 3 days after the disease onset. Therefore, an early CT may not be able to detect PN or may underestimate its extent. There have been attempts to develop investigational modalities that may help in early detection of necrotizing pancreatitis.

Endoscopic ultrasound (EUS) is a minimally invasive investigational modality that provides high resolution images of the pancreas. The close proximity of the transducer to the

Department of Gastroenterology, Post Graduate Institute of Medical Education and Research (PGIMER), Chandigarh, 160012, India

Conflict of Interest: None

Correspondence to: Dr Surinder Singh Rana, Assistant Professor, Department of Gastroenterology, Post Graduate Institute of Medical Education and Research (PGIMER), Chandigarh, 160012, India, Tel.: +91 172 2749123, Fax: +91 172 2744401, e-mail: drsurinderrana@yahoo.co.in

Received 10 May 2014; accepted 3 July 2014

pancreas and absence of interfering intestinal gases results in high spatial resolution images that are superior to those provided by CT and magnetic resonance imaging [8,9]. Due to these advantages, EUS has been shown to be a useful modality for evaluation of various pancreatic disorders, such as determining the etiology of idiopathic AP and evaluation of chronic pancreatitis as well as pancreatic tumors [8-10]. However, there is paucity of data on the role of EUS in the assessment of severity of pancreatitis and detection of PN [11-14]. Also, the parenchymal features on EUS of AP especially pancreatic and extra-PN (EPN) have not been well described in the literature. As EUS provides high resolution images of the pancreas, we hypothesized that EUS may be able to detect pancreatic abnormalities earlier than the conventional cross sectional imaging like CT and we conducted this prospective study to evaluate the EUS features of both acute interstitial pancreatitis and acute necrotizing pancreatitis at admission and compare them with the radiological findings obtained on CT done on the 7th day of admission.

Patients and methods

Consecutive patients with AP seen at our unit from December 2012-November 2013 were prospectively included in the study. Patients with no contraindication to EUS and presenting to us within 5 days of onset of symptoms were enrolled. Those with coronary artery disease/pre-existing cardiac disorder or respiratory disorder, malignancy, pregnancy, underlying chronic pancreatitis, pancreatic malignancy, and patients refusing consent for participation in the study were excluded. An informed consent was obtained from all patients prior to the study initiation and the study protocol was approved by the institute ethics committee. Patients were given standard medical care throughout the study period. All the participants of this study were thoroughly interviewed, and subjected to clinical and laboratory examination. Diagnosis of AP was based on suggestive clinical history (acute onset upper abdominal pain with or without radiation to back, vomiting, constipation, and obstipation), physical examination, and elevated serum amylase to greater than three times the upper limit of normal and/or positive abdominal imaging [16]. Hematological investigations, blood sugar, serum amylase, blood urea, serum creatinine, albumin, globulin, lipid profile, calcium, phosphate, arterial blood gas analysis, and liver function tests were done on the day of admission. The etiology of AP was based on the patient's history of alcohol and drug use, biochemical investigations, transabdominal ultrasonography, and radiological findings.

All patients diagnosed with AP underwent EUS on the day of admission by either of the two experienced endosonologists (SSR, DKB) using a radial echoendoscope (EG-3670 URK radial echoendoscope, Pentax Corp., Japan or GF-UE 160 radial echoendoscope, Olympus Corp., Japan) at a frequency of 7.5 MHz. EUS was performed with the patient in the left lateral decubitus position under conscious sedation with

intravenous midazolam (2.5-5 mg). The uncinate process and head of pancreas were evaluated from the duodenum, and the body and tail of the pancreas was evaluated from the stomach. On EUS the echo pattern of the pancreas was evaluated and any hyperechoic or hypoechoic foci/areas in the pancreas were sought. Presence of ascites or pleural effusion as well as any peripancreatic collection was also noted. The gallbladder as well as common bile duct (CBD) was evaluated for presence of stones and the mediastinum was evaluated for presence of lymph nodes. EUS elastography has been available to us for the last 8 months and patients with EPN seen during that period also underwent elastography.

An abdominal contrast-enhanced CT scan was performed in all the patients on day 7 of onset of symptoms, and presence of PN/EPN recorded. PN was defined as focal or diffuse areas of non-enhanced pancreatic parenchyma on contrast-enhanced CT whereas EPN was defined as extrapancreatic morphological changes more than simple fat stranding [17].

Statistical analysis

The descriptive data was presented as percentages for categorical variables and mean \pm SD for quantitative variables. The patients were divided into two groups: with and without PN and the various EUS findings were compared in both groups.

Results

Of the 46 patients evaluated for enrolment in the study, 10 did not undergo EUS (severely hypoxemic: 3; hemodynamically unstable: 3; refused consent: 4) and were excluded from the study. Also, 4 more patients were excluded from the final analysis as they had underlying chronic pancreatitis. Eventually 32 patients (22 male; age 40.68 ± 12.46 years) with AP were included in the study and underwent EUS within 24 h from admission. The etiology of AP was alcohol in 16 (50%); gallstones in 13 (41%); and idiopathic in 3 (9%) patients. On CT, PN was present in 20 (62%) patients and the mean CT severity index was 6.45 ± 2.96 . Thirteen (41%) patients with PN also had EPN, 17 (53%) patients had pleural effusion, and 15 (47%) patients had ascites. None of the patients had EPN alone.

EUS findings in patients without PN (n=12)

In patients without PN (n=12), EUS revealed normal echo pattern in 6 patients, and diffusely hyperechoic and enlarged pancreas in 6 patients, with acute peripancreatic fluid collection in two patients (Fig. 1A). Four patients with normal echo pattern had few echogenic foci without shadowing in the body of the pancreas and all these patients had alcohol related AP. The CT revealed Grades A, B, C and D pancreatitis in 2, 4, 4, and 2 patients, respectively.

EUS findings in patients with PN (n=20)

In patients with PN/EPN, EUS revealed loss of normal echo pattern of the pancreas along with the novel findings of either multiple hypoechoic or hyperechoic areas measuring more than 5 mm in diameter. Multiple hypoechoic areas alone were observed in 5 (25%) patients (Fig. 1B) whereas multiple hyperechoic areas were seen in 7 (35%) patients (Fig. 1C) with PN. Eight patients (40%) with PN had a mixed pattern with both hypo and hyperechoic areas being observed (Fig. 1D). None of these EUS findings were seen in patients with acute non-necrotizing pancreatitis. Also 13 (41%) of these patients had peripancreatic hypoechoic areas that correlated with the presence of EPN on CT (Fig. 1C, 2). EUS elastography was done in three of these patients with EPN and the EPN was found to be softer than the surrounding pancreas suggesting possibly fat necrosis (Fig. 2).

Other EUS findings

EUS detected CBD stones in two patients, pleural effusion in 17 patients and ascites in 15 patients. In one patient multiple mediastinal lymph nodes were found and eventual diagnosis of sarcoidosis-related hypercalcemic pancreatitis was made.

Discussion

PN is one of the important prognostic factors in patients with AP and early detection of acute necrotizing pancreatitis can help manage these patients better. PN currently cannot be diagnosed early in the course of illness and is currently best detected by contrast enhanced cross sectional imaging techniques like CT or magnetic resonance imaging done after 5-7 day from onset of symptoms [7,18]. As EUS provides high resolution images of the pancreas, it is possible that it may be able to detect pancreatic abnormalities earlier than the conventional cross sectional imaging like CT. In this study we have shown that EUS done on the day of admission in patients with acute necrotizing pancreatitis had novel findings of either multiple hypoechoic or hyperechoic areas measuring more than 5 mm in diameter and these findings were not present in any of the patients with acute interstitial pancreatitis.

Cho *et al* performed EUS on the second day of admission (EUS examination time from admission, median: 26 h, range: 2-46 h) in 90 patients with AP and of these 27 (30%) had severe AP [15]. The authors in this study described a novel EUS finding of a geographical hyperechoic area (GHA) that was defined as variably sized, geographically shaped, with focal heterogenous hyperechoic portions and hypoechoic rim as compared to

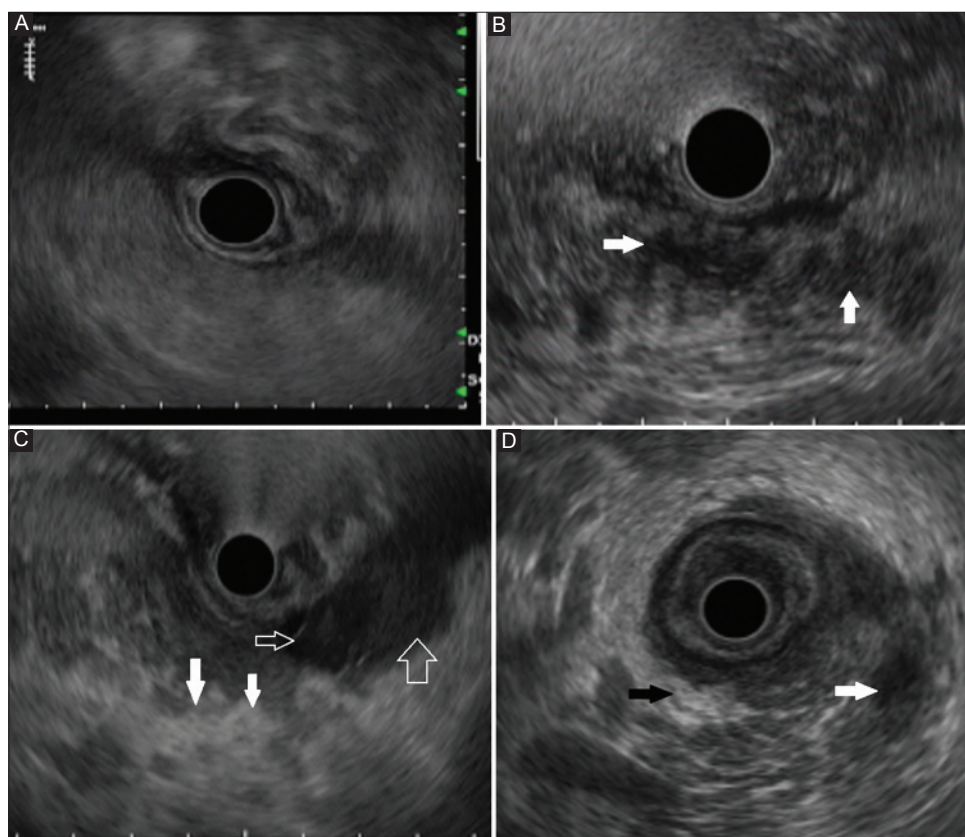


Figure 1 Endoscopic ultrasound in (A) acute interstitial pancreatitis: Diffusely increased echogenicity. (B) Necrotizing pancreatitis: Multiple hypoechoic areas (arrows). (C) Necrotizing pancreatitis: Multiple hyperechoic areas (bold arrows). Peripancreatic echogenicity suggestive of extrapancreatic necrosis also seen (open arrows). (D) Necrotizing pancreatitis: Mixed hyperechoic (black arrows) and hypoechoic areas (white arrows)

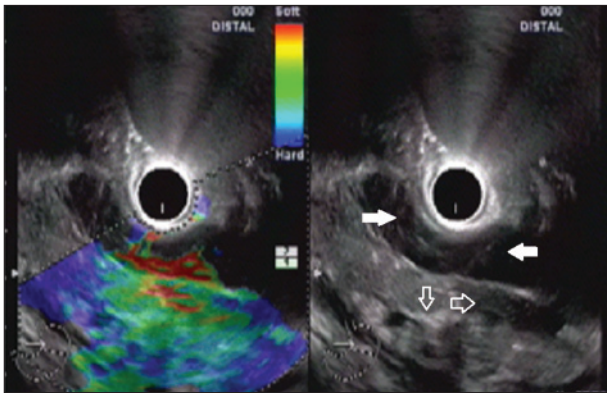


Figure 2 Endoscopic ultrasound (EUS) in necrotizing pancreatitis: mixed hyperechoic and hypoechoic areas (open arrows). Peripancreatic echogenicity, soft on EUS elastography, suggestive of EPN also seen (bold arrows)

background hypo-echogenicity. On comparing mild pancreatitis with severe pancreatitis, the authors found that the geographic hyperechoic area (GHA) of the pancreas was a predictive factor (OR 2.9, 95%CI 1.1-8.2, $P=0.04$) for the severe form, and that patients with GHA had significantly longer duration of fever, abdominal pain and hospital stay than those without GHA (5.5 vs. 1 day (s), $P=0.002$; 4 vs. 3 days, $P=0.023$; 11 vs. 8 days, $P=0.021$, respectively). The GHA described in this study is similar to the hyperechoic areas seen in our study and although the authors did not compare the EUS and CT findings, the GHA was a marker of severity of pancreatitis and in our study also hyperechoic areas were seen in acute necrotizing pancreatitis only.

Sotoudehmanesh *et al* prospectively studied 114 patients with AP (severe in 42 patients) and did EUS on the second day of admission [14]. They found that the presence of peripancreatic edema in EUS correlated with the severity of AP (sensitivity, specificity and accuracy: 65.8, 75.7 and 72.2%, respectively). In our study, the presence of peripancreatic hypoechoic areas correlated with presence of EPN on CT and these areas were found to be soft on elastography possibly suggesting fat necrosis. However, as only 3 patients underwent EUS elastography, these findings need to be confirmed in a study with large sample size. Sugiyama *et al* studied 23 patients with AP (necrotizing pancreatitis in 7 patients) with EUS and found that all seven patients with necrotizing pancreatitis showed a poorly defined focal hypoechoic area with or without interspersed echogenic spots and similar multiple hypoechoic areas alone were observed in 7 (35%) of our patients with PN [19]. They also found that EUS could differentiate edematous and necrotizing pancreatitis as well as CT could and our results have been similar also. Along with this, the added advantage of EUS is its ability to detect various etiological factors of AP such as CBD stones and pancreatic structural abnormalities such as pancreas divisum. In our study, EUS was able to detect CBD stones in two patients and multiple mediastinal lymph nodes in one patient and these findings were not detected on previous imaging modalities.

Although EUS is a minimally invasive imaging modality, time consuming and can be uncomfortable to the patient, however the advantage of detecting PN early in the course of the disease

Summary Box

What is already known:

- Pancreatic necrosis (PN) may develop in up to 15% of patients with acute pancreatitis and is associated with increased morbidity and mortality
- PN is currently detected by the loss of vascular enhancement on computed tomography or magnetic resonance imaging
- However, on cross sectional imaging the signs of PN evolve over several days

What the new findings are:

- Patients with acute necrotizing pancreatitis have multiple parenchymal hypoechoic or hyperechoic areas on endoscopic ultrasound (EUS)
- EUS done at admission can reliably detect pancreatic necrosis earlier than other cross sectional imaging modalities

seems promising and outweighs some of these disadvantages. The possible limitations of EUS could be the patients who have contraindications for EUS such as patients with hemodynamic or severe respiratory compromise as were 6 of our patients. Our study is a small sample size pilot study and further studies with large sample sizes are needed to confirm our results.

In conclusion, patients with acute necrotizing pancreatitis have multiple hypoechoic or hyperechoic areas in the pancreas on EUS done at admission and these findings predict PN reliably. Also, EUS can detect co-existent disorders such as CBD stones. However, further studies with large sample sizes are needed to confirm our initial results as well as to determine whether or not this will ultimately improve patients' outcome.

References

1. Forsmark CE, Baillie J. AGA Institute technical review on acute pancreatitis. *Gastroenterology* 2007;**132**:2022-2044.
2. Cappell MS. Acute pancreatitis: etiology, clinical presentation, diagnosis and therapy. *Med Clin N Am* 2008;**92**:889-923.
3. Nadkarni N, Bhasin DK, Rana SS, et al. Diastolic dysfunction, prolonged QTc interval and pericardial effusion as predictors of mortality in acute pancreatitis. *J Gastroenterol Hepatol* 2012;**27**:1576-1580.
4. Babu RY, Gupta R, Kang M, Bhasin DK, Rana SS, Singh R. Predictors of surgery in patients with severe acute pancreatitis managed by the step-up approach. *Ann Surg* 2013;**257**:737-750.
5. Derveniz C, Johnson CD, Bassi C, et al. Diagnosis, objective assessment of severity, and management of acute pancreatitis. *Int J Pancreatol* 1999;**25**:195-210.
6. Muddana V, Whitcomb DC, Khalid A, Slivka A, Papachristou GI. Elevated serum creatinine as a marker of pancreatic necrosis in

- acute pancreatitis. *Am J Gastroenterol* 2009;**104**:164-170.
7. Balthazar EJ. Acute pancreatitis: assessment of severity with clinical and CT evaluation. *Radiology* 2002;**223**:603-613.
 8. Rana SS, Bhasin DK, Rao C, Singh K. Role of endoscopic ultrasound in idiopathic acute pancreatitis with negative ultrasound, computed tomography, and magnetic resonance cholangiopancreatography. *Ann Gastroenterol* 2013;**26**:66-70.
 9. Rizk MK, Gerke H. Utility of endoscopic ultrasound in pancreatitis: a review. *World J Gastroenterol* 2007;**13**:6321-6326.
 10. Amin S, Dimaio CJ, Kim MK. Advanced EUS imaging for early detection of pancreatic cancer. *Gastrointest Endosc Clin N Am* 2013;**23**:607-623.
 11. Sugiyama M, Wada N, Atomi Y, Kuroda A, Muto T. Diagnosis of acute pancreatitis: value of endoscopic sonography. *AJR Am J Roentgenol* 1995;**165**:867-872.
 12. Schoefer M, Rathgeber A, Lang J, Nagell W, Dancygier H. Prognostic value of endoscopic ultrasound in acute pancreatitis (Abstr). *Gastroenterology* 1998;**114** (Suppl 1):A495.
 13. Kotwal V, Talukdar R, Levy M, Vege SS. Role of endoscopic ultrasound during hospitalization for acute pancreatitis. *World J Gastroenterol* 2010;**16**:4888-4891.
 14. Sotoudehmanesh R, Hooshyar A, Kolahdoozan S, Zeinali F, Shahraeni S, Keshtkar AA. Prognostic value of endoscopic ultrasound in acute pancreatitis. *Pancreatol* 2010;**10**:702-706.
 15. Cho JH, Jeon TJ, Choi JS, et al. EUS finding of geographic hyperechoic area is an early predictor for severe acute pancreatitis. *Pancreatol* 2012;**12**:495-501.
 16. Bradley EL III. A clinically based classification system for acute pancreatitis. *Arch Surg* 1993;**128**:586-590.
 17. Bakker OJ, van Santvoort H, Besselink MG, et al; Dutch Pancreatitis Study Group. Extrapancreatic necrosis without pancreatic parenchymal necrosis: a separate entity in necrotising pancreatitis? *Gut* 2013;**62**:1475-1480.
 18. Banks PA, Bollen TL, Dervenis C, et al. Acute pancreatitis classification working group. Classification of acute pancreatitis--2012: revision of the Atlanta classification and definitions by international consensus. *Gut* 2013;**62**:102-111.
 19. Sugiyama M, Wada N, Atomi Y, Kuroda A, Muto T. Diagnosis of acute pancreatitis: value of endoscopic sonography. *AJR Am J Roentgenol* 1995;**165**:867-872.