



## Case Report

# Urothelial carcinoma associated with infective endocarditis due to a *Leuconostoc* Species: A rare case report

S. Abouradi<sup>\*</sup>, S. Ejjebli, K. Chawki, A. Drighil

Cardiology, Ibn Rochd University Hospital Center, Casablanca, Morocco

## ARTICLE INFO

## Keywords:

Case report  
Endocarditis  
Urothelial carcinoma  
Leuconostoc  
Infectious disease

## ABSTRACT

**Introduction:** and importance: *Leuconostoc* is a genus of gram-positive bacteria, this type of bacteria, which can be found in green vegetables and are used in wine, cheese, and sugar production, is an uncommon cause of disease in human beings

**Case report:** We report the case of a 60 years old male, with a medical history of nasopharyngeal carcinoma treated by chemotherapy and radiotherapy. The patient was admitted for total hematuria and episodic fever for the last 2 months. blood test found an anemia at 5g/dl, hyperleukocytosis at 18,000/ml, The transthoracic echocardiography showed, moderate mitral regurgitation, severe mitral stenosis with a valve area of 1.5cm<sup>2</sup>, and a mobile vegetation measuring 14 × 6 mm on A2 part of the anterior mitral valve. Transesophageal echocardiography (TEE) showed a 16 × 8 mm mitral vegetation. An empirical antibiotic therapy then adapted to the antibiogram

**Clinical discussion:** our patient is at an extremely elevated risk for infective endocarditis. This case is interesting because the pathogenic bacterial species for IE are typically staphylococci and streptococci, Two similar cases of *Leuconostoc* spp endocarditis were found in the literature, effective therapy of penicillin-resistant group viridians streptococci with combination therapy, our team opted for empiric treatment with ceftriaxone associated to gentamycin

**Conclusion:** It is critical for clinicians to be aware of the many pathogenic organisms, including *Leuconostoc* species. It is also clear that a higher index of suspicion must be maintained in patients with multiple predisposing factors such as the patient in the case presented.

## 1. Introduction

Infective endocarditis (IE) is commonly caused by the hematogenous spread of various microorganisms that target the endocardium with staphylococci and streptococci accounting for the majority of cases. Due to the multitude of bacterial and even fungal pathogens, treatment options should be targeted specifically against microorganisms that are isolated in blood cultures. If an empiric antibiotic therapy is warranted, first-line treatment usually targets methicillin susceptible and resistant staphylococci, streptococci, and enterococci. Although there is an important caveat, clinicians must consider when using vancomycin antibiotic therapy.

*Leuconostoc* is a genus of gram-positive bacteria, placed within the family of Lacto-bacillaceae, this type of bacteria, which can be found in green vegetables and are used in wine, cheese, and sugar production, is an uncommon cause of disease in human beings (1); these

microorganisms have only recently been recognized as a potential cause of infection in a variety of patient populations (2).

When dealing with IE caused by *Leuconostoc*, vancomycin is not a suitable option for treatment. *Leuconostoc* is catalase-negative, produces lactic acid, and is characterized by its intrinsic and chromosomal resistance to vancomycin [1–3]. It was previously believed that this bacterial species was non-pathogenic in nature until recently published reports revealed the infectious potential of the *Leuconostoc* species in many patient populations [4,5].

## 2. Case report

We report the case of a 60 years old north African male who visited the emergency department accompanied by his family, with a medical history of nasopharyngeal carcinoma 26 years ago treated by chemotherapy and radiotherapy complicated with hypothyroidism under

<sup>\*</sup> Corresponding author.

E-mail address: [saraabouradi17@gmail.com](mailto:saraabouradi17@gmail.com) (S. Abouradi).

levothyroxine, our patient was diagnosed with a right renal urothelial carcinoma (UC) 2 years ago that was treated with surgery, an end stage kidney failure undergoing dialysis twice a week using a tunneled central venous catheter that was placed 3 years ago and a deafness caused by an operated cholesteatoma. There was no medical history of familial neoplasia or drug allergies.

The patient was admitted in the cardiology department for significant weight loss associated to nausea, vomiting, dyspnea, total hematuria and episodic fever (39 °C) for the last 2 months. The medical examination revealed a conscious patient with a blood pressure of 100/64 mmHg, heart rate of 113 bpm, temperature of 38.5 C, respiratory rate of 18 cpm, and oxygen saturation of 97% on room air. The cardiovascular examination found a grade IV/VI systolic and diastolic murmurs, no Janeway lesions or Osler nodes were found.

In the context of the pandemic, the first suspected diagnosis was a sars-cov 2 pulmonary infection, ruled out by a negative Covid PCR, a chest X-ray was also performed showing a bilateral pleural effusion.

Complete blood count found an anemia with a hemoglobin rate at 5g/dl, white blood cell count (WBC) at 18,000/ml, C-reactive protein (CRP) elevated at 104 mg/dl, Procalcitonin at 1, erythrocyte sedimentation rate (ESR) was 48 mm, creatinine (Cr) 40.6 mg/dl, with a GFR of 15 ml/min/m<sup>2</sup>; a positive rheumatoid factor, hypothyroidism with a pituitary thyroid stimulating hormone at 100mUI/l.

The EKG showed an incomplete left bundle branch block with no anginal symptoms, transthoracic echocardiography (TTE) showed a mitral valve with calcified leaflets, moderate mitral regurgitation (Fig. 1), severe mitral stenosis with a valve area of 1.5cm<sup>2</sup>, and a mobile vegetation measuring 13 × 6 mm on A2 part of the anterior mitral valve (Figs. 2 and 3). We also observed a tricuspid aortic valve with calcified leaflets and reduced cusp separation, moderate aortic regurgitation, moderate aortic stenosis with a valve area of 1.2 cm<sup>2</sup>. The left ventricular size was within normal limits and the left ventricular ejection fraction was 63%. Transesophageal echocardiography (TEE) showed a 16 × 8 mm mitral vegetation. An empirical antibiotic therapy was initiated after the collection of recipient blood samples for culturing.

Leuconostoc species grew in 2 out of 2 blood cultures. Antibiotic

treatment was adapted to the antibiogram with ceftriaxone and gentamicin. A cranial and Thoracoabdominal pelvic scan were realized and revealed an occipital ischemic injury, bilateral mild pleural effusion, metastatic damage to the liver, bladder tumor occupying all the lumen measuring 59 × 56 × 49mm and a mild peritoneal effusion.

Considering the results of imaging studies, clinical findings and blood tests, a diagnosis of infective endocarditis due to *Leuconostoc* spp was established. The patient received intravenous antibiotic therapy consisting of ceftriaxone 2g and gentamycin adapted to renal function.

The Nephrology team was consulted to assist in the management of the patient's chronic kidney disease. Throughout the patient's hospitalization, his tunneled central venous catheter was removed and the patient received a transfusion of 4 blood bags per-dialysis because of his severe anemia with a control of hemoglobin at 9.5g/dl. During his hospitalization, the patient had a transurethral endoscopic bladder resection of his mass that revealed a secondary extension of his primary renal cancer. Other departments took part in the management of our patient, endocrinology with the adaptation of doses of L-thyroxin and Oncology team who pronounced that his cancer is in a late stage and decided for a palliative chemotherapy after treatment of his actual endocarditis.

After the patient's discharge, the medical follow-up was done in the cardiology department for 2 months with weekly clinical checkups and echocardiography controls that showed a regression in the size of the vegetation.

The patient died by an hemorrhagic shock caused by a severe hematuria related to his urothelial carcinoma before starting his chemotherapy.

### 3. Discussion

This case reports a story of a cancer patient afflicted by a complicated course of infective endocarditis with an uncommon organism: *Leuconostoc* spp. What had initially been described as a nagging headache, quickly developed into what we now know to be *Leuconostoc* species bacteremia from seeded aortic valves. In evaluating what may have led

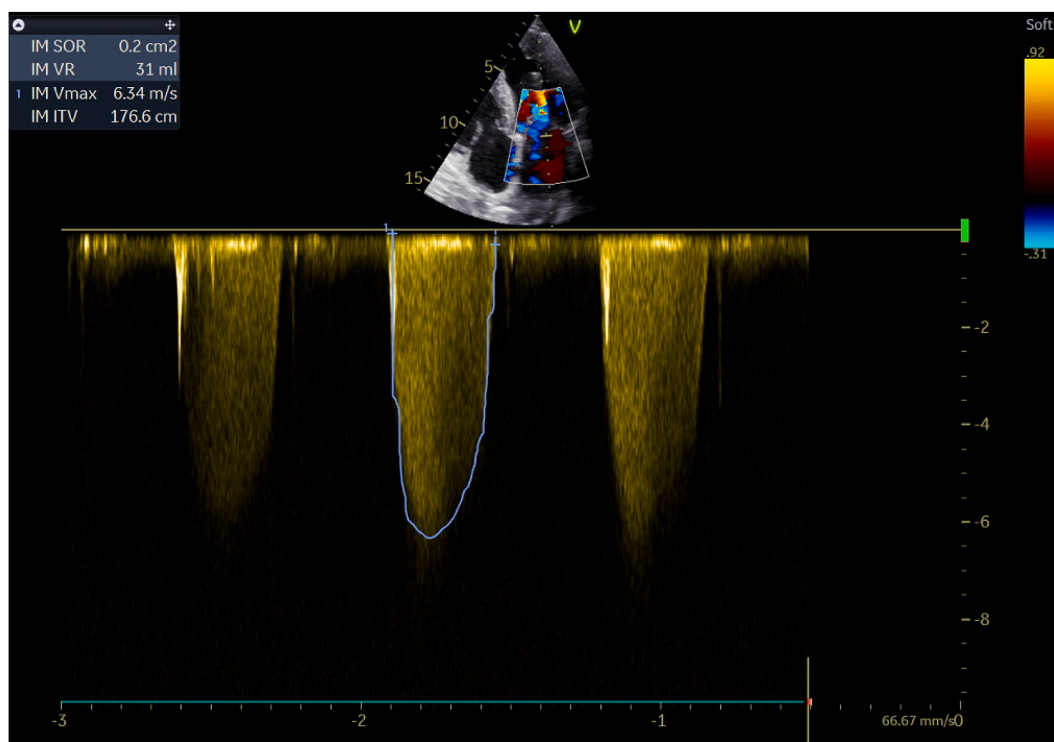


Fig. 1. Echocardiography: continuous Doppler on the mitral valve showing a Moderate mitral regurgitation.

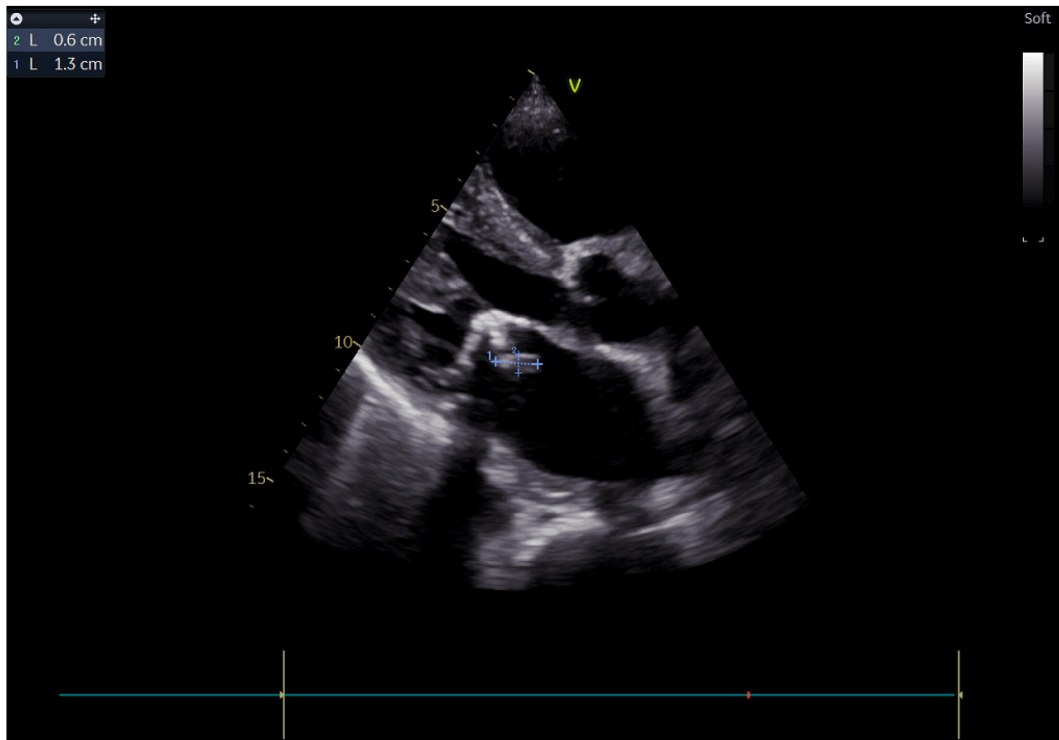


Fig. 2. Parasternal long axis view showing the mitral vegetation measuring 6 × 13mm.

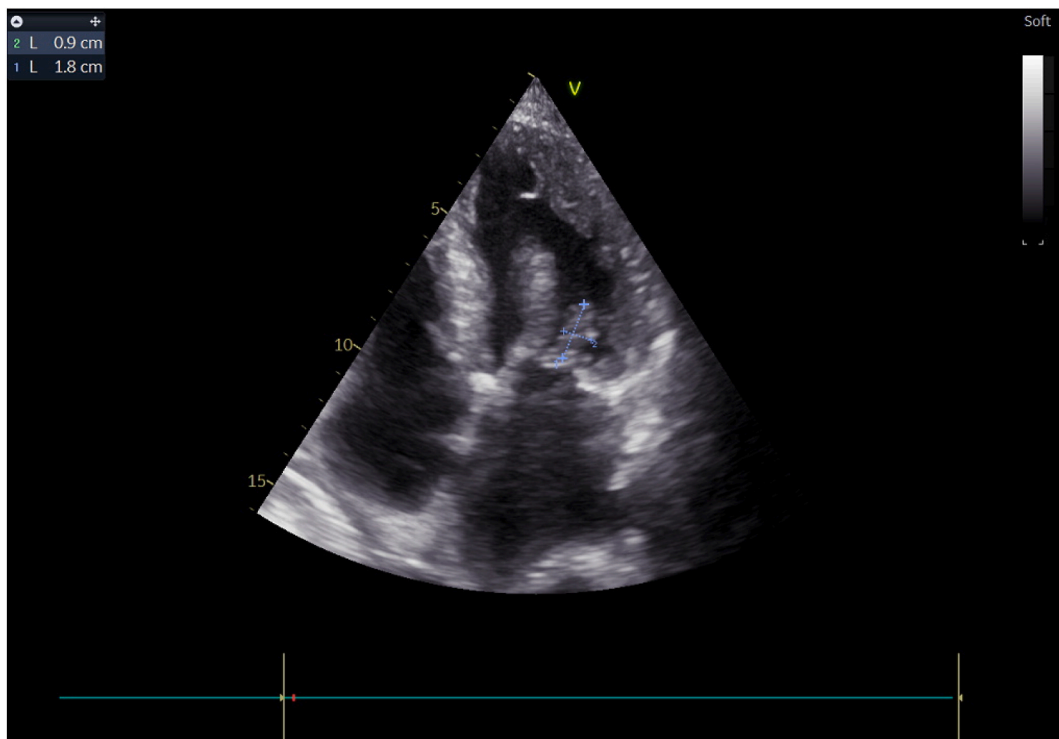


Fig. 3. Four cavities view with transthoracic echocardiography showing the mitral vegetation.

to this patient's eventual clinical course, it is imperative to note all predisposing factors. Our patient had a history of nasopharyngeal cancer, a renal carcinoma and a chronic renal failure undergoing dialysis with a persistent central venous catheter that was never changed and kept over 3 years, all of those factors had placed our patient at an extremely elevated risk for infective endocarditis. This case is interesting

because the pathogenic bacterial species for IE are typically staphylococci and streptococci, not *Leuconostoc* species [6].

Until 1985, *Leuconostocs* were known as “nonpathogenic to plants and animals”. However, due to continued reports of different infections, they are currently recognized as opportunistic pathogens affecting patients with a wide spectrum of underlying diseases; Still the portal of

entry remains uncertain. One possibility is their introduction into the blood stream during catheter implantation, which could explain the case of our patient, another portal of entry is the gastrointestinal tract due to the natural habitat of *Leuconostoc* in food, which would explain the association with underlying gastrointestinal disease and frequent gastrointestinal symptoms [7].

*Leuconostoc* is a genus of Gram-positive, catalase and oxidase negative, chain forming ovoid cocci placed within the family of leuconostocaceae [6,4,8]. This bacterial species was thought to be non-pathologic until recently published reports have revealed their infectious potential in immune compromised and severely ill patients. Two similar cases of *Leuconostoc* spp endocarditis were found in the literature, the first one regarding a drug user and the second one with no previous pathological history [1,9]. IE with *Leuconostoc* species can be troubling considering they are hetero-fermentative and potentially “slime” (dextran and sucrose producing) forming [10,11].

High-level resistance to vancomycin is nearly a constant in *Leuconostoc* species. Reports suggest the involvement of a chromosomal factor, which leads to a change in the end of a pentapeptide in the cell wall. This vancomycin binding side usually ends in alanine-alanine, but in *Leuconostoc* species it ends in alanine-lactate. Another possibility, as in *Enterococci*, is the production of a new membrane protein codified by plasmids [12]. Concerning treatment, multiple studies showed that the complete elimination of most bacterial pathogens of endocarditis needs two to four weeks of monotherapy, so we opted to treat our patient for six weeks following the American Heart Association (AHA) guidelines for treatment of penicillin-resistant bacteria in a high-risk patient [13, 9]. Additionally, the AHA advises that daptomycin alone is not effective against multidrug resistant IE and should be used in combination with other agents [13]. Upon further review of the available literature on *Leuconostoc* species infection, several studies listed daptomycin as an effective treatment for *Leuconostoc*-associated bacteremia [14]. Considering our patient had an uncommon bacteria and an aortic valve vegetation, we pursued a full six-week course of an intravenous antibiotic therapy. As published reports do show effective therapy of penicillin-resistant group viridians streptococci with combination therapy, typically ceftriaxone or penicillin with gentamycin [15,9], our team opted for empiric treatment with ceftriaxone associated to gentamycin.

#### 4. Conclusion

Infective endocarditis can prove to be a threatening disease when left untreated also if caused by a new organism. It is critical for clinicians to be aware of the many pathogenic organisms, including *Leuconostoc* species, and appropriate management strategies in order to avoid different complications that may ensue. It is also clear that a higher index of suspicion must be maintained in patients with multiple predisposing factors such as the patient in the case presented.

#### Ethical approval

The study is exempt from ethical approval in my institution.

#### Sources of funding

No sources or sponsors.

#### Author contributions

S. ABOURADI: care of the patient  
S. EJJEBLI: study concept literature  
K. CHAWKI: writing paper  
A. DRIGHIL: Interpretation and analysis.

#### Trial registry number

1. Name of the registry: Research Registry
2. Unique identifying number or registration ID: researchregistry7636
3. Hyperlink to your specific registration (must be publicly accessible and will be checked): <https://www.researchregistry.com/browse-the-registry/#home/registrationdetails/62081a6c64416d001e7b905f/>

#### Consent

Name: anonymous patient

Title of article: Urothelial carcinoma associated with infective endocarditis due to a *Leuconostoc* Species: A rare case report

Medical practitioner or corresponding author: Sara ABOURADI

I give my consent for this information about MYSELF, relating to the subject matter above to appear in the journal Annals of Medicine and Surgery.

I understand the following:

1. The Information will be published without my name attached and every attempt will be made to ensure anonymity. I understand, however, that complete anonymity cannot be guaranteed. It is possible that somebody somewhere - perhaps, for example, somebody who looked after me, if I was in hospital, or a relative - may identify me.
2. The Information may be published in a journal which is read worldwide or an online journal. Journals are aimed mainly at health care professionals but may be seen by many non-doctors, including journalists.
3. The Information may be placed on a website.
4. I can withdraw my consent at any time before online publication, but once the Information has been committed to publication it will not be possible to withdraw the consent Date: May 15, 2021.

#### Guarantor

ABOURADI Sara.

#### Declaration of competing interest

No conflicts of interest to declare.

#### References

- [1] J.A. Starr, *Leuconostoc* species-associated endocarditis, *Pharmacotherapy* 27 (2007) 766–770.
- [2] A.P. Kuzin, T. Sun, J. Jorczak-Baillaz, V. Healy, C.T. Walsh, J.R. Knox, Enzymes of vancomycin resistance: the structure of Dalanine D-lactate ligase of naturally resistant *Leuconostoc mesenteroides*, *Structure* 8 (5) (2000) 463–470, doi.org/bkbb3w.
- [3] J.D. Martínez-Pajares, O. Díaz-Morales, F. Acosta-Conzález, J.C. Ramos-Díaz, Sepsis por *Leuconostoc* spp. en un lactantesano, *Arch. Argent. Pediatr.* 110 (2) (2012) e32–e34, doi.org/d3h5.
- [4] P.E. García-Granja, J. López, R. Ladrón, J.A. San Román, Infective endocarditis due to *Leuconostoc* species, *Rev. Esp. Cardiol.* S1885–5857 (2017) 30217.
- [5] *Leuconostoc* species endocarditis in an intravenous drug use, May 2018; *Journal of Cardiology Cases* 18(1); DOI:10.1016/j.jccase.2018.04.002.
- [6] L. Jofré, A. Sakurada, M.T. Ulloa, J.C. Hormázabal, V. Godoy, J. Fernández, et al., Infección por *Leuconostoc* en pacientes con síndrome de intestino corto, nutrición parenteral y alimentación enteral continua, *Rev Chil Infecta* 23 (4) (2006) 340–345, doi.org/ct25zz.
- [7] M.A. Ballesteros Sanz, C. Ruiz De Alegría-Puig, C. Fernandez-Mazarra, M. Gutierrez Cuadra, Bacteremia and sepsis due to *Leuconostoc mesenteroides*, *Med. Clin.* 134 (2010) 87–92.
- [8] R. Facklam, J. Elliott, Identification, classification, and clinical relevance of catalase-negative, Gram-positive cocci, excluding the *Streptococci* and *Enterococci*, *Clin. Microbiol. Rev.* 8 (1995) 479–495.
- [9] [15a] D. Valencia, V. Valencia, A. Fershko, *Leuconostoc* species endocarditis in an intravenous drug user, *Journal of Cardiology Cases* 18 (1) (2018) 37–41, <https://doi.org/10.1016/j.jccase.2018.04.002>;
- [15b] R.A. Agha, T. Franchi, C. Sohrabi, G. Mathew, A. Kerwan, A. Thoma, B. Vasudevan, The SCARE 2020 guideline: updating consensus surgical CASE

- REport (SCARE) guidelines, *Int. J. Surg.* (2020), <https://doi.org/10.1016/j.ijsu.2020.10.034>.
- [10] S. Handwerger, H. Horowitz, K. Coburn, A. Kolokathis, G.P. Wormser, Infection due to *Leuconostoc* species: six cases and review, *Rev. Infect. Dis.* 12 (1990) 602–610.
- [11] T. Sampelayo, S. Moreno, E. Bouza, *Leuconostoc* species as a cause of bacteremia: two case reports and a literature review, *Eur. J. Clin. Microbiol. Infect. Dis.* 10 (1991) 505–509.
- [12] H.W. Horowitz, S. Handwerger, K.G. van Horn, G.P. Wormser, *Leuconostoc*, an emerging vancomycin-resistant pathogen, *Lancet* 2 (1987) 1329–1330.
- [13] L. Baddour, W. Wilson, A. Bayer, V. Fowler, I. Tleyjeh, M. Rybak, et al., Infective endocarditis in adults: diagnosis, antimicrobial therapy, and management of complications: a scientific statement for healthcare professionals from the American Heart Association, *Circulation* 134 (2016) 1435–1486.
- [14] Y. Huang, C. Liao, L. Teng, P. Hsueh, Daptomycin susceptibility of unusual Grampositive bacteria: comparison of results obtained by the Etest and the broth microdilution method, *Antimicrob. Agents Chemother.* 51 (2007) 1570–1572.
- [15] J. Swenson, R. Facklam, C. Thornsberry, Antimicrobial susceptibility of vancomycin-resistant *Leuconostoc*, *pediococcus*, and *lactobacillus* species, *Antimicrob. Agents Chemother.* 34 (1990) 543–549.