



A Case of Vanishing Bile Duct Syndrome after Drug-Induced Liver Injury Caused by Pelubiprofen

Haein Bak^{1*}, Hayeon Kim^{2*}, Sieun Lee¹, Yoonseok Lee¹, Soo-Min Bang¹, and Young-Sun Lee¹

¹Department of Internal Medicine, Korea University College of Medicine, Seoul;

²Department of Pathology, Korea University Guro Hospital, Korea University College of Medicine, Seoul, Korea.

Vanishing bile duct syndrome (VBDS) is a rare disease characterized by ductopenia and cholestasis, and is linked to immunological damage to the bile duct system. VBDS can be triggered by infection, ischemia, autoimmune diseases, adverse drug reactions, and humoral factors associated with malignancy. A few cases of VBDS associated with nonsteroidal anti-inflammatory drug-related drug-induced liver injury (DILI) have been reported. Here, we report a case of a 29-year-old patient who developed DILI that progressed to VBDS after the administration of pelubiprofen.

Key Words: Pelubiprofen, vanishing bile duct syndrome, bile duct disease, drug-induced liver injury

INTRODUCTION

Drug-induced liver injury (DILI) is a major cause of acute liver injury, and it may also be a cause of acute liver failure.¹⁻³ Nonsteroidal anti-inflammatory drugs (NSAIDs) can cause liver injury, from mild elevation of aminotransferase levels to acute liver failure and death.⁴ Despite the low incidence of NSAID-induced liver injury, numerous patients are affected by DILI due to the widespread use of NSAIDs.⁵

Vanishing bile duct syndrome (VBDS) is a serious cholestatic disease associated with infectious etiologies, autoimmune diseases, adverse drug reactions, and malignancy-related humoral factors.⁶ VBDS can occur in DILI patients with progressive cholestasis, potentially leading to liver failure and death.⁷

Received: August 13, 2020 **Revised:** September 28, 2020

Accepted: October 6, 2020

Corresponding author: Young-Sun Lee, MD, PhD, Department of Internal Medicine, Division of Gastroenterology and Hepatology, Guro Hospital, Korea University College of Medicine, 48 Gurodong-ro, Guro-gu, Seoul 08308, Korea.
Tel: 82-2-2626-1030, Fax: 82-2-2626-1038, E-mail: lys810@korea.ac.kr

*Haein Bak and Hayeon Kim contributed equally to this work.
•The authors have no potential conflicts of interest to disclose.

© Copyright: Yonsei University College of Medicine 2020

This is an Open Access article distributed under the terms of the Creative Commons Attribution Non-Commercial License (<https://creativecommons.org/licenses/by-nc/4.0>) which permits unrestricted non-commercial use, distribution, and reproduction in any medium, provided the original work is properly cited.

Here we report a case of VBDS caused by pelubiprofen in an adult, requiring liver transplantation. To our knowledge, no case of VBDS related to pelubiprofen has been reported so far.

CASE REPORT

A 29-year-old woman visited a local hospital with a 1-day history of mild fever, runny nose, sputum, and muscle pain. She received fluid therapy and an NSAID (pelubiprofen) for 2 days (90–180 mg). Subsequently, she experienced more than 10 episodes of vomiting and nausea, and was admitted to the emergency department. She had no history of other drugs or herbal medication, and was a social drinker.

Although the patient was febrile (38.0°C), her heart rate and blood pressure were normal. Asymptomatic erythematous maculopatches were noted on the postauricular area, neck, and trunk on day 2 of hospitalization. Conjunctivitis and oral mucositis were also observed. Her serum alanine aminotransferase (ALT), aspartate aminotransferase (AST), and total bilirubin levels had significantly increased to 1443 IU/L, 1006 IU/L, and 3.12 mg/dL (direct bilirubin dominant, 2.62 mg/dL), respectively. The prothrombin time–international normalized ratio was 1.05. Anti-hepatitis A virus immunoglobulin M, hepatitis B surface antigen, hepatitis B surface antibody, and anti-hepatitis C virus showed negative results. Antinuclear anti-

bodies, anti-smooth muscle antibody, and anti-mitochondrial antibody results were all negative. Serum ceruloplasmin level were within the normal range. Computed tomography showed arterial heterogeneous enhancement of the liver parenchyma, edematous gallbladder wall thickening, and small reactive lymph nodes at the portacaval and retrocaval spaces, suggesting secondary changes of acute hepatitis. The Roussel Uclaf Causality Assessment Method score was 6, which was probable for DILI.

High fever persisted after hospitalization, and skin and mucosal lesions were aggravated. On day 8 of hospitalization, methylprednisolone 30 mg was initiated due to suspected pelubiprofen-induced DILI and Stevens–Johnson syndrome. After steroid treatment, the fever subsided and skin lesions improved. ALT and AST levels, which had peaked at 6479 and 4254 IU/L, respectively, on day 2 of admission, rapidly decreased (Fig. 1). However, serum bilirubin levels had reached 11.81 mg/dL by day 23 of admission. Alkaline phosphatase (ALP) and gamma glutamyl transferase (GGT) were also increased to 528 and 869 IU/L, respectively. The steroid was maintained for a month. Methylprednisolone (30 mg) was initiated and tapered in half every week until it was tapered out.

Liver biopsy performed on day 23 of admission (Fig. 2A and B) revealed bile canalicular cholestasis around the perivenular area and moderate lobular inflammation. The biopsy specimen had two portal tracts. Fibrosis or fatty changes were not identified. Immunohistochemical staining for cytomegalovirus and RNA in situ hybridization for Epstein–Barr virus was negative. The absence of interface hepatitis and bile duct

injury could have excluded autoimmune hepatitis (AIH) and primary biliary cholangitis (PBC). DILI was suspected based on clinical history, laboratory results, and histologic findings.

On day 26 of admission, skin lesions improved, and AST and ALT levels decreased to 141 and 339 IU/L, respectively. The patient was discharged and followed up at the outpatient clinic. Over the next 4 months, her bilirubin level fluctuated but never decreased to <10 mg/dL (Fig. 1). ALP and GGT were also not normalized.

A second liver biopsy was performed on day 124, and revealed chronic cholestatic hepatitis with a bile canalicular pattern (Fig. 2C and D). Furthermore, >50% of the 23 portal areas in the specimen lacked bile ducts accompanying hepatic arterioles. Immunostaining for CK19 confirmed bile duct loss and bile ductular proliferation. Periportal fibrosis was also noted. During the follow-up period, the patient complained of continuous pruritus. Based on the histopathological features, clinical history, and laboratory findings, our diagnosis of the patient was VBDS. Currently, after more than 14 months, she is awaiting liver transplantation.

This case has been approved by Korea University Guro Hospital Institutional Review Board (IRB No. 2020GR0257).

DISCUSSION

VBDS or ductopenia refers to a progressive destruction and disappearance of the intrahepatic bile ducts, leading to cholestasis.^{8,9} Various disease conditions can cause VBDS, includ-

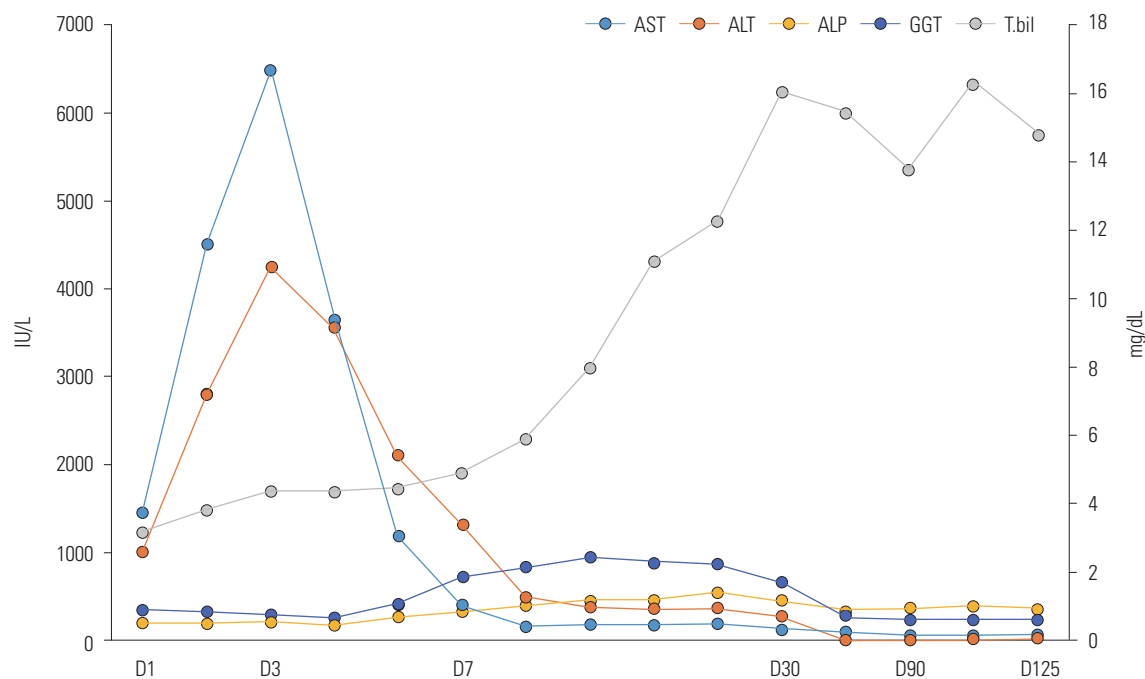


Fig. 1. Changes in AST, ALT, ALP, GGT (IU/L), and bilirubin (mg/dL) levels for 124 days. Steroids were first administered on day 8 of admission. The first liver biopsy was performed on day 23, and a second liver biopsy was performed on day 124. AST, aspartate aminotransferase; ALT, alanine aminotransferase; ALP, alkaline phosphatase; GGT, gamma glutamyl transferase.

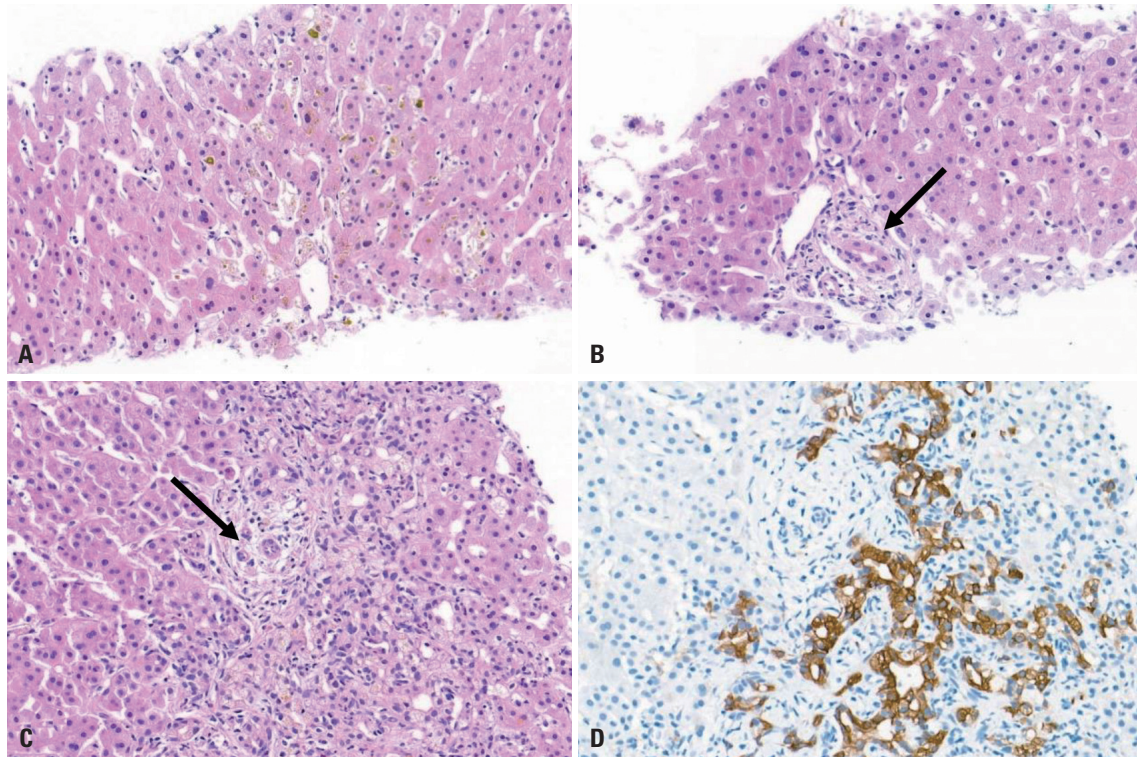


Fig. 2. Representative microscopic photographs of the two liver biopsies. (A) In the first biopsy, perivenular cholestasis with a bile canalicular pattern was identified. (B) The two portal tracts included in the biopsy specimen showed intact bile duct epithelial cells (arrow). (C) The second biopsy demonstrated cores of hepatic parenchyma with periportal fibrosis. In >50% of the 23 portal tracts, hepatic arterioles were unaccompanied by bile ducts (arrow). (D) CK19 immunostaining revealed bile duct loss and bile ductular proliferation around the portal tracts. (A, B, and C) Hematoxylin and eosin staining, $\times 200$. (D) Immunohistochemical staining for CK19, $\times 200$.

ing drug- or toxin-induced biliary injury.¹⁰ Although DILI rarely causes chronic liver disease,¹¹ our patient ingested pelubiprofen, which caused DILI with cutaneous reaction and progressed to VBDS. The hepatic and cutaneous lesions could be a hypersensitivity reaction affecting cholangiocytes and keratinocytes due to the shared immunogenic proteins and cell-surface presentation of drug-protein adducts or immunogenic drug metabolites.¹²

The incidence of NSAID-induced DILI is 0.29–9 cases/100000 patient-years, and 99% of reported cases have been caused by diclofenac, ibuprofen, sulindac, acetylsalicylic acid, naproxen, piroxicam, and nimesulide.^{13,14} The exact mechanism remains unclear, but most cases of DILI due to NSAIDs exhibit an idiosyncratic pattern that may be accompanied by an immunologic reaction.¹⁴ As there are no specific symptoms or diagnostic markers, it is difficult to identify NSAIDs as the cause of DILI; hence, it is important to make a differential diagnosis from AIH or PBC. Pelubiprofen, an NSAID used worldwide, is similar to ibuprofen but has relatively selective effects on COX-2 activity (COX-1/COX-2 ratio: 3.7). Therefore, it could have less potential for use in gastrointestinal ulcers than other NSAIDs, and is preferred for patients who require long-term use of NSAID. Three cases of ibuprofen-related VBDS have been reported in pediatrics.¹⁵ Skin involvement was presented in these cases, but the prognosis varied. Two cases showed clinical

improvement with ursodeoxycholic acid (UDCA) treatment, while in the other case, liver transplantation was needed to handle persistent jaundice lasting more than 4 months, as in our case.

Transaminase, ALP, and bilirubin levels are transiently elevated in most cases of drug-induced cholestasis. In our case, AST and ALT levels peaked on day 2 of admission and rapidly normalized thereafter. However, the total bilirubin level was progressively elevated and persistently high for 4 months, leading toward ductopenia and VBDS confirmed by repetitive liver biopsy.¹⁶ The general diagnostic criteria for VBDS are 1) persistent ALP elevation for more than 6 months after DILI, 2) exclusion of PBC, sclerosing cholangitis, and graft-versus-host disease, and 3) paucity of intralobular bile ducts in liver biopsy at least 1 month after onset of disease.¹⁷ Our patient met these three criteria.

Treatments for VBDS are yet to be established. UDCA is the most frequently attempted therapy. Plasma exchange and glucocorticoids have also been attempted.¹⁸ Although some patients showed clinical improvement, others progressed to severe cholestasis, liver cirrhosis, or hepatic failure, which required liver transplantation.¹⁹ Although corticosteroid use is controversial, corticosteroid was administered for 28 days, starting with a dose of methylprednisolone 30 mg which was tapered in half every week until it was tapered out since the

patient had a skin lesion suspected to be Stevens–Johnson syndrome.²⁰ Intractable severe cholestasis for over 4 months did not improve; therefore, liver transplantation was the only treatment option.

Pelubiprofen, an NSAID, is generally well-tolerated. However, clinicians must be aware of a rare adverse effect of pelubiprofen—serious acute liver disease leading to VBDS.

ACKNOWLEDGEMENTS

This study was supported by a National Research Foundation of Korea grant from the South Korean government (Ministry of Education, Science and Technology 2018R1A1A1A05076977 and 2019M3E5D1A01068997). This study was also supported by a grant from the Korea University Guro Hospital (Korea Research-Driven Hospital) (No. O2000961).

AUTHOR CONTRIBUTIONS

Conceptualization: Young-Sun Lee. **Data curation:** Haein Bak, Hayeon Kim, and Sieun Lee. **Formal analysis:** Haein Bak, Hayeon Kim, and Yoonseok Lee. **Funding acquisition:** Young-Sun Lee. **Investigation:** Haein Bak, Hayeon Kim, and Young-Sun Lee. **Methodology:** Hayeon Kim and Soo-Min Bang. **Project administration:** Young-Sun Lee. **Resources:** Haein Bak and Young-Sun Lee. **Software:** Young-Sun Lee. **Supervision:** Young-Sun Lee. **Validation:** Sieun Lee, Yoonseok Lee, and Soo-Min Bang. **Visualization:** Haein Bak and Hayeon Kim. **Writing—original draft:** Haein Bak and Hayeon Kim. **Writing—review & editing:** Young-Sun Lee. **Approval of final manuscript:** all authors.

ORCID iDs

Haein Bak	https://orcid.org/0000-0001-5848-822X
Hayeon Kim	https://orcid.org/0000-0002-8869-3176
Sieun Lee	https://orcid.org/0000-0002-2241-1578
Yoonseok Lee	https://orcid.org/0000-0001-5493-3592
Soo-Min Bang	https://orcid.org/0000-0003-3969-1964
Young-Sun Lee	https://orcid.org/0000-0001-6396-0859

REFERENCES

- Lee WM. Drug-induced acute liver failure. *Clin Liver Dis* 2013;17:575-86, viii.
- Kullak-Ublick GA, Andrade RJ, Merz M, End P, Benesic A, Gerbes AL, et al. Drug-induced liver injury: recent advances in diagnosis and risk assessment. *Gut* 2017;66:1154-64.
- Low EXS, Zheng Q, Chan E, Lim SG. Drug induced liver injury: East versus West—a systematic review and meta-analysis. *Clin Mol Hepatol* 2020;26:142-54.
- Sarges P, Steinberg JM, Lewis JH. Drug-induced liver injury: highlights from a review of the 2015 literature. *Drug Saf* 2016;39:801-21.
- Sriuttha P, Sirichanchuen B, Permsuwan U. Hepatotoxicity of nonsteroidal anti-inflammatory drugs: a systematic review of randomized controlled trials. *Int J Hepatol* 2018;2018:5253623.
- Bakhit M, McCarty TR, Park S, Njei B, Cho M, Karagozian R, et al. Vanishing bile duct syndrome in Hodgkin's lymphoma: a case report and literature review. *World J Gastroenterol* 2017;23:366-72.
- Zoubek ME, Lucena MI, Andrade RJ, Stephens C. Systematic review: ibuprofen-induced liver injury. *Aliment Pharmacol Ther* 2020;51:603-11.
- Nakanuma Y, Tsuneyama K, Harada K. Pathology and pathogenesis of intrahepatic bile duct loss. *J Hepatobiliary Pancreat Surg* 2001;8:303-15.
- Desmet VJ. Vanishing bile duct syndrome in drug-induced liver disease. *J Hepatol* 1997;26 Suppl 1:31-5.
- Zen Y, Hübscher SG, Nakanuma Y. Bile duct diseases. In: Burt AD, Ferrell LD, Hübscher SG, editors. *MacSween's pathology of the liver* (7th ed). Philadelphia (PA): Elsevier; 2018. p.515-93.
- Park SH, Plank LD, Suk KT, Park YE, Lee J, Choi JH, et al. Trends in the prevalence of chronic liver disease in the Korean adult population, 1998-2017. *Clin Mol Hepatol* 2020;26:209-15.
- Bonkovsky HL, Kleiner DE, Gu J, Odin JA, Russo MW, Navarro VM, et al. Clinical presentations and outcomes of bile duct loss caused by drugs and herbal and dietary supplements. *Hepatology* 2017;65:1267-77.
- Björnsson ES. Hepatotoxicity by drugs: the most common implicated agents. *Int J Mol Sci* 2016;17:224.
- Meunier L, Larrey D. Recent advances in hepatotoxicity of non steroidal anti-inflammatory drugs. *Ann Hepatol* 2018;17:187-91.
- Kim HY, Yang HK, Kim SH, Park JH. Ibuprofen associated acute vanishing bile duct syndrome and toxic epidermal necrolysis in an infant. *Yonsei Med J* 2014;55:834-7.
- Chang Y, Kim JI, Lee B, Kim SG, Jung MJ, Kim YS, et al. Clinical application of ultrasonography-guided percutaneous liver biopsy and its safety over 18 years. *Clin Mol Hepatol* 2020;26:318-27.
- Vanishing bile duct syndrome. In: *LiverTox: Clinical and research information on drug-induced liver injury* [Internet]. Bethesda (MD): National Institute of Diabetes and Digestive and Kidney Diseases; 2012 [accessed on 2020 September 10]. Available at: <https://www.ncbi.nlm.nih.gov/books/NBK548715/>.
- Li L, Zheng S, Chen Y. Stevens-Johnson syndrome and acute vanishing bile duct syndrome after the use of amoxicillin and naproxen in a child. *J Int Med Res* 2019;47:4537-43.
- Pusl T, Beuers U. Ursodeoxycholic acid treatment of vanishing bile duct syndromes. *World J Gastroenterol* 2006;12:3487-95.
- Weber S, Benesic A, Rotter I, Gerbes AL. Early ALT response to corticosteroid treatment distinguishes idiosyncratic drug-induced liver injury from autoimmune hepatitis. *Liver Int* 2019;39:1906-17.