

# Midline nasal dermoid cyst with Tessier's 0 cleft

**Yadavalli Guruprasad,  
Dinesh Singh Chauhan**

*Department of Oral and Maxillofacial Surgery, Academy of Medical Education's Dental College Hospital and Research Centre, Raichur, Karnataka, India*

**Address for correspondence:**

*Dr. Yadavalli Guruprasad, Department of Oral and Maxillofacial Surgery, Academy of Medical Education's Dental College Hospital and Research Centre, Raichur-584 103, Karnataka, India.  
E-mail: guru\_omfs@yahoo.com*

## Abstract

This is a rare anomaly of midline nasal dermoid cyst (NDC) along with Tessier's 0 cleft. Midline NDCs present most commonly result from aberrant embryological development, and most commonly give rise to bifid nasal deformity resulting in midline cleft of the nose. Craniofacial clefts are among the most disfiguring of all facial anomalies. They exist in a multitude of patterns and with varying degrees of severity. The bifid nose deformity is generally an indicator of Tessier number 0 cleft. We present a rare combination of midline NDC with a mild Tessier's 0 cleft in a 4-year-old female child who was surgically treated with wide emphasis given on its diagnosis and other treatment modalities.

**Key words:** Midline facial swelling, nasal dermoid, Tessier's 0 cleft

## INTRODUCTION

Congenital midline nasal masses are rare developmental anomalies estimated to occur in one out of every 20,000-40,000 births.<sup>[1]</sup> A nasal dermoid cyst (NDC) typically presents as a midline mass located anywhere from the glabella to columella. The majority of NDC's are diagnosed in infancy and early childhood, but in some cases a lesion may not be noticed until complications occur.<sup>[1]</sup> Tessier craniofacial clefts may involve entire soft tissue and skeletal elements throughout the course of the cleft, resulting in a distorted craniofacial growth pattern and altered potential for normal growth.<sup>[2]</sup> The Tessier number 0 cleft patient may present with minimal notching in the lip, vermilion and nose, and a minimally bifid nose. The bifid

nose deformity is an indicator of Tessier's 0 cleft with various degrees of skeletal problems.<sup>[2,3]</sup> We report a rare case of Tessier's 0 cleft with presence of midline NDC within the groove of the bifid nose in a 4-year-old female child.

## CASE REPORT

A 4-year-old female child was referred to department of oral and maxillofacial surgery with a chief complaint of swelling on the nose since 1 year which had increased in size from past 2 months. There was no previous history of facial trauma, infection, or surgery and familial inheritance. Further, clinical evaluation revealed a swelling on the nasal dorsum and a well-defined groove

between two alar domes causing increase in columellar width. The anterior edge of nasal septum was thick and separated in the shape of a “Y,” contributing to a bifid appearance of nose and there was presence of a midline punctum over the swelling. CT scan axial view showed a soft tissue swelling overlying glabella and in between nasal septum with no evidence of intracranial extension. Taking all of these findings into consideration, the patient was diagnosed with midline NDC with Tessier’s 0 cleft. All the laboratory tests were in normal ranges and treatment was planned in two stages, excision of the dermoid cyst initially and rhinoplasty in the second stage.

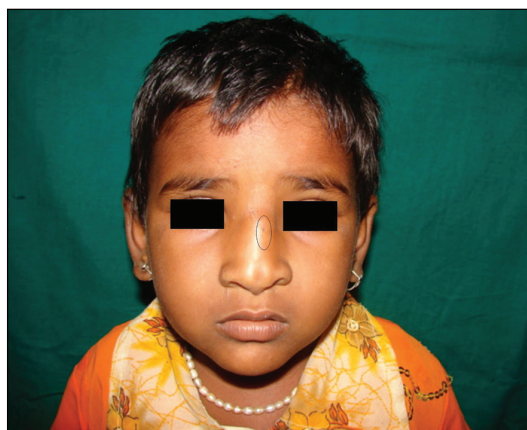Under general anesthesia, using a midline vertical incision on dorsum of the nose, cystic lining was exposed and a tract was found extending from punctum to a cystic cavity overlying the nasal bridge. The entire cystic mass was excised and layered closure was done using 3-0 polyglactin and 6-0 prolene sutures. Histopathological examination revealed that the cyst is lined by keratinizing squamous epithelium with attached pilosebaceous structures suggestive of

dermoid cyst [Figures 1-6]. The surgical wound healed uneventfully and no recurrence was found during the follow-up period. The correction of nasal deformity was planned for second stage surgery during postadolescent period.

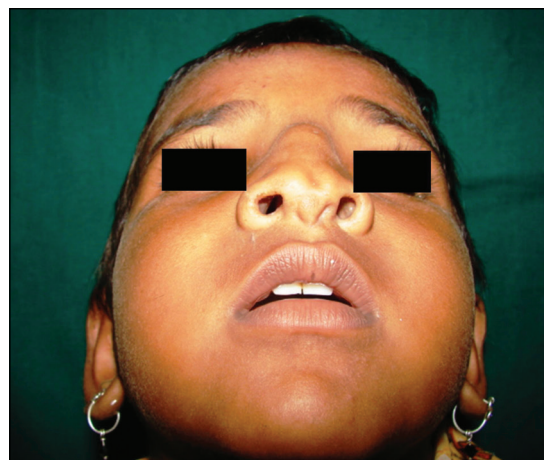## DISCUSSION

NDCs are believed to result from embryologic defects during the development of frontonasal region. They are often associated with a sinus tract, and their extent varies. In particular, they may remain confined to the surface, involve deep, local tissues, or even extend into intracranial compartment. Patients with midline nasal masses require magnetic resonance imaging (MRI) or CT imaging to assess the lesion and determine possible intracranial extension.<sup>[1,3]</sup>

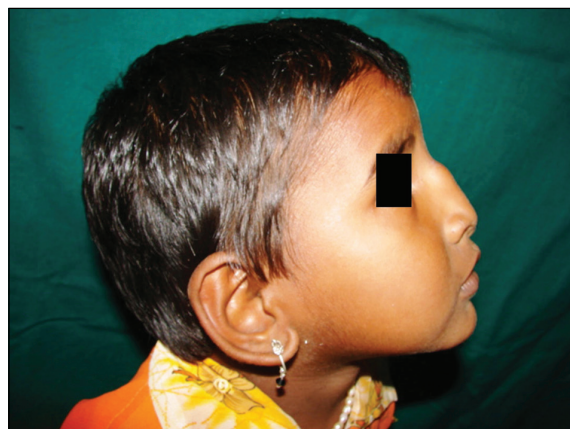Craniofacial clefts were classified by Tessier in 1973 based on his personal experience yielded by clinical, radiologic, and surgical observations. The exact incidence is not known, but estimates range from 1.4 to 4.9 per 100,000 live births.<sup>[2,3]</sup> These clefts are found along the lines of fusion of different processes responsible for development of face during the first 8 weeks of life. Tessier craniofacial clefts may involve



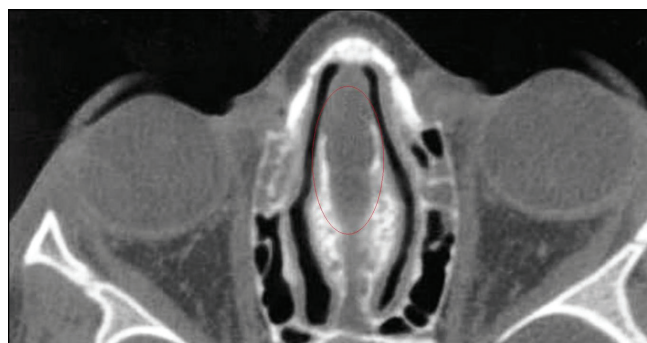
**Figure 1:** Frontal view photograph showing swelling on dorsum of the nose and mild depression in midline. Note the presence of a punctum at dorsum of the nose (ellipse)



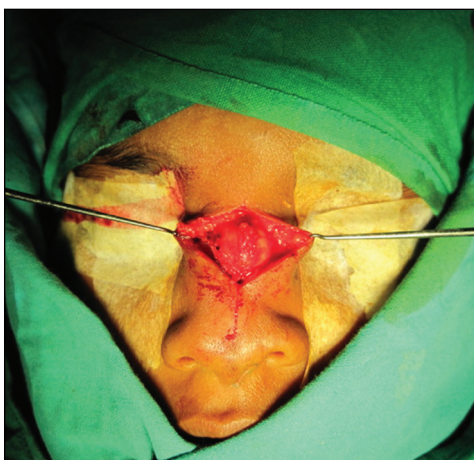
**Figure 2:** Worms eye view showing swelling on dorsum of the nose and mild depression in the midline. Note the increased width of columella



**Figure 3:** Lateral view showing convexity of swelling over dorsum of the nose



**Figure 4:** Axial computed tomography (CT) scan view showing the dermoid cyst lining within the confines of nasal septum (ellipse)

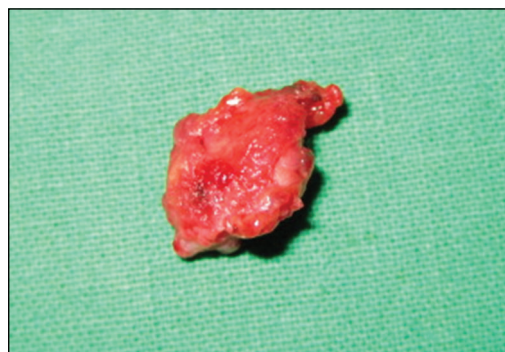

**Figure 5:** Intraoperative photograph showing the cyst after exposure

entire soft tissue and skeletal elements throughout the course of cleft, resulting in a distorted craniofacial growth pattern and altered potential for normal growth. The number 0 cleft results from failure of the two medial nasal processes to fuse in the midline. An incomplete median cleft may occur as an isolated entity or as part of syndromes such as oral-facial-digital (OFD) syndrome. The bifid nose is a malformation that falls within a spectrum of Tessier number 0 cleft, occurring directly in the midline of the lip and nose.<sup>[2,3]</sup> The nasal bridge is usually broad, with associated orbital hypertelorism. The columella and nasal tip are typically bifid and broadened, with a midline depression or groove.<sup>[4]</sup> The nose appears shortened in the vertical dimension. In our case, it was a mild Tessier's 0 cleft involving nose without orbital hypertelorism.

A thorough preoperative evaluation and appropriate planning are essential before excision of a NDC. Many different approaches have been advocated for the removal of nasal dermoids, ranging from a simple extracranial excision to complex procedures in which intracranial excision and nasal reconstruction are required.<sup>[5]</sup> Incision and drainage, aspiration, curettage, and subtotal excision fail to eradicate the cyst, resulting in recurrence. A midline vertical incision remains the most common approach. The cutaneous punctum is removed in continuity with the cyst by making an elliptical incision around the sinus opening.<sup>[5,6]</sup> Other approaches; such as transverse incision, lateral rhinotomy, external rhinoplasty, inverted-U incision, and degloving procedures; have also been advocated. Failure to diagnose and excise nasal dermoid properly can result in progressive enlargement, skeletal distortion, infection, meningitis, and intracranial abscess.<sup>[7]</sup> We advise a complete evaluation and neurosurgical consultation if any clinical or radiographic indication of intracranial involvement is found.

From a surgical point of view for managing Tessier's 0 cleft, even microform clefts may be disfiguring. When planning to



**Figure 6:** Surgical specimen of excised dermoid cyst

treat number 0 cleft, the surgeon must assess severity of the cleft. In more severe cases, when the nasal dorsum is affected and duplication of the septum occurs, resection of the excess tissue over the nasal dorsum, and closing in the midline may be performed.<sup>[8]</sup> A Z-plasty and broken-line scars are performed only if it is necessary to provide significant soft tissue nasal length, avoiding nonanatomic correction. Some authors have surgically managed the patients with resection of dorsal nasal skin, reshaping of cartilaginous structures, and using bicoronal approach in severe cases. They have proposed performing lateral osteotomies even in children. However, this may have some deleterious effects on nasal growth and it is better to postpone the lateral osteotomy until postadolescent period.<sup>[8,9]</sup>

The combined extraoral and intraoral approach enables a clear exposure of all nasal and lateral maxillary structure and especially in relation with the cleft region. For this reason, repair of bifid nose may be accomplished without previously described skin excision and wide dissections, yielding a better healing.<sup>[9]</sup> Besides lengthening the columella with this incision involving the only nasal sill area, modified forked flap enables exposure of the nose as well.<sup>[10]</sup>

In conclusion, Tessier's 0 cleft with presence of midline NDC within the groove of bifid nose is a very rare occurrence. Successful management of the midline NDCs along with Tessier's 0 cleft requires a thorough preoperative evaluation followed by a meticulous excision of dermoid cyst with appropriate planned surgical technique, later for correction of nasal deformity.

## REFERENCES

1. Denoyelle F, Ducroz V, Roger G, Garabedian EN. Nasal dermoid sinus cysts in children. *Laryngoscope* 1997;107:795-800.
2. Tessier P. Anatomical classification of facial, cranio-facial and latero-facial clefts. *J Maxillofac Surg* 1976;4:69-92.
3. Mullin WR, Millard DR Jr. Management of congenital bilateral cleft nose. *Plast Reconstr Surg* 1985;75:253-7.
4. Boo-Chai K. The bifid nose. With report of 3 cases in siblings. *Plast Reconstr Surg* 1965;36:626-8.

5. Yavuzer R, Bier U, Jackson IT. Be careful: It might be a nasal dermoid cyst. *Plast Reconstr Surg* 1999;103:2082-3.
6. Bloom DC, Carvalho DS, Dory C, Brewster DF, Wickersham JK, Kearns DB. Imaging and surgical approach of nasal dermoids. *Int J Pediatr Otorhinolarygol* 2002;62:111-22.
7. Huisman TA, Schneider JF, Kellenberger CJ, Martin-Fiori E, Willi UV, Holzmann D. Developmental nasal midline masses in children: Neuroradiological evaluation. *Eur Radiol* 2004;14:243-9.
8. Turkaslan TO, Ozcan H, Genc B, Ozsoy Z. Combined intraoral and nasal approach to Tessier no. 0 cleft with bifid nose. *Ann Plast Surg* 2005;54:207-10.
9. Blake WE, Chow CW, Holmes AD, Meara JG. Nasal dermoid sinus cysts: A retrospective review and discussion of investigation and management. *Ann Plast Surg* 2006;57:535-40.
10. Butow KW. Construction of the congenitally missing columella in midline clefts. *J Craniomaxillofac Surg* 2007;35:287-92.

**How to cite this article:** Guruprasad Y, Chauhan DS. Midline nasal dermoid cyst with Tessier's 0 cleft. *J Nat Sc Biol Med* 2014;5:479-82.

**Source of Support:** Nil. **Conflict of Interest:** None declared.

Access this article online	
<b>Quick Response Code:</b>	<b>Website:</b> www.jnsbm.org
	<b>DOI:</b> 10.4103/0976-9668.136272