

Trans-umbilical Laparoscopic Appendectomy for Acute Appendicitis without Raising Skin-flaps: An Easy-to-use Modification Applied to the Series of 164 Patients from a Rural Institute of Central India

Priyadarshan Anand Jategaonkar, Sudeep Pradeep Yadav¹

Department of Surgery, Mahatma Gandhi Institute of Medical Sciences, Sevagram, Wardha, ¹Jagjivanram Western Railway Hospital, Mumbai Central, Mumbai, Maharashtra, India

INTRODUCTION

Laparoscopic appendectomy (LA) is widely used and generally accepted method having several advantages over open appendectomy. Moreover, trans-umbilical laparoscopic surgery, with its benefits regarding post-operative pain and cosmesis has contributed to further improvements in LA. Although it reduces the number of ports, it may add on to the umbilical trauma. Conventional single-port surgery needs expensive equipments (which may not be readily available) and require a larger umbilical incision.^[1] Furthermore, it is applied principally to chronic appendicitis. However, acute appendicitis, with all its complications, forms a major chunk of emergency general surgical practice at any institution. We, in this paper, try to study a simple easy-to-learn technique and discuss its application to acute appendicitis with various complicated scenarios.

MATERIALS AND METHODS

A total of 164 patients from our rural institute from central India underwent appendectomy by the technique described from August 2009 to March 2011. Out these 164 patients, 102 were males and 62 were females. The mean body mass

ABSTRACT

Background: Laparoscopic appendectomy (LA) is widely used and generally an accepted method for managing appendicitis. And the recent invention of laparoscopic trans-umbilical-appendectomy is a further improvement of LA. However, it requires expensive instruments with the requisite expertise. We discuss a useful modification of trans-umbilical appendectomy for acute appendicitis using routine instruments. **Materials and Methods:** From August 2009 to March 2011, 164 patients were operated by this method at our rural center. Out of them, 102 were males and 62, females. Mean age for males was 27.5 years (range, 14-51) and females, 31.2 years (range, 17-48). Mean body mass index was 21.7 kg/m² (range, 16.2-29) and 23.2 kg/m² (range, 17.4-30) for males and females respectively. Acute appendicitis patients wherein surgery was deemed essential were offered this technique. Three umbilical ports (one 10 mm and two 5 mm) were strategically placed to dissect out appendix. Routine laparoscopic instruments were used for all. **Results:** Mean operative-time was 45 min (range, 30-90) with 1.8% conversion-rate to conventional laparoscopy. Average blood-loss was 15 ml (range, 10-25). We had one caecal electrosurgical injury, which was managed expectantly. Umbilical sepsis and seroma were 3% and 6.1% respectively. Patients were discharged after an average 1.3 days (range, 1-4). The scars had receded in the umbilicus giving a near-scarless abdomen. **Discussion:** Recently developed technique of single-port appendectomy has primarily been used for chronic appendicitis. Moreover, >1 inch incision induced per-umbilicum rises the attendant morbidity. We study a surgeon-friendly simple technique applied to acute appendicitis. **Conclusion:** Method described here is feasible and safe for managing acute appendicitis. It can be learnt rather easily (learning curve of 15 cases) by a laparoscopic surgeon and avoids expensive instrumentation. Thus, it may stand out in providing benefits of modern surgery to population of developing countries.

Key words: Acute appendicitis, Laparoscopic appendectomy, Trans-umbilical surgery

index (BMI) was 21.7 kg/m² (range, 16.2-29) for males and 23.2 kg/m² (range, 17.4-30) for females. The average age was 27.5 years (range, 14-51) for males and 31.2 years (range, 17-48) for females. Eleven females had umbilical scar of laparoscopic tubal ligation. 50 males and 23 females had some form of medical co-morbidity in this series

Access this article online

Quick Response Code:



Website:

www.jstcr.org

DOI:

10.4103/2006-8808.118593

Address for correspondence: Dr. Priyadarshan Anand Jategaonkar, 201, Yamuna Apartment, Yashasvi Nagar, Balkum, Thane (W), Thane - 400 608, Maharashtra, India.
E-mail: shekharsmitaj@yahoo.com

Table 1: Patient features

Patient characteristics	Parameters
Number of patients	164
Sex (male: female)	102:62
Average age (years)	
Male	27.5 (range, 14-51)
Female	31.2 (range, 17-48)
Average BMI (kg/m ²)	
Male	21.7 (range, 16.2-29)
Female	23.2 (range, 17.4-30)
Comorbidities	
Male	24 HT, 18 DM, 8 HT+DM
Female	13 HT, 6 DM, 4 HT+DM
Previous abdominal surgery	
Male	0
Female	11 TL
Pathology	
Acute appendicitis	145
Perforated appendicitis	13
Gangrenous appendicitis	6

HT – Hypertension; DM – Diabetes mellitus; TL – Tubal ligation; BMI – Body mass index

[Table 1]. A well-explained consent about the procedure was taken from everybody. To avoid the outcome-bias, all the patients were operated by the same fellowship-trained laparoscopic surgeon.

Surgical technique

We used 30° 10 and 5 mm rigid laparoscopes and routine instruments for all cases. Under general anesthesia, the patient was placed in the supine position with 15-20° Trendelenberg position. The surgeon stood on the left side of the patient and camera-assistant on the left of surgeon. Monitor placed on the right of the patient. Certain maneuvers were adapted to rectify intra-corporeal as well as extra-corporeal instrument-clashing and to purchase ‘elbow-space’ for the surgeon and camera-assistant.

Pneumoperitoneum created by Veress needle inserted at 5 O'clock position at the umbilical mound. An 11 mm curvilinear incision at this position was used to insert 10 mm camera-trocar. Two 5 mm curvilinear skin-crease incisions were placed on the umbilical mound at 7 and 12 O'clock positions on the umbilical mound for the left and right-hand working trocars respectively [Figure 1]. Fascial trajectories for these trocars were not overlapping with the skin-entries, but they were planned 3-4 mm away from the respective cutaneous entries [Figure 1]. This was achieved as follows-once in subcutaneous space, the trocar lifted the skin and subcutaneous tissue and was made to enter the fascia and peritoneum at 3-4 mm beyond the skin-incision. This modification helped in reducing intra-corporeal “sword-fighting” of instruments. We set the

pressure of the pneumoperitoneum to 14 mm of Hg. This pneumoperitoneum stretched the umbilicus to purchase some extra distance between the trocars. All these maneuvers maintained the triangular arrangement between trocars as well as optimized the distance between them to achieve adequate degree of freedom and avoided them to be “on-top” of each other [Figure 2]. We called this as the “triangle-in-triangle effect” of placement of trocars [Figure 1].

System adopted to rectify the operator-assistant crowding was as follows. The 5 O'clock camera-port position allowed the assistant's camera-holding hand to always be underneath the surgeon's hands. We adjusted the distant tip of 10 mm camera-port to be just inside the peritoneal cavity. This step made it possible to keep the laparoscope withdrawn most of the times, thus, having minimal intra-corporeal length of the laparoscope. Both the 5 mm working trocars were pushed with an extra 2-3 mm distance toward the target. The light cable was made to exit from the top of the laparoscope. Five mm, both valved trocars were preferred. With the valves adjusted outwardly, one of them was used for CO₂ insufflation (this avoided fogging of the lens) and the other one was used for venting the surgical smoke when required. This entire assembly helped in achieving a ‘clash-free’ surgery.

The arrangement of trocars at the umbilical mound was dictated and modified by the location of the appendix. Pelvic appendix can be operated by the above-mentioned assembly. However, appendix placed high up in the right hypochondrium (e.g., sub-hepatic appendix) may not be amenable to this arrangement. For such case, one can adopt following trocar assembly – 5 O'clock (10 mm - camera port) × 9 O'clock (5 mm - left hand working port) × 2 O'clock (5 mm - right hand working port). We used this modification in 16 cases of sub-hepatic appendices performed in this series.

Contemplating adhesions in 11 patients with umbilical scars, open technique for creating pneumoperitoneum was used. Ultrasonic scalpel was used wherever necessary. Mesoappendix dissection commenced from its tip to reach the base [Figure 3]. This reduced the ‘bulk’ of specimen to be removed. It was then doubly looped with catgut and divided. The specimen extracted via 10 mm port under vision [Figure 2]. Turgid appendixes not amenable to be removed via 10 mm trocar were extracted through endobags. Thorough saline wash was given. We inserted a tube drain (three patients of perforated appendix) through 7 O'clock 5 mm port. All ports closed with polyglactin 2/0. Skin closed with monofilament sub-cuticular suture and

infiltrated with local anesthesia to achieve near-normal umbilical appearance [Figure 4]. Therapeutic doses of broad-spectrum antibiotics were administered in all.

RESULTS

Our mean operative time was 45 min (range, 30-90) and blood-loss 15 ml (range, 10-25). There was one inadvertent electro-surgical caecal injury during one of our initial cases. This patient recovered well with expectant line of management. Three of our patients (conversion rate = 1.8%) had to be converted to conventional 3-port LA to complete the safe dissection. Two amongst them had retrocaecal appendix firmly adherent to the caecum, thus, precluding dissection under vision. One patient had intense peri-appendicular adhesions that could not be attended with our technique. However, there were no conversions to open appendectomy. None of the patients required any additional ports for dissection/drainage.

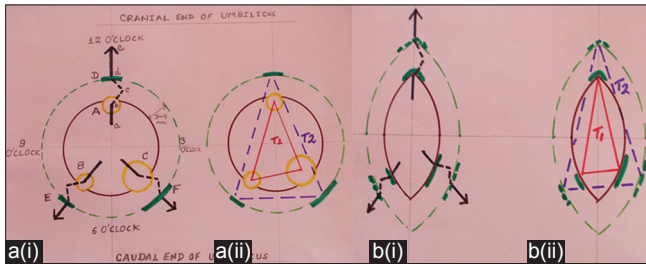


Figure 1: Port positions. a(i) Wide umbilicus showing skin entries (A-5 mm, B-5 mm, C-10 mm) and respective fascial entries (D, E, F) of the ports. Note the technique of port insertion: ab -skin and subcutaneous entry, bc-upward and forward deflection in the subcutaneous space, cd-downward and forward deflection in the subcutaneous space, de-fascial and peritoneal entries. Note that the skin and the fascial entries are not overlapping. a(ii) Triangle (T1) -in-triangle (T2) -effect for wide umbilicus. b(i) and b(ii): a similar depiction for narrow umbilicus

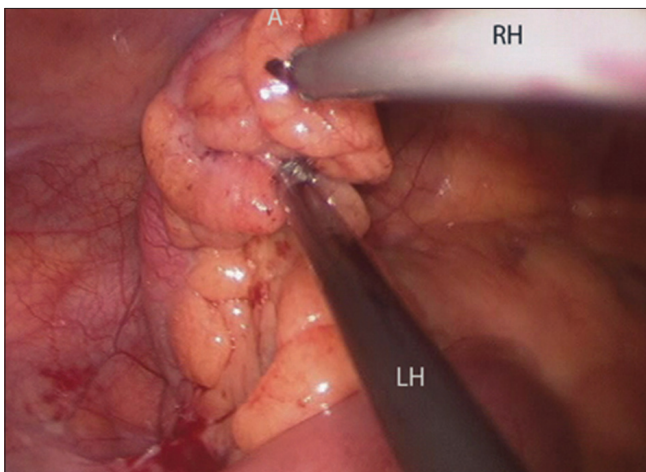


Figure 3: Trans-umbilical view of acutely inflamed and turgid appendix (A). Note the triangular ergonomics of right- and left-working instruments (RH and LH)

Visual Analog Scale was used to record pain scores. It was average 1 and 0.3 on the post-operative day 0 and 1 respectively; and nil on days 5 and 7. Though we have not compared these scores with conventional 3-port appendectomy cases undertaken at our unit, we feel that they were less for the technique described. All patients were ambulatory on the same day of surgery and were discharged by 1.3 days (range, 1-4) post-operatively. Umbilical sepsis and umbilical seroma were 3% and 6.1% respectively [Table 2].

DISCUSSION

The laparoscopic trans-umbilical technique described here for appendectomy is a further improvement of standard single-port technique, which is helpful to the surgeons working especially with limited resources in a developing country like India. As only the routine laparoscopic

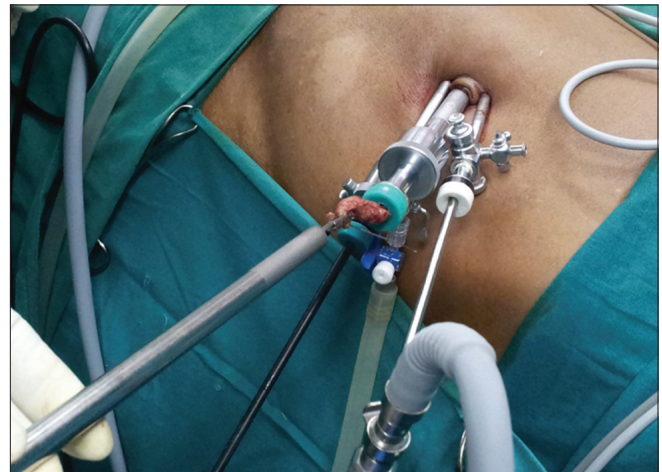

Figure 2: Port position. 10 mm camera-port at 5 O'clock position and two 5 mm working ports at 7 and 12 O'clock. Appendix is being extracted through 10 mm port under laparoscopic vision from 5 mm trocar. Note the position of light cable and port-valves

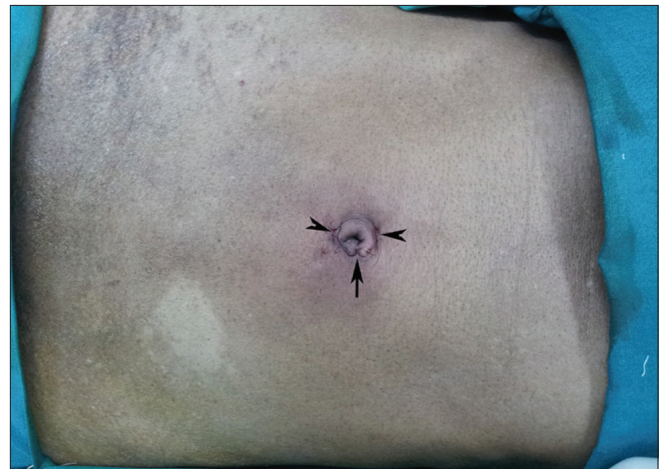

Figure 4: Post-operative umbilicus. Note near-invisible scars of 10 mm port (arrow) and 5 mm ports (arrow-heads)

Table 2: Results

Perioperative outcomes	Parameters
Intra-operative	
Average surgical duration (min)	45 (range, 30-90)
Average blood loss (ml)	15 (range, 10-25)
Conversion rate	1.8%
Post-operative period	
Pain (average visual analogue scale)	
Post-operative day 0	1 (range, 0.6-2)
Post-operative day 1	0.3 (range, 0.2-0.8)
Post-operative day 5	0
Post-operative day 7	0
Umbilical seroma	6.1%
Umbilical sepsis	3%
Hospital stay (days)	1.3 (range, 1-4)
Incisional hernia	0

instruments are used, such a laparoscopic surgeon can get familiarized easily with this technique. It has potential of reducing the cost of surgery. In late 2009, we started using this technique for chronic appendicitis before applying it for acute cases. Although there are conflicting results regarding duration of laparoscopic single-incision appendectomy as compared to conventional laparoscopic surgery,^[2,3] with an increasing number of cases our operative time reduced gradually.

The three curvilinear skin incisions placed strategically at the umbilical mound form a perfect ergonomic triangle necessary for safe and effective dissection of the target organ. Further, the fascial entries of the trocars are done about 3-4 mm away from their respective cutaneous entries. This particular arrangement of the trocars in pneumoperitoneum-induced stretched umbilicus further widens the triangle made by the three trocars, thus, easing on the ergonomic complexity besides eliminating the chop-stick effect of the instruments. Furthermore, by avoiding larger peri-umbilical incision and raising the skin-flap the post-operative short and long-term complications like sub-cutaneous seroma can be easily barred. Hence, the incidence of seroma in our series was less (6.1%) as compared to that reported in literature (13.3%).^[4] Another advantage of this technique was found to be maneuverability of 5 mm working ports at the umbilical mound subject to the location of the target organ.

One of the problems, which can be commonly faced especially in the early part of the learning process, is the loss of pneumoperitoneum through oversized port-incisions. We feel that the precision to place the exact size of these incisions is the key to avoid loss of pneumoperitoneum. We had this situation in four of our initial cases wherein we narrowed the incisions by taking a stitch.

The problem of specimen extraction especially in these cases of acute appendicitis can be tactfully solved by the non-touch reverse railroading technique via 10 mm port after alignment or else through endobags. We feel that this had a major contribution in drastically reducing (3% in our series) the otherwise high incidence (6.7%) of umbilical sepsis as reported for single-incision appendectomy.^[4] However, it is too early to comment on this due to the paucity of randomized studies. Moreover, the inflammatory edema fluid in such acute cases may actually aid in easily opening up the dissecting planes by suction-dissection technique. Hence, the apparently difficult pathology may in fact be easily managed without many problems.

Conversion rates reported in the literature for single-incision appendectomy are variable and as high as 25%.^[3,5] In our series, it was 1.8%. It depends on the degree of complexity the surgeon faces during the procedure and the expertise of, not only the operating surgeon, but the entire surgical team. We feel that formal fellowship training to the surgeon as well as structured training programs for paramedical personnel facilitate the surgical team to acquire requisite expertise very early on their otherwise steep learning curve of trans-umbilical surgeries. In this series, the learning curve of our surgical team to attain expertise in this operative technique was the initial 15 patients. We further insist that one needs an equally competent camera-operating assistant as even smaller inadvertent camera movements while in dissection disturbs the surgical ergonomics to a larger extent.

The mathematical relationship of length of incision and the amount of port-site pain has been elegantly explored to its detail by Blinman.^[6] It proves that total tension (and hence the pain) acting across multiple incisions is always lesser than that acting at a single incision of equal length. Hence, it's better to use two/three smaller trocars than to use a single larger one as such a single-port can add up to 50% more tension on the wound than the smaller trocars. As the tension on the port site wound is directly proportional to the square (and not addition) of the length of incision, the amount of tension expected to act at three of our port sites collectively would be 476.1 units. As against this, the tension expected at the single-incision surgery using 25 mm or 35 mm ports would be up to the tune of 1540.6 units or 3016.7 units respectively. Logically, three-trocar trans-umbilical technique is expected to produce markedly less pain than single-incision approach. Although the pain results reported in the literature are varied and puzzling,^[4,7] these calculations may point

towards better pain scores for the technique studied in this paper.

The cosmetic appearance of the umbilicus remains near-normal and appealing as the port scars get eventually receded in the umbilical cicatrix. Although we did not encounter any incisional hernia at the umbilicus on follow-up of more than 3 years in this series, we insist that a further long-term follow-up should be undertaken to evaluate the true incidence. We further feel that, this technique may also be used for tackling other intra-abdominal pathologies.

CONCLUSION

The technique described here is feasible and safe for managing cases of acute appendicitis. It has a potential to reduce the cost of surgery and post-operative pain scores as compared to single-port methods. Hence, it may be considered as a competent alternative to single-incision LA especially for developing nations.

REFERENCES

1. Frutos MD, Abrisqueta J, Luján JA, García A, Hernández Q, Valero G, *et al.* Single incision transumbilical laparoscopic appendectomy: Initial experience. *Cir Esp* 2011;89:37-41.
2. Greaves N, Nicholson J. Single incision laparoscopic surgery in general surgery: A review. *Ann R Coll Surg Engl* 2011;93:437-40.
3. Ahmed K, Wang TT, Patel VM, Nagpal K, Clark J, Ali M, *et al.* The role of single-incision laparoscopic surgery in abdominal and pelvic surgery: A systematic review. *Surg Endosc* 2011;25:378-96.
4. Kang KC, Lee SY, Kang DB, Kim SH, Oh JT, Choi DH, *et al.* Application of single incision laparoscopic surgery for appendectomies in patients with complicated appendicitis. *J Korean Soc Coloproctol* 2010;26:388-94.
5. Chouillard E, Dache A, Torcivia A, Helmy N, Ruseykin I, Gumbs A. Single-incision laparoscopic appendectomy for acute appendicitis: A preliminary experience. *Surg Endosc* 2010;24:1861-5.
6. Blinman T. Incisions do not simply sum. *Surg Endosc* 2010;24:1746-51.
7. Kim HO, Yoo CH, Lee SR, Son BH, Park YL, Shin JH, *et al.* Pain after laparoscopic appendectomy: A comparison of transumbilical single-port and conventional laparoscopic surgery. *J Korean Surg Soc* 2012;82:172-8.

How to cite this article: Jategaonkar PA, Yadav SP. Trans-umbilical Laparoscopic Appendectomy for Acute Appendicitis without Raising Skin-flaps: An Easy-to-use Modification Applied to the Series of 164 Patients from a Rural Institute of Central India. *J Surg Tech Case Report* 2013;5:8-12.

Source of Support: Nil, **Conflict of Interest:** None declared.

Announcement

Android App



Download
**Android
application**

FREE

A free application to browse and search the journal's content is now available for Android based mobiles and devices. The application provides "Table of Contents" of the latest issues, which are stored on the device for future offline browsing. Internet connection is required to access the back issues and search facility. The application is compatible with all the versions of Android. The application can be downloaded from <https://market.android.com/details?id=comm.app.medknow>. For suggestions and comments do write back to us.