

Accidental discovery of a mass on the left main bronchus in a patient undergoing thyroid surgery

ABSTRACT

A left lung mass after induction and tracheal intubation, which partially was obstructing the left main bronchus, was accidentally discovered in a 56-year-old female scheduled to undergo elective total thyroidectomy. Her preoperative chest X-ray showed a right-sided shift of the trachea. She did not have stridor or shortness of breath or superior vena cava obstructive syndrome. Induction and tracheal intubation were performed uneventfully. Fiberoptic bronchoscopy performed and showed complete obstruction on the left main bronchus. Excision biopsy suggested mucoepidermoid carcinoma (MEC). MEC is one of the very rare neoplasms of the lungs. Most lesions are low grade and overall prognosis may be more favorable than other forms of lung cancer.

Key words: Anesthesia; lung mass; mucoepidermoid

Introduction

Mucoepidermoid carcinoma (MEC) is a type of salivary gland tumor. MECs are one of the rare neoplasms of the lungs with an incidence of 0.1%–0.2% mostly occur in young adult patients.^[1,2] Most lesions are low grade and overall prognosis may be more favorable than other forms of lung cancer.^[3,4] The precise nature of these neoplasms is not yet clear and little is known on the histogenesis and pathogenesis of the disease. This is probably due to its rarity and the small number of published studies focusing on its molecular aspects. Mediastinal mass often does not cause symptoms except if it is large and is picked up incidentally by imaging studies performed for other reasons. In some patients, the obstruction caused by a mass is not complete obstruction, and therefore, there is no obvious signs and symptoms. We report a case of a bronchial MEC tumor with a detailed pathological, immune histochemical, and molecular analysis,

as well as a review of the current literature on the histogenic and molecular characteristics of the disease.

Case Report


A 56-year-old female complained of hypertension and diabetes for 10 years and controlled with medications. She is obese with body mass index 35. Hemithyroidectomy was performed 1 year ago, and she was booked for total Thyroidectomy. Patient preoperative chest X-ray (CXR) showed a right side tracheal deviation due to a large thyroid mass. The patient feels heaviness due to the thyroid mass but no stridor or shortness of breath or superior vena cava compression syndrome or orthopnea. On examination, there was an equal air entry bilaterally. In the operative room, standard monitoring was applied. Preoxygenation for 3 min was applied. Induction of anesthesia was achieved with propofol 2 mg/kg, fentanyl 2 mcg/kg, and rocuronium 0.6 mg/kg. Tracheal Intubation

This is an open access journal, and articles are distributed under the terms of the Creative Commons Attribution-NonCommercial-ShareAlike 4.0 License, which allows others to remix, tweak, and build upon the work non-commercially, as long as appropriate credit is given and the new creations are licensed under the identical terms.

For reprints contact: reprints@medknow.com

How to cite this article: Abaalkhayl M. Accidental discovery of a mass on the left main bronchus in a patient undergoing thyroid surgery. Saudi J Anaesth 2018;12:465-7.

Access this article online

Website: www.saudija.org	Quick Response Code
DOI: 10.4103/sja.SJA_6_18	

MOHAMMED ABAALKHAYL

Department of Anesthesia and Intensive Care, College of Medicine, Qassim University, Buraydah, Qassim, Saudi Arabia

Address for correspondence: Dr. Mohammed Abaalkhayl, Department of Anesthesia and Intensive Care, College of Medicine, Qassim University, P. O. Box 14452, Qassim, Saudi Arabia. E-mail: dr.msaa@hotmail.com

was performed easily. Confirmed by auscultation, there is a good right side air entry, but marked decreases in the left side air entry with no abnormal sounds. Oxygen saturation (SpO₂) was 97% on 100% oxygen. Other vital signs were all within normal range. Attempts were made to adjust the tube, but it was above carina by many maneuvers. CXR done showed the tube was above carina by 2 cm. Right tracheal deviations were same preoperatively and there was no sign of pneumothorax. Moreover, some consolidation of the left upper lobe was noticed. We compared it with preoperative CXR. Fiberoptic bronchoscopy (FOB) performed showed normal right main bronchus and lobes. The left side showed a soft-tissue mass nearly completely obstructed in the left main bronchus below the primary carina at the level of the secondary carina. We consulted a thoracic surgeon. A bronchoscopy was done, and computed tomography (CT) scan was suggested before biopsy. Carcinoid tumor was to be ruled out. The general surgery team canceled thyroidectomy procedure. Sugammadex 2 mg/kg was given and the trachea was extubated. The patient was shifted to postanesthesia care unit (PACU) and was breathing normally in a sitting position. The patient was shifted to the ward with 24-h monitoring. The patient slept normally with oxygen saturation maintained above 94% on room air. CT showed endobronchial soft-tissue lesion within the left main bronchus measured 1 cm with subsequent total collapse of the left lower lobe and hyperinflation of left upper lobe [Figure 1]. Rigid bronchoscopy and endobronchial tumor resection were performed uneventfully. The trachea was extubated, and the patient was shifted to PACU with normal vital sign. Excision biopsy confirmed the diagnosis of MEC was made where chemotherapy was advised.

Discussion

The case represents early detection and management of an intraoperative event with asymptomatic preoperative

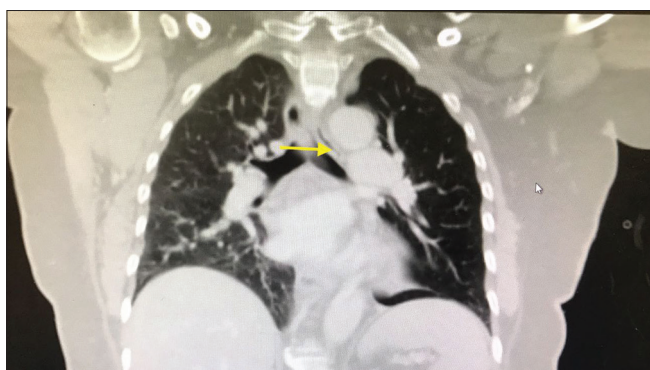


Figure 1: Spiral computed tomography showed endobronchial soft-tissue lesion within the left main bronchus measured 1 cm with subsequent total collapse of the left lower lobe and hyperinflation of the left upper lobe. No lymph node involved

patient. Mediastinal mass often does not cause symptoms except if it is large and is picked up incidentally by imaging studies performed for other reasons. In some patients, the obstruction caused by a mass on the tracheobronchial tree is not complete obstruction, and therefore, there is no obvious signs and symptoms except if the patient has a CXR finding preoperatively. In our case, once the patient was under anesthesia, the mass caused complete obstruction of the left main bronchus. FOB represents the main diagnostic tool for MECs because it allows direct visualization of the lesions and biopsies although extraluminal or peripheral lesions cannot be assessed by bronchoscopy.^[5] In our case, given the rich vascularity of the lesion, the surgeon preferred to perform biopsy through rigid bronchoscopy to avoid hemorrhagic complications. MEC generally affects patients younger than those affected by the most common nonsmall cell lung cancer.^[6] In a series of 56 cases published by Yousem *et al.*, more than 50% of the sufferers were under 30 years of age, while in that of Li *et al.*, the mean age was 34 years. The mean ages were between 50 and 55 years in other reports; it seems that high-grade MEC occurs more frequently in older patients, in comparison with low-grade MEC.^[7] No clear sex predilection has been ruled out. Surgery is the mainstay of treatment for MEC.^[8] If the tumor is apparently invasive and large, preoperative (neoadjuvant) chemotherapy and/or radiotherapy may be used to decrease the size and improve resectability before surgery.

Conclusion

We believe that any abnormal findings after induction of anesthesia should be investigated before the commencement of surgery and proper action to be taken. It is wise to cancel the procedure and investigate it afterward with special reference to elective procedures.

Declaration of patient consent

The authors certify that they have obtained all appropriate patient consent forms. In the form the patient(s) has/have given his/her/their consent for his/her/their images and other clinical information to be reported in the journal. The patients understand that their names and initials will not be published and due efforts will be made to conceal their identity, but anonymity cannot be guaranteed.

Financial support and sponsorship

Nil.

Conflicts of interest

There are no conflicts of interest.

References

1. Kitada M, Matsuda Y, Sato K, Hayashi S, Ishibashi K, Miyokawa N, *et al.* Mucoepidermoid carcinoma of the lung: A case report. *J Cardiothorac Surg* 2011;6:132.
2. Brambilla E, Travis WD, Colby TV, Corrin B, Shimosato Y. The new world health organization classification of lung tumours. *Eur Respir J* 2001;18:1059-68.
3. Eversole LR. Histogenic classification of salivary tumors. *Arch Pathol* 1971;92:433-43.
4. Fois AG, Diana G, Arcadu A, Marras V, Crivelli P, Putzu C, *et al.* Bronchial mucoepidermoid carcinoma: A case report. *Int J Surg Case Rep* 2017;31:159-62.
5. Leonardi HK, Jung-Legg Y, Legg MA, Neptune WB. Tracheobronchial mucoepidermoid carcinoma. *J Thorac Cardiovasc Surg* 1978;76:431-8.
6. Turnbull AD, Huvos AG, Goodner JT, Foote FW Jr. Mucoepidermoid tumors of bronchial glands. *Cancer* 1971;28:539-44.
7. Klacsmann PG, Olson JL, Eggleston JC. Mucoepidermoid carcinoma of the bronchus: An electron microscopic study of the low grade and the high grade variants. *Cancer* 1979;43:1720-33.
8. Ishizumi T, Tateishi U, Watanabe S, Matsuno Y. Mucoepidermoid carcinoma of the lung: High-resolution CT and histopathologic findings in five cases. *Lung Cancer* 2008;60:125-31.