
Superior mediastinal syndrome secondary to Pott's spine in a child

Sir,

Superior mediastinal syndrome (SMS) in children is a medical emergency necessitating prompt intervention often involving multimodality approach.

A 9-year-old appropriately immunized boy presented with complaints of fever, nonproductive cough, loss of appetite, and weight loss for 2 months, with exertional dyspnea and orthopnea for 7 days. There was no history of noisy breathing, difficulty in swallowing, weakness or pain over limbs, back pain, bleeding or blood component therapy, or contact with tuberculosis (TB). He was hemodynamically stable but had mild tachypnea with suprasternal retraction which further increased on the supine position. There was fullness over the face and neck, with dilated veins over the neck. Multiple, painless, soft, nonmatted cervical lymph nodes of around 1 cm × 1 cm were present over bilateral anterior triangle of the neck with mild pallor. His anthropometric parameters were within normal limits, and systemic examination revealed hepatomegaly and biphasic wheeze on auscultation over bilateral lung fields. There was no tenderness or deformity over the spine, and nervous system examination was essentially normal. Skiagram of the chest showed

mediastinal widening, right middle lobe infiltrates, and right-sided minimal pleural effusion. Complete blood counts revealed only mild microcytic and hypochromic anemia, but renal and liver function parameters were within normal limits. A diagnosis of SMS was considered and further investigations were commenced. Fine needle aspiration cytology (FNAC) from cervical lymph nodes was reported as reactive lymphoid hyperplasia. A contrast-enhanced computed tomography (CT) scan of the thorax and abdomen showed a large, multiloculated abscess in the mediastinum causing compression over trachea, esophagus, superior vena cava (SVC) anteriorly, and destruction of vertebra posteriorly [Figure 1a and b]. The right middle lobe alveolar infiltrates and minimal pleural effusion were also confirmed. Abdomen was essentially normal. Contrast-enhanced magnetic resonance imaging (MRI) of the spine revealed destroyed D1 and D2 vertebra replaced by intraosseous abscess, multiple paravertebral collections from C2 to D5 vertebral level with epidural abscess at C6–D4 level causing compression of the spinal cord. C5–D4 vertebrae had altered marrow signal intensity with postcontrast enhancement along with subtle signal changes in the cord [Figure 2], and screening of the brain was normal. A diagnosis of disseminated TB with Pott's spine causing spinal cord compression and

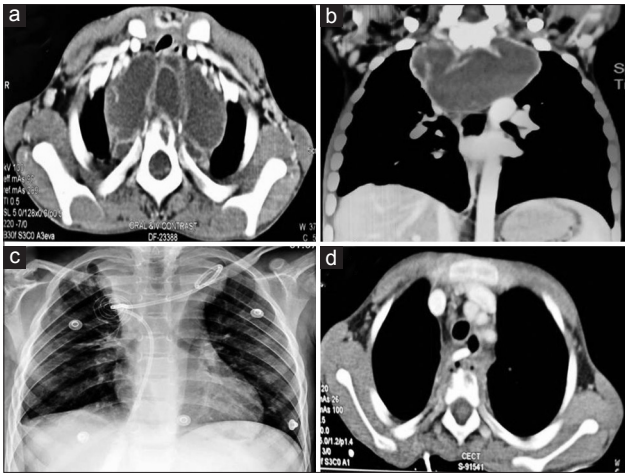


Figure 1: (a and b) Contrast-enhanced computed tomography scan of the chest showing a large, multiloculated abscess in the mediastinum causing compression over trachea, esophagus, superior vena cava anteriorly, and destruction of vertebra posteriorly. (c) Chest X-ray showing pigtail catheter inside the mediastinal abscess. (d) Computed tomography scan of the chest postpigtail catheter removal showing near complete resolution of mediastinal abscess

SMS was made and the child was started on four drugs anti-TB therapy (ATT) and corticosteroid. CT-guided pigtail catheter insertion was done through the right paraspinal space under general anesthesia [Figure 1c] and 60 ml of thick pus was aspirated. The pigtail catheter was kept for next 48 h draining 120 ml of pus with the child being in strict bed rest. Clinical features of SMS also resolved completely over this period. The Mantoux test was strongly positive (30 mm). Pus was negative for acid-fast bacilli (AFB) but came out to be positive for *Mycobacterium tuberculosis* sensitive to rifampicin by GeneXpert. Postremoval of pigtail catheter, repeat CT scan of the thorax also confirmed near complete resolution of the mediastinal abscess [Figure 1d]. HIV serology and induced sputum for AFB and GeneXpert were negative. Contact screening with chest X-ray failed to find out any case of pulmonary TB in the contacts. There was no evidence of sinus formation at the insertion site after catheter removal. Upon consultation with orthopedic surgeon, a cervicothoracic brace was applied. In the meantime, the child became afebrile, had substantial improvement of appetite, and did not develop any neurological deficit. Corticosteroid therapy was tapered and stopped after a total of 8 weeks. Pus for culture in mycobacterium growth indicator tube media grew *M. tuberculosis* and it was sensitive to all the first-line ATT. After 6 months, he is totally asymptomatic and planned of total duration of ATT for 12 months with close follow-up.

Establishing a diagnosis in children with SMS can be challenging. It is recommended that the least invasive diagnostic procedure, especially the ones performed with the child in an upright position, should be performed first.^[1] Hence, FNAC of cervical lymph node was done at the onset in our patient, but it was noncontributory. CT scan of the

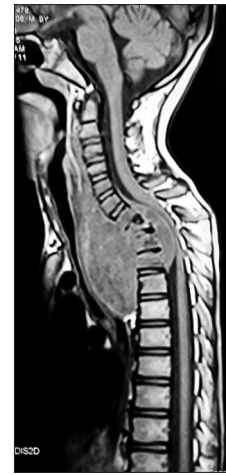


Figure 2: Contrast-enhanced magnetic resonance imaging of the spine showing destroyed D1 and D2 vertebra replaced by intraosseous abscess, multiple paravertebral collections from C2 to D5 vertebral level with epidural abscess at C6–D4 level causing compression of the spinal cord

chest suggested a tubercular involvement of mediastinum and lung and MRI further confirmed Pott's spine. The confirmation of the tubercular etiology was with the help of Xpert MTB (cartridge-based nucleic acid amplification technique). It is currently recommended by the WHO as a replacement of conventional practice (microscopy, culture, or histopathology) for testing specific nonrespiratory specimens in the diagnosis of extrapulmonary TB in both adults and children.^[2]

Malignancies, especially non-Hodgkin's lymphoma and T-cell lymphoblastic leukemia, are the most common causes of SMS in children.^[1] TB may cause compression/obstruction of superior mediastinal structures in different ways leading to SMS: enlarged mediastinal tubercular lymph node,^[3] TB mediastinitis, or secondary to paradoxical enlargement of lymph node while on ATT.^[4] To the best of our knowledge, there has been only a single case report of Pott's disease presenting with SVC compression in children.^[5] Neurological deficit is reported in 10–30% cases of spinal TB,^[6] but our patient neither had any clinical feature suggestive of spinal involvement nor had any neurological deficit pertaining to it. The literature suggests that approximately 33–50% of spinal TB patients have concomitant evidence of pulmonary focus or have a reported history of pulmonary TB.^[7] Although the index case had radiological evidence of pulmonary involvement, bacteriological confirmation was unsuccessful.

In cases of spinal TB, it is advised to start ATT as early as possible, often empirically, much before a bacteriological diagnosis can be established.^[8] Corticosteroid seems to have a definite role in spinal TB only in cases with arachnoiditis and spinal tuberculoma.^[8] In view of MRI findings suggestive of arachnoiditis, corticosteroid was also given along with ATT in our patient. In cases of spinal TB, indication of evacuation of paravertebral abscess is its

persistence increase in size despite medical treatment.^[8] Drainage of pus was decided in our patient in view of SMS and very high risk of impending vertebral collapse leading to spinal cord compression. CT scan-guided pigtail catheter drainage of the abscess was undertaken as similar procedure has been reported to be both safe and effective in the drainage of tubercular abscesses involving the spine.^[9]

Our case emphasizes that TB should be considered as a differential diagnosis in children with SMS in a TB endemic country. Timely diagnosis and early institution of therapeutic interventions are associated with very good prognosis in SMS of tubercular etiology.

Acknowledgment

We would like to acknowledge Dr. Kanaram Jat for his help in the management of the patient.

Financial support and sponsorship

Nil.

Conflicts of interest

There are no conflicts of interest.

**Anirban Mandal, Amitabh Singh, Rachna Seth,
Sushil Kumar Kabra**

Department of Pediatrics, All India Institute of Medical Sciences,
New Delhi, India
E-mail: skkabra@hotmail.com

REFERENCES

1. Henry M, Sung L. Supportive care in pediatric oncology: Oncologic emergencies and management of fever and neutropenia. *Pediatr Clin North Am* 2015;62:27-46.
2. World Health Organization. Automated Real-Time Nucleic Acid Amplification Technology for Rapid and Simultaneous Detection of Tuberculosis and Rifampicin Resistance: Xpert MTB/RIF

Assay for the Diagnosis of Pulmonary and Extrapulmonary TB in Adults and Children: Policy Update. Geneva: World Health Organization; 2013. Available from: http://www.apps.who.int/iris/bitstream/10665/112472/1/9789241506335_eng.pdf?ua=1. [Last accessed on 2015 Jul 12].

3. Bandyopadhyay SK, Sarkar N, Ghosh S, Dasgupta S. Tubercular mediastinal lymphadenopathy presenting as superior vena cava syndrome. *J Assoc Physicians India* 2002;50:1194-5.
4. Mínguez C, Roca B, González-Miño C, Simón E. Superior vena cava syndrome during the treatment of pulmonary tuberculosis in an HIV-1 infected patient. *J Infect* 2000;40:187-9.
5. Ohri A, Shah I, Chandane P. Pott's disease presenting as a superior mediastinal mass: A case report. *Int J Biomed Adv Res* 2013;4:146-8.
6. Tuli SM, editor. Tuberculosis of the spine. In: *Tuberculosis of the Skeletal System*. New Delhi: J.P. Brothers; 1991. p. 132-253.
7. Schirmer P, Renault CA, Holodny M. Is spinal tuberculosis contagious? *Int J Infect Dis* 2010;14:e659-66.
8. Sahu JK, Menon RP, Lodha R, Kabra SK. Benign superior mediastinal syndrome due to intrathoracic tuberculosis in a child-association with endobronchial tuberculosis. *Indian J Pediatr* 2010;77:1021-3.
9. Dinç H, Ahmetoglu A, Baykal S, Sari A, Sayil O, Gümele HR. Image-guided percutaneous drainage of tuberculous iliopsoas and spondylodiskitic abscesses: Midterm results. *Radiology* 2002;225:353-8.

This is an open access article distributed under the terms of the Creative Commons Attribution-NonCommercial-ShareAlike 3.0 License, which allows others to remix, tweak, and build upon the work non-commercially, as long as the author is credited and the new creations are licensed under the identical terms.

Access this article online	
Quick Response Code: 	Website: www.lungindia.com
	DOI: 10.4103/0970-2113.213826

How to cite this article: Mandal A, Singh A, Seth R, Kabra SK. Superior mediastinal syndrome secondary to Pott's spine in a child. *Lung India* 2017;34:487-9.