

CASE REPORT

Supermicrosurgical replantation of a small amputated nasal tissue in a child

Richard Tee  & Michael Woodfield

Department of Plastic and Reconstructive Surgery, Waikato Hospital, Pembroke Street, Hamilton 3240, New Zealand

Correspondence

Richard Tee, Waikato Hospital, Pembroke Street, Hamilton 3240, New Zealand.
Tel: +61 4 5666999; Fax: +64 7 8382032;
E-mail: richardteembbs@gmail.com

Funding Information

No sources of funding were declared for this study.

Received: 1 July 2017; Revised: 8 September 2017; Accepted: 19 September 2017

Clinical Case Reports 2017; 5(12): 1961–1965

doi: 10.1002/ccr3.1223

Case Report

An 8-year-old boy was brought to the Emergency Department at tertiary trauma hospital in New Zealand, one evening after a dog bite injury. The avulsed tissue was retrieved by family and kept cool in an artificial ice gel bag prior to being seen by the plastic surgery resident. At the time of review 6 h postinjury, however, it was noted that the artificial ice gel bag had become warm. Intravenous amoxicillin with clavulanic acid was given. Patient was up to date with his immunization schedule.

Gross inspection revealed a defect that included several nasal subunits (partial nasal tip, medial third of his right alar, and the soft triangle, Fig. 1). The contaminated amputated composite tissue measured approximately, $1 \times 1.5 \text{ cm}^2$ was composed of skin, subcutaneous fat, cartilage, and mucosa. As the patient did not fast, the procedure was postponed until 8 a.m. the next day. The avulsed nasal tissue was kept at 4°C overnight. The initial surgical plan was to reapply the amputated part as a composite graft. Risk and benefits of the procedure including future reconstruction were discussed with the mother. The possibility of replantation was brought up but mentioned it would be subjected to the intraoperative findings.

At the time of surgery, both the wound and the graft were gently debrided under $2.5\times$ loupe magnification.

Key Clinical Message

This study reports a case of an 8-year-old boy who suffered from a dog bite injury to the nose. The amputated nasal tissue measured approximately $1.0 \times 1.5 \text{ cm}$ and included part of the tip, alar, and soft triangle subunits. Both ends of an artery of less than 0.5 mm were found, and replantation was performed. Chemical leeching was performed postoperatively. At 5-year follow-up, a good aesthetic result was achieved.

Keywords

Composite graft, dog bite, nasal reconstruction, nose replantation, supermicrosurgery.

During debridement, a pulsating vessel was observed at the junction of the tip and right alar at the wound edge (Fig. 2). The amputated part was carefully positioned within the defect and the mucosal surface repaired. After this, under surgical microscope magnification, an opposing vessel end was found on the amputated tissue where the pulsating vessel was noted. The wound bed end of the vessel was trimmed and irrigated with papaverine and intraluminally with heparinized saline solution until a pulsatile stream of blood was observed. After ascertaining the artery could be repaired without tension, anastomosis was attempted. Four interrupted 11-0 nylon sutures were used in a quadrangular fashion for an end-to-end anastomosis of the artery (Fig. 3). The time taken to perform the microanastomosis was approximately 40 min. At the release of the vessel clamp, the vessel was observed to be patent. The replanted tissue initially became pink, though by the end of the procedure, had a blue hue (Fig. 2), with demonstrable capillary refill. The skin sutures were loosely, but accurately, tacked. During the first 24-h postoperative period, the operating surgeon manually induced bleeding from the wound by applying heparinized saline.

The patient was discharged the next day on oral cephalixin. There was no postoperative infection. At the one-month follow-up appointment, the replanted tissue

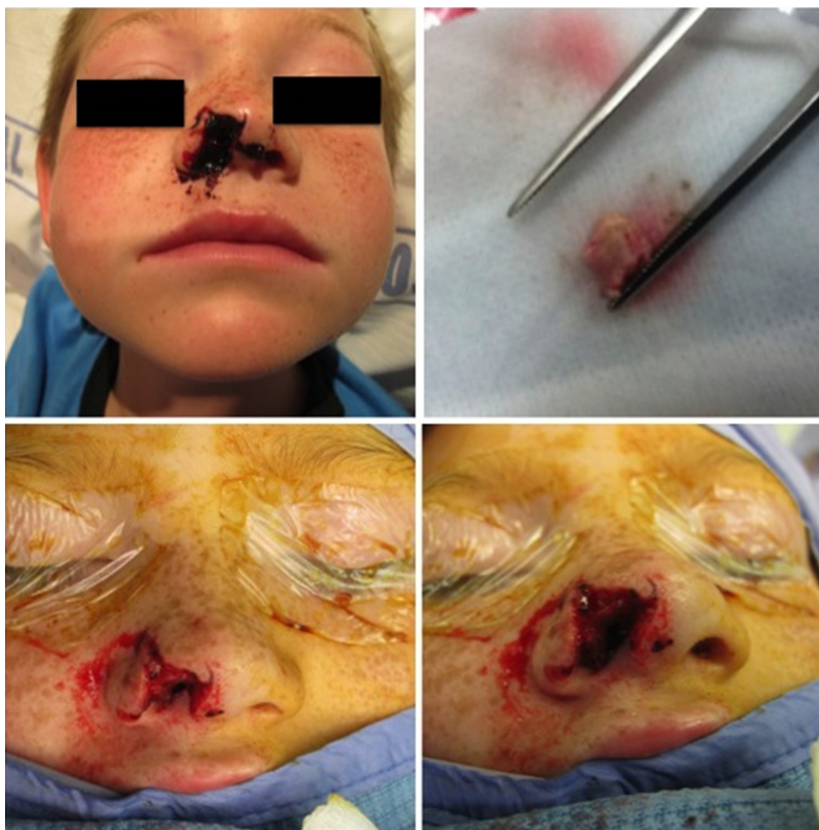

Figure 1. Dog bite amputation of right nasal tip and alar that included several nasal subunits (partial nasal tip, medial third of right alar, and the soft triangle). Top left, amputated nasal tissue. Bottom right and left, intraoperative pictures showing the size of nasal defect.

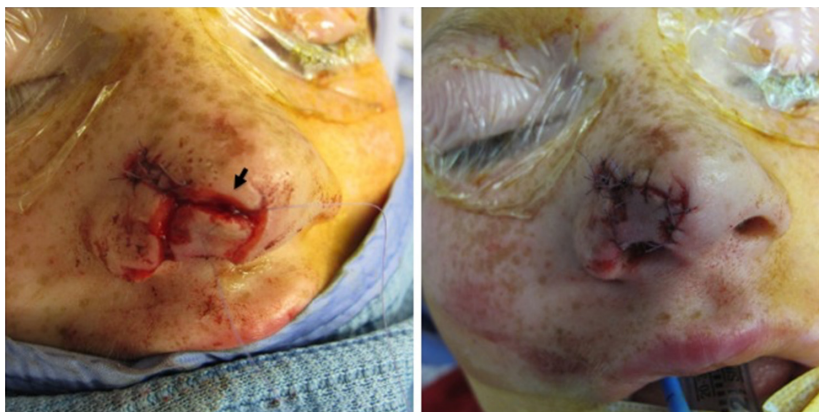

Figure 2. Supermicrosurgery anastomosis of artery only (left, arrow indicates anastomosis site). Right, blueish hue of the replanted tissue at the end of procedure indicating venous congestion.

remained viable (Fig. 4). The outcome was excellent requiring no secondary reconstructive procedure with the last follow-up appointment being 5 years postoperatively (Fig. 5). Patient (13 years old) claimed no one ever noticed the injury on his nose nor is he conscious of it.

Discussion

In this study, we report an artery only nasal replantation of a 1.5 cm² amputated nasal tip/alar tissue using supermicrosurgery technique. A satisfactory aesthetic outcome

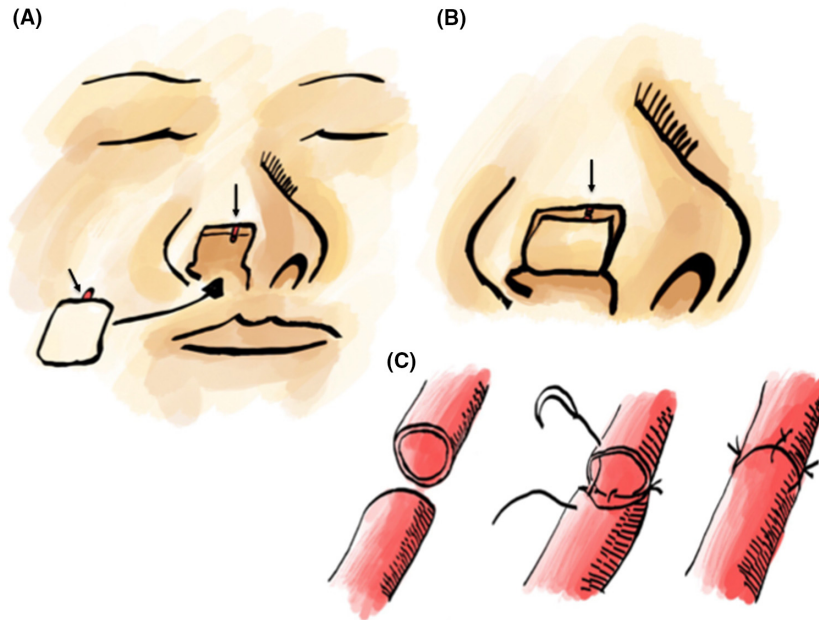


Figure 3. Schematic diagram of replantation: (A) Insetting of amputated nasal tissue (arrows showing both ends of artery); (B) artery ends opposed (arrow); (C) quadrangular anastomosis of artery using 11-0 suture (from left to right).

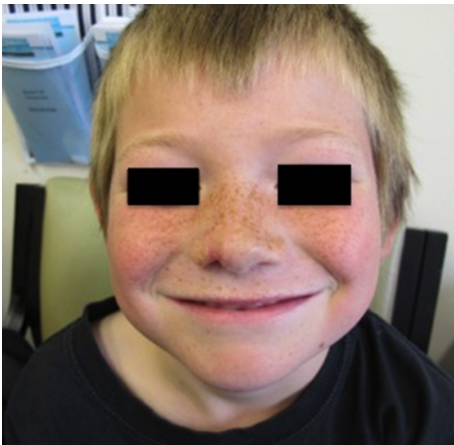

Figure 4. One-month follow-up showed survival of replanted nasal tissue.

was achieved obviating the need for subsequent secondary reconstruction. In this section, we discuss the historical outcomes of composite grafting in traumatic nasal amputation and how advancement in microsurgery challenges the conventional teaching of the size threshold to attempt replantation.

There is a general belief that composite grafting of traumatically amputated nasal tissue has poor outcome [1, 2]; however, related publications are few. A Pubmed search of the keywords “nasal amputation” or “nose amputation” yielded only 22 articles in the English

literature related to either composite grafting [3–10] or microvascular replant [11–25] of amputated nasal segments. In the seven articles related to composite grafting, a total of 12 cases are reported. The largest series was reported by Grabb and Dingman [7] in which five of five cases failed, followed by Miller et al. in which three of three cases failed [8]. All cases required secondary reconstruction. The remaining studies were isolated reports with varying degree of success using hyperbaric oxygen therapy [3, 9] or cooling therapy [6, 10]. These outcomes are interesting, considering composite grafting was conventionally accepted for small traumatic nasal amputation parts.

It is well accepted that successful replantation of the native amputated tissue will yield the best outcome, and therefore should be attempted whenever possible [26]. Most successful nasal replantations were reported in the last two decades. A significant portion of these reported cases were related to human [14, 15, 27] or dog bites [12, 15, 20, 21], with avulsion of the vessels, crushing of the amputated parts, and contamination, all of which are predictors of poor outcome. Excellent aesthetic results achieved in these cases [12, 20] demonstrate that suboptimal conditions should not preclude an attempt at replantation.

The size threshold for free composite graft figure is more arbitrary than scientific. Some [1] even suggested no part of the graft should be 0.5 cm from the viable cut edge of the wound. This recommendation may be in the

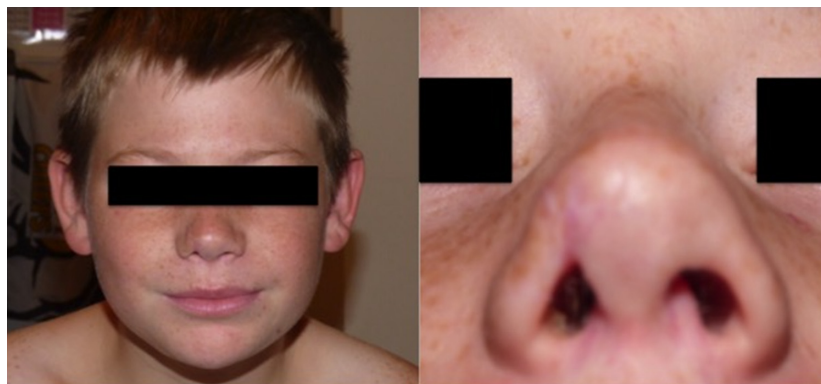


Figure 5. Five-year follow-up of the replanted nasal tissue with no secondary revision since the replantation. Patient is 13 years old. Despite some mild asymmetry from the nasal view, patient reported it had not been noticed by anyone.

context of reconstructing a defect created in elective procedures. As the technique of supermicrosurgery has shown to be feasible, the spectrum of replantable amputated parts has expanded [28]. This challenges the conventional threshold for composite grafting in traumatic nasal amputation [19, 20]. Kim et al. [19] reported a successful case of nasal replantation of a $2.5 \times 2.6 \text{ cm}^2$ amputated segment, anastomosing an artery and vein of around 0.6 mm diameter with six interrupted 11-0 sutures. While the size of our vessel was not exactly measured, only four interrupted 11-0 sutures were required, indicating a comparably smaller vessel.

We do not recommend attempt to replant all small nasal amputation part at all costs. We would, however, like to use this case to illustrate, when opportunity arises, supermicrosurgical replantation may be a better option to ensure survival of amputated part. This may only require a careful survey around the wound edge for pulsatile vessel. The effort is certainly justified, as the resultant defect, should the composite graft failed, would have required staged forehead flap reconstruction. Furthermore, the defect in this case is known to be very unfavorable for the survival of composite grafts. Chandawarkar et al. [29] in their experience with auricular composite grafting stated that at the columellar-lobular junction, alar rim and the soft triangle, partial composite graft loss is a rule rather than the exception.

In Kim et al.'s successful case, exploration and anastomosis of one artery and one vein of approximately 0.6 mm took a total operating time of under 3 h. The anesthetic time for this case was <2 h, illustrating that replantation can be performed within a reasonable duration [19]. Many similar cases reported in the literature have consistently reported success in replanting nasal subunits with only arterial repair [11, 12, 14, 15, 17–21, 24, 25], suggesting the need to survey for available artery only and hence obviating the need for time spent looking for vein.

Finally, we did not apply medicinal leeches in this case. For a pediatric patient, medicinal leeching on area such as the nose requires sedation and intubation. We do not feel it was justified here. Furthermore, leeches carried the risk of infection not only from its commensal organisms but also prion transmission. As for the duration of chemical leeching, the authors feel that if we were to attempt another similar replantation, we would continue with chemical leeching longer. However, the replanted nasal tissue survived in this case. Even if venous congestion was an issue in this case, in the face of various suboptimal conditions, the nourishing of the amputated part through the anastomosis probably would have had significant impact on its survival. Interestingly, in experimental animal studies, Nakajima observed vessels to have grown into the periphery of the skin flap by day 2 postoperation [30]. Ayurek et al. in a 2 cm^2 alar replant observed resolution of venous congestion by day 3 [11]. It could be that for a small volume facial tissue replant, shorter duration is required for inosculation.

In conclusion, we propose that in selected cases, rigid size threshold for composite graft should be put aside. If artery is found and flow is healthy, microsurgical replantation should be attempted. The success of such attempts avoids secondary staged reconstruction.

Authorship

RT: performed surgery, first follow-up, drafting of paper and revision, illustration. MW: oversee management of patient, follow-ups, helped in manuscript preparation, and revision of manuscript.

Conflict of Interest

None declared.

References

- Davis PaS, O. H. 1985. Soft tissue injuries of the face. P. 1088 in J. L. I. Rowe NaW, ed. Maxillofacial injuries. Churchill Livingstone, New York.
- Mueller, R. 2012. Facial trauma: soft tissue injuries. PP 23–48 in J. E. Rodriguez EaL, ed. Plastic surgery. Vol. 3: Craniofacial, Head and Neck Surgery, Paediatrics Plastic Surgery. Elsevier Health Sciences, London, New York, Oxford, St Louis, Sydney, Toronto.
- Cantarella, G., R. F. Mazzola, and D. Pagani. 2005. The fate of an amputated nose after replantation. *Am. J. Otolaryngol.* 26:344–347.
- Cort, D. F. 1973. Nasal tip replantation. Case report. *Plast. Reconstr. Surg.* 52:194–196.
- Flanary, C. J., and J. E. Clemons. 1994. Successful replantation of an amputated nose. *Otolaryngol. Head Neck Surg.* 111(3 Pt 1):309–311.
- Fuleihan, N. S., M. A. Natout, R. C. Webster, N. A. Hariri, M. A. Samara, and R. C. Smith. 1987. Successful replantation of amputated nose and auricle. *Otolaryngol. Head Neck Surg.* 97:18–23.
- Grabb, W. C., and R. O. Dingman. 1972. The fate of amputated tissues of the head and neck following replacement. *Plast. Reconstr. Surg.* 49:28–32.
- Miller, P. J., C. Hertler, G. Alexiades, and T. A. Cook. 1998. Replantation of the amputated nose. *Arch. Otolaryngol. Head Neck Surg.* 124:907–910.
- Nichter, L. S., D. T. Morwood, G. S. Williams, and R. J. Spence. 1991. Expanding the limits of composite grafting: a case report of successful nose replantation assisted by hyperbaric oxygen therapy. *Plast. Reconstr. Surg.* 87:337–340.
- Hirase, Y. 1993. Postoperative cooling enhances composite graft survival in nasal-alar and fingertip reconstruction. *Br. J. Plast. Surg.* 46:707–711.
- Akyurek, M., T. Safak, and A. Kecik. 2004. Microsurgical revascularization of almost totally amputated alar wing of the nose. *Ann. Plast. Surg.* 53:181–184.
- Flores, R. L., N. Bastidas, and R. D. Galiano. 2007. Successful replantation of an amputated nose after dog bite injury. *Otolaryngol. Head Neck Surg.* 136:326–327.
- Hammond, D. C., C. L. Bouwense, W. T. Hankins, G. S. Maxwell-Davis, J. Furdyna, and P. A. Capraro. 2000. Microsurgical replantation of the amputated nose. *Plast. Reconstr. Surg.* 105:2133–2136; quiz 2137; discussion 2138–.
- Hussain, G., S. Thomson, and V. Zielinski. 1997. Nasal amputation due to human bite: microsurgical replantation. *Aust. N. Z. J. Surg.* 67:382–384.
- James, N. J. 1976. Survival of large replanted segment of upper lip and nose. Case report. *Plast. Reconstr. Surg.* 58:623–625.
- Jeng, S. F., F. C. Wei, and P. K. Chen. 1991. Successful replantation of an amputated nasal tip by microvascular anastomosis. *Plast. Reconstr. Surg.* 87:1118–1120.
- Jeng, S. F., F. C. Wei, and M. S. Noordhoff. 1994. Replantation of amputated facial tissues with microvascular anastomosis. *Microsurgery* 15:327–333.
- Kayikcioglu, A., S. Karamursel, and A. Kecik. 2001. Replantation of nearly total nose amputation without venous anastomosis. *Plast. Reconstr. Surg.* 108:702–704.
- Kim, S., H. Jeong, T. H. Choi, and J. S. Kim. 2010. Successful re-plantation of an amputated nasal segment by supermicrosurgery: a case report and review of the literature. *J. Plast. Reconstr. Aesthet. Surg.* 63:e380–e383.
- Stillaert, F. B., N. Roche, A. Zeltzer, and S. Monstrey. 2012. Artery only microanastomosis in nose replantation: a report of two cases. *J. Plast. Reconstr. Aesthet. Surg.* 65:513–516.
- Tajima, S., K. Ueda, and Y. Tanaka. 1989. Successful replantation of a bitten-off nose by microvascular anastomosis. *Microsurgery* 10:5–7.
- Yao, J. M., S. Yan, J. H. Xu, J. B. Li, and P. Ye. 1998. Replantation of amputated nose by microvascular anastomosis. *Plast. Reconstr. Surg.* 102:171–173.
- Okumus, A., S. Vasfi Kuvat, and F. Kabakas. 2010. Successful replantation of an amputated nose after occupational injury. *J. Craniofac. Surg.* 21:289–290.
- Sanchez-Olaso, A. 1993. Replantation of an amputated nasal tip with open venous drainage. *Microsurgery* 14:380–383.
- Niazi, Z., T. C. Lee, P. Eadie, and D. Lawlor. 1990. Successful replantation of nose by microsurgical technique, and review of literature. *Br. J. Plast. Surg.* 43:617–620.
- Pribaz, J. J. 2000. Microsurgical Replantation of the Amputated Nose. *Plast. Reconstr. Surg.* 105:2138–2139.
- Sun, W., Z. Wang, S. Qiu, and S. Li. 2010. Successful microsurgical replantation of the amputated nose. *Plast. Reconstr. Surg.* 126:74e–76e.
- Koshima, I., T. Yamamoto, M. Narushima, M. Mihara, and T. Iida. 2010. Perforator flaps and supermicrosurgery. *Clin. Plast. Surg.* 37:683–689, vii–iii.
- Chandawarkar, R. Y., A. L. Cervino, and M. D. Wells. 2003. Reconstruction of nasal defects using modified composite grafts. *Br. J. Plast. Surg.* 56:26–32.
- Nakajima, T. 1978. How soon do venous drainage channels develop at the periphery of a free flap? A study in rats. *Br. J. Plast. Surg.* 31:300–308.