



Uterine artery embolization combined with ultrasound-guided dilation and curettage for the treatment of cesarean scar pregnancy: Efficacy and 5–8-year follow-up study

Zhuxin Gu^a, Pengfei Jia^a, Ziyang Gao^b, Weiwei Gu^a, Hui Zhao^a, Suming Zhao^{a,*}

^a Department of Interventional Radiology, affiliated Hospital of Nantong University, Nantong, 226000, Jiangsu, China

^b Department of Digital Subtraction Angiography, affiliated Hospital of Nantong University, Nantong, 226000, Jiangsu, China

ARTICLE INFO

Keywords:

Complications
Infertility
Ovarian
Scar pregnancy

ABSTRACT

Objective: To evaluate the efficacy and safety of uterine artery embolization (UAE) combined with dilation and curettage (D&C) using ultrasound as a treatment for cesarean scar pregnancy (CSP) and assess its effect on ovarian and reproductive function.

Methods: A total of 54 patients with uterine CSP between January 2011 and December 2015 were included in this retrospective study. The patients were treated with UAE combined with D&C using ultrasound for the treatment of CSP and followed up for 5–8 years. Their medical records, medical histories, clinical manifestations, treatment courses, and treatment results were analyzed.

Results: The 54 patients were initially treated without severe complications. β -Human chorionic gonadotropin (β -hCG) normalization took 36.11 ± 10.73 days (range, 25–84 days), length of hospitalization was 6.6 ± 1.5 days (range, 4–10 days), and total blood loss was 18.48 ± 8.41 mL (range, 5–33 mL). All patients resumed normal menstruation after 33.48 ± 8.71 days (range, 26–70 days). At the 5–8-year follow-up after UAE combined with D&C by ultrasound for the treatment of uterine CSP, the menstrual volume in 32 (59.3%) patients decreased versus before the operation. Compared with pretreatment, the menstrual cycle was prolonged in two (3.7%) cases, shortened in 10 (18.5%) cases, irregular in one (1.9%) case, and unchanged in 39 (72.2%) cases. Three patients conceived naturally and successfully gave birth to healthy children. Seven (12.96%) patients with accidental natural pregnancies chose induced abortion with no significant change in their sex lives.

Conclusion: UAE combined with D&C using ultrasound for the treatment of uterine CSP is safe and effective and may not affect the fertility of patients aged <40 years. However, menstrual volume may be reduced in some patients.

1. Introduction

Cesarean scar pregnancy (CSP) is a type of ectopic pregnancy that occurs in the uterine scar after cesarean section (CS). Studies have shown that its incidence ranges from 1/1800 to 1/2200 in all pregnancies¹ with an increase in the numbers of cesarean deliveries and patients with CSP.² Without timely treatment, CSP can cause hemorrhage, uterine rupture or excision, loss of fertility, or even death.³ Treatment with uterine artery embolization (UAE) has achieved a good short-term clinical effect,^{4–6} but whether it affects the ovarian function and fertility of patients in the long term remains unknown. Here we evaluated the long-term efficacy of UAE combined with dilation and curettage in the treatment of uterine CSP and assessed whether it affects ovarian and reproductive function to provide

a basis for the choice of clinical treatment and reference.

2. Materials and methods

A total of 54 patients diagnosed with CSP and treated at the Department of Interventional Radiology, Affiliated Hospital of Nantong University, between January 2011 and December 2015 were followed up for 5–8 years. This study was approved by the Institutional Ethics Committee.

2.1. Diagnosis

The clinical manifestation of CSP was defined as a history of CS. One

* Corresponding author.

E-mail address: ruonanxu1992@163.com (S. Zhao).

<https://doi.org/10.1016/j.jimed.2022.03.006>

Received 6 December 2021; Received in revised form 2 March 2022; Accepted 10 March 2022

Available online 18 March 2022

2096-3602/© 2022 Shanghai Journal of Interventional Radiology Press. Publishing services by Elsevier B.V. on behalf of KeAi Communications Co. Ltd. This is an open access article under the CC BY-NC-ND license (<http://creativecommons.org/licenses/by-nc-nd/4.0/>).

clinical manifestation of pregnancy is irregular vaginal bleeding. In all patients, transvaginal ultrasonography confirmed that the pregnancy capsule was located at the incision in the isthmus of the anterior wall of the uterus.

2.2. Treatments

The interventional treatment steps were as follows: operation under digital subtraction angiography (DSA) guidance under local anesthesia via femoral artery puncture into a 5F vascular sheath; placement of a 5F Robert catheter or catheter combined with a microcatheter in bilateral iliac artery angiography in a clear direction; and blood supply of an open uterine artery under DSA perspective with a diameter of 560–710 μm of gelatin sponge particles to slowly embolize bilateral uterine arteries until the end of the uterine artery was not visible (Fig. 1).

2.3. Postoperative observation and management

Vaginal bleeding and the discharge of necrotic tissue were observed after the interventional surgery. Ultrasound-guided curettage surgery was performed within 72 h after UAE, and the tissue obtained after curettage was sent to the pathology laboratory (Fig. 2).

2.4. Follow-up

Each patient was followed up by telephone annually to assess changes in menstrual volume and cycle after versus before the interventional surgery and check a second pregnancy, childbirth, or induced abortion had occurred and whether there were post-surgery side effects such as postoperative hot flashes, night sweats, or mood or sexual desire changes. All patients were followed for 5–8 years after discharge from the hospital.

2.5. Statistical analysis

Descriptive analyses were performed in the study.

3. Results

The clinical features of the 54 patients (31.4 ± 3.9 years; range, 24–40 years) treated with UAE followed by dilation and curettage are presented in Table 1. The gestational age was 51.91 ± 21.78 days (range, 30–180 days), gravidity was 2.72 ± 1.05 (range, 1–5), and interval since the last CS was 2.79 ± 0.38 years (range, 1–15 years). UAE was successfully performed in all 54 patients with CSP, and ultrasound-guided hysterectomy was performed within 2 days postoperative. $\beta\text{-HCG}$

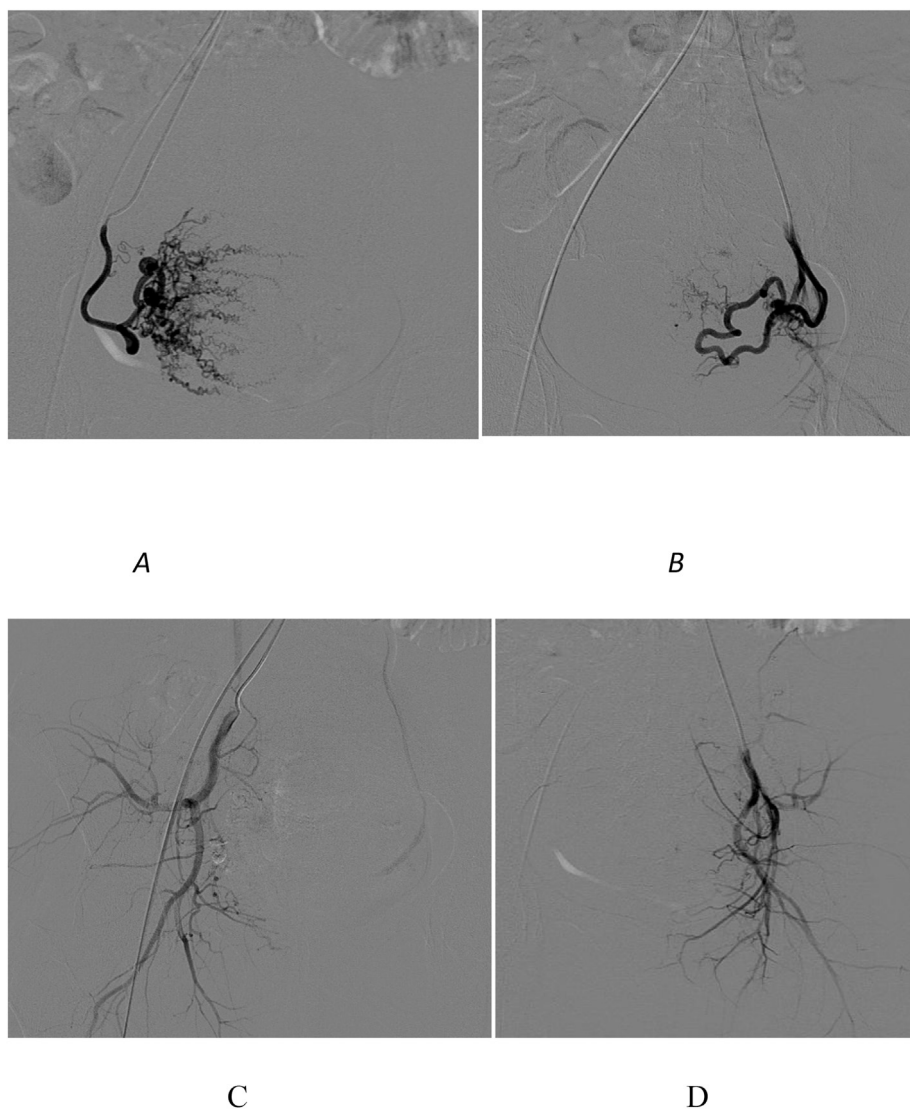


Fig. 1. A and B: Bilateral uterine artery angiography showed distortion and thickening of the uterine artery, which was equivalent to thickening of local staining of blood vessels in the pregnancy capsule, and delayed emptying of contrast agent. C and D: Bilateral artery embolization after uterine artery embolization.

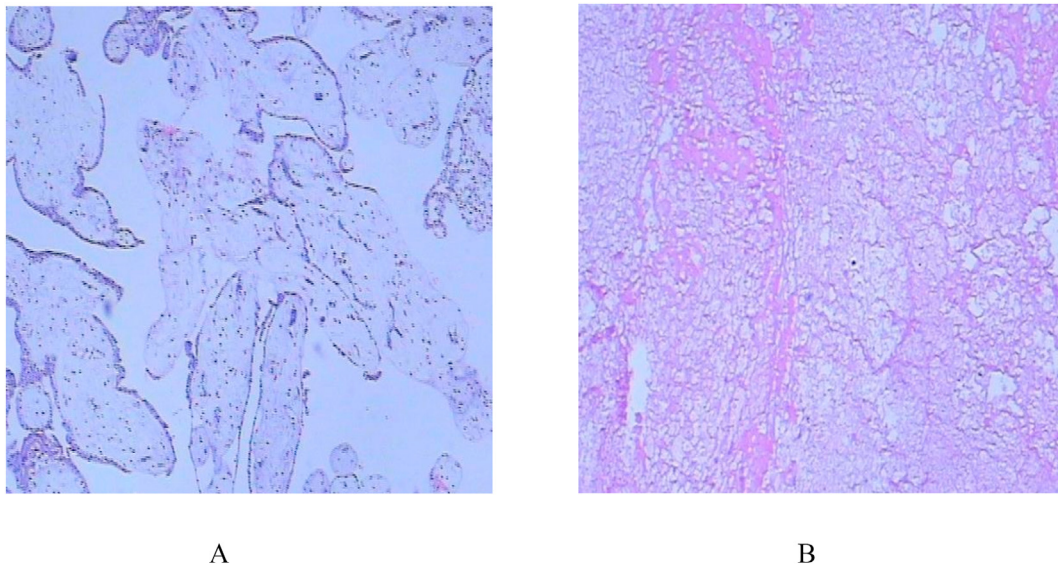


Fig. 2. Comparison of pathological images. A: Normal uterine villus tissue. B: Pathological image of necrotic tissue after uterine artery embolization combined with ultrasound-guided curettage.

Table 1
Clinical features of patients treated with UAE followed by D&C (n = 54).

Characteristic	Mean ± SD
Mean age (years)	31.4 ± 3.9 (range 24–40)
Gravidity (number)	2.72 ± 1.05 (range 1–5)
Gestational age (days)	51.91 ± 21.78 (range 30–180)
<40	9
40–70	39
>70	6
Time interval since last CS (years)	2.79 ± 0.38 (range 1–15)
Serum level of b-hCG before treatment	26079.7 ± 3549.0 (range 108.55–113755.0)
<5000	11
5000–10000	6
>10000	37

normalization took 36.11 ± 10.73 days (range, 25–84 days), length of hospitalization was 6.6 ± 1.5 days (range, 4–10 days), and total blood loss was 18.48 ± 8.41 mL (range, 5–33 mL). All patients resumed normal menstruation after 33.48 ± 8.71 days (range, 26–70 days) (Table 2).

During the follow-up of 5–8 years, 32 (59.3%) patients reported a decrease in menstrual volume, 4 (7.4%) reported a decrease in menstrual volume, 28 (51.9%) reported a slight decrease in menstrual volume, and 20 (37.0%) reported no change in menstrual volume. Dark menstrual fluid was observed in 22 patients (40.7%). The menstrual cycle was lengthened in two patients (3.7%), shortened in 10 (18.5%), irregular in 1 (1.9%), and unchanged in 39 (72.2%). Leucorrhoea increased in two patients, dysmenorrhoea increased in 2 (3.7%), and uterine fibroids increased in 2 (3.7%). Three patients conceived naturally and had successful subsequent deliveries of healthy children. Seven (12.96%) women underwent induced abortions due to unwanted pregnancies. There were two cases (3.7%) of amenorrhoea: one after intrauterine device (IUD) implantation and one after extensive hysterectomy due to endometrial cancer. In addition, hot flashes, night sweats, mood changes,

Table 2
Clinical outcomes after treatment of CSP.

Characteristic	Mean ± SD
Serum level of β-hCG normalization (days)	36.11 ± 10.73 (range 25–84)
Hospitalization (days)	6.6 ± 1.5 (range 4–10)
Total blood loss (ml)	18.48 ± 8.41 (range 5–33)
Time for resumption of menstruation (days)	33.48 ± 8.71 (range 26–70)

and sexual desire did not significantly change compared to the preoperative levels (Table 3).

4. Discussion

The uterine CSP is implanted in the CS uterine incision scar and located completely outside the uterine cavity. The uterus is surrounded by the myometrium and fibrous scar tissue that is unique to ectopic pregnancy. Bleeding easily occurs in life-threatening cases because of scar tissue and placental implants, which can cause uterine rupture as reported in the literature.⁷ The current CSP classification is based on the direction of gestational cystic growth and myometrial thickening between the pregnancy sac and the posterior wall of the bladder.⁸ This study enrolled 54 patients, including four with early type I CSP, 40 with early type II CSP, 8 with early type III CSP, and two in the middle of pregnancy.

Table 3
Follow-up.

Variable	Cases (N = 54)	%
Menstrual cycle (n)		
Prolonged	2	3.7
Shortened	10	18.5
Irregular	1	1.9
Unchanged	39	72.2
Total	52	96.3
Menstrual volume		
No change	20	37
Decrease	32	59.3
Increase	0	0
Total	52	96.3
Dysmenorrhoea		
No change	49	90.7
Emerging	2	3.7
Exacerbation	1	1.9
Total	52	96.3
Menstrual color		
Kermesinus	22	40.7
No change	30	55.6
Total	52	96.3
Fertility after treatment (n)	3	5.6
Abortion	7	12.96
Amenorrhoea	2	3.7
Leucorrhoea		
Decrease	0	0
Increase	2	3.7
No change	52	96.3

CSP should be treated as soon as possible after diagnosis. The treatment method mainly depends on gestational age, patients' general condition, blood β -hCG level, embryonic sac size, and blood loss at that time point. The principle of CSP treatment is to kill trophoblasts, remove embryonic tissue, prevent massive bleeding, retain reproductive and endocrine function, and delay or maintain conservative treatment, which may lead to uterine rupture or massive bleeding and even endanger the patient's life. Various conservative, surgical, and interventional treatments are considered for CSP; however, each has its own advantages and disadvantages, and a unified optimal treatment method is lacking.

Several studies have reported the effectiveness of UAE combined with methotrexate in the treatment of uterine scar pregnancy.^{9,10} However, some studies have shown that while achieving good clinical efficacy, UAE also has some complications such as premature ovarian failure and amenorrhea caused by endometrial atrophy (1.23%).¹¹ A total of 54 patients with uterine scarring were successfully treated with UAE combined with ultrasound-guided hysterectomy, and they were followed up by phone for 5–8 years. A total of 32 patients (59.3%) reported decreased menstruation, among whom 28 (51.9%) reported a mild decrease and 4 (7.4%) reported a significant decrease, while 20 patients (37.0%) reported no change in menstruation. After UAE treatment, part of the blood in the ovarian artery might supply the ischemic uterus via collateral circulation, thus exacerbating ovarian ischemia,¹² which may lead to decreased menstrual volume. For example, if endometrial injury, embolization transition, and postoperative infection occur after UAE, patients may have irregular menstrual cycles, shortened menstrual periods, decreased menstrual volume, or amenorrhea postoperatively.¹³

In our center, UAE is performed with special attention to avoid excessive embolization. After moderate embolization of the uterine artery, uterine curettage was performed under ultrasonographic guidance. Non-targeted embolization of the ovaries and endometrium may be a potential cause of infertility after UAE, which can lead to decreased menstruation, premature ovarian failure, and premature menopause.¹⁴ Yan Ma et al. reported gelatin sponge particle embolization of the uterine arteries and followed patients for 4 years; there was one case (8.3%) of decreased menstrual quantity described as a volume decrease of less than one-third as abnormal.¹⁵ After UAE, menstrual volume was reduced by 71.4% (35/49), and menstrual duration was shortened by 28.6% (14/49); the cause of hypomenorrhea may be endometrial necrosis or intrauterine adhesion presenting after UAE.¹⁶

In this center, after UAE, menstrual cycle shortening occurred in 10 cases (18.5%), menstrual cycle extension occurred in two cases (3.7%), no changes occurred in 39 cases (72.2%), and irregularities occurred in one case (1.9%). Chrisman et al.¹⁷ reported that ovarian failure was related to age and that decreased menstrual volume was more likely to occur in patients aged >45 years. Data from randomized trials and prospective case series suggested that treatment for ovarian function may be required after UAE, but in most women over 45 years of age, there is little evidence that its effects may induce amenorrhea.^{18,19} This study included 54 patients younger than 40 years of age, and 59.3% of them reported reduced menstrual cycles. Further studies are required to determine whether age is associated with the decreased menstrual flow after UAE.

Kim²⁰ reported that ovarian reserve was affected by UAE in premenopausal women. Younger ovaries (according to ovarian age) exhibit a greater capacity for recovery after ovarian damage. The results of this study showed that all patients with CSP retained their uteri after UAE treatment. Follow-up showed that UAE did not affect fertility. UAE does not affect ovarian reserve in women aged <40 years as evidenced by the lack of significant changes in anti-Müllerian hormone levels after embolization. The findings presented by Bruce McLucas et al.^{21,22} indicate that UAE is more beneficial than traditional myomectomy in women desiring preserved fertility. Women of reproductive age and those with uterine fibroids should consider UAE. In addition, seven patients with accidental natural pregnancy chose artificial abortion; of them, two (3.7%) experienced uterine scar pregnancy again. The rate of repeated CSP is reportedly 15.6%.²³ Among the 54 patients studied here,

amenorrhea occurred in two (3.7%), including one after IUD implantation and another after extensive hysterectomy for endometrial cancer.

5. Conclusion

Through this 5-8-year follow-up study, UAE combined with uterine curettage guided by ultrasound for the treatment of CSP in patients younger than 40 years was safe and effective. It did not affect reproductive function, but in some patients, menstrual quantity decreased. UAE can cause postoperative early menopause; hence, further long-term follow-up and mechanisms underlying the decrease in menstrual quantity require exploration in future studies.

Ethical approval

All procedures involving human participants were performed in accordance with the ethical standards of the institutional and/or national research committee and the 1964 Helsinki Declaration and its later amendments or comparable ethical standards.

Informed consent

Informed consent was obtained from all individual participants included in the study.

Declaration of competing interest

The authors declare no conflict of interests related to this article.

Acknowledgement

Zhuxin Gu and Pengfei Jia reviewed the literature and wrote the manuscript. Ziyang Gao performed statistical analysis and wrote the manuscript. Weiwei Gu and Xiaohu Yang collected the data about the patients and wrote the manuscript. Suming Zhao collected the data about the patients. Hui Zhao performed the surgical procedures. Guobiao Huang followed up the cases and collected the data. We thank LetPub (www.letpub.com) for its linguistic assistance during the preparation of this manuscript.

References

- Jacquemyn Y, Kerremans M, Op de Beeck B, et al. Caesarean scar pregnancy. *BMJ Case Rep.* 2012;2012, bcr1120115163.
- Peng KW, Lei Z, Xiao TH, et al. First trimester caesarean scar ectopic pregnancy evaluation using MRI. *Clin Radiol.* 2014;69:123–129.
- Peng M, Li L, Ding Y, et al. Exploration of the successful treatment algorithms used in 23 cases of early live caesarean scar pregnancy. *Gynecol Obstet Invest.* 2015;79:139–144.
- Liu G, Wu J, Cao J, et al. Comparison of three treatment strategies for caesarean scar pregnancy. *Arch Gynecol Obstet.* 2017;296:383–389.
- Yin X, Su S, Dong B, et al. Angiographic uterine artery chemoembolization followed by vacuum aspiration: an efficient and safe treatment for managing complicated caesarean scar pregnancy. *Arch Gynecol Obstet.* 2012;285:1313–1318.
- Liu G, Wu J, Cao J, et al. Comparison of three treatment strategies for caesarean scar pregnancy. *Arch Gynecol Obstet.* 2017;296:383–389.
- Wang LL, Chen JY, Yang HX, et al. [Correlation between uterine scar condition and uterine rupture for pregnancy women after previous caesarean section]. *Zhonghua Fu Chan Ke Za Zhi.* 2019;54:375–380. Chinese.
- Gonzalez N, Tulandi T. Caesarean scar pregnancy: a systematic review. *J Minim Invasive Gynecol.* 2017;24:731–738.
- Feng Y, Chen S, Li C, et al. Curettage after uterine artery embolization combined with methotrexate treatment for caesarean scar pregnancy. *Exp Ther Med.* 2016;12:1469–1475.
- Kohi MP, Spies JB. Updates on uterine artery embolization. *Semin Intervent Radiol.* 2018;35:48–55.
- Serres-Cousine O, Kuijper FM, Curis E, et al. Clinical investigation of fertility after uterine artery embolization. *Am J Obstet Gynecol.* 2021;225:403.e1–403.e22.
- Kim HS, Tsai J, Lee JM, et al. Effects of utero-ovarian anastomoses on basal follicle-stimulating hormone level change after uterine artery embolization with tris-acryl gelatin microspheres. *J Vasc Interv Radiol.* 2006;17:965–971.

13. Jurkovic D, Hillaby K, Woelfer B, et al. First-trimester diagnosis and management of pregnancies implanted into the lower uterine segment Cesarean section scar. *Ultrasound Obstet Gynecol.* 2003;21:220–227.
14. Mohan PP, Hamblin MH, Vogelzang RL. Uterine artery embolization and its effect on fertility. *J Vasc Interv Radiol.* 2013;24:925–930.
15. Ma Y, Yang C, Shao X. Efficacy comparison of transcatheter arterial embolization with gelatin sponge and polyvinyl alcohol particles for the management of cesarean scar pregnancy and follow-up study. *J Obstet Gynaecol Res.* 2017;43:682–688.
16. Chen H, Zhou J, Wang H, et al. The treatment of cesarean scar pregnancy with uterine artery embolization and curettage as compared to transvaginal hysterotomy. *Eur J Obstet Gynecol Reprod Biol.* 2017;214:44–49.
17. Chrisman HB, Saker MB, Ryu RK, et al. The impact of uterine fibroid embolization on resumption of menses and ovarian function. *J Vasc Interv Radiol.* 2000;11:699–703.
18. Kaump GR, Spies JB. The impact of uterine artery embolization on ovarian function. *J Vasc Interv Radiol.* 2013;24:459–467.
19. Kaump GR, Spies JB. The impact of uterine artery embolization on ovarian function. *J Vasc Interv Radiol.* 2013;24:459–467.
20. Kim CW, Shim HS, Jang H, et al. The effects of uterine artery embolization on ovarian reserve. *Eur J Obstet Gynecol Reprod Biol.* 2016;206:172–176.
21. McLucas B, Voorhees 3rd WD, Snyder SA. Anti-Müllerian hormone levels before and after uterine artery embolization. *Minim Invasive Ther Allied Technol.* 2018;27:186–190.
22. McLucas B, Voorhees 3rd WD, Elliott S. Fertility after uterine artery embolization: a review. *Minim Invasive Ther Allied Technol.* 2016;25:1–7.
23. Wang Q, Peng HL, He L, et al. Reproductive outcomes after previous cesarean scar pregnancy: follow up of 189 women. *Taiwan J Obstet Gynecol.* 2015;54:551–553.