



Contents lists available at ScienceDirect

## International Journal of Surgery Case Reports

journal homepage: [www.casereports.com](http://www.casereports.com)

# Aldosterone deficiency after unilateral adrenalectomy for Conn's syndrome: a case report and literature review

Ekua Yorke<sup>a</sup>, Sara Stafford<sup>b</sup>, Daniel Holmes<sup>c</sup>, Sachiv Sheth<sup>c</sup>, Adrienne Melck<sup>a,\*</sup><sup>a</sup> Department of Surgery, St. Paul's Hospital, Vancouver, British Columbia, Canada<sup>b</sup> Department of Endocrinology, Surrey Memorial Hospital, Surrey, British Columbia, Canada<sup>c</sup> Department of Pathology and Laboratory Medicine, St. Paul's Hospital, Vancouver, British Columbia, Canada

## ARTICLE INFO

## Article history:

Received 29 July 2014

Received in revised form

30 December 2014

Accepted 3 January 2015

Available online 10 January 2015

## Keywords:

Aldosterone

Adrenalectomy

Hypertension

Conn's

Hypokalemia

## ABSTRACT

**INTRODUCTION:** Approximately 35% of cases of Conn's syndrome (primary aldosteronism) result from a solitary functioning adrenal adenoma, and these patients are best managed by adrenalectomy. Postoperative hypoaldosteronism after unilateral adrenalectomy is uncommon.

**CASE PRESENTATION:** We present a case and literature review of hypoaldosteronism after unilateral adrenalectomy for Conn's syndrome, which demonstrates the insidious and sometimes delayed presentation.

**DISCUSSION:** In this clinical case we summarize the previously published cases of post-adrenalectomy hypoaldosteronism based on a PUBMED and EBSCOhost search of all peer-reviewed publications (original articles and reviews) on this topic. A few cases of aldosterone insufficiency post-adrenalectomy for Conn's syndrome were identified. The etiological factors for prolonged selective suppression of aldosterone secretion after unilateral adrenalectomy remain unclear.

**CONCLUSION:** It is important to be aware of the risk of postoperative hypoaldosteronism in this patient population. Close postoperative follow-up is necessary and strongly recommended, especially in patients with certain risk factors. Patients may need mineralocorticoid supplementation during this period.

© 2015 The Authors. Published by Elsevier Ltd. on behalf of Surgical Associates Ltd. This is an open access article under the CC BY-NC-ND license (<http://creativecommons.org/licenses/by-nc-nd/4.0/>).

## 1. Introduction

Primary aldosteronism (PA), or Conn's syndrome, results from unregulated release of excess aldosterone from one or both adrenal glands. Aldosterone-producing adenoma and bilateral idiopathic hyperaldosteronism are the two most common subtypes of PA. A much less common form, unilateral hyperplasia, is caused by micronodular or macronodular hyperplasia of the zona glomerulosa of predominantly one adrenal gland [1]. Between 30 and 35% of PA cases result from a solitary functioning adrenal adenoma [1] and these patients are best managed by adrenalectomy. Postoperatively, some patients may experience transient hypoaldosteronism requiring mineralocorticoid replacement, but this is an uncommon scenario. Here, we present a case report and literature review of hypoaldosteronism after unilateral adrenalectomy for PA.

## 2. Presentation of case

A 66-year-old female was referred for surgical management of her PA in January 2012. The patient presented with a

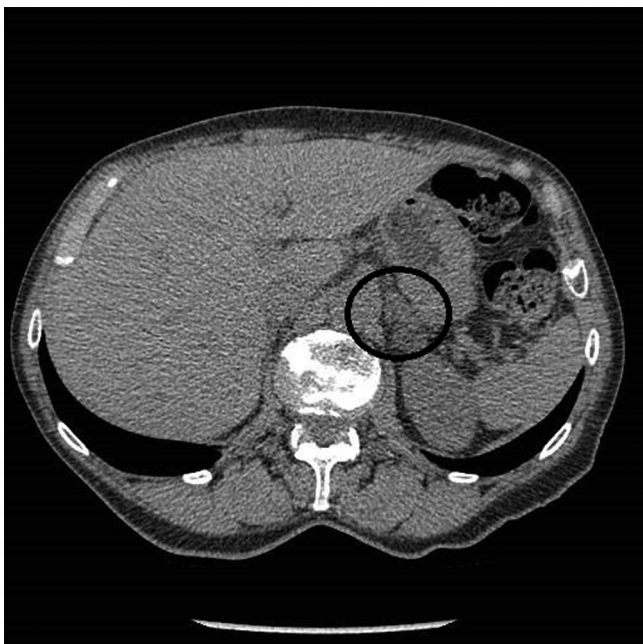
13-year history of hypertension and hypokalemia. On presentation, she was on nifedipine and triamterene/hydrochlorothiazide, but her blood pressure remained elevated at 134/84 mmHg. On June 29th 2011 she had a serum aldosterone level of 688 pmol/L (normal 70–660) which was associated with a suppressed plasma renin level of <0.05 ng/L/s (normal 0.05–0.55) yielding an elevated aldosterone/renin ratio of >13,760 (normal <2500). Her plasma potassium at this time was 3.9 mmol/L (normal 3.5–5.0 mmol/L). Soon after these results were received, spironolactone was added. On August 12th 2011, she was taken off her triamterene and spironolactone. At the same time she was started on potassium supplementation and her potassium was closely followed.

On September 26th 2011, after she had been off the spironolactone and triamterene for six weeks, she underwent confirmatory testing with a saline suppression test which was positive (post-saline aldosterone 445 pmol/L, normal <140 pmol/L). A CT scan revealed a 1.8 cm nodule in the left adrenal gland consistent with an adenoma and a normal appearing right adrenal gland (Fig. 1). She went on to have adrenal venous sampling on November 17th 2011 which showed marked left dominance in aldosterone production with a lateralization index of 72.6, well above the commonly employed threshold of 4 used to define lateralization [2].

In March 2012, she underwent an uneventful left retroperitoneoscopic adrenalectomy. She was discharged home on the first

\* Corresponding author. Tel.: +1 604 806 9108.

E-mail address: [amelck@providencehealth.bc.ca](mailto:amelck@providencehealth.bc.ca) (A. Melck).



**Fig. 1.** CT image of left 1.8 cm adrenal nodule with an average attenuation of 2.6 Hounsfield units.

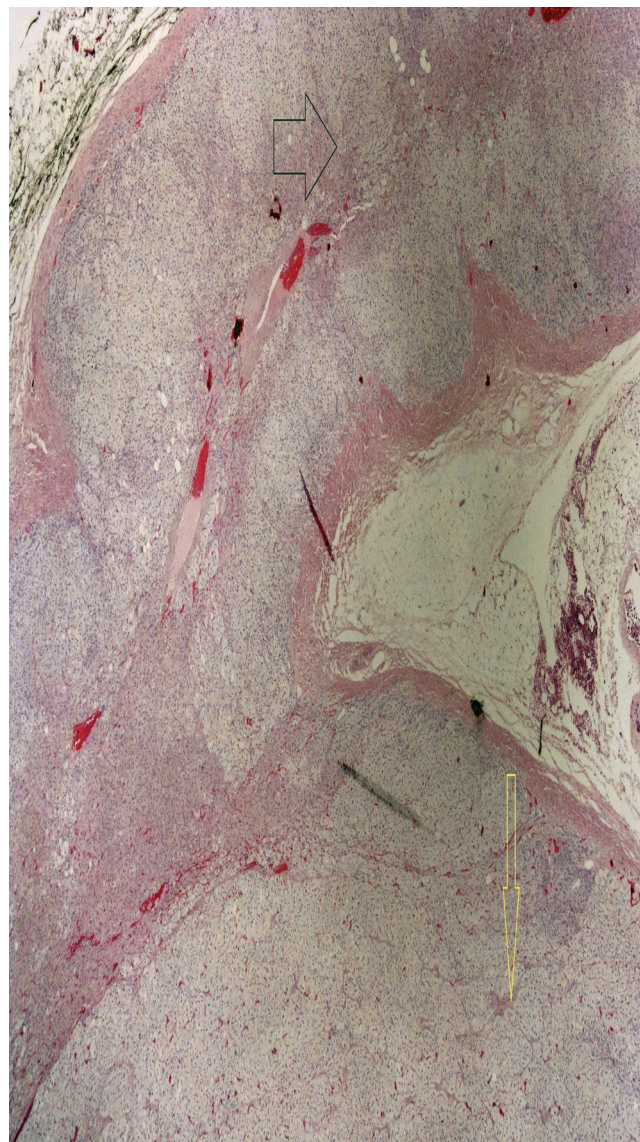
postoperative day with a blood pressure of 135/71 mmHg. She was advised to continue her preadmission antihypertensives except for spironolactone.

Gross pathologic examination revealed an 18.3 gram left adrenal gland measuring  $6.0 \times 3.5 \times 1.5$  cm with a 1.8 cm round, firm, and well-circumscribed orange-tan nodule within the adrenal cortex without areas of hemorrhage or degeneration. The residual adrenal cortex appeared grossly normal without significant atrophy. Microscopic sections of the nodule confirmed the presence of a fibrous pseudocapsule at the expansive border of the tumor (Fig. 2). The component cells had large pale-staining, lipid-rich cytoplasm and smaller cells with relatively sparse lipid and lightly eosinophilic cytoplasm. Nuclear pleomorphism, hyperchromasia, and mitotic figures were absent (Fig. 3). These findings were consistent with a benign adrenal adenoma. The microscopic examination of the remaining adrenal cortex was normal, and there were no signs of nodular hyperplasia.

At her first follow-up appointment three weeks after surgery, her nifedipine had been stopped and her triamterene/hydrochlorothiazide halved. She was complaining of lightheadedness and her blood pressure was 130/80 mmHg. Her plasma potassium without any supplementation was normal at 4.9 mmol/L. Her remaining antihypertensives were discontinued. At her next follow-up visit four weeks postoperatively, she had ongoing lightheadedness and was found to be hypotensive with a blood pressure of 102/72 mmHg. Additionally, her potassium was elevated at 6.1 mmol/L and sodium was decreased at 132 mmol/L (normal 135–148). She was diagnosed with aldosterone deficiency and started on aldosterone replacement (fludrocortisone 0.1 mg daily). Her fludrocortisone was successfully weaned over the following months. By six months postoperatively she was off all medication, her potassium had normalized to 4.2 mmol/L and her blood pressure also normalized to 122/72 mmHg.

### 3. Discussion

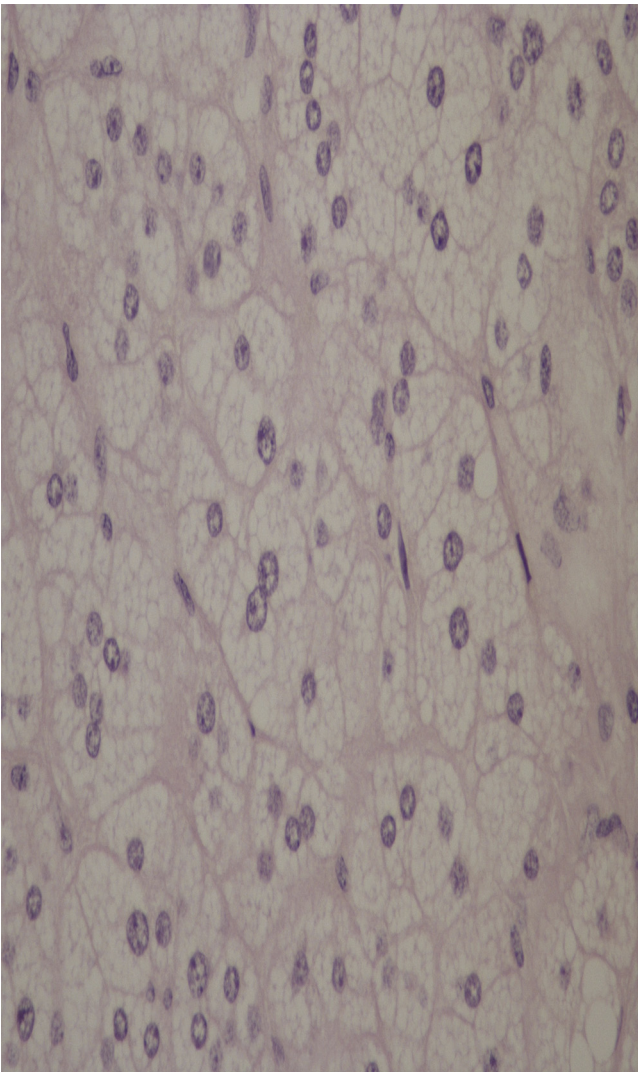
We performed a literature review based on a search of all peer-reviewed publications on PUBMED and EBSCO-host databases. Our search terms included “aldosterone”,



**Fig. 2.** Low power view (2× objective) of an adenoma with expansive smooth borders (yellow arrow) sharply demarcated from the adjacent normal adrenal cortex (black arrow).

“primary aldosteronism”, “adrenal adenoma”, “hyperaldosteronism”, “adrenalectomy”, “postoperative hyperkalemia”, “postoperative hypoaldosteronism”, “hyperkalemia”, “hypoaldosteronism”, and “adrenal hypotension”. The search was not restricted by date or language of publication.

After unilateral adrenalectomy for PA, some patients manifest hyperkalemia postoperatively [3]. Some think this is due to the inability of the remaining adrenal gland to secrete sufficient amounts of aldosterone immediately after surgery [3,4]. In 2010, Huang et al [5] described a case of a 62-year-old man who presented with prolonged and severe hyperkalemia after laparoscopic left adrenalectomy for an aldosteronoma. Two weeks after his surgery, he was found to have hyperkalemia and volume depletion. His volume depletion was determined by poor skin turgor, flat jugular veins and postural hypotension. The patient findings of elevated plasma renin activity and inappropriately low aldosterone in the setting of normal plasma cortisol and adrenocorticotropic hormone (ACTH) suggested hypoaldosteronism. They attributed the hypoaldosteronism to be due to defects in aldosterone biosynthesis or selective unresponsiveness to angiotensin II in the adrenal zona



**Fig. 3.** High power view (40× objective) demonstrating bland appearing large, lipid-rich cells composing most of the adenoma.

glomerulosa. They suggested that their findings of dissociated renin and aldosterone levels imply that contralateral aldosterone secretion after unilateral adrenalectomy is not determined by feedback control, but rather by the synthetic capability of the remaining adrenal gland.

Gordon et al [6] showed a prolonged postoperative period of up to 2 years in which patients no longer requiring antihypertensive medications had evidence of intravascular volume depletion, associated with low to low-normal serum aldosterone and high to high-normal plasma renin activity, despite being off their antihypertensive medication. This suggests a decreased adrenal mass as being the potential cause for the postoperative hyperkalemia. This is in contrast to the findings of Gadallah et al [7] who reported a case in which severe hyperkalemia and hypotension were associated with very low serum aldosterone levels. In this patient, plasma renin activity was extremely low, suggesting suppression of the juxtaglomerular apparatus of the kidneys. The gradual normalization of hyperkalemia and the renin and aldosterone levels meant this suppression was reversible.

Very low levels of aldosterone are usually seen transiently in the postoperative period, and some published studies suggest that the remaining adrenal gland produces normal aldosterone levels by 6 months [8–11]. However, Gordon et al [6] concluded that the

tendency to hypotension after unilateral adrenalectomy is clinically significant and if left untreated, may not recover spontaneously. This was based on a prospective evaluation of blood pressure and hormone response to unilateral adrenalectomy for Conn's syndrome in twenty-six patients seen at regular intervals for two years postoperatively. At two years, seven patients (27%) had systolic blood pressures below the fifth percentile which was more than five times the expected rate. Mean plasma aldosterone levels were significantly lower than in age- and sex-matched controls at 1 and 2 years postoperatively, suggesting relative aldosterone deficiency.

Three weeks elapsed between our patient's surgery and her development of classical clinical features of aldosterone deficiency. Similar to Morimoto et al., [12], this could be attributed to her preoperative spironolactone which may have a protective role. They explain that preoperative spironolactone corrects the metabolic derangements caused by excessive aldosterone, such as prolonged hypervolemia. This prevents the juxtaglomerular apparatus from being fully suppressed preoperatively and to resume normal function postoperatively.

In 2012, Fischer et al [13] sought to identify risk factors predisposing to hyperkalemia post-adrenalectomy. They performed a retrospective chart review and found that eighteen of their 110 patients who underwent adrenalectomy for PA developed hyperkalemia. Six of these patients required mineralocorticoid replacement therapy. They describe higher age and impaired renal function as risk factors for postoperative hyperkalemia, and found that preoperative treatment with mineralocorticoid receptor antagonists did not influence the incidence of hypoaldosteronism and hyperkalemia in their patients. Renal function as a risk factor is a significant finding because patients with PA have been shown to be at a higher risk for earlier and prominent renal involvement as compared to patients with essential hypertension [14]. Renal impairment was not an issue in our patient as her creatinine and eGFR had always been normal.

#### 4. Conclusion

The case reported here highlights the importance of careful postoperative follow up in Conn's patients after adrenalectomy. There is a described risk of aldosterone insufficiency that may require mineralocorticoid supplementation. The reasons for prolonged selective suppression of aldosterone secretion after unilateral adrenalectomy remain unclear. Variables such as the preoperative dose of spironolactone, the size of the adrenal mass, the duration and severity of PA and the degree of hypokalemia may be factors [5]. Some patients may have a decreased residual adrenal mass. In this case the postoperative hypoaldosteronism was transient; however, further studies to evaluate which patients are at risk will prove useful. Though there are only a few case reports of hypotension and hyperkalemia post-adrenalectomy, the consequences of this if left undiagnosed can be severe. We therefore recommend that all patients undergo close follow up postoperatively and have their blood pressure, plasma potassium and sodium, and serum aldosterone levels monitored. Older patients and patients with preoperative impaired renal function may require more prolonged monitoring.

#### Disclosure

This work was not supported by any grants or fellowships. The authors have nothing to disclose. Informed consent was obtained and the patient's privacy has been protected at all times.

### Conflict of interest

We the authors declare that we have no competing interests.

### Funding

We do not have any sponsorship or sources of funding.

### Author contribution

Ekua Yorke – principal author, researcher, read and approved final manuscript.

Adrienne Melck –co-author, researcher, and proofreader, read and approved final manuscript.

Sara Stafford – senior author and proofreader, read and approved final manuscript.

Daniel Holmes – senior author and proofreader, read and approved final manuscript.

Sachiv Sheth – senior author and proofreader, read and approved final manuscript.

### Consent

Written informed consent was obtained from the patient for publication of this case report and the accompanying image. A copy of this consent can be made available to the journal upon request.

### References

- [1] W.F. Young Jr., Endocrine Hypertension, in: D.G. Gardner, D. Shoback (Eds.), Greenspan's Basic & Clinical Endocrinology, 9e, McGraw-Hill, New York, NY, 2011, Accessed on: 14. 12. 2014. chapter 10 <http://accessmedicine.mhmedical.com/content.aspx?bookid=380&Sectionid=39744050>
- [2] M.J.E. Kempers, J.W.M. Lenders, L. van Outhousden, G.J. van der Wilt, L.J.S. Kool, A.R.M.M. Hermus, J. Deinum, J.R. Systematic Review, diagnostic procedures to differentiate unilateral from bilateral adrenal abnormality in primary aldosteronism, *Ann. Intern. Med.* 151 (2009) 329–337.
- [3] J.R. Gill Jr., Hyperaldosteronism, in: K.L. Becker, J.P. Bilezikian, W.J. Bremner, W. Hung, C.R. Kahn, D.L. Loriaux, E.S. Nylén, R.W. Rebar, G.L. Robertson, L.J.B. Wartofsky (Eds.), Principles and Practice of Endocrinology and Metabolism, 2nd ed, Lippincott Co., Philadelphia, 1995, pp. 716–734.
- [4] N.M. Kaplan, R.G. Victor, Primary Aldosteronism, in: Clinical Hypertension, 7th ed., Lippincott Williams & Wilkins, Baltimore, 1998, pp. 365–382.
- [5] W.T. Huang, T. Chau, S.T. Wu, S.H. Lin, Prolonged hyperkalemia following unilateral adrenalectomy for primary hyperaldosteronism, *Clin. Nephrol.* 5 (2010) 392–397.
- [6] R.D. Gordon, P.G. Hawkins, S.M. Hamlet, T.J. Tunny, S.A. Klemm, A.W. Backmann, W.L. Finn, Unexpected incidence of low blood pressure 2 years after unilateral adrenalectomy for primary aldosteronism, *Clin. Exp. Pharmacol. Physiol.* 16 (1989) 281–286.
- [7] M.F. Gadallah, Y. Kayyas, F. Boules, Reversible Suppression of the Renin-Aldosterone Axis After Unilateral Adrenalectomy for Adrenal Adenoma, *Am. J. Kidney Dis.* 32 (1) (1998 Jul) 160–163.
- [8] E.G. Biglieri, P.E. Slaton Jr, W.S. Silen, M. Galante, P.H. Forsham, Post-operative studies of adrenal function in primary aldosteronism, *J. Clin. Endocrinol. Metab.* 5 (1966) 553–558.
- [9] E.L. Bravo, H.P. Dustan, R.C. Tarazi, Selective hypoaldosteronism despite prolonged pre- and post-operative hyperreninaemia in primary aldosteronism, *J. Clin. Endocrinol. Metab.* 41 (3) (1975) 611–617.
- [10] H. Groth, W. Vetter, M. Stimpel, P. Greminger, W. Tenschert, E. Klaiber, H. Vetter, Adrenalectomy in primary aldosteronism: a long term follow up study, *Cardiology* 72 (Suppl 1) (1985) 107–116.
- [11] T. Kawasaki, K. Uezono, M. Ueno, Y. Noda, K. Kumamoto, Y. Kawano, M. Ogata, K. Fukiyama, T. Omae, F.C. Bartter, Influence of unilateral adrenalectomy on renin-angiotensin-aldosterone system in primary aldosteronism, *Jpn. Heart J.* 5 (September 21) (1980) 681–692.
- [12] S. Morimoto, R. Takeda, M. Murakami, Does Prolonged Pretreatment with Large Doses of Spironolactone hasten Recovery from Juxtaglomerular-Adrenal Suppression in Primary Aldosteronism, *J. Clin. Endocrinol.* 31 (1970) 659–664.
- [13] E. Fischer, G. Hanslik, A. Pallauf, C. Degenhart, U. Linsenmaier, F. Beuschlein, M. Bidlingmaier, T. Mussack, R. Ladurner, K. Hallfeldt, M. Quinkler, M. Reincke, Prolonged zona glomerulosa insufficiency causing hyperkalemia in primary aldosteronism after adrenalectomy, *J. Clin. Endocrinol. Metab.* 97 (11) (2012) 3965–3973.
- [14] G.P. Rossi, G. Bernini, G. Desideri, B. Fabris, C. Ferri, G. Giacchetti, C. Letizia, M. Maccario, M. Mannelli, M.J. Matterello, D. Montemurro, G. Palumbo, D. Rizzoni, E. Rossi, A.C. Pessina, F. Mantero, PAPA Study Participants. Renal Damage in primary aldosteronism: results of the PAPA Study, *Hypertension* 2 (August) (2006) 232–238.

### Open Access

This article is published Open Access at [sciedirect.com](http://sciedirect.com). It is distributed under the [IJSCR Supplemental terms and conditions](#), which permits unrestricted non commercial use, distribution, and reproduction in any medium, provided the original authors and source are credited.