



The Natural History of Kienböck's Disease Diagnosed at More than 50 Years of Age

Ji Sup Hwang, MD*, Bum Jin Shim, MD[†], Qingyuan Li, MD*[‡], Jihyeung Kim, MD*, Goo Hyun Baek, MD*[§]

*Department of Orthopedic Surgery, Seoul National University Hospital, Seoul,

[†]Department of Orthopaedic Surgery, Hallym University Chuncheon Sacred Heart Hospital, Chuncheon, Korea

[‡]Department of Hand and Microsurgery, Tianjin Hospital, Tianjin, China

[§]Department of Orthopedic Surgery, Seoul National University College of Medicine, Seoul, Korea

Background: Previous literatures suggest that the prognosis of Kienböck's disease might be favorable despite no surgery if it is diagnosed in late age, but the evidence is not clear. The aim of this study was to determine the radiographic and clinical progression of Kienböck's disease diagnosed at more than 50 years of age.

Methods: Data of 27 patients diagnosed with Kienböck's disease at more than 50 years of age between 2000 and 2016 were investigated. During the study period, no treatment, either surgical or nonsurgical, was applied. We explained to the patients that the affected lunate was not expected to collapse further if found late in age. Annual visits were recommended, through which radiographic and clinical observation was made. We assessed changes in Stahl index and radioscapoid angle between the initial assessment and the final follow-up, and clinical assessment was made using pain in visual analog scale (VAS) and Dornan's criteria.

Results: Initially, 2 patients were in Lichtman stage 1, 6 in stage 2, 5 in stage 3A, 11 in stage 3B, and 3 in stage 4. Radiographic follow-up of at least 5 years (mean, 7.8 years) was made in 14 patients, whose Stahl index and radioscapoid angle did not differ significantly from their initial measurements. Arthritic appearance was not found, and progression in the Lichtman stage was detected in 1 lunate, from 3A to 3B. Despite no surgical treatment for an average of 7.5 years (range, 5.0–15.7 years) of observation period in the 27 patients, average pain in VAS improved from 3.5 (range, 1–7) to 0.8 (range, 0–2), with excellent or good clinical status by Dornan's criteria.

Conclusions: Our study suggests that Kienböck's disease diagnosed at more than 50 years of age can follow a benign natural course in radiographic and clinical aspects. Therefore, surgical interventions should be considered carefully in this age group.

Keywords: Lunate, Avascular necrosis, Kienböck's disease, Conservative treatment, Natural history

Kienböck's disease is manifested by avascular necrosis of the lunate.¹⁾ Mostly affected at young age, the necrotic lunate is vulnerable to subsequent collapse.²⁾ Patients

with the disease has high risk of disintegration of carpal biomechanics and of early-onset arthritis.¹⁾ As a surgical intervention, revascularization of the lunate is attempted using vascularized bone grafts or radial osteotomy.¹⁾ For advanced stages, salvage procedures such as partial or total wrist fusion are performed to manage arthritic pain by sacrificing the wrist motion.¹⁾

Meanwhile, reports on patients with Kienböck's disease diagnosed in late age have been made by some studies. Including the first case report in 1982,³⁾ the studies showed favorable outcomes of nonsurgical treatment in this subset of patients.^{4,5)} In a recent cross-sectional study,

Received January 13, 2022; Revised April 23, 2022;

Accepted May 18, 2022

Correspondence to: Goo Hyun Baek, MD

Department of Orthopedic Surgery, Seoul National University Hospital,
101 Daehak-ro, Jongno-gu, Seoul 03080, Korea

Tel: +82-2-2072-2335, Fax: +82-2-764-2718

E-mail: ghbaek@snu.ac.kr

the percentage of collapsed lunates was smaller in aged patients without any symptoms than in young symptomatic patients.⁶⁾ These findings imply that lunates in Kienböck's disease might have a favorable prognosis and not undergo a significant collapse if diagnosed late in life. Following these case reports and series,³⁻⁵⁾ we did not perform any interventions, either surgical or nonsurgical, for patients with Kienböck's disease whose diagnosis was made at more than 50 years of age. Annual observation was made for their radiographic and clinical check-ups. Through analysis of more than five years of follow-up, we aimed to determine the radiographic and clinical progression of Kienböck's disease diagnosed at more than 50 years of age.

METHODS

We obtained Institutional Review Board approval for the study (No. H-2011-104-1174), and the need for informed consent was waived. All research was performed in accordance with relevant guidelines and regulations.

Patients who were diagnosed with Kienböck's disease at more than 50 years of age at our institute were subjects of this study. The diagnosis was made based on history and radiographs according to the established criteria.⁷⁾ Tenderness on the involved lunate aided in the diagnoses. For the patients, we explained that the affected lunate was not expected to collapse further if found in late age. Instead, treatment was focused on concomitant hand diseases (e.g., carpal tunnel release for carpal tunnel syndrome and stretching exercise for chronic synovitis). Regardless of the stage of the disease at the time of diagnosis, surgical treatment for the Kienböck's disease was not recommended. Nonsurgical treatments, such as immobilization using splints, were also not made, except for pain control using nonsteroidal anti-inflammatory drugs. Annual visit to the clinic was recommended to detect any significant collapse of the lunate and arthritic change in carpal bones. To ensure the minimum 5 years of follow-up, we selected the patients whose diagnoses were made before 2016.

Clinical and Radiographic Evaluation

From the anteroposterior and lateral radiographs of the wrists, measurements were made including disease staging using Lichtman's modification of Stahl's original classification,⁸⁾ ulnar variation as described by Gelberman et al.,⁹⁾ Stahl index as described by Youm et al.,¹⁰⁾ and radioscapoid angle according to Goldfarb et al.¹¹⁾ For the Stahl index and radioscapoid angle, three orthopedic surgeons (JSH, BJS, and QL) made the measurements from the radio-

graphs that had been mixed up in nonchronological order. One surgeon (BJS) repeated the measurements more than 3 weeks later. The interobserver reliability ranged from 0.936 to 0.965 for Stahl index and from 0.916 to 0.952 for radioscapoid angle. The intraobserver reliability ranged from 0.981 to 0.989 for Stahl index and from 0.953 to 0.967 for radioscapoid angle. Therefore, a mean of the two sets of measurements made by the author who performed the intraobserver reliability testing (BJS) was used for the analysis.

At each visit to the clinic, we evaluated the patients' clinical and radiographic status. The severity of wrist pain was assessed using visual analog scale (VAS) from 0 to 10. For the affected and unaffected sides, grip strength was measured using a dynamometer, and the percent grip strength was calculated for the affected side. All measures of strength compared to the contralateral side were corrected for limb dominance in all right-handed individuals by assuming the right hand was 15% stronger. Passive range of motion (ROM) of the wrist in extension and flexion was evaluated using a goniometer. Clinical results were evaluated using Dornan's criteria: excellent if no complaints and capable of working without difficulty; good if capable of working without loss of time, but with symptoms after very heavy use; fair if improvement in symptoms but unable to resume heavy work; and poor if no improvement, with persistent weakness and pain in the wrist.^{5,12)} For patients who could not visit the clinic for any reason, telephone interviews were made to check for whether they had surgical treatment for Kienböck's disease at other hospitals and to assess the wrist pain in VAS.

Statistical Analysis

Descriptive statistics (means, standard deviations, and percentages) were calculated for all variables of interest. To assess the radiographic progression of the disease, patients whose radiographs were followed up for more than 5 years were selected. The Stahl index and radioscapoid angle measured from their initial and final radiographs were compared, of which the statistical significance was determined using Wilcoxon signed-rank test. Clinical progression of the disease was assessed by comparing the initial and final pain in VAS and ROM of the wrist, of which the statistical significance was determined using Wilcoxon signed-rank test. All statistical analyses were performed using the IBM SPSS ver. 26.0 (IBM Corp., Armonk, NY, USA), and a $p < 0.05$ was considered statistically significant.

RESULTS

Patient Characteristics

Between 2000 and 2016, 27 patients were diagnosed with Kienböck's disease at more than 50 years of age. There were 6 men and 21 women, whose mean age at the diagnosis was 62.3 years (range, 50–75 years). All 27 patients had tenderness of the lunate at palpation. Twenty-one patients complained of wrist pain for average 14.3 months (range, 0.8–61.0 months). The average VAS was 3.5 (range, 1–7). The average ROM of the wrist was 32° (range, 20°–60°) for extension and 36° (range, 10°–60°) for flexion. Two patients were in Lichtman stage 1, 6 in stage 2, 5 in stage 3A, 11 in stage 3B, and 3 in stage 4. There was no correlation between pain in VAS or wrist ROM and the Lichtman stage. The average ulnar variance was +1.0 mm (range, –2.1 to +3.4 mm) (Table 1).

Radiographic Progression

Among the 27 patients, more than 5 years of radiographic follow-up was made in 14 patients, for which comparison

between the initial and the final radiographic parameters could be made with average 7.8 years (range, 5.0–14.4 years) of interval. Radiographic follow-up in the other 13 patients did not reach 5 years because of their refusal to undergo radiographic assessment (Table 1). A lunate in 1 patient that was initially classified as Lichtman stage 3A changed to Lichtman stage 3B one year after the diagnosis (Fig. 1A and B). During the next 4 years of observation, there was no further collapse (Fig. 1C). The other 12 lunates showed no change in Lichtman stage during the follow-up. The initial radiographs showed average Stahl index and radioscapoid angle of 0.37 (range, 0.24–0.49) and 64.4° (range, 53°–73°), respectively. At the final follow-ups, the measurements averaged 0.36 (range, 0.23–0.50) and 62.3° (range, 48°–72°), respectively. There was no statistical significance in the changes for both parameters (Table 2, Fig. 2).

Clinical Progression

As well as the radiographic assessment, more than 5 years of follow-up was made for the physical examinations in

Table 1. Demographics of the Subjects of This Study

Variable	Total patients (n = 27)	Follow-up > 5 yr (n = 14)	Follow-up < 5 yr (n = 13)
Age at diagnosis (yr)	62.3 (50 to 75)	62.5 (50 to 75)	61.7 (53 to 74)
Women	21 (78)	10 (77)	11 (79)
Right hand involved	16 (59)	8 (57)	8 (62)
Duration of symptom (mo)	14.3 (0.8 to 61.0)	14.9 (1.3 to 24.0)	13.7 (0.8 to 47.0)
Lichtman stage			
1	2 (7)	0	2 (15)
2	6 (22)	4 (29)	2 (15)
3A	5 (19)	3 (21)	2 (15)
3B	11 (41)	4 (29)	7 (54)
4	3 (11)	3 (21)	0
Pain in VAS	3.5 (1 to 7)	3.5 (1 to 7)	3.3 (1 to 7)
Range of wrist motion			
Dorsiflexion (°)	32.2 (20 to 60)	35.0 (20 to 60)	20.0 (10 to 30)
Volar flexion (°)	36.1 (10 to 60)	33.1 (10 to 40)	33.3 (10 to 60)
Ulnar variance (mm)	+1.0 (–2.1 to +3.4)	+0.9 (–2.6 to +3.2)	+1.0 (–4.1 to +3.4)
Radiographic follow-up (yr)	4.7 (1.0 to 14.4)	7.8 (5.0 to 14.4)	2.0 (1.0 to 4.5)
Clinical follow-up (yr)	7.6 (5.0 to 15.7)	7.6 (5.0 to 14.4)	7.5 (5.1 to 15.7)

Values are presented as median (range) or number (%).
VAS: visual analog scale.

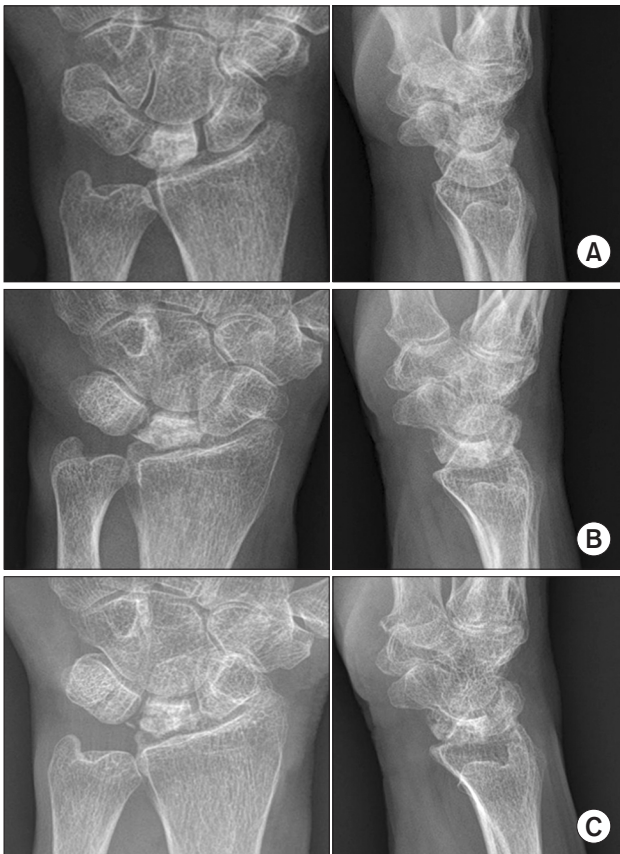

Fig. 1. Wrist pain persisted for 5 years in a 66-year-old woman. (A) Plain radiographs showed Kienböck's disease (Lichtman stage 3A) and chronic synovitis at the dorsum of the wrist. For the latter condition, passive stretching exercise and pain control using nonsteroidal anti-inflammatory drugs were recommended. (B) One year later, apparent collapse of the lunate with persistent radiographic sign of the synovitis could be found. (C) After continuous observation of additional 4.7 years, the lunate did not collapse further, with radiographic signs of the synovitis no longer apparent. Intermittent pain of twice a month was the only remaining symptom.

the same 14 patients, and the remaining 13 patients were interviewed by telephone. Improvement in pain was found in all 27 patients, none of whom had undergone surgical treatment for Kienböck's disease. The average VAS was 0.8 (range, 0–2) at the last follow-up ($p = 0.001$). Clinical results were excellent in 22 patients and good in 5 patients according to Dornan's criteria.¹²⁾ The average percentage grip strength at the last follow-up was 85% (range, 74%–102%). The final ROM of the wrist was 41° (range, 20°–60°) for extension and 41° (range, 20°–65°) for flexion. When compared to the initial measurements, there was no statistically significant difference in both extension (32° vs. 41°, $p = 0.054$) and flexion (36° vs. 41°, $p = 0.079$). Focal tenderness of the lunate, which was present at the

initial diagnosis of all patients, no longer existed.

DISCUSSION

Natural history of Kienböck's disease is not well defined. Because collapse of the necrotic lunate was delayed through surgical interventions,²⁾ the disease has been thought to be progressive in nature. More studies are required for better understanding, but the low incidence of the disease has made it difficult. In the present study, 27 patients with a diagnosis of Kienböck's disease at more than 50 years of age were observed for an average of 4.7 years. More than 5 years of radiographic follow-up could be made in 14 patients over a period ranging from 5.0 to 14.4 years. By analyzing Stahl index for lunate collapse and radioscapoid angle for its effect on carpal biomechanics, we found that both radiographic parameters did not deteriorate after more than 5 years of observation.

Outcomes of nonsurgical treatment have been reported for Kienböck's disease diagnosed in late age in case reports^{13,14)} and case series.⁵⁾ Clinical outcomes assessed by wrist pain and ROM or functional scores were consistently favorable despite no surgical intervention. On the other hand, Taniguchi et al.⁵⁾ reported after an average 5.5 years of follow-up that collapse in the lunates and arthritic changes in the surrounding carpal joints were consistently found in all 13 cases. Outcomes were favorable in clinical aspects, but not in radiographic. To the best of our knowledge, our study is the second case series that reported radiographic follow-up data in this subset of patients. The gender ratio, mean age at diagnosis, mean age at the onset of symptom, and ulnar variance were similar to those in the previous study. However, a significant difference in the radiographic progression could be observed. Despite the longer follow-up period, none of the lunates resulted in arthritic changes. Increase in the lunate height could be found, and the trabecular patterns inside the lunate became similar to the surrounding carpal bones (Fig. 3). We believe that Kienböck's disease, if diagnosed in late age, has a benign natural course not only clinically, but also radiographically.

The reason for the favorable prognosis of Kienböck's disease diagnosed in late age is unclear. Nevertheless, necrotic lunates that do not collapse imply that they comprise a totally different disease entity from Kienböck's disease diagnosed in earlier age. Taniguchi et al.⁵⁾ suggested osteoporosis as a predisposing factor of necrotic lunate in the elderly. A high proportion of women was also observed in our series (78%), but further evaluation using bone mineral density or bone turnover markers is required

Table 2. Radiographic Follow-up of More Than 5 Years for Patients with Kienböck's Disease Diagnosed at More Than 50 Years of Age

Case	Sex	Age at diagnosis (yr)	Ulnar variance (cm)	Initial measurement			Final measurement			Follow-up (yr)
				Lichtman stage	Stahl index	RSA (°)	Lichtman Stage	Stahl index	RSA (°)	
1	Male	57	1.8	3A	0.31	55	3A	0.39	54	14.4
2	Male	72	1.1	2	0.49	55	2	0.50	NA	5.0
3	Female	67	-0.5	4	0.26	71	4	0.27	72	8.1
4	Female	50	-2.6	3B	0.27	73	3B	0.29	65	10.7
5	Female	60	2.8	4	0.24	66	4	0.23	67	8.6
6	Female	61	1.7	3A	0.47	56	3A	0.36	58	9.5
7	Female	67	1.8	2	0.46	61	2	0.50	60	5.0
8	Female	57	3.2	2	0.47	58	2	0.47	47	7.2
9	Female	69	1.4	4	0.31	63	4	0.30	70	6.8
10	Male	56	0.1	3B	0.25	73	3B	0.26	65	6.6
11	Female	75	1.2	3B	0.33	68	3B	0.39	66	5.8
12	Female	66	-0.2	3A	0.45	60	3B	0.31	58	5.7
13	Female	62	2.8	3B	0.34	67	3B	0.33	66	5.1
14	Female	55	-0.5	3B	0.46	66	3B	0.46	62	10.1

RSA: radioscaphoid angle, NA: not applicable.

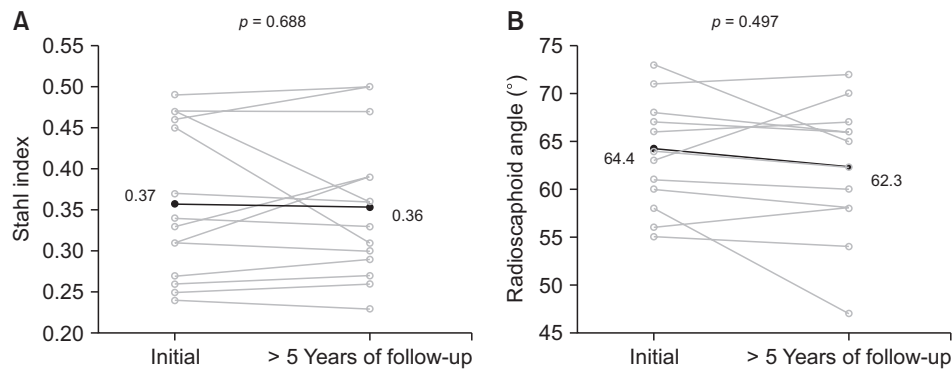


Fig. 2. For 14 patients with Kienböck's disease diagnosed at more than 50 years of age, we compared the initial and final measurements of Stahl index (A) and radioscaphoid angle (B) with at least 5 years of interval. The measurements are shown with circles, and the two time points are connected with gray lines. Solid circles connected with a black line indicate mean values. The p -values between the measurements were calculated using Wilcoxon signed-rank test.

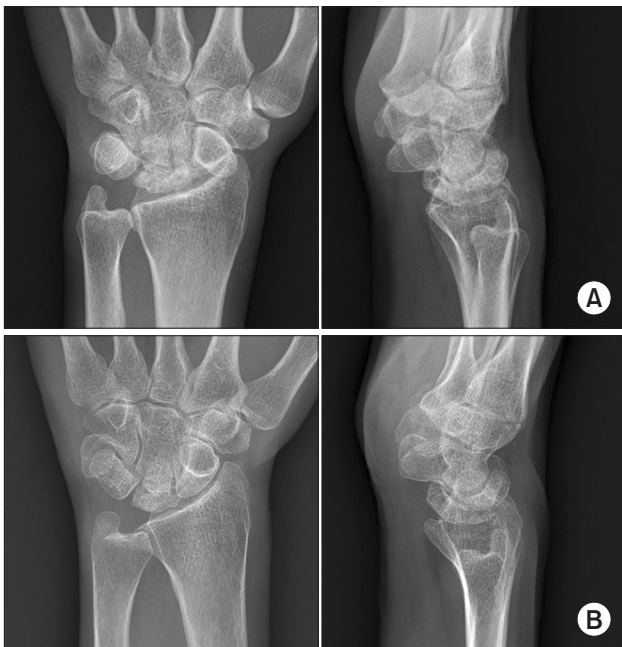

Fig. 3. A 50-year-old woman underwent carpal tunnel release and her concomitantly found Kienböck's disease (Lichtman stage 3B) was closely observed for its clinical and radiographic progression. (A) Initial radiographs showed collapse of the lunate with evident sclerotic change. (B) Radiographs taken 10.7 years after the diagnosis showed an apparent increase in the height of the lunate. Note the trabecular pattern inside the lunate, which became similar to that of other carpal bones. Intermittent pain existed, but the patient was satisfied with not having undergone surgery for Kienböck's disease.

to prove this hypothesis. Furthermore, diminished vulnerability to collapse is also not explained if osteoporosis is a predisposing factor. Otherwise, ulnar variance becomes more positive as aging.¹⁵ A positive ulnar variance, which diminishes the axial loading of the radius,¹⁶ may act as a protective factor for the lunate collapse. Although data

were not shown, 2 of our patients with highly negative ulnar variance were both in advanced stages when initially diagnosed. Because of the small number of subjects in this study, however, no definite conclusion can be drawn.

During the observation period for the patients, our treatment was focused on other concomitant hand diseases. We could find carpal tunnel syndrome in 4 patients, ulnar impaction syndrome in 3 patients (Fig. 4), chronic synovitis of the wrist in 3 patients (Fig. 1), De Quervain disease in 3 patients, pisotriquetral arthritis in 2 patients, flexor tenosynovitis in 2 patients, and rheumatoid arthritis in 1 patient. Flattening deformation, frequently found in the lunates with avascular necrosis,² may become, in the long term, a cause of carpal tunnel syndrome¹⁷ and dorsal synovitis.¹⁸ Furthermore, the chronically decreased ROM in the affected wrist might increase the burden on the surrounding soft- and bony-tissue structures, of which the possible consequence includes De Quervain disease and flexor tenosynovitis. Complaints of the patients warranted a great deal of attention at the initial visits. But our long-term observation on these patients found that most of them no longer had to seek for help in the long run. Decision for surgery, therefore, should be made with caution. Treatments of the concomitant hand diseases may alleviate pain and improve hand function in patients with Kienböck's disease, especially in the elderly.

Evaluation of treatment effects on the lunate pathology in Kienböck's disease has been attempted in many ways. Abnormal signals in magnetic resonance and radio-nuclide imaging have served as evidence that the ischemic lunate is a hallmark pathology of the disease.¹⁹ Normalization of the signal could be found after radial shortening osteotomy²⁰ and vascularized bone graft.²¹ The most widely used diagnostic tool would be plain radiography to measure Stahl index, carpal height ratio, and scapholu-

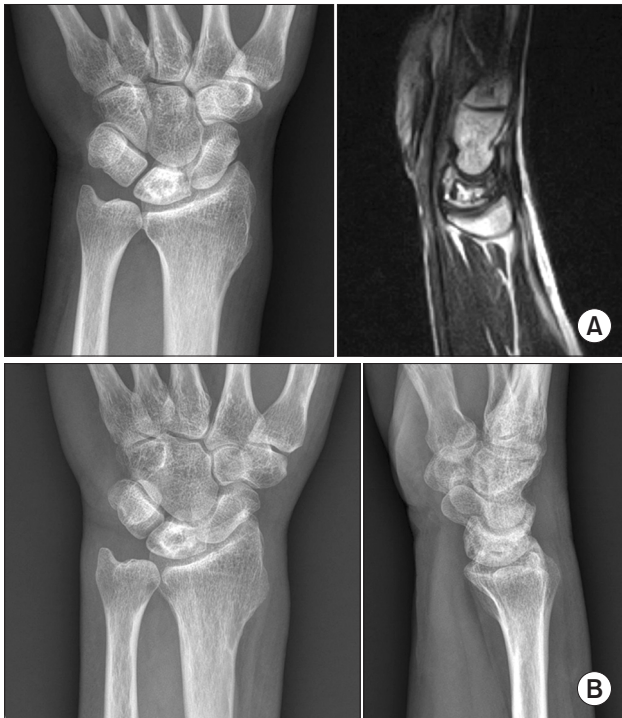

Fig. 4. Wrist pain in a 57-year-old man, mainly located on the ulnar side of the wrist. (A) The plain radiograph showed a large cystic lesion in the lunate and a positive ulnar variance. Magnetic resonance imaging showed a geographic bone lesion surrounded by low-signal rim inside the lunate, indicative of Kienböck's disease (Lichtman stage 2). (B) Follow-up of 7.2 years resulted in no further collapse in the lunate and no arthritic involvement. Intermittent pain control and lifestyle modification of avoiding the pronated position of the forearm resulted in favorable clinical outcome.

nate angle. Absence of sclerotic or cystic changes and of fragmentation,²²⁾ and normalization of the trabecular patterns inside the lunate²³⁾ have also been related to favorable treatment outcome. Lastly, lunate tenderness to palpation can be checked for both diagnosis and treatment monitoring in physical examination,²⁴⁾ where its disappearance could be found in our consecutive series at the last follow-up visits.

There are some limitations of this study. First, although telephone interviews were performed in all 27 patients to confirm the improvement in their symptoms despite no surgical treatment for Kienböck's disease, loss to follow-up for the radiographic assessment can be a limitation of this study. However, this is the first study that provides any radiographic evidence of favorable outcome after more than 5 years of observation period. Second, because of the retrospective nature of the study, demographic or risk factors, such as tobacco use, employee status, or

comorbidities, were not evaluated.

Our study suggests that the Kienböck's disease diagnosed at more than 50 years of age can follow a benign natural course in radiographic and clinical aspects. Therefore, surgical interventions should be considered carefully in this age group.

CONFLICT OF INTEREST

No potential conflict of interest relevant to this article was reported.

ORCID

Ji Sup Hwang <https://orcid.org/0000-0001-8671-0350>
 Bum Jin Shim <https://orcid.org/0000-0002-3751-2304>
 Qingyuan Li <https://orcid.org/0000-0002-3846-6709>
 Jihyeung Kim <https://orcid.org/0000-0002-3182-5035>
 Goo Hyun Baek <https://orcid.org/0000-0002-9126-7194>

REFERENCES

1. Lutsky K, Beredjiklian PK. Kienbock disease. *J Hand Surg Am.* 2012;37(9):1942-52.
2. Salmon J, Stanley JK, Trail IA. Kienbock's disease: conservative management versus radial shortening. *J Bone Joint Surg Br.* 2000;82(6):820-3.
3. Jain AS. Kienbock's disease of the wrist in an elderly female. *Hand.* 1982;14(2):182-4.
4. Yoshida T, Tada K, Yamamoto K, Shibata T, Shimada K, Kawai H. Aged-onset Kienbock's disease. *Arch Orthop Trauma Surg.* 1990;109(5):241-6.
5. Taniguchi Y, Yoshida M, Iwasaki H, Otakara H, Iwata S. Kienbock's disease in elderly patients. *J Hand Surg Am.* 2003;28(5):779-83.
6. van Leeuwen WF, Janssen SJ, ter Meulen DP, Ring D. What is the radiographic prevalence of incidental Kienbock disease? *Clin Orthop Relat Res.* 2016;474(3):808-13.
7. Allan CH, Joshi A, Lichtman DM. Kienbock's disease: diagnosis and treatment. *J Am Acad Orthop Surg.* 2001; 9(2):128-36.
8. Lichtman DM, Alexander AH, Mack GR, Gunther SF. Kienbock's disease: update on silicone replacement arthroplasty. *J Hand Surg Am.* 1982;7(4):343-7.
9. Gelberman RH, Salamon PB, Jurist JM, Posch JL. Ulnar variance in Kienbock's disease. *J Bone Joint Surg Am.* 1975; 57(5):674-6.
10. Youm Y, McMurthy RY, Flatt AE, Gillespie TE. Kinematics

- of the wrist. I. An experimental study of radial-ulnar deviation and flexion-extension. *J Bone Joint Surg Am.* 1978; 60(4):423-31.
11. Goldfarb CA, Hsu J, Gelberman RH, Boyer MI. The Lichtman classification for Kienbock's disease: an assessment of reliability. *J Hand Surg Am.* 2003;28(1):74-80.
 12. Dornan A. The result of treatment of Kienbock's disease. *J Bone Joint Surg Br.* 1949;31(4):518-20.
 13. Ribbans WJ. Kienbock's disease: two unusual cases. *J Hand Surg Br.* 1988;13(4):463-5.
 14. Geutjens GG. Kienbock's disease in an elderly patient. *J Hand Surg Am.* 1995;20(1):42-3.
 15. Sanderson PL, Cameron IC, Holt GR, Stanley D. Ulnar variance and age. *J Hand Surg Br.* 1997;22(1):21-4.
 16. Giunta RE, Biemer E, Muller-Gerbl M. Ulnar variance and subchondral bone mineralization patterns in the distal articular surface of the radius. *J Hand Surg Am.* 2004;29(5):835-40.
 17. Shinohara T, Nakamura R, Nakao E, Hirata H. Carpal tunnel syndrome associated with Kienbock disease. *Nagoya J Med Sci.* 2016;78(3):267-73.
 18. Ichinose H, Nakamura R, Nakao E, Shinohara T, Tatebe M, Yamada H. Wrist swelling in Kienbock's disease. *J Wrist Surg.* 2018;7(5):389-93.
 19. Stuckey SL, Kalff V, Hoy G. Bone scan findings in Kienbock's disease: a case report with atypical findings and literature review. *Clin Nucl Med.* 1997;22(7):481-3.
 20. Lee JH, Kim J, Hwang JS, Baek GH. Improvement in lunate perfusion after radial closing-wedge osteotomy in patients with Kienbock's disease. *Hand Surg Rehabil.* 2021;40(5):588-94.
 21. Moran SL, Cooney WP, Berger RA, Bishop AT, Shin AY. The use of the 4 + 5 extensor compartmental vascularized bone graft for the treatment of Kienbock's disease. *J Hand Surg Am.* 2005;30(1):50-8.
 22. Miura H, Sugioka Y. Radial closing wedge osteotomy for Kienbock's disease. *J Hand Surg Am.* 1996;21(6):1029-34.
 23. Shin YH, Kim J, Gong HS, Rhee SH, Cho MJ, Baek GH. Clinical outcome of lateral wedge osteotomy of the radius in advanced stages of Kienbock's disease. *Clin Orthop Surg.* 2017;9(3):355-62.
 24. Mehrpour SR, Kamrani RS, Aghamirsalim MR, Sorbi R, Kaya A. Treatment of Kienbock disease by lunate core decompression. *J Hand Surg Am.* 2011;36(10):1675-7.