

Single Case – General Neurology

Postoperative Textiloma Mimicking Intracranial Rebleeding in a Patient with Spontaneous Hemorrhage: Case Report and Review of the Literature

Nicola Montemurro^{a, b} Domenico Murrone^c Bruno Romanelli^c
Aldo Ierardi^c

^aDepartment of Translational Research and New Technologies in Medicine and Surgery, University of Pisa, Pisa, Italy; ^bDepartment of Neurosurgery, Azienda Ospedaliera Universitaria Pisana (AOUP), Pisa, Italy; ^cUnit of Neurosurgery, “Di Venere” City Hospital, ASL Bari, Bari, Italy

Keywords

Textiloma · Gossypiboma · Gauzoma · Muslinoma · Surgical complications

Abstract

During craniotomy, hemostatic materials such as oxidized cellulose and cotton pads, commonly used to control bleeding, may cause a granulomatous reaction that may produce space-occupying mass lesions termed textiloma (or gossypiboma). We present a 46-year-old female who underwent a right frontotemporal craniotomy and surgical removal of intraparenchymal cerebral hemorrhage, and who developed a textiloma during the postoperative period causing seizures. Granulomatous reactions due to hemostatic agents have been reported experimentally, as well as after cranial and spinal operations. We emphasize that although it is rare, an adverse reaction such as a postoperative textiloma due to hemostatic material and subsequent granuloma formation can result in a false image of rebleeding, tumor recurrence, radiation necrosis, or postoperative abscess, depending on the particular clinical history of each patient.

© 2020 The Author(s)
Published by S. Karger AG, Basel

Introduction

During craniotomy, hemostatic materials such as oxidized cellulose and cotton pads are used to control bleeding. Hemostatic materials commonly used for hemostasis may cause a granulomatous reaction that may produce space-occupying mass lesions termed textiloma (or gossypiboma) that are clinically or radiologically apparent. Intracranial body granuloma reactions initially provoke no clinical symptoms, but they may appear months or even years after surgical procedure [1–4]. All classes of hemostatic agents may cause a granulomatous reaction that may mimic recurrent or progressive intracranial tumor, radiation necrosis, abscess, resolving infarction, or intracranial rebleeding on postoperative imaging studies, depending on the particular clinical history of each patient.

Case Presentation

A 46-year-old female, with no significant past medical and surgical illnesses, was admitted to our Department of Neurosurgery because of left hemiplegia followed by secondary generalized seizures. A computed tomography (CT) scan of the head showed the presence of a spontaneous right frontotemporal intraparenchymal cerebral hemorrhage. The patient underwent a right frontotemporal craniotomy and surgical removal of the intraparenchymal cerebral hemorrhage; an anticonvulsive medication was started. Blood tests did not show increased inflammatory parameters, merely a mild leukocytosis. Ten days after surgery, the patient started to develop subsequent seizures. A postoperative CT scan showed a small hyperdense mass lesion in the surgical cavity mimicking a minimal intracranial rebleeding (Fig. 1a). A follow-up CT brain scan 20 days after surgery showed persistence of the small hyperdense mass lesion (Fig. 1b). Subsequent magnetic resonance imaging (MRI) scans revealed a contrast hyperintense enhancing mass at the surgical site (Fig. 1c, d), suggestive of textiloma, developed during the postoperative period following surgery and the cause of seizures. A clinical follow-up 3 months later showed the patient had a good recovery with no seizures, even if a slight left hemiparesis persisted.

Discussion

Chemical hemostatic materials (gelatin sponge, oxidized cellulose, and microfibrillar collagen) are used to achieve hemostasis during neurosurgical procedures. Gelatin sponges were introduced into surgical practice more than 50 years ago. Since that time granulomatous reactions to gelatin foam (Gelfoam), as well as to oxidized cellulose (Oxycel), oxidized regenerated cellulose (Surgicel), microfibrillar collagen (Avitene), or nonabsorbable materials including various forms of cotton pledgets and cloth (such as muslin), have been reported after neurosurgical operations [1, 4–14]. These agents are usually removed prior to surgical closure, except in the case of muslin, which is used to reinforce unclippable intracranial aneurysms [12]. Granulomatous reactions due to hemostatic agents have been reported experimentally [15], as well as after cranial [1, 4–6, 8, 9, 11–14] and spinal [1, 10, 16] operations. Fibrin sealant has not been reported in the neurosurgical literature as the source of a granulomatous reaction [9]. Textiloma (from Latin *textile*, a woven fabric, plus the suffix *oma*, meaning swelling or tumor), gossypiboma (from Latin *Gossypium*, the genus of cotton plants), gauzoma (from surgical gauze), and muslinoma (from muslin, a woven cotton fabric) are all terms that

describe foreign body-related inflammatory pseudo-tumors [1]. These terms refer to mass effect brain lesion arising from retained, absorbable or nonabsorbable hemostatic agents used during surgery, together with the associated inflammatory reaction. In current neurosurgical practice, textiloma, which has an historical precedence denomination in preference to gossypiboma, often refers to a resorbable hemostatic agent that is intentionally left in place to prevent the potentially disastrous consequences of postoperative intracranial hemorrhage. Textilomas may present at any time, from immediately postoperatively to several decades after initial surgery [17, 18]. In this case report, oxidized regenerated cellulose, which is commonly used during surgery to obtain a good hemostasis, was the cause of the foreign body reaction. In the general surgical literature, the incidence of textiloma is highest following abdominal surgery, followed by orthopedic procedures. Textilomas have been reported in all major anatomic compartments: chest, retroperitoneum, extremities, head, and neck [4]. Granulomatous reactions in the head to foreign bodies such as suture material [19], cotton pads [5, 8, 15], cadaveric [20] or synthetic [21] dural grafts, and shunt catheters [22] have been described in numerous publications. Histologic examination typically shows a core of degenerating hemostatic agent surrounded by an inflammatory reaction [4]. Ribalta et al. [4] reported variable proportions of acute and chronic inflammatory cells, foreign body giant cells, collagen deposition, reactive vascular proliferation, and degenerated foreign material in their cases. Resorbable hemostatic agents are used in all craniotomies at our institution. The pathologic reaction described in this paper represents a rare case considering the large number of patients in whom such materials are used and sometimes left during surgery. Nevertheless, it is important to recognize that all the manufacturers of these agents recommend removal of the material once hemostasis is achieved. The increasing use of MRI monitoring enables the opportunity to study these granulomatous reactions. Despite the importance of MRI in the diagnosis of textiloma or gossypiboma, the diagnosis must be reached by radiological suspicions, as also by intraoperative findings.

Conclusion

In patients with a history of cranial operation, textiloma (although no pathognomonic radiologic characteristics are defined for these lesions) should be taken into account in the differential diagnosis when a hyperdense mass lesion is found after surgery, as it is believed that they are much more common than reported [23]. Gelatin sponge, oxidized cellulose, oxidized regenerated cellulose, and microfibrillar collagen, if properly used, are excellent and essential tools for safe control of minor bleeding in neurosurgery. We emphasize that although it is rare, an adverse reaction such as a postoperative textiloma (gossypiboma) due to hemostatic material and subsequent granuloma reaction can result in a false image of rebleeding, tumor recurrence, radiation necrosis, or postoperative abscess.

Statement of Ethics

The patient provided both oral and written informed consent for the publishing of this report.

Disclosure Statement

The authors have no conflicts of interest to declare.

Funding Sources

The authors did not receive any funding support.

Author Contributions

N.M. carried out the literature search and performed the manuscript preparation. D.M., B.R., and A.I. collected the clinical and surgical data. All authors read and approved the final manuscript.

References

- 1 Akpınar A, Ucler N, Özdemir CO. Textiloma (gossypiboma) mimicking recurrent intracranial abscess. *BMC Res Notes*. 2015 Aug;8(1):390.
- 2 Dinesh SK, Lee SY, Thomas J. A case of mistaken identity: intracranial foreign body reaction after AVM embolisation mimicking a glioma. *J Clin Neurosci*. 2008 Apr;15(4):463–5.
- 3 Menkü A, Akdemir H, Tucer B, Kontas O, Durak AC. Foreign body granuloma mimicking recurrent of convexity meningioma. *Turk Neurosurg*. 2003;13(2):53–6.
- 4 Ribalta T, McCutcheon IE, Neto AG, Gupta D, Kumar AJ, Biddle DA, et al. Textiloma (gossypiboma) mimicking recurrent intracranial tumor. *Arch Pathol Lab Med*. 2004 Jul;128(7):749–58.
- 5 Feldman RP, Marcovici A, Suarez M, Goodrich JT. Foreign body granuloma mimicking intracranial meningioma: case report and review of the literature. *Neurosurgery*. 1999 Apr;44(4):855–8.
- 6 Hasturk AE, Basmaci M. Foreign body granuloma mimicking recurrent intracranial tumor: a very rare clinical entity. *Acta Med Iran*. 2013;51(11):816–8.
- 7 Hoyland JA, Freemont AJ, Denton J, Thomas AM, McMillan JJ, Jayson MI. Retained surgical swab debris in post-laminectomy arachnoiditis and peridural fibrosis. *J Bone Joint Surg Br*. 1988 Aug;70(4):659–62.
- 8 Chambi I, Tasker RR, Gentili F, Loughheed WM, Smyth HS, Marshall J, et al. Gauze-induced granuloma (“gauzoma”): an uncommon complication of gauze reinforcement of berry aneurysms. *J Neurosurg*. 1990 Feb;72(2):163–70.
- 9 Kothbauer KF, Jallo GI, Siffert J, Jimenez E, Allen JC, Epstein FJ. Foreign body reaction to hemostatic materials mimicking recurrent brain tumor. Report of three cases. *J Neurosurg*. 2001 Sep;95(3):503–6.
- 10 Kucukyuruk B, Biceroglu H, Abuzayed B, Ulu MO, Kafadar AM. Paraspinal gossypiboma: A case report and review of the literature. *J Neurosci Rural Pract*. 2010 Jul;1(2):102–4.
- 11 Peloquin P, Vannemreddy PS, Watkins LM, Byrne RW. Intracranial cotton ball gossypiboma mimicking recurrent meningioma: report of a case with literature review for intentional and unintentional foreign body granulomas. *Clin Neurol Neurosurg*. 2012 Sep;114(7):1039–41.
- 12 Perrini P, Montemurro N, Caniglia M, Lazzarotti G, Benedetto N. Wrapping of intracranial aneurysms: single-center series and systematic review of the literature. *Br J Neurosurg*. 2015;29(6):785–91.
- 13 Solaini L, Prusciano F, Bagioni P. Intrathoracic gossypiboma: a movable body within a pseudocystic mass. *Eur J Cardiothorac Surg*. 2003 Aug;24(2):300.
- 14 Williams RG, Bragg DG, Nelson JA. Gossypiboma—the problem of the retained surgical sponge. *Radiology*. 1978 Nov;129(2):323–6.
- 15 Sturdy JH, Baird RM, Gerein AN. Surgical sponges: a cause of granuloma and adhesion formation. *Ann Surg*. 1967 Jan;165(1):128–34.
- 16 Van Goethem JW, Parizel PM, Perdieu D, Hermans P, de Moor J. MR and CT imaging of paraspinal textiloma (gossypiboma). *J Comput Assist Tomogr*. 1991 Nov-Dec;15(6):1000–3.
- 17 Roumen RM, Weerdenburg HP. MR features of a 24-year-old gossypiboma. A case report. *Acta Radiol*. 1998 Mar;39(2):176–8.
- 18 Stoll A. Retained surgical sponge 40 years after laminectomy. Case report. *Surg Neurol*. 1988 Sep;30(3):235–6.

- 19 Rossitch E Jr, Bullard DE, Oakes WJ. Delayed foreign-body reaction to silk sutures in pediatric neurosurgical patients. *Childs Nerv Syst.* 1987;3(6):375–8.
- 20 Alleyne CH Jr, Barrow DL. Immune response in hosts with cadaveric dural grafts. Report of two cases. *J Neurosurg.* 1994 Oct;81(4):610–3.
- 21 Siccardi D, Ventimiglia A. Fibrotic-haemorrhagic reaction to synthetic dural substitute. *Acta Neurochir (Wien).* 1995;132(1-3):148–9.
- 22 Iaquinandi A, Corrivetti F, Lunardi P, Ferlosio A, Giannini E, Novegno F. Brain granuloma: rare complication of a retained catheter. Case Report. *World Neurosurg.* 2018 Feb;110:210–6.
- 23 Benedetto N, Gambacciani C, Montemurro N, Morganti R, Perrini P. Surgical management of acute subdural haematomas in elderly: report of a single center experience. *Br J Neurosurg.* 2017 Apr;31(2):244–8.

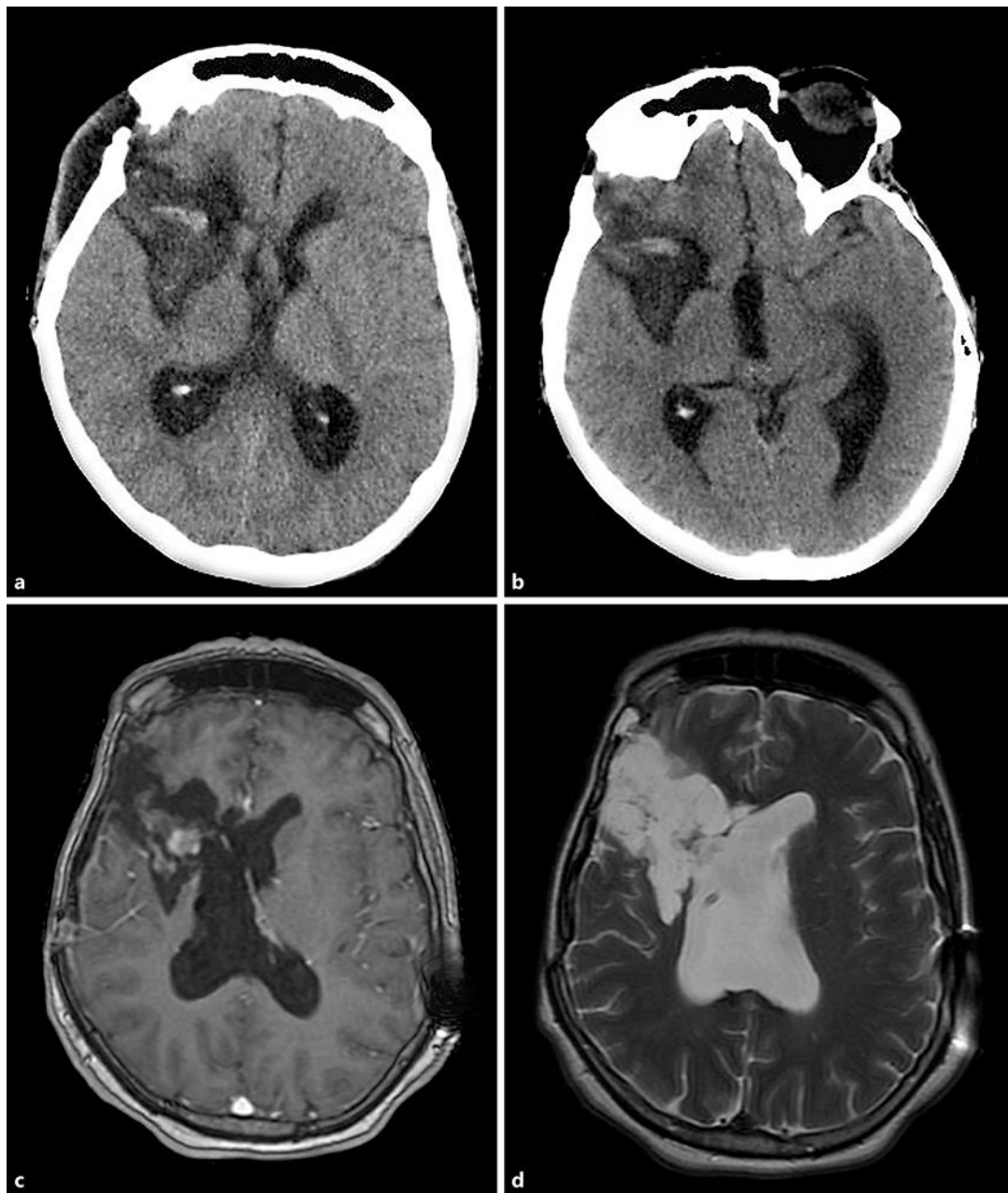


Fig. 1. Postoperative axial CT scan (a) shows a hyperdense mass lesion in the surgical cavity. A follow-up brain CT scan 20 days after surgery (b) shows persistence of the hyperdense mass lesion. Postoperative axial gadolinium-enhanced T1-weighted (c) and axial T2-weighted (d) MRI show enhancement of the textiloma.