

A novel adhesive suture retention device for the closure of fragile skin under tension



Lacey L. Roybal, DO, Collin M. Blattner, DO, John Young, MD, and William Lear, MD
Salem, Oregon

Key words: adhesive retention device; aged skin; fragile skin; Mohs micrographic surgery; tension; wound closure.

INTRODUCTION

The closure of surgical defects in areas with fragile or damaged skin can be challenging. Aged and photodamaged skin is prone to tearing with even minimal tension during the placement of percutaneous sutures.^{1,2} Often dermal sutures cannot be placed given the lack of supportive dermal and subcutaneous tissue. Multiple methods have been previously described in the literature to assist surgeons in the closure of fragile skin.¹⁻⁵ These methods involve cutting dressing materials in various configurations, adhering them to the skin, and suturing through it. When used on larger defects or those under tension, these dressing materials often fail to provide adequate support. Furthermore, they can absorb or trap excessive bodily fluid, which leads to malodor and maceration.

The role for a purpose-driven adhesive device to bolster the skin strength and allow for suturing under tension is appealing. We present 6 cases using the HEMIGARD device, a novel, reinforced adhesive device that was custom designed to reinforce skin, elevate the suture above the skin surface, and be used with a wide variety of suture tensions without tearing or deformation. We find this method allows us to primarily close many wounds that would have otherwise required grafting or second-intent healing.

CASE ONE

An 80-year-old woman presented with invasive squamous cell carcinoma of the right medial knee. She underwent Mohs micrographic surgery (MMS), and the tumor was cleared after a single stage with a resulting 5.0-cm-wide by 3.5-cm-long defect. Options for wound closure were discussed including linear closure, a skin graft, or second-intent healing.

Abbreviations used:

ARD: adhesive retention device
MMS: Mohs micrographic surgery
USP: United States Pharmacopeia

The patient and physician decided on a linear closure. Given the size of the defect with surrounding fragile skin, the decision to use an early prototype of the HEMIGARD adhesive retention device (ARD) (SUTUREGARD Medical, Inc; Portland, OR) was made. The skin around the defect was cleaned with 70% alcohol and let dry. A Cavilon (3M; St. Paul, MN) barrier film was applied. An ARD was applied to the middle portion on each side of the wound. A United States Pharmacopeia (USP) 0 nylon suture with a reverse cutting needle was used to suture through the central holes of the ARD using a simple interrupted pattern (Fig 1). Additional percutaneous simple interrupted percutaneous USP 3-0 nylon sutures were placed to close the rest of the wound (Fig 2). A dressing was placed. The patient was instructed to avoid wetting the ARD but to cleanse the lateral wound portions with soap and water daily and apply petroleum jelly. The ARD and all sutures were removed 2 weeks postoperatively. The skin beneath the reinforced ARD was protected and allowed for complete wound closure. In contrast, the skin adjacent to the ARD, which was sutured without support, failed under the tension of the suture, likely caused by postoperative edema (Fig 3).

CASE 2

A 98-year-old woman presented with invasive squamous cell carcinoma of the left forearm. The

From Silver Falls Dermatology.

Funding sources: None.

Conflicts of interest: Dr Lear is a shareholder in SUTUREGARD (SUTUREGARD Medical, Portland, OR). The rest of the authors have no conflicts to disclose.

Correspondence to: Lacey L. Roybal, DO, 1793 13th St SE, Salem, OR 97302. E-mail: lroybal@silverfallsderm.net.

JAAD Case Reports 2020;6:109-14.

2352-5126

© 2020 by the American Academy of Dermatology, Inc. Published by Elsevier, Inc. This is an open access article under the CC BY-NC-ND license (<http://creativecommons.org/licenses/by-nc-nd/4.0/>).

<https://doi.org/10.1016/j.jidcr.2019.12.010>

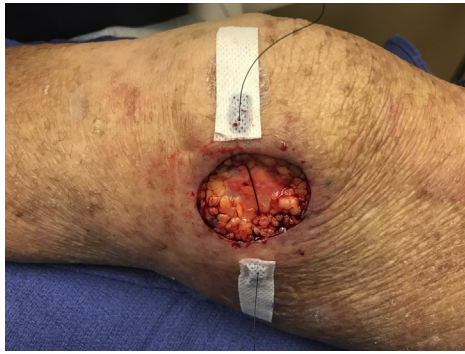

Fig 1. Surgical defect (3.5 cm × 5.0 cm) of the right medial knee. A prototype of the HEMIGARD adhesive retention device was applied to the middle portion with USP 0 nylon suture placed through the device holes.

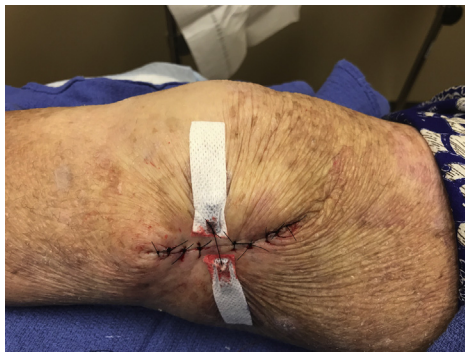

Fig 2. The wound was apposed without damage to skin, and its lateral portions were closed using USP 3-0 nylon simple interrupted sutures.

tumor was cleared after a single stage of MMS, leaving a 3.0-cm-wide by 3.0-cm-long defect. After discussion of closure options, the patient and the physician decided on a linear closure. The wound was closed using the placement of simple interrupted USP 3-0 nylon sutures. However, as a bandage was being applied, it was noted that the skin was tearing where the percutaneous sutures were placed along the central portion of the wound (Fig 4). These sutures were removed, and the skin around the area was cleaned with 70% alcohol and let dry. The damaged skin was not removed. A Cavilon barrier film was applied to the wound edge and allowed to dry for several minutes. An ARD was placed on the torn skin in the center of the defect. The wound was completely approximated using a USP size 0 nylon simple interrupted suture pattern through the ARD (Fig 5). After 14 days of wound healing, the sutures and ARD were removed without evidence of dehiscence.

CASE 3

A 73-year-old man presented with squamous cell carcinoma in situ of his right posterior calf and

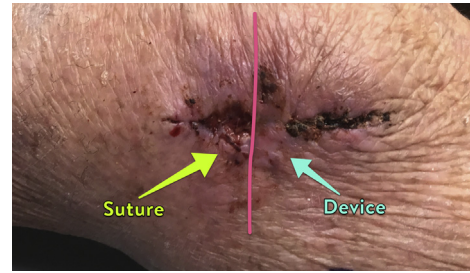


Fig 3. Right medial knee defect after 14 days of wound healing with the HEMIGARD and sutures removed. The yellow arrow indicates the area of skin tearing where the lateral 3-0 nylon sutures were placed. The blue arrow indicates the intact well-approximated skin edge where the HEMIGARD device was placed.

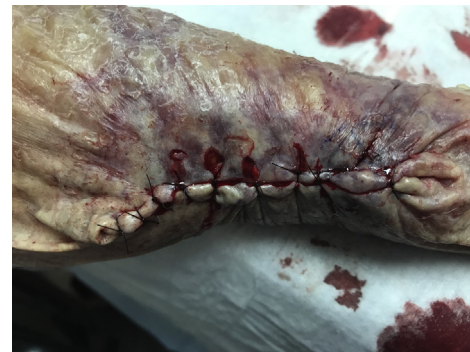

Fig 4. “Cheese wiring” of simple interrupted nylon sutures on the left forearm of a patient with very fragile skin after repair under minimal tension.

nodular basal cell carcinoma of the lateral portion of his right posterior calf. After 1 stage of MMS for each site, the tumors were cleared leaving 2 connecting defects measuring 3.0-cm wide by 5.0-cm long. The patient had a history of chronic lymphocytic leukemia and was immunosuppressed. Options for wound closure were discussed and because of the combination of wound tension and the demonstrated inability of the periwound skin to withstand the tension of sutures, the ARD was used. The skin around the wound was cleaned with 70% alcohol and let dry. A Cavilon barrier film was applied to periwound skin. An ARD was adhered on each side of wound and a USP size 0 nylon suture with a reverse cutting needle was used to suture through the holes of the ARD with a simple interrupted pattern (Fig 6). Additional simple interrupted 3-0 nylon sutures were placed to close the lateral portions of the wound. The patient was instructed to avoid wetting the ARD but to cleanse the lateral wound portions with soap and water and apply petroleum jelly. The ARD and sutures were removed at 21 days postoperatively without evidence of infection or dehiscence.

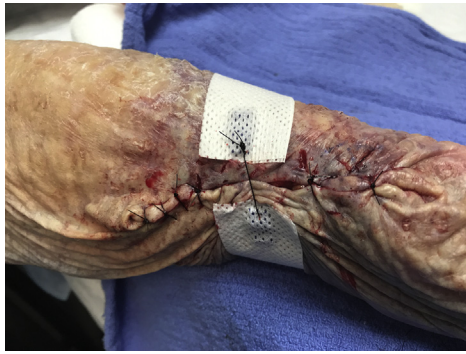

Fig 5. A prototype HEMIGARD adhesive retention device was placed on damaged and nondamaged skin along the central portion of the wound on the left forearm, which had previously ripped under tension. A USP size 0 nylon suture was placed through the center of the device to appose the wound edges. This wound healed without complications.

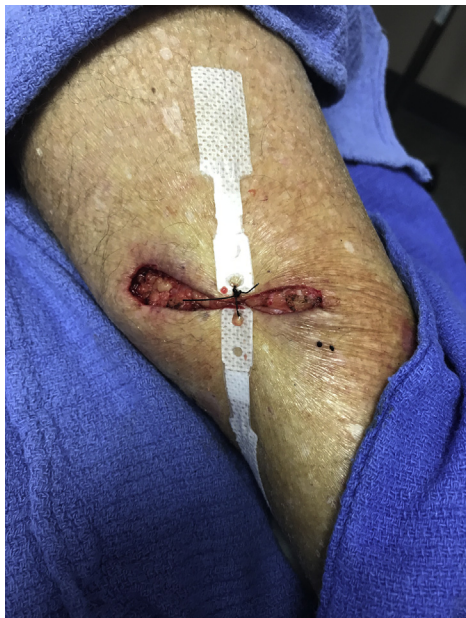

Fig 6. A large (3.0 cm × 5.0 cm) defect on the right calf in an immunocompromised patient. The final iteration of the HEMIGARD adhesive retention device was used to appose the central portion of the defect with USP size 0 nylon suture. The remainder of the defect was closed, and the wound healed well without complication.

CASE 4

A 62-year-old woman presented with nodular basal cell carcinoma on her right lower posterior leg. After 1 stage of MMS, the tumor was cleared, leaving a 2.5-cm-wide by 3.5-cm-long defect. Because of high tension across the area the ARD device was utilized. The skin around the wound was cleaned with 70% alcohol and let dry. Two ARDs were adhered on each side of the wound at the

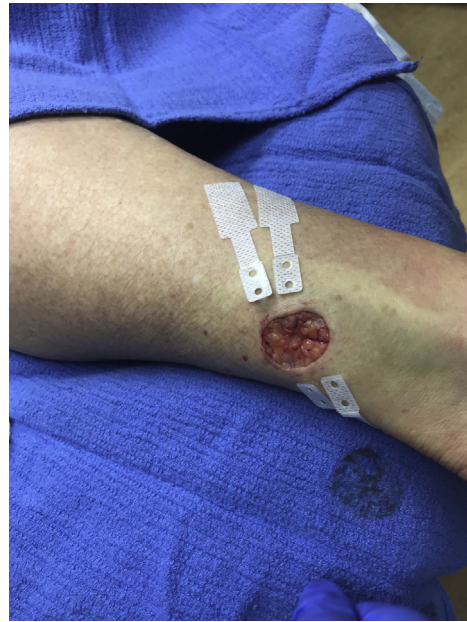

Fig 7. Two HEMIGARD adhesive retention devices are used to close a 2.5 cm by 3.5 cm defect on the right lower posterior leg under high tension.

central portion (Fig 7), and 2 USP size 0 nylon simple interrupted sutures were placed across the ARDs. The lateral portions of the wound were closed with 4-0 Polysorb buried sutures, and 1 Steri-strip was placed on top on each side of the wound for additional support (Fig 8). The nylon sutures and ARDs were removed after 140 days without any dehiscence or complications.

CASE 5

A 71-year-old woman with squamous cell carcinoma on the left anterior shin presented for treatment with MMS. The tumor was cleared after one stage leaving a 3.0-cm-wide x 1.7-cm-long defect. Wound closure options were discussed with the patient, and, given the fragile skin under tension, the decision to use an ARD was made. The skin around the defect was cleaned with 70% alcohol and let dry. An ARD was applied to the middle portion on each side of the wound. The wound was completely approximated using a USP size 0 nylon simple interrupted suture pattern. A buried horizontal mattress Polysorb 4-0 suture was placed using a deep-superficial-superficial-deep pattern (Figs 9 and 10). The ARDs were removed at 14 days, and the wound was well approximated and healing appropriately (Fig 11).

CASE 6

A 68-year-old man with an invasive squamous cell carcinoma on the right pretibial skin presented for

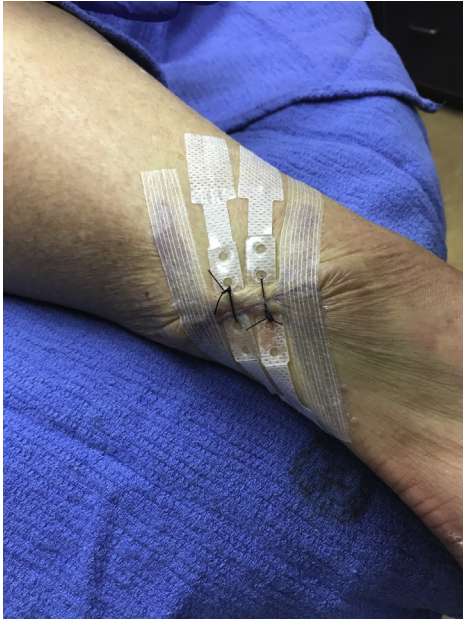

Fig 8. The right lower posterior leg defect apposed with 2 HEMIGARD ARDs with 0 nylon suture. Absorbable 3-0 Polysorb sutures and steri-strips used for remainder of wound closure. The wound healed with excellent cosmesis.

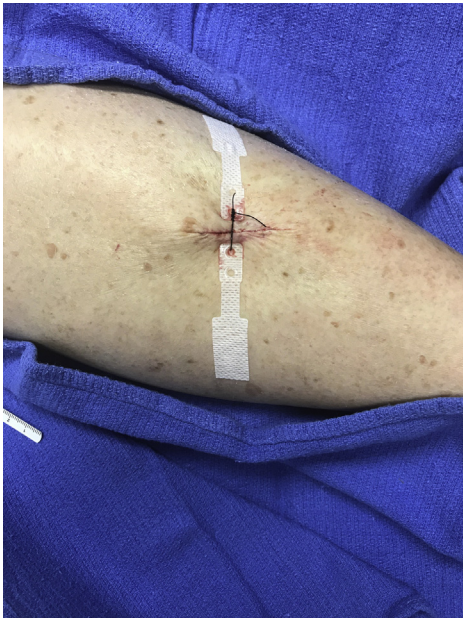

Fig 9. Left anterior shin wound (3.0 cm wide \times 1.7 cm long) apposed using a HEMIGARD ARD with a 0 nylon simple interrupted suture. Buried absorbable 4-0 Polysorb sutures are placed on each side of the defect.

treatment with MMS. The tumor was cleared after 1 stage leaving a defect of 1.8-cm wide by 3.2-cm long. Wound closure options were discussed with the patient, and, given the fragile skin under tension,

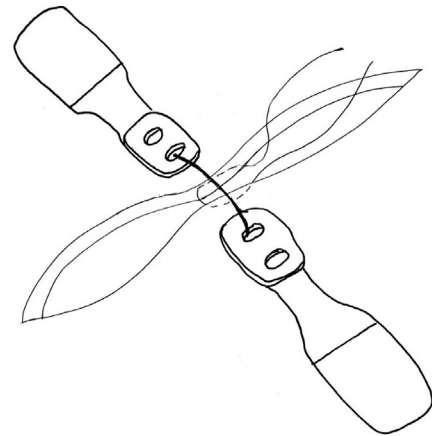


Fig 10. When a simple interrupted suture is used to appose the HEMIGARD ARDs, there is a suture crossing the wound, complicating placement of a central buried absorbable suture. We perform the central buried suture using a deep-superficial-superficial-deep horizontal mattress pattern.

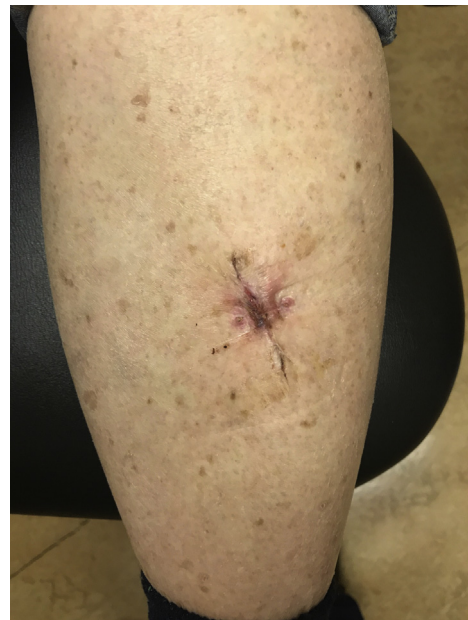

Fig 11. Well approximated left anterior shin defect without complications after 14 days at suture removal.

the decision to use the ARD was made. The skin around the defect was cleaned with 70% alcohol and let dry. An ARD was applied to the middle portion on each side of the wound. The wound was completely approximated using a USP size 0 nylon suture placed using a vertical mattress (far-far-near-near pattern) (Fig 12). This pattern allowed for a vertical buried Polysorb 4-0 suture to be placed between the ARD (Fig 13). Buried Polysorb 4-0 sutures were placed

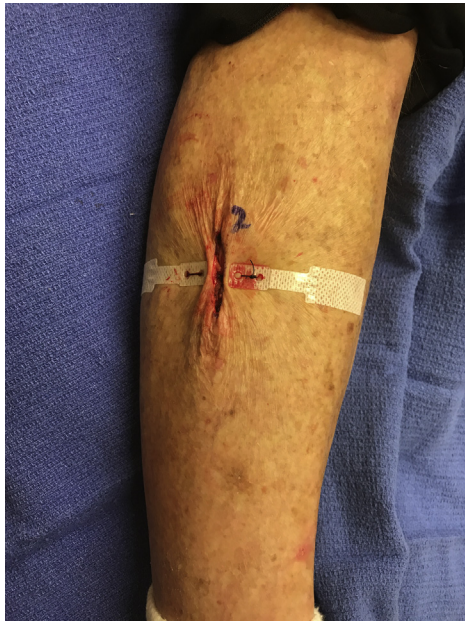

Fig 12. Right pretibial skin defect (1.8 cm wide \times 3.2 cm long) approximated by placing a USP 0 nylon suture in a vertical mattress (far-far-near-near) pattern across the HEMIGARD ARDs.

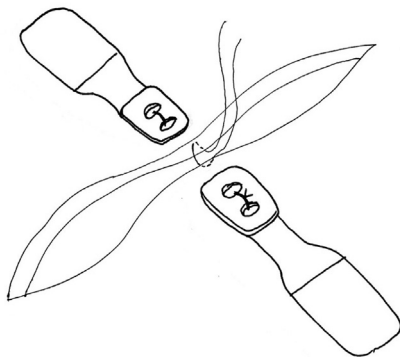


Fig 13. When a vertical mattress suture is used to appose the HEMIGARD ARDs, there is no suture crossing the wound, allowing a standard vertical buried absorbable suture placement.

along the wound and Steri-strips to cover the wound (Fig 14). The ARDs were removed at 14 days, and the wound was well approximated and healing appropriately.

DISCUSSION

Wounds under tension in areas with thin, fragile, or damaged skin are difficult to repair. The dermoepidermal junction in aged skin flattens by

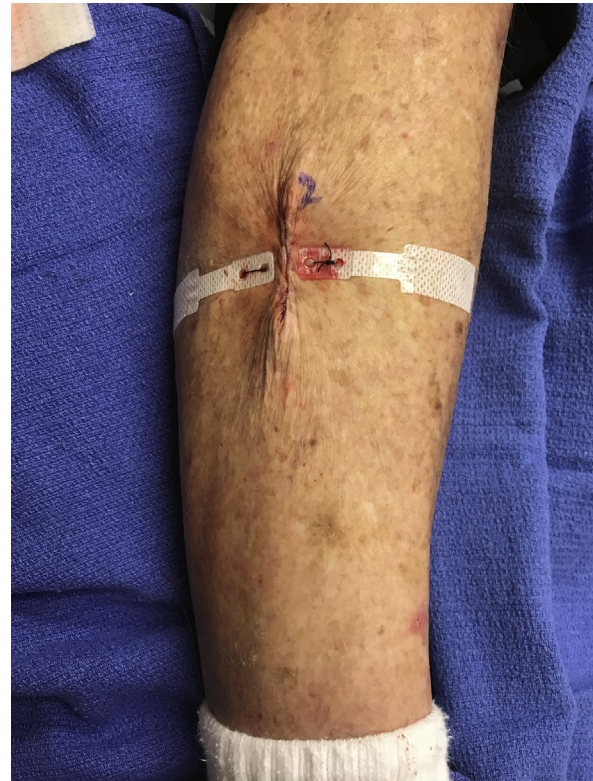

Fig 14. Final sutured right pretibial skin defect after additional absorbable 4-0 Polysorb sutures are placed to close the lateral portions of the wound.

more than one-third, making it more vulnerable to shearing forces.⁶ With age there is an overall loss of subcutaneous fat, and the dermis becomes thinner with an associated reduction in collagen turnover and an increase in the degradation of elastic fibers. These changes result in a higher susceptibility to tear-like injuries.⁶ Other factors that contribute to thinning of the skin include actinic damage, collagen disorders, and medications including immunosuppressive agents and corticosteroids. Intraoperatively, the placement of sutures often results in “cheesewiring” of the fragile skin under tension. Postoperatively, edema and swelling may increase the tension past the fracture point of the skin with subsequent tearing of skin closed by sutures.

Previous methods have been described to support wound closure in patients with fragile skin. Most of these methods involve application of supportive dressings to the top of the epidermis near the wound edge to increase tensile strength or act as an additional layer on the skin surface to reduce tearing with suturing. Reported materials used include Fixomull (BSN Medical, Inc, Hamburg, Germany), Steri-strips, polyethylene film with an acrylate adhesive, and a hydrocolloid dressing.¹⁻⁵ Hydrocolloids and film dressing can trap excessive moisture

beneath them resulting in wound maceration. When used alone, nonwoven polyester (eg, Fixomull) will absorb excessive fluid and can lead to malodor and poor dressing hygiene. Most importantly, use of these materials will not prevent initiation of fracturing of the skin. Once this fracture has been initiated, further propagation will ensure much more readily, potentially leading to skin failure.

The HEMIGARD is composed of 3 zones: (A) a water-resistant rigid, elevated wound end zone with 2 holes to accept and withstand the forces of a high-tension nonabsorbable simple interrupted or vertical mattress suture; (B) a less-rigid and nonelevated water-resistant middle zone; and (C) the least rigid zone with monolayer of stretchy nonwoven polyester. Zone A provides a rigid leading wound edge that resists fracture initiation and elevates the suture above the skin surface. Zone B provides a waterproof and rigid zone to transmit the force of wound closure further away from the wound edge. Zone C reduces shear forces from higher tension wound closures to reduce blistering in the trailing edge.

The HEMIGARD ARD was designed to have a lower breathable layer of nonwoven polyester to absorb sweat and a nonabsorbent top layer of polyethylene to resist fluid absorption and allow for improved and simpler wound hygiene. However, we instruct patients to avoid frequent soaking of the portion of the wound with the HEMIGARD ARDs. In the event of soaking, the patient is to leave the ARD open to air dry prior to covering. If the lateral (zone C) starts to lift off the skin, then it can be reinforced with additional nonwoven polyester dressing or similar. It can be retained up to 2 weeks, at which point there is adequate wound strength without external support. This 2-week duration may be similar to the mechanical benefit of the most common absorbable suture, polyglactin 910.⁷ In 3 of the 5 cases presented, the HEMIGARD ARD was used to close wounds without absorbable buried sutures and provided 2 full weeks of mechanical support to the wound without subsequent wound dehiscence or other healing complications.

In cases in which use of buried dermal sutures is possible and desired, the use of the HEMIGARD ARD can limit the use of percutaneous sutures for aesthetic reasons. For example, in 3 of the cases in this report, the only percutaneous sutures were those used for the HEMIGARD ARD. Remaining skin supports were buried absorbable sutures and

Steri-strips. This punctureless method has the potential to decrease “train tracking” in that the HEMIGARD ARD both elevates the percutaneous suture above the skin and bears most of the tension with a nonabsorbable large-caliber suture. In cases with more wound tension, more than 1 pair of HEMIGARD ARD can be used to effect closure, as documented in one of the cases in this report.

In our cases, we repaired both intact skin and previously damaged skin under tension with the novel HEMIGARD ARD. In our practice, the use of the HEMIGARD ARD has allowed for primary closure of high-tension wounds in challenging patients, where it significantly improved wound closure and cosmetic outcomes without any significant wound complications. Use of the device also reduces the need for more complex and expensive options for such wounds. Skin flaps are rarely performed on extremities because of poor vasculature. Skin grafts require additional surgical sites for donor skin and, on lower extremity, often fail to survive. Second-intent wound healing can often take months on the lower extremity, and, increasingly, there are myriad advanced and expensive wound products being deployed to speed the healing of such wounds.⁸ The HEMIGARD ARD provides a simple, inexpensive method using commonly available and widely performed suturing techniques to prevent the need for such solutions. Further research will be valuable to explore the cosmetic and functional outcomes of its use.

REFERENCES

1. Foster RS, Chan J. The Fixomull skin support method for wound closure in patients with fragile skin. *Australas J Dermatol*. 2011; 52:209-211.
2. Lipnik MJ. A Novel Method of Skin Closure for Aging or Fragile skin. *Cutis*. 2015;96:260-262.
3. Davis M, Nakhdjevani A, Lidder S. Suture/steri-strip combination for the management of lacerations in thin-skinned individuals. *J Emerg Med*. 2011;40:322-323.
4. Mazzurco JD, Krach KJ. Use of a hydrocolloid dressing to aid in the closure of surgical wounds in patients with fragile skin. *J Am Acad Dermatol*. 2012;66:335-336.
5. Pacifico M, Teixeira R, Ritz M. Suturing of fragile skin. *J Plast Reconstruct Aesthet Surg*. 2009;62:e637-e638.
6. Farage MA, Miller KW, Elsner P, Maibach HI. Characteristics of the aging skin. *Adv Wound Care*. 2013;2:5-10.
7. Townsend KL, Lear W, Robertson BL, Krusic JJ. Buried absorbable polyglactin 910 sutures do not result in stronger wounds in porcine full thickness skin incisions. *J Mech Behav Biomed Mat*. 2016;63:386-389.
8. Abdel-Sayed P, Hirt-Burri N, Roessingh ADB, Raffoul W, Applegate LA. Evolution of biological bandages as first cover for burn patients. *Adv Wound Care*. 2019;8:555-564.