

CONTRIBUTION TO THE ANATOMICAL STUDY OF THE CORTICOPERIOSTEAL FLAP OF THE MEDIAL FEMORAL CONDYLE

Rômulo Guimarães Andrade¹, Henrique Gubert Bufáçala¹, Leandro Alves de Oliveira¹, Fabiano Inácio de Souza², Mário Yoshihide Kuwae³, João Alfrío Teixeira da Silva Júnior⁴

ABSTRACT

Objective: to perform the anatomical study, in cadavers, of the corticoperiosteal flap of the medial femoral condyle, based on the medial genicular artery, evaluating challenges in dissection and the topographic patterns. **Materials and methods:** fifteen limbs from eight cadavers were studied, ages ranging from 19 to 74 years old. They were placed at supine position, and a longitudinal incision on the medial face of the lower part of the thigh was performed, exposing medial vastus and sartorius muscles, with descendent genicular vessels being also exposed. The distance between the descendent genicular artery and the medial articular line of the knee, the diameter of the vessel, the length of the pedicle, and the presence of the fasciocutaneous

branch and its location were analyzed. **Results:** the distance between the origin of the descendent genicular artery and the medial articular line of the knee ranged from 11.2cm to 14.5cm, with an average of 12.63cm. The mean artery diameter was 2.5mm (from 2.25mm to 2.75mm). The distance between the descendent genicular artery and the fasciocutaneous branch ranged from 1.0 to 1.5cm. The mean length of the vascular pedicle was 7.01cm, ranging from 5.6cm to 8.6cm. **Conclusion:** the corticoperiosteal flap of the medial femoral condyle of the knee is easy to dissect, presents a constant vascular pedicle, with average length of 7.0cm and diameter of 2.5mm, enabling it to be indicated for microsurgical transplants.

Keywords – *Cadaver; Anatomy; Microsurgery*

INTRODUCTION

Traumatic injuries of the upper and lower limbs can lead to many consequences, among them pseudarthrosis, which are very difficult to treat.

There are several methods for the treatment of pseudarthrosis, from the use of synthetic materials such as compression plates, numerous types of external fixators, to intramedullary nailing, usually associated with avascular bone grafts, resulting in successful treatment in most cases.

In patients that do not progress satisfactorily, vascularized bone grafts can be indicated, as proposed by Östrup and Fredrickson⁽¹⁾, achieving good results, with the vascularized fibula graft being the most widely used, although it is difficult to dissect and can potentially cause instability in the donor segment^(1,2).

The objective of this work is the anatomical cadaver study of the corticoperiosteal flap of the medial femoral condyle based on the medial genicular artery, assessing the difficulty of dissection and topographic patterns.

1 – Third-year Resident of Orthopedics and Traumatology, HC-FM-UFG, Goiás, Brazil.

2 – Master's degree in Orthopedics, Department of Orthopedics, School of Medicine, USP, Goiás, Brazil.

3 – Head, Hand and Microsurgery Group, Department of Orthopedics, HC-FM-UFG, Goiás, Brazil.

4 – Head, Department of Orthopedics, Traumatology and Plastic Surgery, HC-FM-UFG, Goiás, Brazil.

Study conducted at the Department of Orthopedics and Traumatology and Plastic Surgery, Hospital das Clínicas, School of Medicine, Universidade Federal de Goiás. Correspondence: Hospital das Clínicas, Departamento de Ortopedia e Traumatologia, Primeira Avenida, s/n, Setor Universitário – 74605-020 – Goiânia-GO. E-mail: fabianoinacio@hotmail.com

We declare no conflict of interest in this article

METHODS

Were used 15 limbs (eight cadavers) from the Institute of Forensic Medicine of the State of Goiás for dissection, in the period between April and July 2007.

The age of the cadavers ranged from 19 to 74 years, five males and three females with heights between 1.64 m and 1.83 m.

The cadavers were placed in a supine position with one of the lower limbs in external rotation (Figure 1). We performed a longitudinal incision on the medial side of the lower third of the thigh (Figure 2). The fascia was incised in the same direction, exposing the vastus medialis (folded anteriorly), the sartorius (folded posteriorly), and we visualized the descending genicular vessels (Figures 3 and 4). These vessels arise from the femoral artery, distal to the adductor hiatus, and branch on the periosteum of the medial femoral condyle (Figure 5).

The distance between the origin of the descending genicular artery and medial knee interline, the vessel diameter, the length of the pedicle, and the presence of the fasciocutaneous branch and its location were all measured. To obtain these measures, we used an engineer's scale (Trident® No. 2, model 7830/1).

RESULTS

The average height of the cadavers was 1.67 m for females (ranging from 1.64 m to 1.71 m) and 1.75 m for males (1.68 m to 1.83 m).

The distance between the origin of the descending genicular artery and medial interline of the knee ranged from 11.2 cm to 14.5 cm, with an average of 12.63 cm. The artery average diameter was 2.5 mm (2.25 mm to 2.75 mm). The distance between the origin of the descending genicular artery and the fasciocutaneous branch ranged between 1.0 and 1.5 cm. This branch was absent in two cases. The average length of the vascular pedicle between the femoral artery and the periosteum of the medial condyle, was 7.01 cm, ranging from 5.6 to 8.4 cm (Table 1).

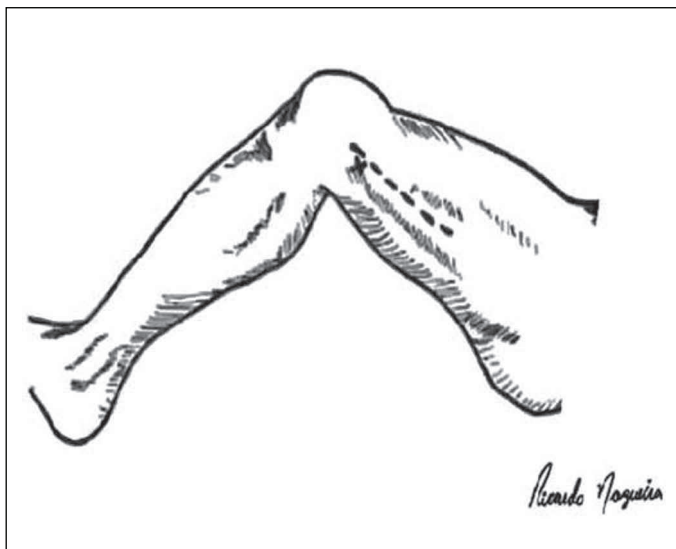


Figura 1 – Posicionamento do membro e local da incisão

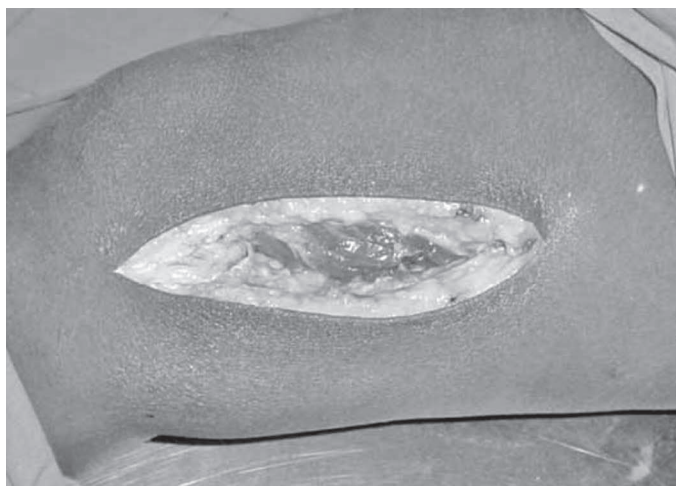

Figura 2 – Incisão na pele e subcutâneo

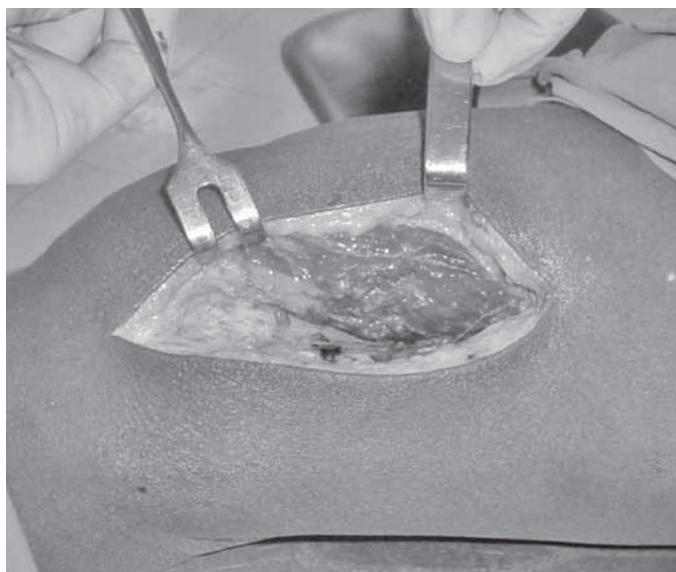


Figura 3 – Afastamento anterior do vasto medial

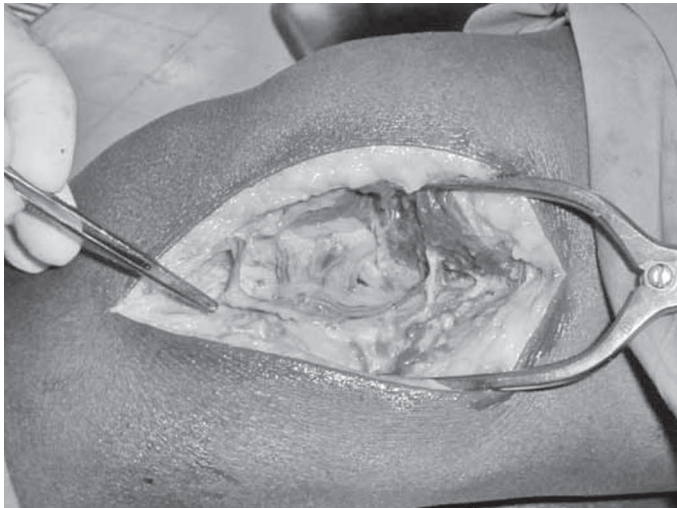


Figure 4 – Exposure of the pedicle and its branches.

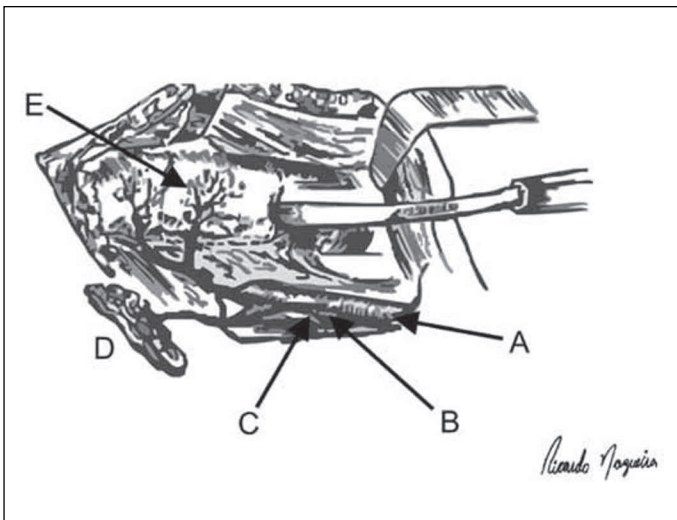


Figure 5 – Diagram of anatomical structures. A: femoral artery. B: origin of the genicular artery. C: tendon of the adductor magnus. D: fasciocutaneous branch.

DISCUSSION

Based on studies by Östrup and Fredrickson⁽¹⁾ and Finley *et al.*⁽²⁾, which showed the good osteogenic capacity of periosteal and bone microsurgical flaps, Sakai *et al.*⁽⁴⁾ proposed a new corticoperiosteal flap, dissected in the medial condylar and supracondylar regions of the femur.

In 1989, Masquelet *et al.*⁽⁵⁾ published the anatomical basis of the periosteal flap, describing the region of the medial femoral condyle as a possible donor site. The corticoperiosteal flap of the medial condyle of the knee is based on the medial vascular geniculate bundle, a branch of the femoral artery.

Table 1 – Measurement of the data collected.

Limb	Height (m)	Distance between genicular artery and medial interline (cm)	Vessel diameter (mm)	Origin of the cutaneous branch (cm)	Length of pedicle (cm)
1	1.64	11.2	2.5	1.2	5.6
2	1.64	11.3	2.5	1.1	5.8
3	1.67	11.7	2.25	1.1	6.1
4	1.67	11.7	2.5	1.3	6.2
5	1.71	12.3	2.5	1.2	6.3
6	1.71	12.5	2.5	1.3	6.4
7	1.68	12.1	2.5	1.0	6.1
8	1.68	11.9	2.25	Absent	6.0
9	1.72	12.5	2.5	1.4	7.5
10	1.72	12.9	2.75	1.1	7.6
11	1.75	13.6	2.75	Absent	8.3
12	1.75	13.4	2.25	1.3	8.4
13	1.79	13.8	2.75	1.4	7.9
14	1.79	14.1	2.5	1.3	8.4
15	1.83	14.5	2.5	1.5	8.6

Source: DOT-HC-FMUFG.

In this study, the average diameter of the artery was 2.5 mm, falling within the limits of 1.5 and 3.8 reported by other authors^(4,6,7).

The length of the pedicle also ensures the viability of the procedure because the average length (7.0 cm) provides alternatives for mobility and spatial arrangement of the receiving area.

The constant origin of the medial genicular artery, with an average distance of 12.63 cm from the medial knee interline, provides safety during the execution of preoperative planning.

These data are in agreement with the literature. However, other authors do not mention the anatomical arrangement of the fasciocutaneous branch emitting from the medial genicular artery. In 86.6% of cases, this branch emerges between 1.0 and 1.5 cm from the origin of the genicular artery. In two cases (13.4%), the fasciocutaneous branch emerged directly from the femoral artery.

The importance of understanding this branch arises from the possibility of including a fasciocutaneous segment in a corticoperiosteal flap, where it could be used as a skin monitor or to stabilize adjacent soft tissues.

The clinical application of the corticoperiosteal flap of the medial femoral condyle has been described by some surgeons in the treatment of various types of pseudarthrosis.

While Doi *et al.*⁽⁶⁾ demonstrated 80% good results in pseudarthrosis of the scaphoid, Kobayashi *et al.*⁽⁸⁾ reported favorable results in periorbital lesions.

Fuchs *et al.*⁽⁹⁾ obtained good results in treating patients with pseudarthrosis of the clavicle and stress that the use of a vascularized flap is technically easier, faster, and results in less morbidity at the donor site compared with the fibular flap.

There are also reports of good results in the treatment of pseudarthrosis of the distal humerus⁽¹⁰⁾ and distal tibia⁽¹¹⁾.

Choudry *et al.*⁽¹²⁾ emphasize that the corticoperiosteal flap of the medial femoral condyle is the best indication for the treatment of recurrent pseudarthrosis smaller than 5.0 cm.

An anatomical understanding is the basis for greater safety in surgical procedures, especially in promising techniques that have scarcely been disseminated.

CONCLUSION

The corticoperiosteal flap of the medial femoral condyle of the knee is easy to dissect, has a constant vascular pedicle, with an average length of 7.0 cm and a diameter of 2.5 mm, which allows for it to be indicated in microsurgical transplants.

REFERENCES

1. Östrup LT, Fredrickson JM. Distant transfer of a free living bone graft by microvascular anastomoses: an experimental study. *Plast Reconstr Surg.* 1974;54(3):274-85.
2. Finley JM, Acland RD, Wood MB. Revascularized periosteal grafts: A new method to produce functional new bone without bone grafting. *Plast Reconstr Surg.* 1978;61(1):1-6.
3. Sakai K, Doi K, Tamaru K, Yamamoto M, Kawai S. Free Vascularized bone and periosteal graft for pseudoarthrosis in the upper limb. *J Jpn Soc Surg Hand.* 1988;5:698-704.
4. Sakai K, Doi K, Kawai S. Free vascularized thin corticoperiosteal graft. *Plast Reconstr Surg.* 1991;87(2):290-8.
5. Masquelet AC, Penteado CV, Romana MC, Chevrel JP. Periosteal flaps: anatomical bases of sites of elevation. *Surg Radiol Anat.* 1990;12(1):3-7.
6. Doi K, Oda T, Soo-Heong T, Nanda V. Free vascularized bone graft for nonunion of the scaphoid. *J Hand Surg Am.* 2000;25(3):507-19.
7. Masquelet AC, Hertel R. The reverse flow medial knee osteoperiosteal flap for skeletal reconstruction of the leg. Description and anatomical basis. *Surg Radiol Anat.* 1989;11(4):257-62.
8. Kobayashi S, Kakibuchi M, Masuda T, Ohmori K. Use of vascularized corticoperiosteal flap from the femur for reconstruction of the orbit. *Ann Plast Surg.* 1994;33(4):351-7.
9. Fuchs B, Steinman SP, Bishop AT. Free vascularized corticoperiosteal bone graft for the treatment of persistent nonunion of the clavicle. *J Shoulder Elbow Surg.* 2005;14(3):264-8.
10. Kakinoki R, Ikeguchi R, Nakayama K, Yamakawa T, Morimoto M, Nakamura T. Treatment of avascular necrosis of the capitulum of the humerus using a free vascularized osteoperiosteal graft from the medial condyle of the femur: a case report. *J Shoulder Elbow Surg.* 2008;17(1):e1-4.
11. Cavadas PC, Landin L. Treatment of recalcitrant distal tibial nonunion using the descending genicular corticoperiosteal free flap. *J Trauma.* 2008;64(1):144-50.
12. Choudry UH, Bakri K, Moran SL, Karacor Z, Shin AY. The vascularized medial femoral condyle periosteal bone flap for the treatment of recalcitrant bony nonunion. *Ann Plast Surg.* 2008;60(2):174-80.