

Case Report

Successful percutaneous flexible ureteroscopy for treatment of distal ureteral stones under modified Valdivia position after Cohen reimplantation

Takaaki Inoue,^{1,2}  Fukashi Yamamichi,² Takahito Endo,² Yasuhiro Kaku,³ Mikito Horikoshi,² Shoji Hara² and Masato Fujisawa³

¹Department of Urology, Kansai Medical University, Osaka, ²Department of Urology, Hara Genitourinary Hospital, and ³Division of Urology, Department of Surgery, Kobe University Graduate School of Medicine, Hyogo, Japan

Abbreviations & Acronyms

CT = computed tomography
fURS = flexible ureteroscope
HU = Hounsfield units
KUB = kidney, ureter, and bladder
UAS = ureteral access sheath
VUR = vesicoureteral reflux

Correspondence: Takaaki Inoue M.D., Ph.D., Department of Urology, Hirakata Hospital, Kansai Medical University, Hirakata Shinmachi 2-3-1, Hirakata, Osaka 573-1191, Japan. Email: inouetak@harahospital.jp

This is an open access article under the terms of the Creative Commons Attribution-NonCommercial License, which permits use, distribution and reproduction in any medium, provided the original work is properly cited and is not used for commercial purposes.

Received 18 February 2019; accepted 16 April 2019.
Online publication 8 May 2019

Introduction: Endoscopic retrograde access to the upper urinary tract after Cohen reimplantation for the treatment of vesicoureteral reflux in children is usually difficult.

Case presentation: We experienced a case involving a few large ureteral stones in the right distal ureter after Cohen reimplantation. We initially failed retrograde access using flexible cystoscope. Therefore, we performed antegrade flexible ureteroscopy through the 10- to 12-Fr access sheath from the middle calyx to treat the few ureteral stones (>1.5 cm) in the right ureter with the patient in the modified Valdivia position. This one-stage procedure was successful. The patient achieved a stone-free status without major complications.

Conclusion: The herein-described approach that was implemented after Cohen reimplantation was successful. We believe that recent endourologic developments contributed to the good outcome in this case.

Key words: Cohen reimplantation, disposable flexible ureteroscope, percutaneous antegrade approach.

Keynote message

Antegrade flexible ureteroscopy after Cohen reimplantation is impressive access and procedure to acquire stone-free status.

Introduction

Cohen reimplantation is a cross-trigonal technique first described by Cohen in 1975 for the treatment of children with VUR. The ureter is tunneled cross-trigonally within the posterior wall of the bladder to exit in the contralateral bladder.¹ Therefore, if a patient requires a diagnostic or therapeutic approach to the upper urinary tract for urolithiasis at an older age, treatment of urothelial cancer, or treatment of ureteral stenosis, it is not easy to access the involved lesion site in the upper urinary tract.

The present report describes a patient who developed a few large stones in the right distal ureter after having undergone Cohen reimplantation for VUR 23 years previously. First, we performed percutaneous antegrade flexible ureteroscopy with access sheath for the right distal ureteral stones with the patient in the modified Valdivia position.

Case presentation

We experienced a case involving a young woman with a few large ureteral stones in the right distal ureter. The patient was 29 years old (height, 160.5 cm; weight, 49.9 kg; body mass index, 19.4 kg/m²) and had a medical history of bilateral Cohen reimplantation for VUR at 6 years of age. She visited to our hospital because of a 1-month history of a frequently occurring high fever. Imaging studies including KUB radiography, intravenous pyelography, and CT revealed a few large ureteral stones measuring 1.5 × 1.2 cm (992 HU), 1.5 × 1.2 cm

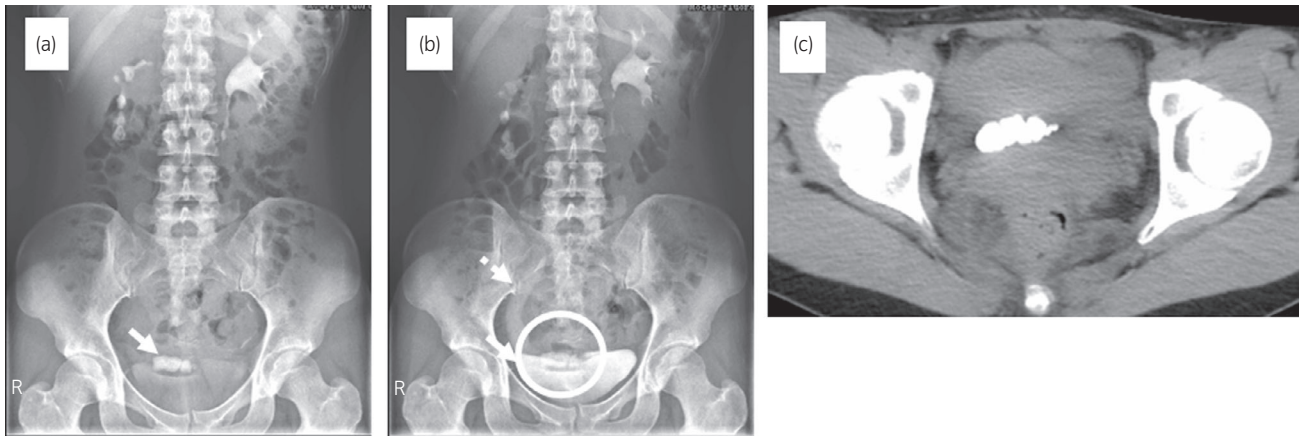


Fig. 1 Intravenous pyelography (a), (b), and CT radiography at pre-operation (c). The arrow and circle reveal right ureteral stones in distal ureter after Cohen procedure for VUR 23 years ago. The dotted arrow indicates a right hydronephrer.

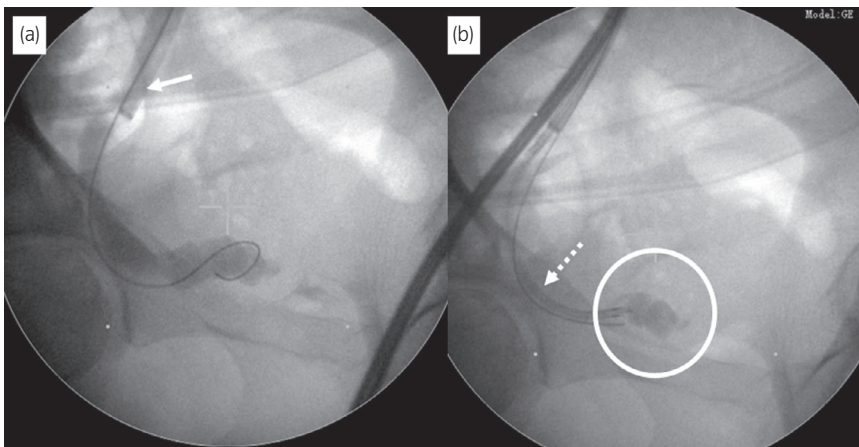


Fig. 2 Fluoroscopic image obtained during antegrade fURS access for the right ureteral stones. (a) The arrow shows the 10- to 12-Fr access sheath in the right ureter. (b) The dotted arrow and circle indicate the fURS and ureteral stones, respectively.

(1072 HU), and 1.4×1.3 cm (1008 HU) with mild hydronephrosis in the right distal ureter (Fig. 1). We might discuss the difficulty of the retrograde ureteral approach because of the patient's history of a bilateral cross-trigonal procedure. Therefore, we initially planned to carry out the percutaneous antegrade approach using flexible ureteroscopy for treatment of the right distal ureteral stones if we were unable to retrogradely insert a guide wire to the ureteral orifice using a flexible cystoscope.

First, we treated the distal ureteral stones with the patient in the modified Valdivia position under general anesthesia. As we expected, the initial attempt to localize the right ureteric orifice by cystoscopy failed because of severe edema of the ureteral orifice and the difficult angle for guide wire insertion. Therefore, we percutaneously punctured the middle renal calyx. A guide wire was passed down the right ureter, but it did not pass through the stones and advance into the bladder. We then inserted a 10- to 12-Fr UAS (UROPASS; Olympus, Tokyo, Japan) to the distal ureter over the guide wire. We advanced a reusable fURS (URF-P6; Olympus) through the UAS to access the target stones (Fig. 2). After reaching the stones, we disintegrated them using a holmium laser (VersaPulse PowerSuite 120; Lumenis, Dreieich, Germany) with the dusting effect (0.3–0.5 J, 20–40 Hz) and then

retrieved as many stone fragments as possible. Finally, the guide wire was passed into the bladder. A 6-Fr ureteral stent into right ureter and 10-Fr nephrostomy tube in right kidney were then antegradely placed. The operative time was 123 min. Although the patient had no postoperative complications, we found that the reusable fURS was damaged. The minor leak in working channel from the tip of fURS was found during reprocessing of scope after procedure.

The patient had stone-free status on KUB in postoperative day 1 (Fig. 3). The patient was discharged on postoperative day 4. The stone components were 97% calcium phosphate and 3% calcium oxalate.

Discussion

In the present case, we successfully performed percutaneous antegrade flexible ureteroscopy with access sheath for treatment of distal ureteral stones with the patient in the modified Valdivia position after bilateral Cohen reimplantation.

The incidence of urolithiasis after ureteroneocystostomy in childhood is rare at 0.06%. The incidence of urolithiasis after Cohen reimplantation is even more uncommon at 0.02%.² As this population gets older, they will be an age group at higher risk for stone formation. Achieving ureteric access for

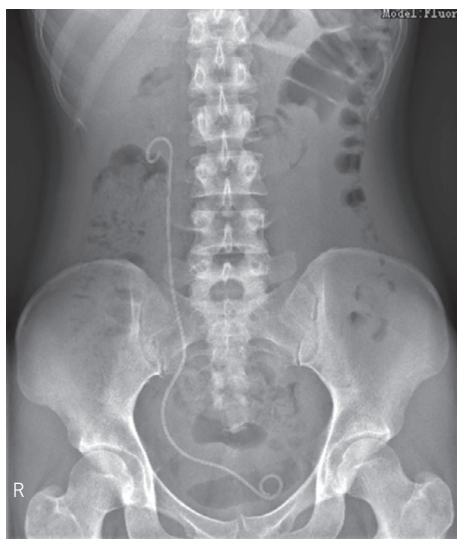

Fig. 3 Kidney, ureter, and bladder radiography on postoperative day 1.

treatment is not easy when a patient with a history of Cohen reimplantation has symptoms due to upper urinary tract stones. Some investigators had some challenges of retrograde approach for patients postoperative Cohen reimplantation like inserting a catheter through a supra-pubic tract under cystoscopic vision, using a curved-tip angiographic catheter or cobra head catheter under cystoscopic guidance (Table 1). Conversely, percutaneous antegrade approach for such a patient was limited. We selected the percutaneous antegrade approach using a fURS with UAS for the distal ureteral stones in this case because of failed retrograde insertion of the guide wire to the ureteric orifice by using flexible cystoscope. To the best of our knowledge, only seven reported cases, including the present case, have utilized the percutaneous antegrade approach after Cohen reimplantation.

However, the case used a fURS with UAS antegradely for treatment of distal ureteral stones under modified Valdivia position is only our case. This technique due to recent endourological developments is easy to access to the target stones. On the other hand, antegrade flexible access through percutaneous tract is so tough because of steep angle between each renal calyx and ureter, especially lower pole and ureter. Therefore, the surgeon needs complicated manipulation of flexible ureteroscopy compared with usual retrograde access even if expert in endourology. Especially, it is one of the most difficult approaches in complicated anatomical case like postoperative Cohen reimplantation. Consequently, the flexible ureteroscopy may be easily damaged. In present case, we had the minor leak in working channel from the tip of fURS after procedure. We wonder if that is why the resistance for reusable fURS often occurred due to much steep angle when the scope is inserted from tip of access sheath to distal ureter. And then, we inserted laser fiber into working channel with slight deflection. Therefore, we will recommend single-use ureteroscopy will be better choice and management option in complicated case like this patient. If we could pass the stiffness guide wire into bladder through the target stones antegradely in present case, we think that it may be possible to approach retrogradely using semi-rigid ureteroscope because the ureter become straight. Anyway, we succeeded percutaneous flexible ureteroscopy through the UAS with safety for treatment of distal ureteral stones under modified Valdivia position after Cohen reimplantation.

Conclusion

We experienced a case involving some large stones >1.5 cm in the right distal ureter after Cohen reimplantation in childhood. We successfully performed percutaneous antegrade flexible ureteroscopy with ureteral access sheath for treatment of the distal ureteral stones with the patient in the modified

Table 1 Summary of previous methods to access upper urinary tract after Cohen reimplantation

	Approach	Patients (n)	Specification of technique
De Castro ⁴	Retrograde	1	Supra-pubic needle inserted opposite the ureter under endoscopic vision
Lamesh ⁵	Retrograde	5	Trocar was inserted from transverse supra-pubic and then ureteral catheter was inserted into the ureter endoscopically
Argueso ⁶	Retrograde	1	Retrogradely inserted guide wire under cystoscopic guidance with 5-Fr cobra head catheter
Santarosa ⁷	Retrograde	1	Supra-pubic puncture was done and then guide wire was inserted endoscopically
Wallis ⁸	Retrograde	6	Retrogradely inserted guide wire under cystoscopic guidance with curved tip vascular access catheter and angle-tipped glide wire
De Castro ⁹	Retrograde	13	Supra-pubic retrograde ureteral catheterization under cystoscopic guidance
Lusuardi ¹⁰	Retrograde	8	Retrogradely inserted Tiemann ureteral catheter under cystoscopic guidance. And then fURS is passed to the stone
Khalil ¹¹	Retrograde	1	Retrogradely inserted curved guide wire into the ureteral orifice and then inserted fURS
Adam ³	Retrograde	1	Supra-pubic puncture was done and guide wire was inserted under cystoscope with grasping forceps
Emiliani ¹²	Retrograde	3	7-Fr angled orifice catheter and angled stiff wire is used for first access. Placed 10-/12-Fr UAS and used single-use fURS
Rich ¹³	Antegrade	1	Antegradely inserted guide wire into the bladder and dilated distal ureter
Chaudhary ¹	Antegrade	1	Antegradely inserted guide wire and placed ureteral stent, and then retrograde transurethral URS was done at 4 weeks later
Krambeck ²	Antegrade	4	Antegradely inserted guide wire and then performed three percutaneous nephrolithotomy, one placement of ureteral stent
Our case	Antegrade	1	Antegradely inserted 10-12 Fr UAS through middle calyx to distal ureteral and then, fURS was inserted through UAS

Valdivia position. We believe that recent endourologic developments contributed to the good outcome in this case.

Acknowledgment

We thank Angela Morben, DVM, and ELS from Edanz Group (www.edanzediting.com/ac), for editing a draft of this manuscript.

Conflict of interest

The authors declare no conflict of interest.

References

- 1 Chaudhary S, Lee M, Andrews HO *et al*. Ureterolithiasis after Cohen re-implantation – case report. *BMC Urol*. 2004; **4**: 1–2.
- 2 Krambeck AE, Gettman MT, BaniHani AH *et al*. Management of nephrolithiasis after Cohen cross-trigonal and Glenn-Anderson advancement ureteroneocystostomy. *J. Urol*. 2007; **177**: 174–8.
- 3 Adam A. A simple and novel method to attain retrograde ureteral access after previous Cohen cross-trigonal ureteral reimplantation. *Curr. Urol*. 2017; **11**: 42–7.
- 4 De Castro R, Ricci S. Catheterization of the ureter after anti-reflux reimplantation using the Cohen technique. *Pediatr. Med. Chir*. 1981; **3**: 67–70.
- 5 Lamesch AJ. Retrograde catheterization of the ureter after antireflux plasty by the Cohen technique of transverse advancement. *J. Urol*. 1981; **125**: 73–4.
- 6 Argueso LR, Kelalis PP, Patterson DE. Strategies for ureteral catheterization after antireflux surgery by the Cohen technique of transverse advancement. *J. Urol*. 1991; **146**: 1583–4.
- 7 Santarosa RP, Hensle TW, Shabsigh R. Percutaneous transvesical ureteroscopy for removal of distal ureteral stone in reimplanted ureter. *Urology* 1993; **42**: 313–6.
- 8 Wallis MC, Brown DH, Jayanthi VR, Koff SA. A novel technique for ureteral catheterization and/or retrograde ureteroscopy after cross-trigonal ureteral reimplantation. *J. Urol*. 2003; **170**: 1664–6.
- 9 De Castro R, Hubert KC, Palmer JS. Retrograde ureteral access after cross-trigonal ureteral reimplantation: a straightforward technique. *J. Pediatr. Urol*. 2011; **7**: 57–60.
- 10 Lusuardi L, Hruby S, Jeschke S *et al*. A new technique for retrograde flexible ureteroscopy after Cohen cross-trigonal ureteral reimplantation. *Urol. Int*. 2011; **87**: 260–2.
- 11 Khalil F, Tlifu M, Traxer O. Retrograde approach to a diverticular kidney stone through a vesicoureteral Cohen, s reimplantation: a novel surgical technique. *Case Rep. Urol*. 2013; **2013**: 247528.
- 12 Emiliani E, Talso M, Audouin M *et al*. Modern flexible ureteroscopy in Cohen cross-trigonal ureteral reimplantations. *J. Pediatr. Urol*. 2017; **13**: 329–31.
- 13 Rich M, Hanna MK, Smith AD. Removal of ureteral stone from patients with cross-trigonal ureteral reimplantation. *Urology* 1987; **30**: 133–5.

Editorial Comment

Editorial Comment to Successful percutaneous flexible ureteroscopy for treatment of distal ureteral stones under modified Valdivia position after Cohen reimplantation

Inoue *et al*. reported a successful case of percutaneous flexible ureteroscopy (URS) for large stones in the distal ureter after Cohen reimplantation.¹ The current treatment of large calculi with a complicated ureter poses a therapeutic challenge, and the best treatment modality remains controversial. Although shock wave lithotripsy represents a beneficial option, retrograde URS and percutaneous antegrade URS (ante-URS) are both recommended as a first-line treatment option according to the European Association of Urology guideline.²

Ante-URS is an alternative consideration for selected cases, including large impacted proximal ureteral calculi with severe hydronephrosis, or when the ureter is not amenable to retrograde manipulation, such as that in patients who have undergone urinary diversion and Cohen cross triangle ureteral reimplantation like the present case.^{3,4} Ante-URS was generally performed with a rigid or flexible nephroscope through a 24–30-Fr nephrostomy tract, in accordance with the

percutaneous nephrolithotomy methods. However, recently, flexible URS has allowed easy approach to the stone through a 12/14-Fr ureteral access sheath with minimal tract dilation and resulted in a higher stone-free rate for proximal ureteral stones of >15 mm.⁵ Ante-URS has some advantages. Despite the invasiveness of establishing a percutaneous tract that leads to the potential risk of hemorrhage, the antegrade approach maintains a low intrarenal pressure. This may significantly decrease the risks of postoperative inflammatory complications and septic phenomena. Furthermore, high irrigation flow and outflow ensures a clear visual field and flash fragments down into the bladder, eliminating the need to remove bits of stone ureteroscopically or to wait for the fragments to pass spontaneously.

However, as the authors mentioned, ante-URS has a great disadvantage of the risk to break down the flexible URS. The reason might include the interaction with the ureteroscope and fragments that return to the percutaneous sheath especially in the modified Valdivia position and excessive bending of the flexible ureteroscope shaft between the renal pelvis and ureter. Single-use URS may become familiar in cases of ante-URS in the future. Further randomized studies are necessary to compare the effectiveness, complications, and ureteroscopic durability of antegrade and retrograde URS.

This is an open access article under the terms of the Creative Commons Attribution-NonCommercial License, which permits use, distribution and reproduction in any medium, provided the original work is properly cited and is not used for commercial purposes.